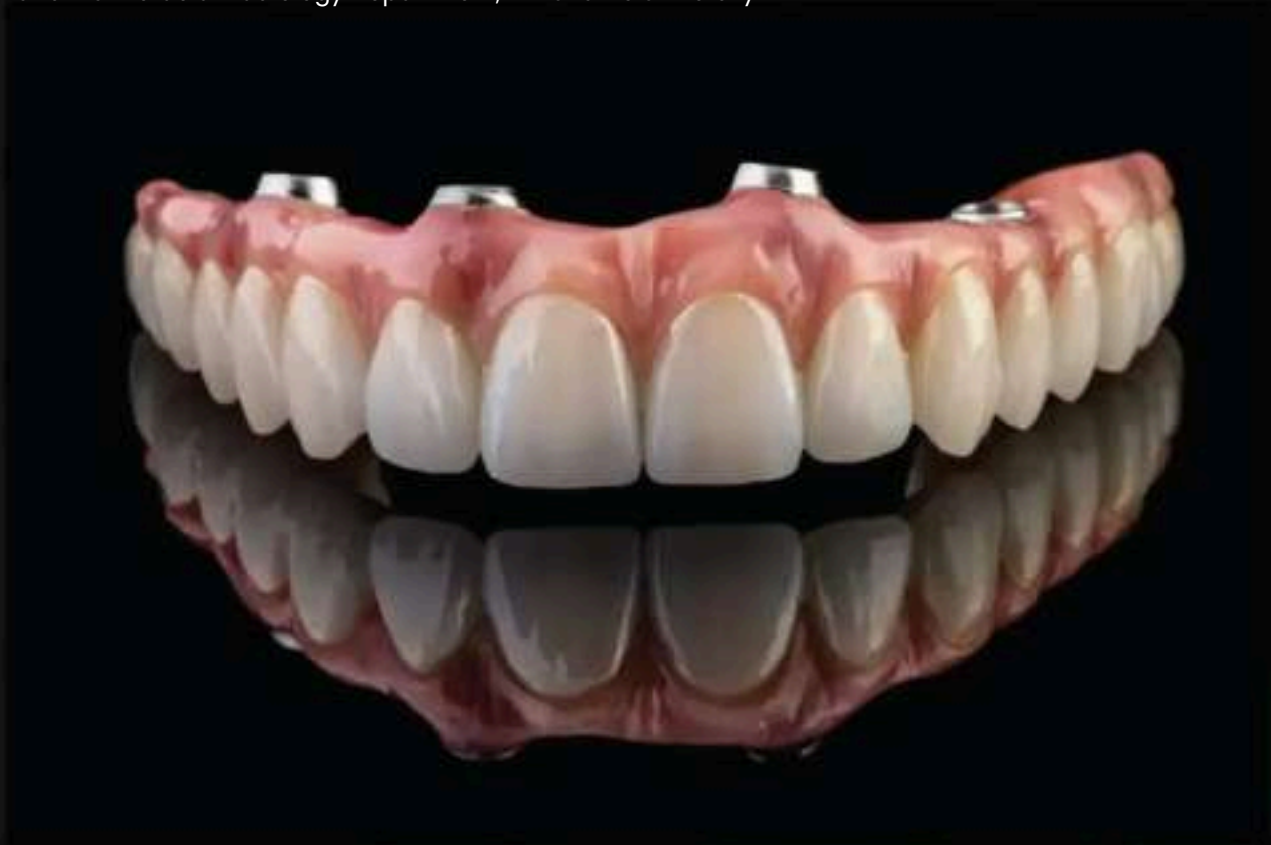

**Jeremy K. Ueno<sup>a</sup>, Ethar M. ElShennawy<sup>b</sup>**

<sup>a</sup> DMD, Board Certified Periodontist.

<sup>b</sup> Clinical Research and Development Specialist, ITXPROS. BDS, MSc. Oral and Maxillofacial Radiology Department, Ain Shams University



# Full – Arch

## Maxillary Rehabilitation

Using Stackable Guides  
and Digital Photogrammetry



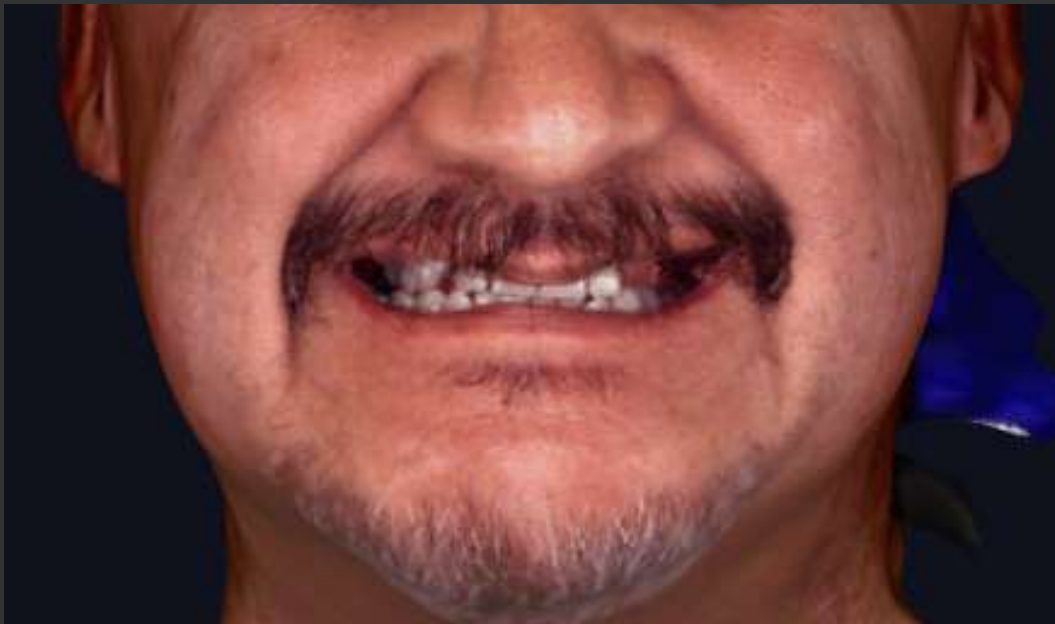## Abstract:

The integration of stackable surgical guides within a completely digital workflow stands as a safe, predictable, and viable treatment modality for complex full-arch rehabilitations. As demonstrated in this case, this technique establishes an accurate and efficient protocol—spanning from preoperative facial scanning to immediate load photogrammetry—that yields successful clinical outcomes. By mitigating surgical variables through guided precision, the clinical team delivered a restorative solution that addressed not only the functional pathology but also the patient's psychosocial well-being.



## Patient Profile & Chief Complaint:

"I just want to look good for my grandkids."



Ruben, a veteran, presented to the practice in June 2025. His chief complaint centered on severe dissatisfaction with his smile, leading to feelings of shame and social withdrawal.

- **Clinical Presentation:** Missing all upper left teeth; significant crossbite. (Fig. 1)
- **Barriers:** The patient initially declined treatment due to financial constraints associated with All-on-X procedures.
- **Solution:** Dr. Ueno's practice selected Ruben as the recipient of a pro-bono Veteran's Day case, removing the financial barrier.

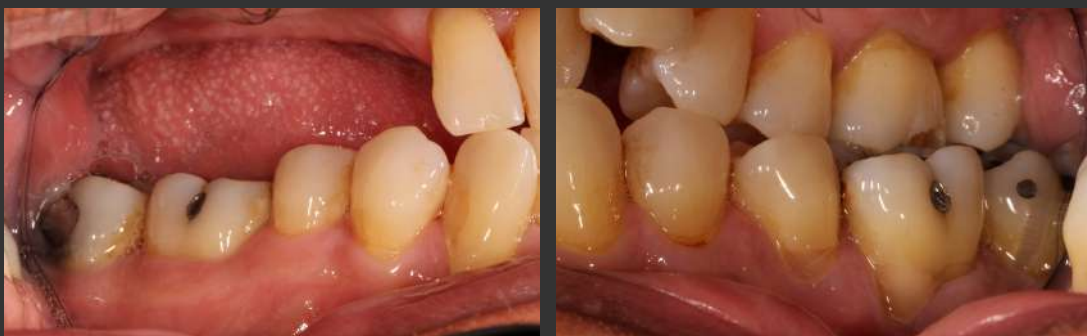

Fig. 1 Intraoral pictures of the left and right sides, respectively.



## Prosthetic and Surgical Planning Phase:

A robust digital planning phase served as the cornerstone of this case. By integrating CBCT imaging, facial scans, and intraoral bite records, Dr. Ueno and ITXPROS team executed a strictly prosthetic-driven workflow. This 'end-in-mind' approach allowed the team to reverse-engineer the surgical plan, ensuring precise implant positioning to maximize the Anterior-Posterior (AP) spread.


- **Preoperative Facial Scanning:** A facial scan was integrated to drive the aesthetics, ensuring the future incisal edge position would correct the crossbite and restore proper lip support. (Fig. 2)



Fig. 2 Preoperative full frontal facial scan using Rayface Facial Scanner.



- **Preoperative Intraoral Bite Scans:** The acquisition of intraoral bite scans digitizes the patient's Maxillo-Mandibular Relationship (MMR), enabling the precise analysis of restorative space and Vertical Dimension of Occlusion (VDO) required to virtually correct the crossbite within a functional, prosthetic-driven surgical plan. (Fig. 3)



A.



B.

Fig. 3 Intraoral Bite Scans. A, Bite scan of the right side. B, Bite scan of the incisors.



- **Digital Smile Design (DSD):** Prior to any surgical planning, a 3D Digital Smile Design was generated using the patient's facial scan. This allowed the team to visualize the correction of the crossbite and the restoration of the smile arc relative to the patient's facial expressions. (Fig. 4)



Fig. 4 Smile Design for the  
prosthetically driven approach.

- **Prosthetic-Driven Implant Placement:** Rather than placing implants solely based on available bone, the team utilized a "top-down" planning philosophy. The approved tooth position dictated the implant sites, ensuring that the screw access holes would be palatal or favorable, and that the transition line would be hidden by the high smile line. (Fig. 5)

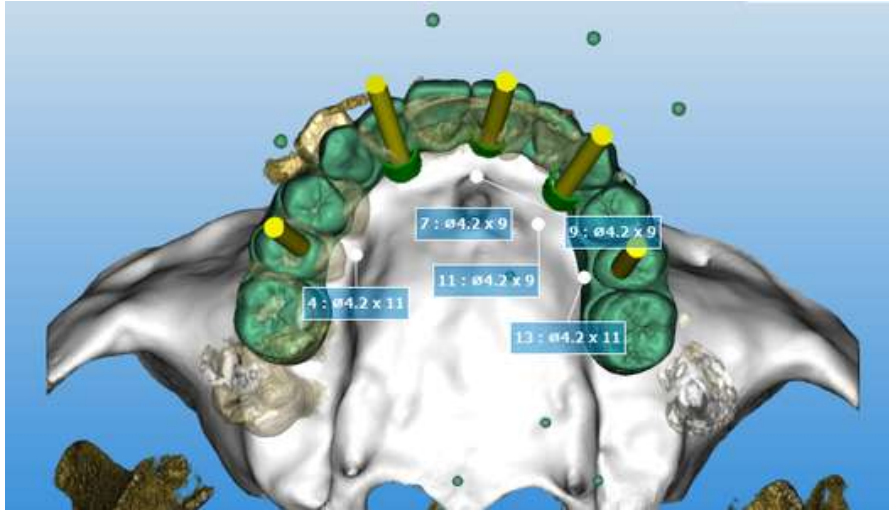


Fig. 5 Implant planning with respect to the approved prosthetic design.

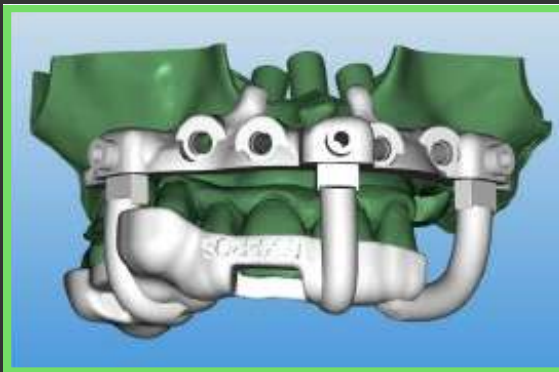


Fig. 6 A: Bone foundation piece with the teeth vertical

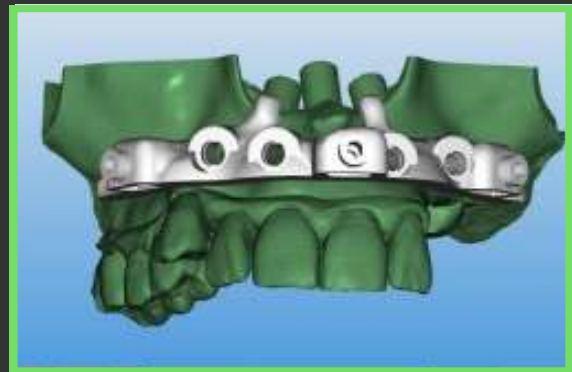


Fig. 6 B: Bone foundation piece with the plane of reduction.




Fig. 6 C: Anticipated bone reduction plane.




Fig. 6 D: Bone foundation piece with the osteotomy guide.




Fig. 6 E: Bone foundation teeth with the abutment timer .

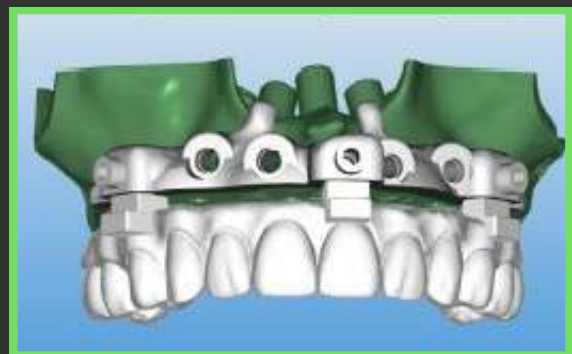

Fig. 6 F: PMMA pick-up attached to the bone foundation piece.

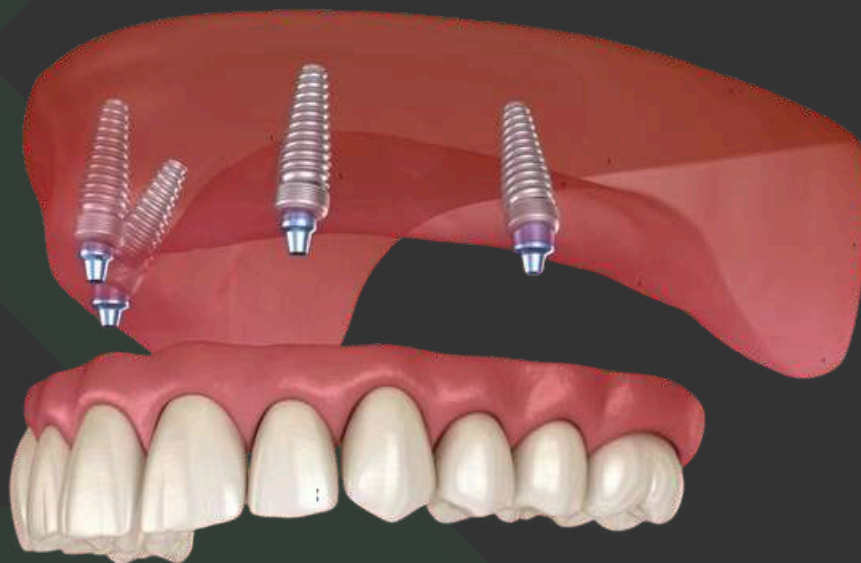


# Surgical Phase:

## Utilizing Stackable Surgical Guides

In edentulous cases presenting with irregular post-extraction ridges, guided bone reduction is often requisite to establish a viable foundation for implant stability. The integration of stackable surgical guides within a fully digital workflow enables the clinician to execute this reduction with sub-millimeter accuracy. This protocol calibrates the bone removal strictly according to the prosthetic plan, ensuring adequate restorative space is created without compromising the alveolar dimensions necessary for optimal implant anchorage.

- **Protocol:** Bone reduction was seated after vertical verification, followed by bone reduction.
- **Placement:** Five implants were placed.
- **Stability:** High primary stability was achieved on all fixtures, green-lighting the immediate load protocol.
- **Soft Tissue:** Due to bone reduction, ample soft tissue allowed for easy primary closure around the multi-unit abutments.
- **PMMA Delivery:** Immediately following implant placement, the final layer of the stackable guide system—the pre-fabricated PMMA pick-up—was utilized for immediate loading.





## Chairside conversion using the iCAM System:

With the implants achieving high primary stability and soft tissue showing favorable healing (Fig.7), the workflow transitioned instantly to the restorative phase. To eliminate the inherent inaccuracies, mess, and time-intensive nature of traditional denture conversions (such as acrylic "pick-ups"), Dr. Ueno utilized the ICAM photogrammetry system.

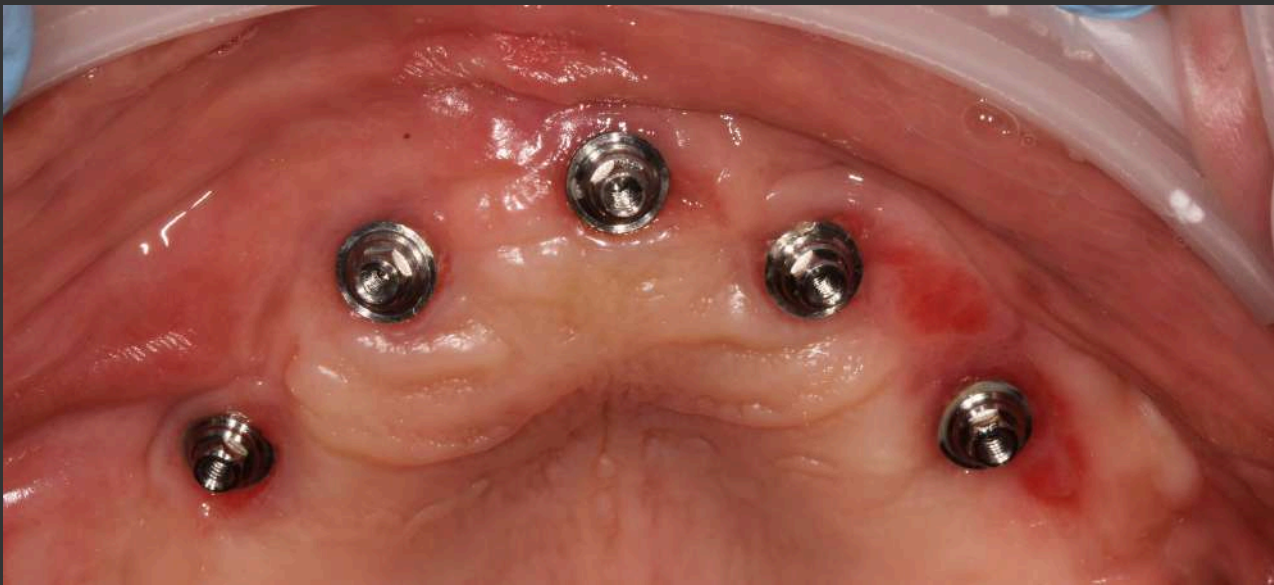

Fig.7 Post-operative intraoral view demonstrating implant positioning and favorable soft tissue healing.

- **Coordinate Capture vs. Scanning:** Unlike standard intraoral scanning, which relies on "stitching" images together—a process that can introduce cross-arch distortion in edentulous cases—the ICAM acts as a coordinate measuring machine. It captures the precise vector and position of the Multi-Unit Abutment platforms using specialized fiducial markers ("scan bodies"). (Fig.8)

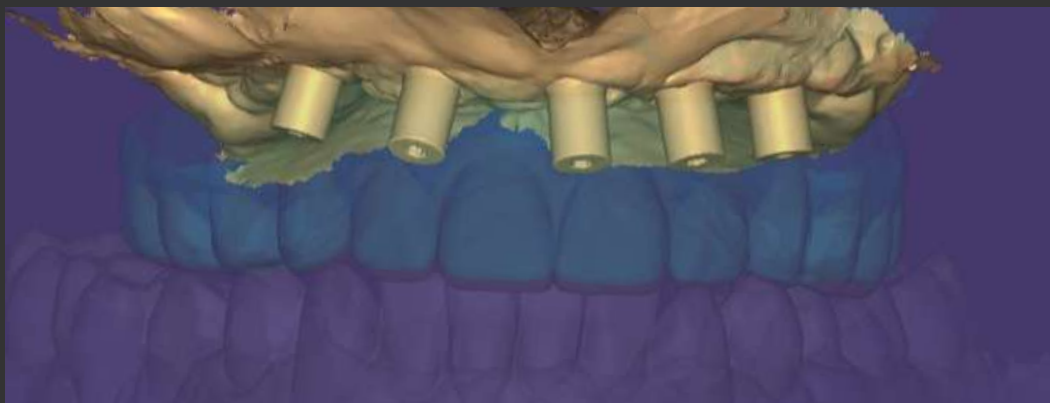


Fig. 8 ICAM scan bodies with the soft tissue scan.

- **Achieving Passive Fit:** A second milled PMMA prototype was fabricated based on the precise photogrammetry coordinates, ensuring a passive fit devoid of internal stress. This restoration acted as a clinical 'test drive,' permitting the validation of occlusion, phonetics, and soft-tissue adaptation prior to committing to the final zirconia material. (Fig. 9)

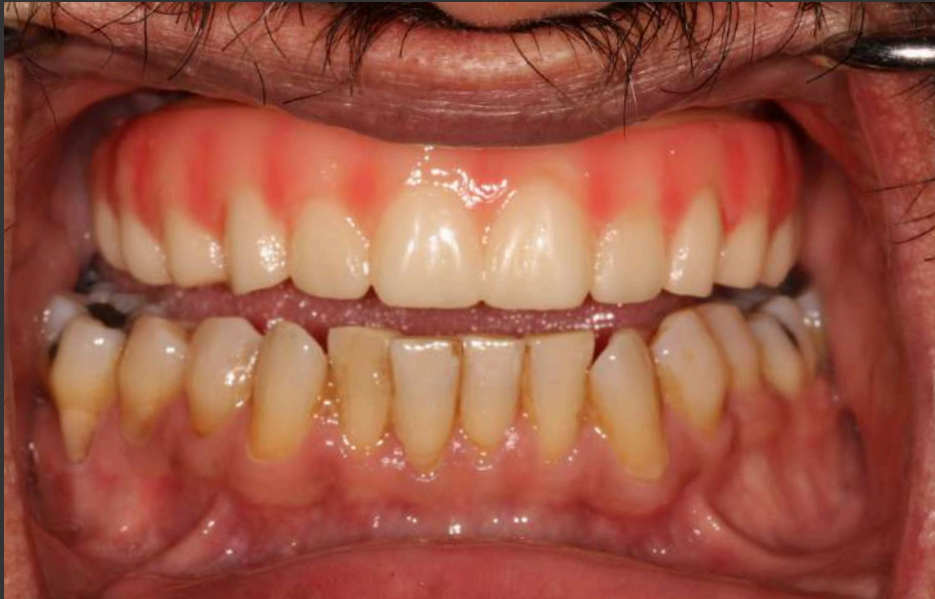
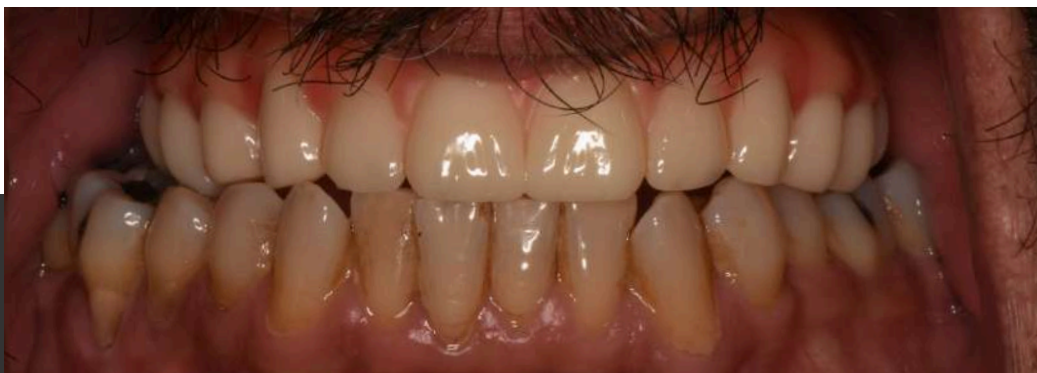
Fig. 9 The secondary milled PMMA after chairside conversion for confirmation of occlusion, aesthetics, and phonetics.

## Final Delivery (Zirconia)

Once the patient confirmed the aesthetics and function of the second PMMA prototype, the design was finalized.

- **Material:** The final prosthesis was milled from monolithic Zirconia, chosen for its high flexural strength and biocompatibility.
- **Outcome:** The final delivery required no chairside adjustments, validating the accuracy of the ICAM data and the integrity of the digital workflow. (Fig. 10)



A.



B.

**(Fig.10) A,** Post-operative retracted view demonstrating the final monolithic zirconia full-arch restoration in occlusion.

**B,** The new smile has restored not just function, but significant confidence, aligning with the goal of human-driven dentistry.