

EXPERTISE FOR ANIMALS



Credit: Andrew Skowron / We Animals

Visual Guide to Welfare Issues in Modern Broiler Production

Expertise for Animals [2026].
Visual Guide to Welfare Issues in
Modern Broiler Production.
Beta Version_July 2026

Published by

Expertise for Animals gGmbH
Oberlandstraße 26-35
12099 Berlin
Germany

Represented by Managing Directors

Eva Seifert and Marietheres Reinke

info@expertiseforanimals.com

Contact the author

m.reinke@expertiseforanimals.com

Find out more

[W: expertiseforanimals.com](https://www.expertiseforanimals.com)

[IG: @expertiseforanimals](https://www.instagram.com/expertiseforanimals)

Please note: The visuals used in this guide are drawn from investigative documentation of broiler production. While they illustrate real conditions observed in commercial production systems, in some cases there is no conclusive confirmation that the animals shown had the conditions described.

The information presented is based on research from peer-reviewed scientific literature, legal expert opinions, and publications by EU and national authorities. This guide is intended for educational and informational purposes and has been prepared to the best of our knowledge.

At Expertise for Animals, we believe that veterinary knowledge should not remain confined to specialist settings. It should be used where it is needed most: to make a real difference for animals.

Beta Version_July 2026

This guide is currently in beta version and is still being developed. The guide is shared at this stage to support learning and feedback. We welcome your feedback. If you have suggestions, corrections, or comments, please fill out this quick survey.

<https://forms.gle/HAepKqzjT324mFcr5>

Abnormally Rapid Growth

Broilers show an immensely increased growth rate compared to older strains or their wild ancestors, the Red Junglefowl. Their high body weight negatively affects several organ systems, especially the musculoskeletal system, the cardiovascular system, and the skin. They frequently develop growth-related health problems, including leg disorders and lameness, skin lesions such as contact dermatitis, and cardiovascular diseases.

What Can Be Observed?

- Juvenile birds [with combs and wattles that are not yet fully developed] with disproportionately large and heavy bodies
- Extremely broad breast muscles
- Strong, thick legs
- Altered gait pattern and lameness
- Immobile birds
- Birds unable to rise and stand
- Leg disorders
- Skin lesions
- Dirty underside of the body
- Birds lying on their backs
- Dead birds



Broiler chickens develop a disproportionately large body due to very fast growth.
Credit: Jo-Anne McArthur / We Animals

Why Does This Matter?


Broilers suffer from health problems directly linked to their high growth rate:

- Leg disorders and lameness
- Skin lesions [contact dermatitis]
- Cardiovascular diseases

These performance-related problems result in pain, suffering, and an increased risk of birds dying. Additionally, they experience severe restrictions in species-specific behaviour due to weight load and health problems.

Limitations of Visual Assessment

Cardiovascular diseases such as ascites syndrome ["pulmonary hypertension syndrome"] or sudden death syndrome are usually not directly identifiable in live broiler chickens but are instead detected in dead birds. For guidance on how to document such findings, see the chapter on cardiovascular diseases.



Modern broilers have larger breast and thigh muscles, heavier leg bones, and relatively short legs.
Credit: Andrew Skowron / We Animals

How Fast Growth Affects Broilers

The skeletal system cannot keep up with the rapid weight gain. Fast growth and high body weight put strong pressure on bones and joints that are still developing.

Fast-growing broiler chickens are forced to reduce their activity even under three weeks of age. Even at low stocking densities, many birds lie close to drinkers and feeders because they may otherwise be unable to reach food and water. In severe cases, growth-related health problems prevent broilers from reaching feed and water at all, ultimately resulting in death from starvation or dehydration.

Fast growth contributes to a wide range of health and welfare problems in broilers. Read more about leg disorders and lameness, skin lesions [contact dermatitis], and cardiovascular diseases in the following chapters, where these issues are described in more detail.



Large, young broiler chicken with down feathers still visible.
Credit: Jo-Anne McArthur / We Animals



Broiler chickens eat more often while lying down as they get older and more lame.
Note: The chicken's legs are spread far out to the sides. Leg disorders are discussed in a separate chapter.
Credit: Stefano Belacchi / Animal Welfare Observatory / We Animals

Excessive Breast Muscle Development

Excessive breast muscle development is a direct result of genetic selection in modern broiler chickens. Combined with intensive feeding practices and housing conditions broilers suffer from severe welfare consequences due to rapid growth. It causes significant negative impacts on both the physical health, their behaviour and mental well-being.

What Can Be Observed?

- Extremely broad breast muscles
- Changed body posture: the large breast muscles shift the bird's centre of gravity forward
- Waddling gait: the birds exhibit a wider stance, with their legs positioned further apart.
- Extended periods of sitting, short locomotor bouts followed by sitting, lying down instead of fleeing
- Impaired breathing

Why Does This Matter?

- Modified gait pattern and impaired walking ability due to high breast muscle mass
- Increased risk of muscle pathologies, e.g. painful deep pectoral myopathy
- Increased risk of breast skin lesions
- Severe restrictions in species-specific behaviour
- High breast muscle mass further exacerbates other painful conditions such as leg disorders and joint diseases
- Laboured breathing due to impaired respiratory function caused by high breast muscle mass
- Pain and suffering

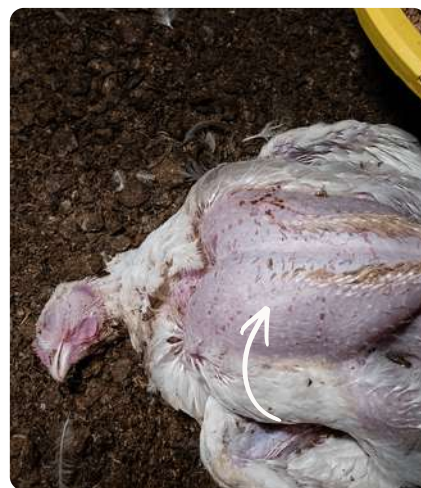Limitations of Visual Assessment

Many of the most severe welfare-relevant consequences of excessive breast muscle development are not externally visible. They can only be detected through veterinary and pathological examination:

- Muscle lesions
- Reduced cardiovascular and respiratory capacity



Broiler chicken with increased breast muscle mass.
Credit: Jo-Anne McArthur / We Animals



When broilers lie on their back after death, their prominently enlarged breast muscles are clearly visible. Credit: Benjamin Blomstedt / We Animals


How Enlarged Breast Muscles Affect Their Body Posture

Unlike laying hens, which can maintain an upright posture due to relatively low breast muscle mass, broilers develop such enlarged breast muscles that their centre of gravity is shifted forwards, resulting in a markedly altered body posture.


Modern broilers display a characteristic waddling gait and a significantly longer stance phase during locomotion, meaning they spend significantly longer periods standing on both legs between steps.

The altered movement pattern resulting from their body conformation may be influenced not only by mechanical inefficiency but also by pain.

Laying hens have considerably less breast muscle mass and place the supporting leg directly under the body's centre of gravity during locomotion, resulting in a more linear body movement.



Laying hen walking in an upright position.
Credit: Jo-Anne McArthur / We Animals



The broiler chicken shows a wide stance and a strongly forward-shifted centre of gravity.
Credit: Andrew Skowron / We Animals

Footpad Lesions

Inflammation of the skin of the footpads and toes is referred to as pododermatitis or footpad dermatitis. The inflammations mostly arise through direct contact of the skin with wet litter. Wet litter softens the footpads, thereby making them more susceptible to lesions and inflammation. Footpad lesions occur in most broiler farms. Severe lesions cause pain and reduced mobility.

What Can Be Observed?

- Lesions on the underside of the foot
- Discolouration of the footpads and toes
- Ulcers and abscesses on the underside of the foot
- Swollen footpads

Why Does This Matter?

- Inflammation, placing continuous stress on the immune system
- Damages the skin barrier, increasing the risk of secondary infections
- Extreme pain, especially in severe erosive or ulcerative lesions
- Impaired locomotion, often visible as limping or unsteady gait
- Reduced mobility results in less access to feed and water leading to hunger and thirst
- In older birds the continuous weight-bearing on affected feet aggravates lesions and pain
- Suffering
- Can trigger secondary lesions (e.g. hock and breast burns) due to altered posture and lying behaviour

Limitations of Visual Assessment

Since the lesions are located on the underside of the feet, they are difficult to see without handling the chickens. Additionally, crusts, litter material, and feces may adhere to the skin lesions and can obscure them. Footpad lesions are easy to see in dead animals, because often the feet are fully exposed.



Severe footpad lesions are clearly visible.
Credit: Andrew Skowron / We Animals



The large central footpad is swollen and discoloured.
Credit: Haig / World Animal Protection / We Animals

How Footpad Lesions Develop

They usually start with a change in skin colour. If the footpads continue to be exposed to pressure and irritation, the skin becomes thickened and calluses form. Cracks may develop in the hardened skin.

In more advanced stages, the skin can grow abnormally, forming rough, cauliflower-like tissue. The surface may also become worn down and covered with brown scabs. These erosions can develop into ulcers, with inflammation spreading into the deeper tissue under the skin.

Broiler chickens affected by footpad lesions show an unsteady or limping gait. They spend more time resting on their hocks instead of standing or walking.



Turning chickens on their backs is stressful.
Credit: Victoria de Martigny / We Animals



There may be a painful ulcer under the scabs. Note: The broiler chicken rests on the hocks instead of standing or walking. An animal can have more than one health problem. The bird is highly likely to have additional health problems, as the legs are markedly splayed. Credit: Bear Witness Australia / We Animals

Hock Burn

Hock burns are a typical form of contact dermatitis in broiler chickens, alongside footpad dermatitis and breast burn. Hock burns become increasingly common as broiler chickens grow. The development is linked to increasing body weight, reduced activity, and prolonged contact with wet litter.

What Can Be Observed?

- Discolouration of the skin on the hock joints
- Cracks and abrasions
- Dark black scabs
- Ulcers and open wounds
- Litter clumping or sticking to the skin

Why Does This Matter?

- Pain due to skin lesions and secondary infections
- Entry of bacteria through damaged skin barrier leading to local and systemic inflammation
- Impaired mobility and reduced activity levels
- Reduced access to feed and water due to locomotion difficulties
- Locomotion impairment affecting most other behavioural needs
- Lameness in severe cases

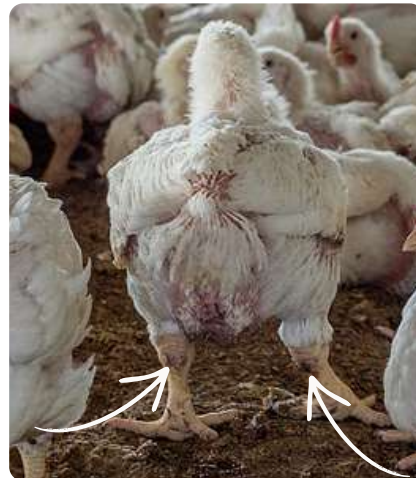
How Hock Burn Develops

Hock burn lesions are caused by prolonged contact with wet litter and ammonia, which chemically damages the skin. High stocking densities increase the risk and severity of hock burns, largely by worsening litter quality.


Hock burns begin with skin cracks and abrasions and can progress to deep ulcers. The open wounds increase the risk of bacterial infection, causing inflammation, lameness, and pain.



Wounds at the hock joint are clearly visible.
Credit: Andrew Skowron / We Animals



Intermediate severity of hock burn: Skin discolouration, dark black scabs and skin irritation.
Credit: Jo-Anne McArthur / We Animals



The hock joints show skin discolouration and small dark black scabs. The feathers on the underside of the body are also visibly soiled. Credit: Victoria de Martigny / We Animals



At first glance, details such as changes to the hock joints are easy to overlook.
Credit: Jo-Anne McArthur / We Animals

Take a closer look.

Breast Burn

Breast burn is a form of contact dermatitis in broiler chickens affecting the skin on their underside. Due to constant contact with the ground, the breast area is particularly exposed to poor litter conditions, which contribute to breast burn. It is characterized by inflammatory skin changes that can range from early redness to more severe tissue damage.

What Can Be Observed?

- Skin redness, ranging from dark pink to red and large brown patches
- Scabs on the breast skin
- Ulcers with black fluid [exudate]
- Breast blisters

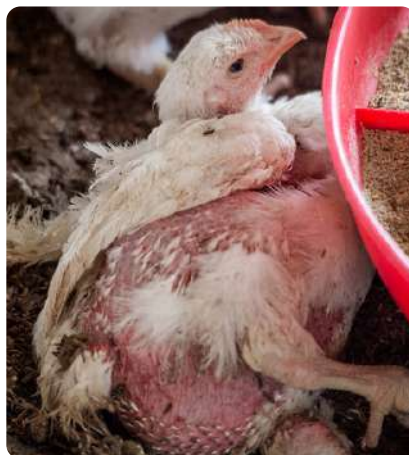Why Does This Matter?

- Inflammation and tissue damage from lesions
- Pain due to contact dermatitis
- Breast lesions can be particularly painful during lying, as birds rest directly on the affected area. As a result, normal resting behaviour itself can become uncomfortable or painful.
- Potential secondary infections caused by invading pathogens further damage the tissue

Limitations of Visual Assessment

Breast skin lesions are often hidden when birds are lying on the ground, as they rest directly on the affected area. Feathers and dirt can cover or partially obscure changes in the breast skin. Breast blisters and breast skin lesions may therefore not be easy to see.

Skin discolouration can also have other causes. For example, circulatory problems may lead to dark red discoloration due to bleeding into the tissue. Stress can also affect the skin colour of chickens.



Overall, the broiler is in poor general condition. The entire skin on the body is reddish in colour, indicating inflammation. Credit: Jo-Anne McArthur / We Animals



The dead chick shows dark red changes in the abdominal area, but these are not caused by contact dermatitis. In the 'armpit', the skin is also dark red in colour, which may indicate cardiovascular disorders. Credit: Jo-Anne McArthur / Animal Equality / We Animals

How Breast Burns Develop

Breast burn develops in the same context as other contact dermatitis conditions and are linked to prolonged contact with wet and ammonia-contaminated litter, as well as reduced mobility and increased time spent sitting or lying.

Breast burns are inflamed areas on the breast with brown to black crusts. Redness of the skin [erythaema] is considered a primary sign of contact dermatitis. In severe cases, the skin can break down and form open sores.

Breast lesions usually develop more slowly and are less common than foot lesions. The number of affected birds varies widely. Breast lesions become more common and more severe as birds get older.

Breast blisters [sternal bursitis] are fluid-filled sacs on the breastbone that enlarge due to repeated pressure or rubbing. They occur rarely in broilers.



The dark red skin may be caused by stress, contact dermatitis, or both. The bird shows poor overall condition (lying on their back, soiled feathers, breathing with an open beak). Credit: Benjamin Blomstedt / We Animals



Prolonged contact with wet litter leads to the development of contact dermatitis. Breast burn may not be easily identified due to the soiled breast area, but if you look closely, you can see brown scabs on the skin. Credit: Molly Condit / Sinergia Animal / We Animals

Leg Disorders and Lameness

Leg disorders refer to a group of different pathological conditions affecting the legs of broiler chickens. Fast growth increases the risk of leg problems and lameness. Genetics, feeding practices and housing conditions all affect growth and, consequently, leg health. Leg disorders may be infectious, developmental, or degenerative in origin.

What Can Be Observed?

- Impaired locomotion (uneven gait, limping, jerky, hobbled or unstable walk, walking more slowly and taking shorter steps)
- Splayed legs
- Valgus (knock knees) & Varus (bowed legs)
- Sitting on their hock
- Prolonged lying and birds preferring to remain crouched when not forced to move
- Behaviours like eating are performed in a sitting position instead of standing
- Dropping their wings to support the body
- In severe cases, birds may only be able to move using their wings or by crawling on their hocks

Why Does This Matter?

- Pain and physical discomfort
- Lameness, impaired mobility, or complete inability to walk
- Broiler chickens remain motivated to express locomotor behaviour, they are physically unable to do so
- Species-typical behaviours, such as dust-bathing, decrease due to high body weight and leg disorders, leaving the birds frustrated, stressed, and suffering
- Reduced mobility results in less access to feed and water leading to hunger and thirst
- Development of secondary welfare problems, such as hock burns and breast lesions, due to prolonged contact with wet litter
- Prolonged suffering, which may last for much or most of the production period
- Death in severe cases or due to on-farm killing

Limitations of Visual Assessment

The exact cause of leg problems and lameness can usually only be determined through a post-mortem necropsy and in some disorders with a histological examination.

Additionally, broilers may mask signs of poor health or welfare, especially in high-stress situations. This means that birds can sometimes appear more active or fit than they actually are, even when they are experiencing pain, illness, or reduced mobility.



The right leg is twisted, and the bird shows bowed legs.
Credit: Lukas Vincour / Zvirata Nejime / We Animals

How Leg Disorders and Lameness Develop

Leg problems in broiler chickens have several causes that often work together. The most important factor is fast growth: Modern broiler chickens are bred to grow very quickly and efficiently convert feed into body weight. This fast growth puts heavy stress on bones and joints that are still not fully developed. The skeleton does not mature fast enough to support the rapid increase in body weight. Factors like management conditions, nutrition, and infections also play a role.

Additionally, infectious or non-infectious bone damage and pain in the spine can lead to lameness as well, sometimes called vertebral lameness or kinky back.



Birds suffering from so called vertebral lameness are unable to walk anymore. They sit with their feet pointing forwards in a hock-sitting posture.
Credit: Haig / World Animal Protection / We Animals



Femoral head necrosis affects the hip joint and can lead to complete fracturing of the femoral head

Femoral head lesions can become so severe in the terminal stage that necrosis and fracture of the femoral head lead to almost complete loss of mobility. This typically occurs in the fifth week of life. Credit: Andrew Skowron / We Animals

Cardiovascular Diseases

Ascites (Pulmonary Hypertension Syndrome) and Sudden Death Syndrome are common in fast-growing broiler chickens. In Sudden Death Syndrome, death occurs very quickly and clinical signs are present only for a short time. In contrast, Ascites develops gradually, causing broiler chickens to suffer over a longer period of time as the condition progresses.

What Can Be Observed?

- Sudden Death Syndrome [flip-over]:
 - Dead broiler with good body condition and a full crop
 - Mostly found lying on the back with the wings outstretched
 - Often one leg raised in the air
- Ascites
 - Live birds: Large broilers silently gasp for air with a high breathing rate
 - Dead birds: Moderate to poor body condition with a large stomach filled with fluid and breast muscles appear darker or blue

Why Does This Matter?

- Ascites: Prolonged suffering
 - Fluid in abdomen which increases internal pressure and compresses the air sacs, causing significant breathing difficulties and distress
 - respiratory failure due to oedema in the lungs
- Sudden Death Syndrome: Severe form of heart failure without any chance for recovery
- Death due to heart failure in both cases



Typical characteristics of chicks affected by sudden death syndrome. Credit: Stefano Belacchi / Animal Welfare Observatory / We Animals

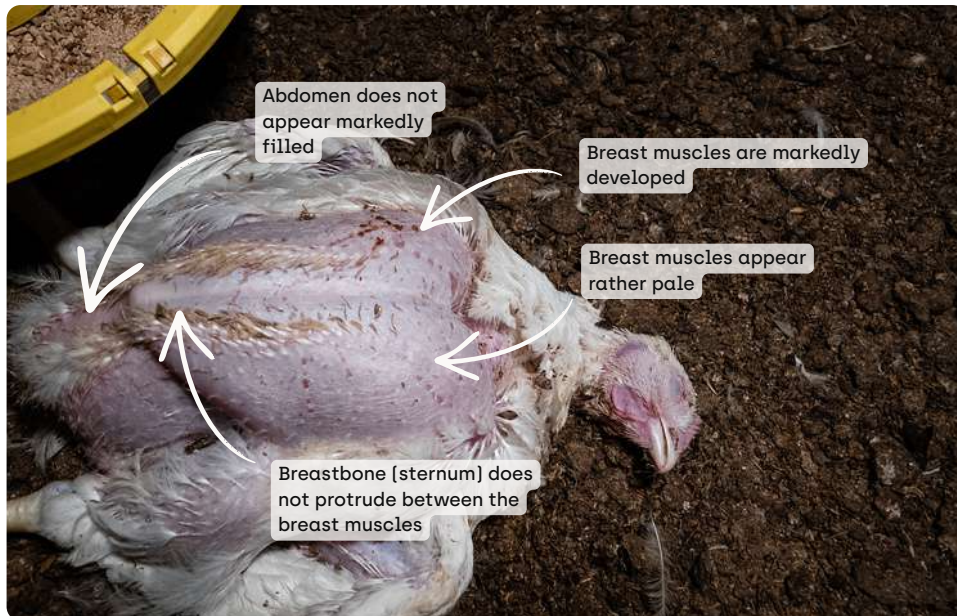
How Cardiovascular Diseases Develop

Ascites syndrome is a cardiovascular and metabolic disorder that leads to overload of the right side of the heart. Affected birds eventually develop right-sided heart failure, which can ultimately be fatal. Ascites can affect broiler chickens from as early as a few days of age, but early stages often remain hidden until later in the growing period.

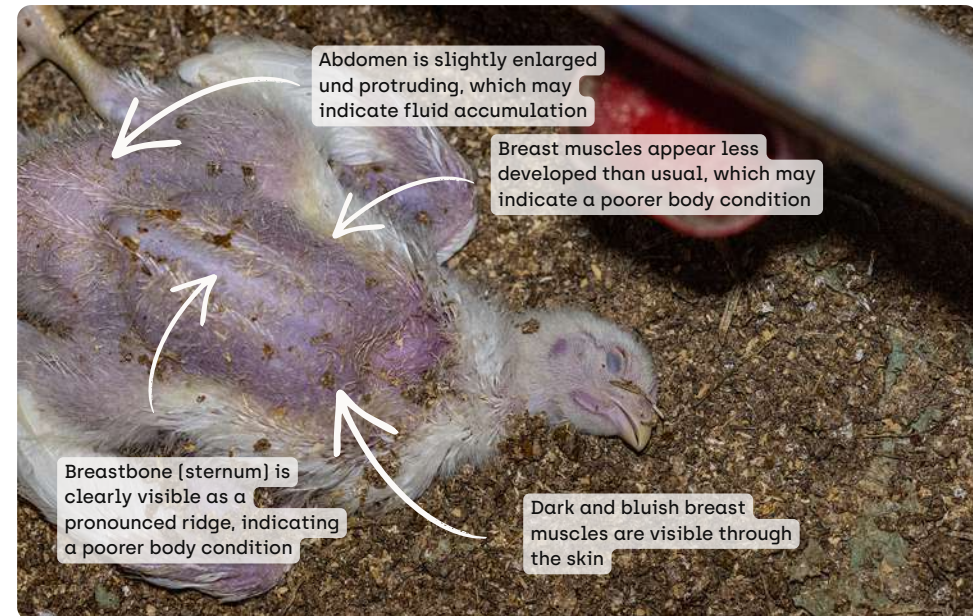
Sudden Death Syndrome causes broilers to die abruptly due to cardiovascular failure. The condition is also linked to fast growth and increasing body weight, but the exact cause is not fully understood yet. Affected birds usually show no prior signs. Just before death, they may lose balance, flap their wings, and show strong muscle contractions. Some birds even jump up into the air and fall down dead on their back or sometimes their stomach. Death typically occurs within less than a minute after the first signs.

Limitations of Visual Assessment

Sudden Death Syndrome and Ascites cannot be definitively diagnosed through visual inspection alone, as confirmation requires post-mortem pathological analysis. However, in some cases, signs shortly before death as described above may provide indirect indications, although these are not specific.



Dead broiler with high body weight and large breast muscles, which indicates a sudden death compared to a chronic condition. Credit: Benjamin Blomstedt / We Animals



A dead broiler showing signs consistent with ascites, which can only be definitively confirmed through pathological examination. Credit: Jo-Anne McArthur / We Animals

Compare the two images to identify differences.

