



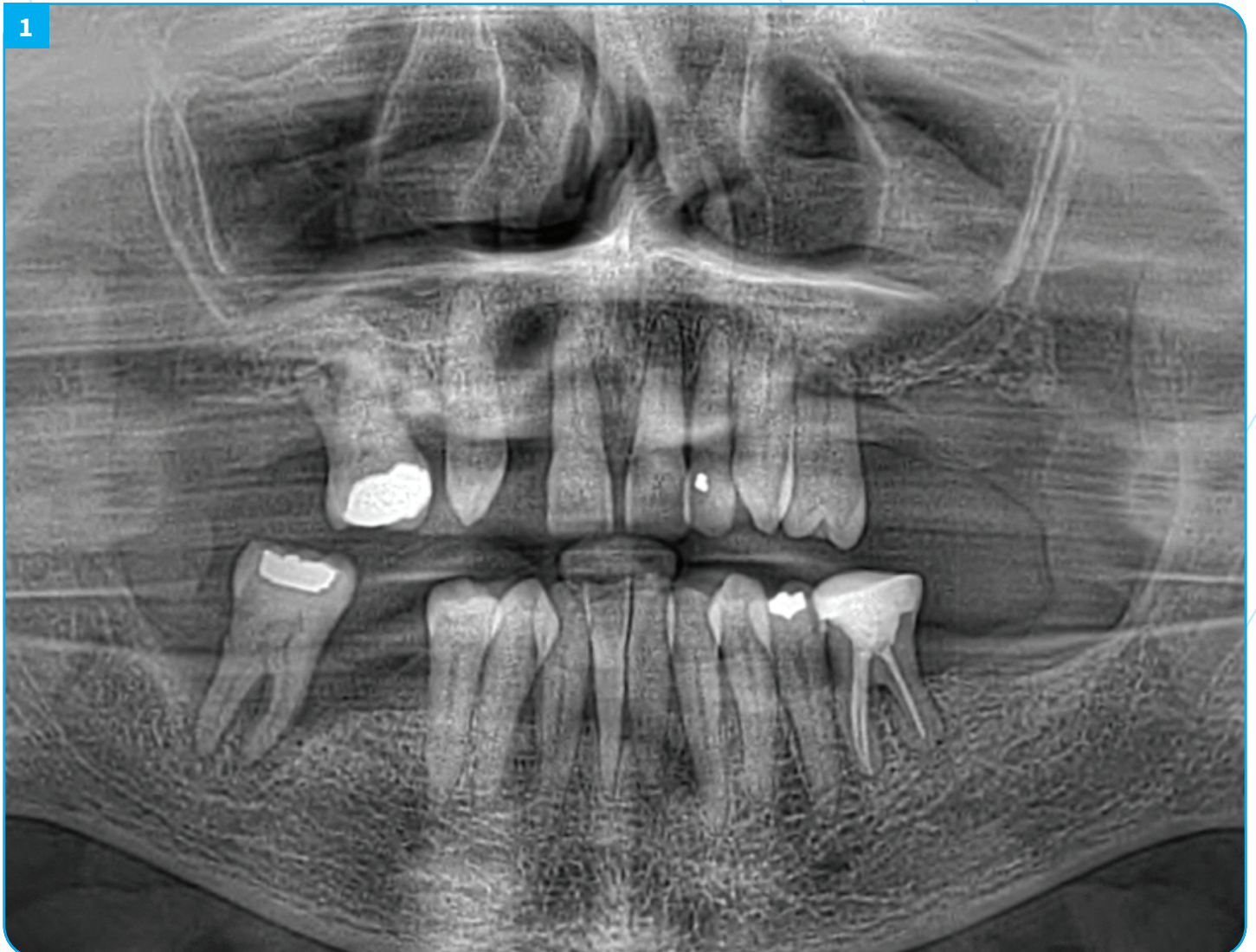
## CLINICAL CASE REPORT

**Surgeon: Dr. Amir Ashourioun | Prosthetist: Dr. Simon Budak**

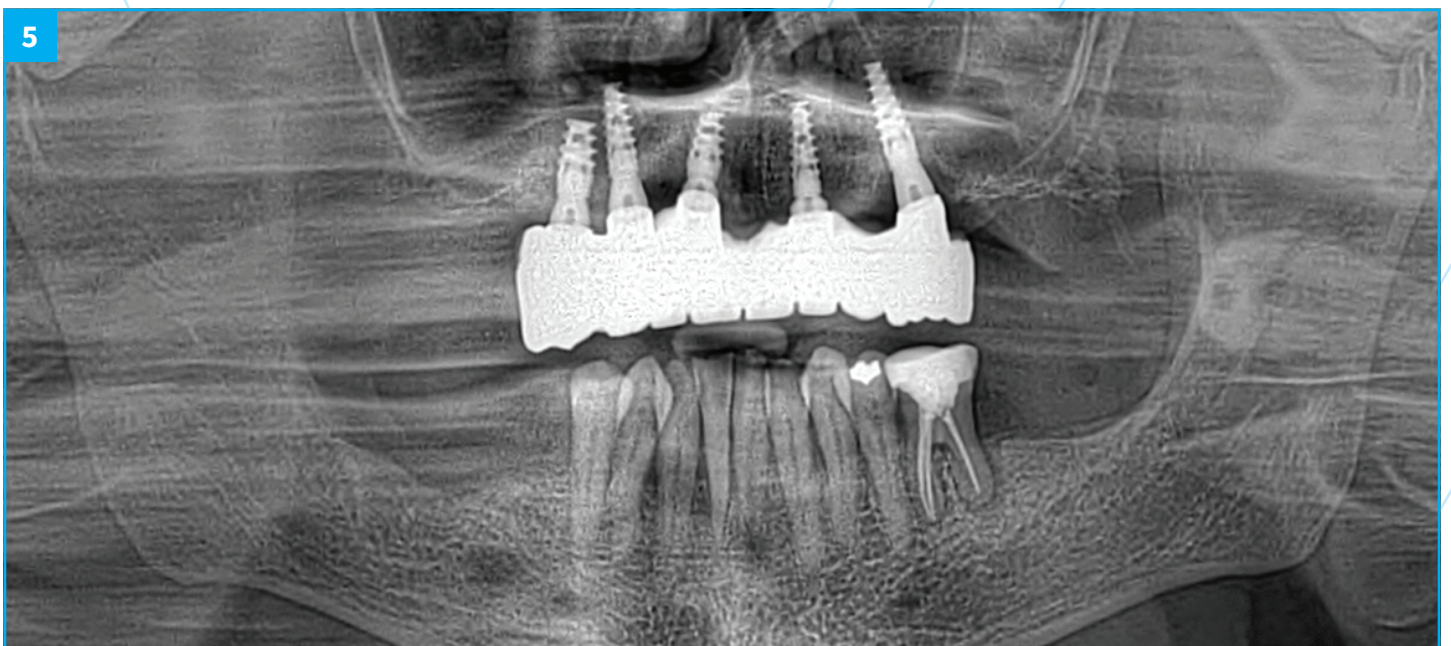
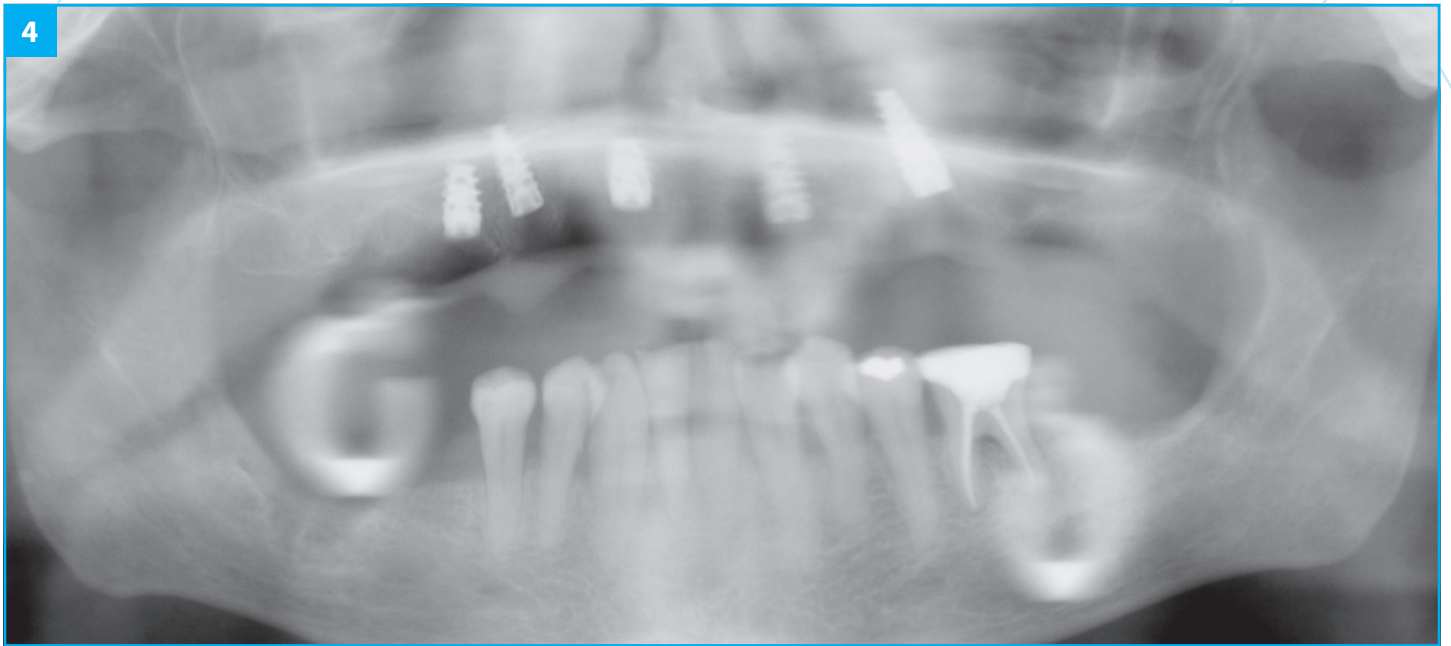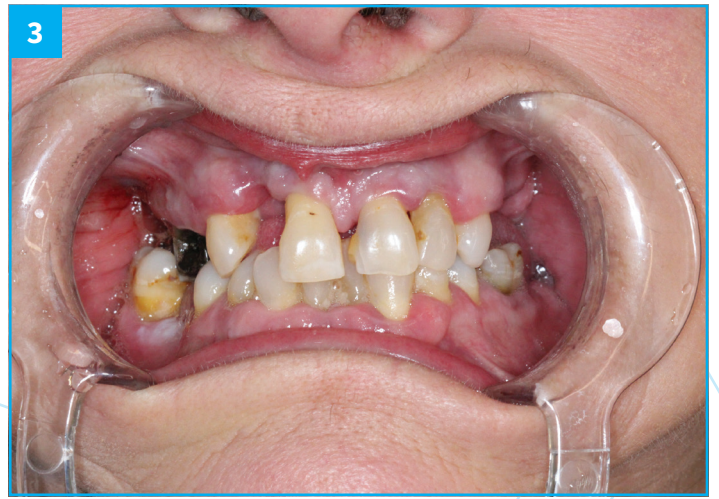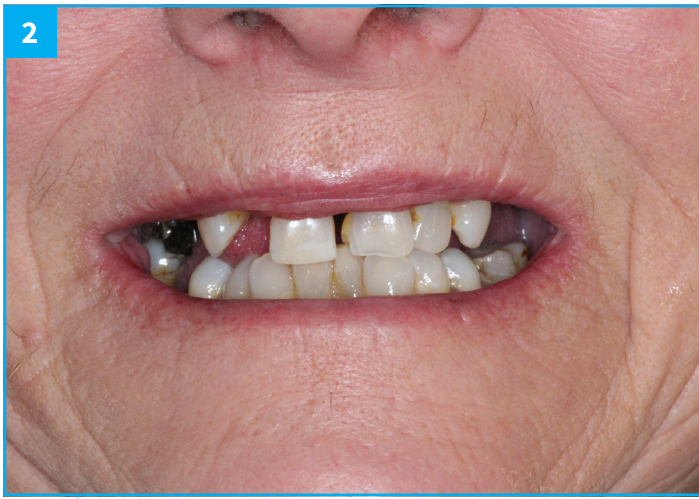# Full-Arch Implant Rehabilitation of a Severely Atrophic Maxilla Using DSI Conical Implants

**Patient:** Female, 61 years old

The patient presented with multiple mobile teeth in the maxilla caused by chronic marginal periodontitis. Several treatment options were discussed, and the final decision was to proceed with an implant-supported fixed complete denture.



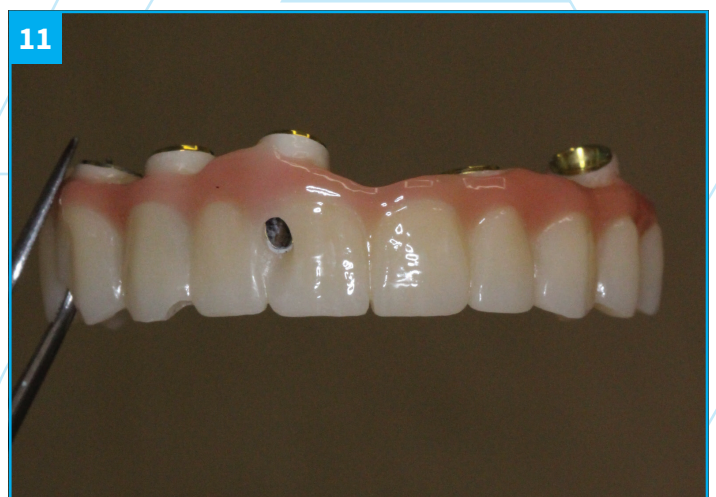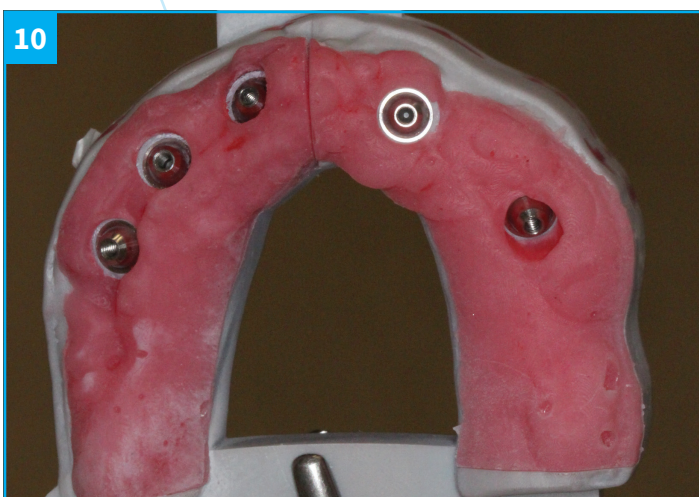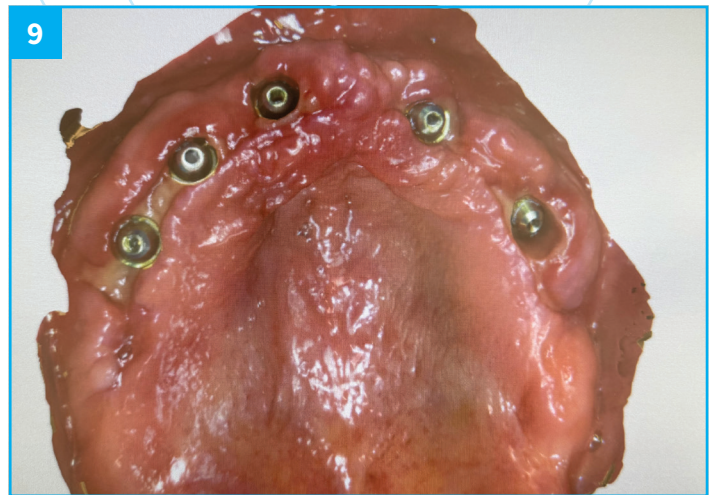
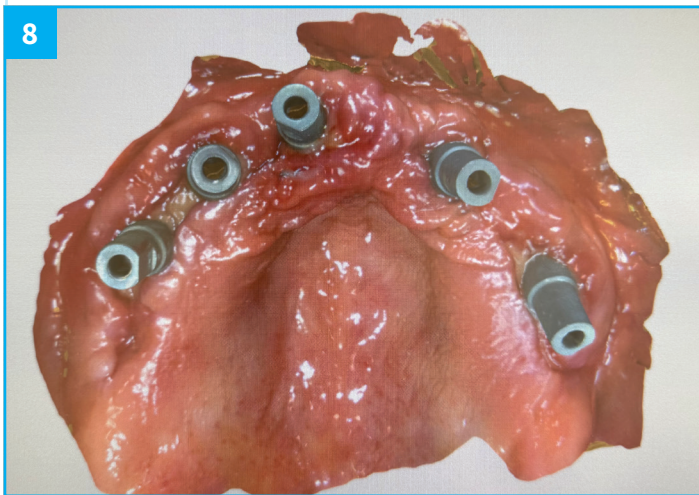
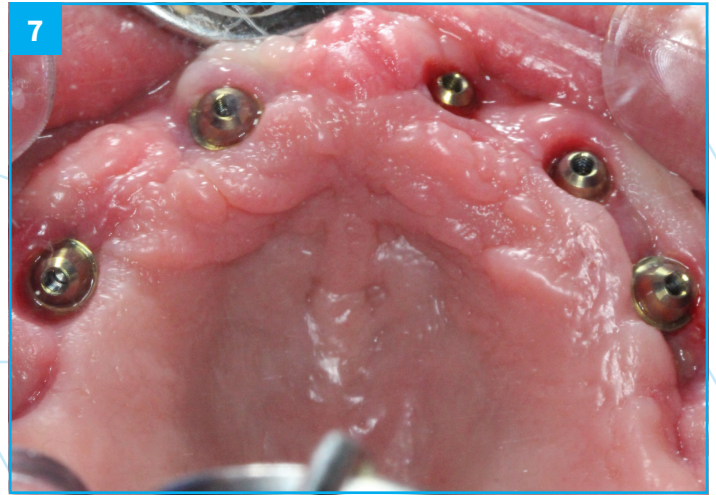


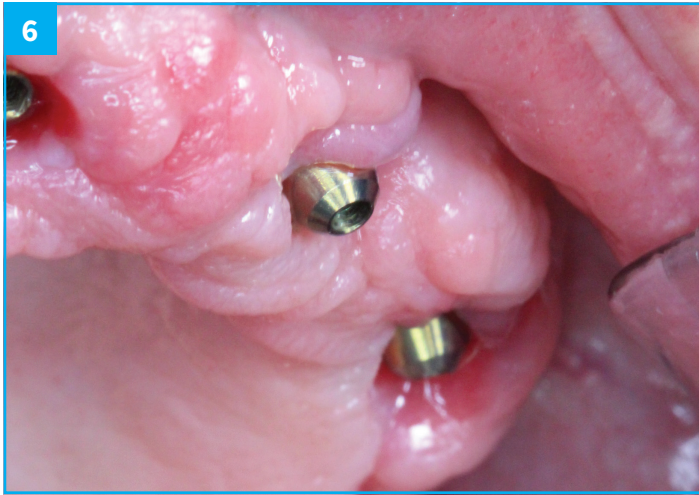

Due to a severely atrophic maxilla, all remaining teeth were extracted under local anesthesia. Immediately following extraction, five DSI conical implants were placed in positions 15, 13, 11, 21, and 24. Cover screws were inserted, and a complete denture was provided as a temporary solution one week post-surgery.

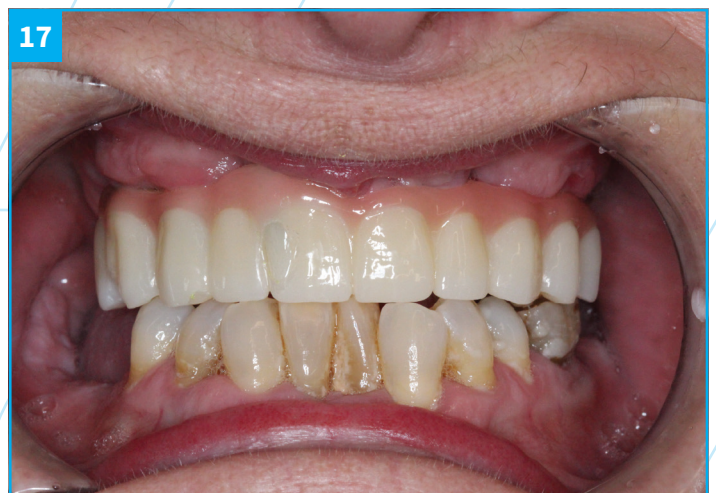
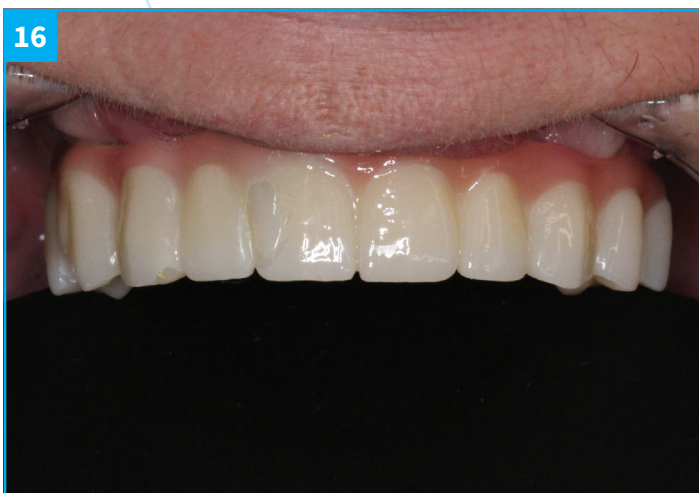
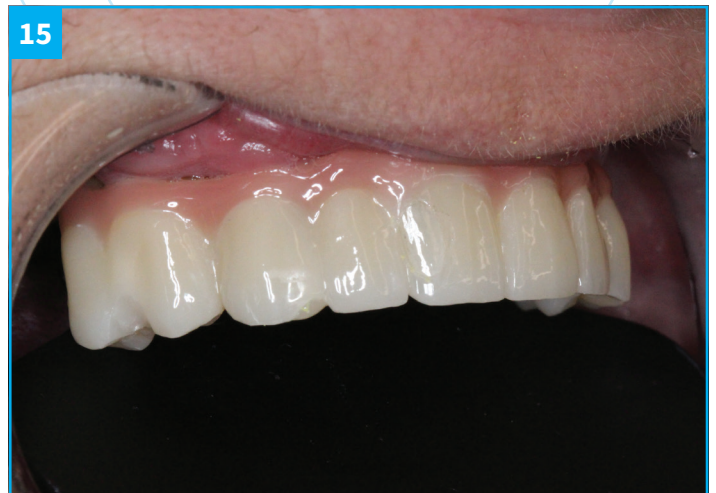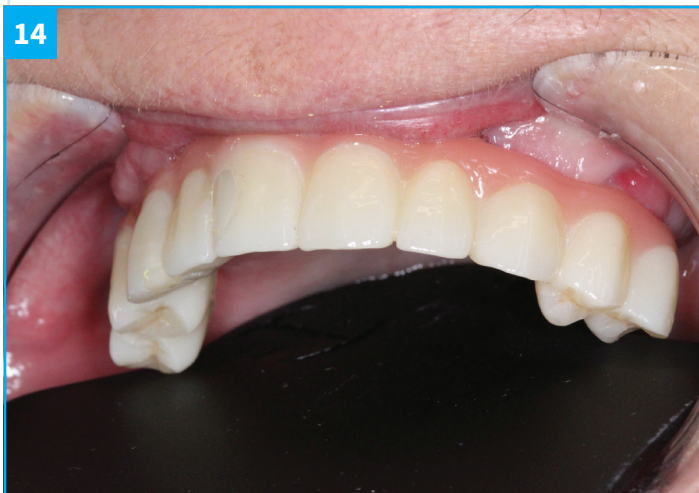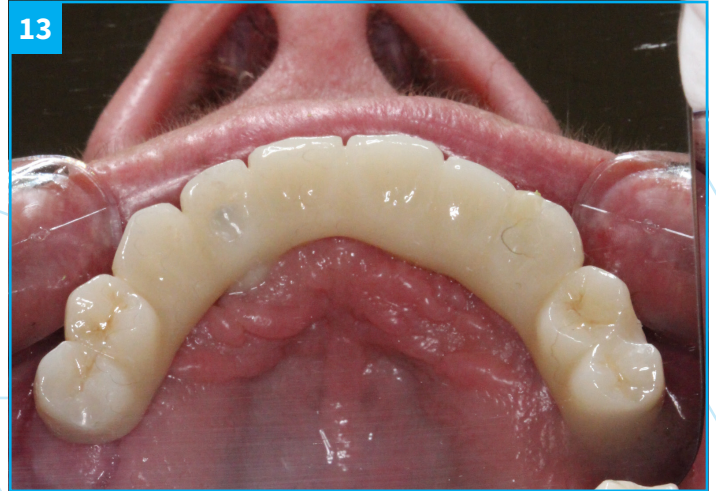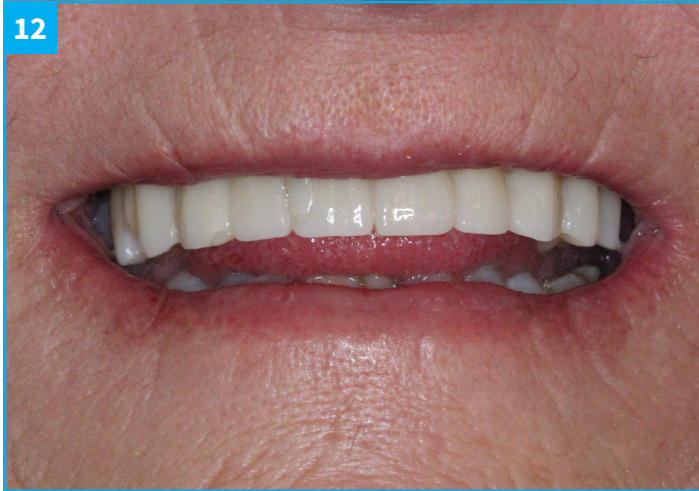After six months of osseointegration, the cover screws were replaced with DSI multi-unit abutments (MUA) 1.6, and healing caps were inserted. One week after the second-stage surgery, digital impressions were taken at the MUA level using DSI scan bodies and a Dentsply Sirona Primescan intraoral scanner.





Two weeks later, the patient received her FP2 suprastructure, which was mounted using prosthetic screws. The screw access openings were sealed with composite, and custom-made zirconia posts were placed where visible for optimal esthetics.







**Dr. Simon Budak,**  
Doctor of Dental Medicine,  
Semmelweis University  
M.Sc. in Implantology and Dental Surgery,  
University of Duisburg-Essen, Germany  
Specialization in implant-prosthetics,  
University of Oslo



**Dr. Amir Ashourioun,**  
Oral Surgeon,  
Semmelweis University  
Doctor of Dental Medicine,  
Semmelweis University

**Materials used for this case:**

**Manufactured by DSI Dental Solutions**

DSI Premium Conical Connection Implants

DSI Healing Caps Concave

DSI Multi-Unit Abutments (MUA) 1.6

DSI Scan Body (MUA level)

