PROPHET NSCLC™

by ONCOHOST GUIDED ONCOLOGY

Case Studies

PROPHET *NSCLC*™

Case courtesy of Cancer Care Associates of York (CCAY)

Case Study: PD-L1 QNS, PROPHET® POSITIVE, SCORE 9.2

PATIENT PROFILE

78-year-old male

Presented with back pain; found to have a right lower lobe lung mass with bone metastases.

PATIENT HISTORY

History of resected Stage II colon cancer (2010), no adjuvant therapy. Diabetes Mellitus, Hypertension, ECOG 1.5. Diagnosed with mNSCLC.

IMAGING

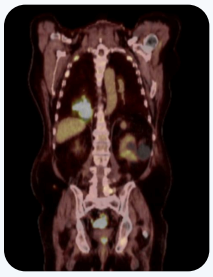

PET-CT: RLL mass + bone metastases

TESTING RESULTS

PD-L1 TPS

QNS (insufficient tissue)

Blood TMB

9.6 mut/Mb

NGS

Insufficient tissue for testing

Blood NGS

No actionable mutations identified

DIAGNOSIS

CT-guided lung biopsy: poorly differentiated malignancy most consistent with **metastatic NSCLC.**

PROPHET*NSCLC*® RESULT

Patient's PROPHET® Result: POSITIVE | Score 9.2/10

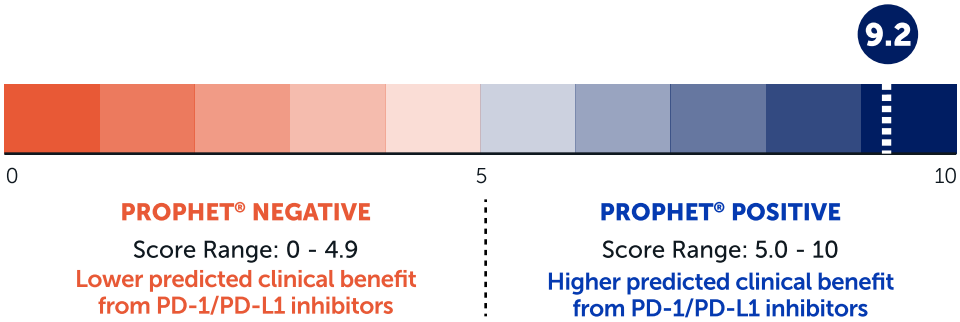

HOW PROPHET*NSCLC*® INFLUENCED THE TREATMENT DECISION

PD-L1 status was unknown due to insufficient tissue. Given the patient's age and frailty, the physician was hesitant to use chemotherapy. The liquid biopsy ruled out an actionable driver mutation, and the **PROPHET® result was POSITIVE, score 9.2**. Given the PROPHET score indicating a high probability of clinical benefit, the physician was comfortable moving forward with monotherapy.

Treatment Decision

Pembrolizumab monotherapy selected, with ongoing monitoring via PET/CT.

ONCOHOST GUIDED ONCOLOGY

OncoHost Inc. | 1110 SE Cary Parkway, Suite 205 | Cary, NC 27518 | oncohost.com
Client Services: 1-855-950-2112 | Fax: 1-919-415-1308 | Email: contact@oncohost.com

PROPHET *NSCLC*™

Case courtesy of Cancer Care Associates of York (CCAY)

Case Study: PD-L1 0%, PROPHET® NEGATIVE, SCORE 1.1

PATIENT PROFILE

67-year-old male

PATIENT HISTORY

47 pack-year smoker (quit 8/2022). Malignant pericardial effusion; 13 cm lung mass with NSCLC. No brain metastases.

TESTING RESULTS

PD-L1 TPS

0%

TMB

0.8 mut/Mb

NGS

No actionable mutations identified

DIAGNOSIS

Adenocarcinoma - **metastatic NSCLC**.

PROPHET*NSCLC*® RESULT

Patient's PROPHET® Result: NEGATIVE | Score 1.1/10

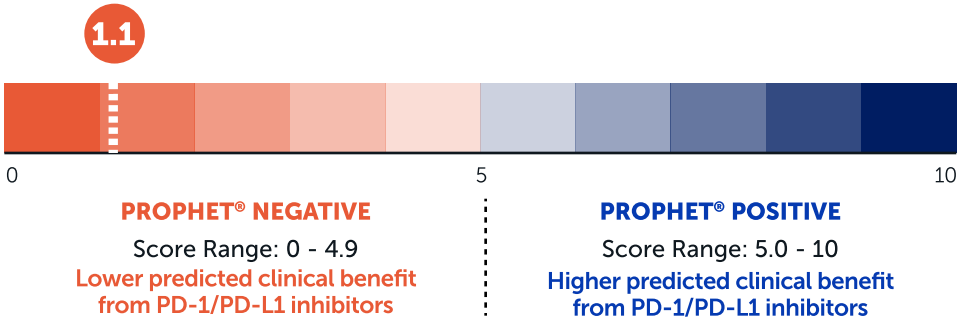

HOW PROPHET*NSCLC*® INFLUENCED THE TREATMENT DECISION

Despite a PD-L1 below 1%, the physician had initially planned to treat with an immune checkpoint inhibitor (ICI) plus chemotherapy. A PROPHET® test, however, returned a **PROPHET® NEGATIVE result, Score 1.1**, indicating a low probability of benefit from PD-1/PD-L1 inhibitor therapy. Based on this additional guidance, the physician instead chose a dual ICI regimen, ipilimumab/nivolumab plus chemotherapy, better suited to the patient's predicted response profile.

Treatment Decision

Dual ICI + chemotherapy per the CheckMate-9LA regimen (ipilimumab/nivolumab + chemotherapy).

ONCOHOST GUIDED ONCOLOGY

OncoHost Inc. | 1110 SE Cary Parkway, Suite 205 | Cary, NC 27518 | oncohost.com
Client Services: 1-855-950-2112 | Fax: 1-919-415-1308 | Email: contact@oncohost.com

PROPHET *NSCLC*™

Case courtesy of WellSpan Adams Cancer Center

Case Study: PD-L1 40%, PROPHET® NEGATIVE, SCORE 4.5

PATIENT PROFILE

85-year-old female

PATIENT HISTORY

Patient is frail with a prior lung adenocarcinoma (1/2024, treated with RT). Recurrence 4/2026 with large pleural effusion.

TESTING RESULTS

PD-L1 TPS

40%

TMB

9.4 mut/Mb

NGS

No actionable mutations identified

DIAGNOSIS

Recurrent **metastatic NSCLC** (adenocarcinoma).

PROPHET*NSCLC*® RESULT

Patient's PROPHET® Result: NEGATIVE | Score 4.5/10

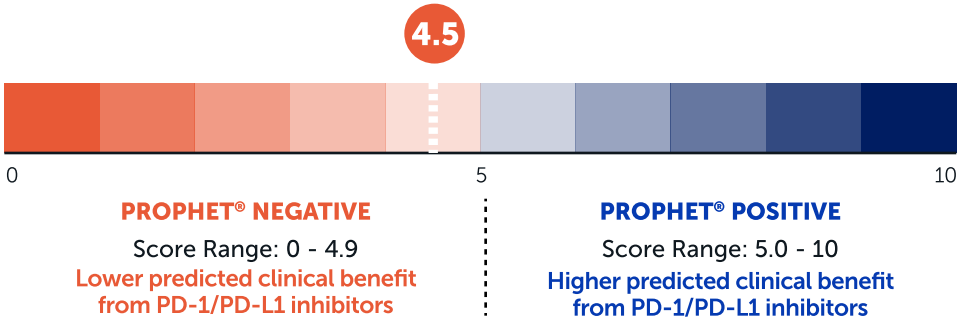

HOW PROPHET*NSCLC*® INFLUENCED THE TREATMENT DECISION

Given the patient's history and frailty, the physician wanted to avoid chemotherapy. With PD-L1 40%, the physician was debating between ICI monotherapy and dual ICI (ipilimumab/nivolumab). A **PROPHET® NEGATIVE result, score 4.5,** indicating a lower probability of clinical benefit from PD-1/PD-L1 inhibitor therapy, which ultimately guided the decision of dual ICI (ipilimumab/nivolumab).

Treatment Decision

Dual ICI (ipilimumab/nivolumab) initiated, with pembrolizumab monotherapy as backup if irAEs.

ONCOHOST GUIDED ONCOLOGY

OncoHost Inc. | 1110 SE Cary Parkway, Suite 205 | Cary, NC 27518 | oncohost.com
Client Services: 1-855-950-2112 | Fax: 1-919-415-1308 | Email: contact@oncohost.com

PROPHET *NSCLC*™

Case courtesy of Miami Cancer Institute

Case Study: PD-L1 50%, PROPHET® POSITIVE, SCORE 6.8

PATIENT PROFILE

70-year-old female

Never smoker, LUL lingular primary with adrenal and CNS metastases.

STAGING & IMAGING

- **PET-CT:** metastases identified in the left adrenal gland, mediastinal lymph nodes, and brain
- **Primary tumor:** 4.2 × 2.4 cm left upper lobe lingular mass extending to the pericardial surface
- **Nodal disease:** pretracheal, right paratracheal, prevascular, and precarinal/ subcarinal lymphadenopathy (up to 1.1 × 0.9 cm) extending to the central right hilum
- **Adrenal metastasis:** 4.5 × 3.1 cm left adrenal gland mass
- **CNS involvement:** 4 × 1.5 cm left parieto-occipital metastasis with a new left cerebellar metastasis; SRS administered to CNS lesions

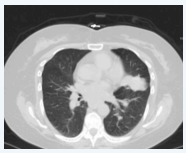

Baseline



Follow-up - partial response

TESTING RESULTS

PD-L1 TPS

50%

TMB

2.4 mut/Mb

NGS

No actionable mutations identified

DIAGNOSIS

Bone biopsy: **poorly differentiated adenocarcinoma**, consistent with a lung primary.

PROPHET*NSCLC*® RESULT

Patient's PROPHET® Result: POSITIVE | Score 6.8/10

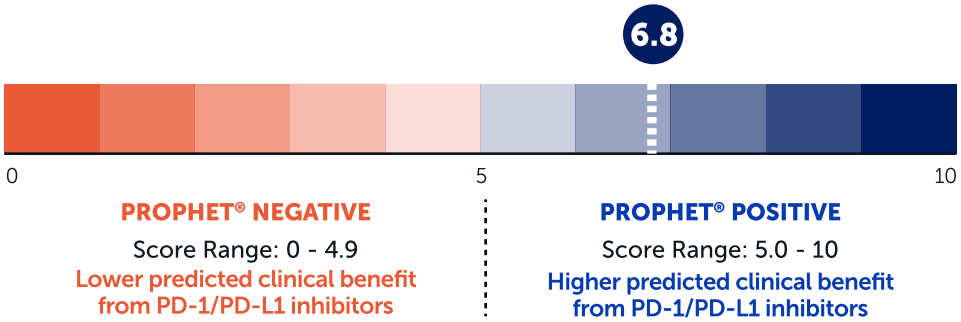

HOW PROPHET*NSCLC*® INFLUENCED THE TREATMENT DECISION

With PD-L1 expression of 50%, never-smoker status, low tumor mutational burden (2.4 mut/Mb), and multifocal disease with CNS involvement, pembrolizumab plus chemotherapy was initially favored for rapid disease control. A **PROPHET® POSITIVE score of 6.8**, indicating a high probability of clinical benefit from PD-1/PD-L1 therapy, gave the provider confidence to change their initial decision and use pembrolizumab monotherapy instead.

Treatment Decision

Pembrolizumab monotherapy selected; patient continues to do well on therapy.

ONCOHOST GUIDED ONCOLOGY

OncoHost Inc. | 1110 SE Cary Parkway, Suite 205 | Cary, NC 27518 | oncohost.com
Client Services: 1-855-950-2112 | Fax: 1-919-415-1308 | Email: contact@oncohost.com

PROPHET *NSCLC*™

Case courtesy of MD Anderson

Case Study: PD-L1 90%, PROPHET® NEGATIVE, SCORE 0.3

PATIENT PROFILE

48-year-old male

PATIENT HISTORY

Presented with recurrent obstructive pneumonia, prompting oncologic work-up. Biopsy revealed metastatic NSCLC squamous cell carcinoma.

TESTING RESULTS

PD-L1 TPS

90%

TMB

61.02 mut/Mb

NGS

No actionable mutations identified

DIAGNOSIS

Metastatic squamous cell carcinoma.

PROPHET*NSCLC*® RESULT

Patient's PROPHET® Result: NEGATIVE | Score 0.3/10

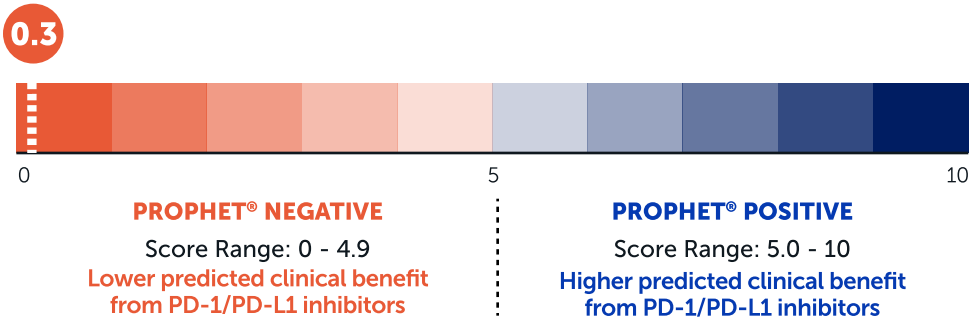

HOW PROPHET*NSCLC*® INFLUENCED THE TREATMENT DECISION

Given elevated PD-L1, TMB, and MSI-high, the physician decided to start with IO monotherapy. The **PROPHET® NEGATIVE, score 0.3** indicated a low probability of clinical benefit to PD-1/PD-L1 inhibitors. The patient progressed rapidly and chemotherapy was quickly added. The PROPHET result is independent of PD-L1 and TMB, highlighting a need to incorporate results in PD-L1 treatment.

Treatment Decision

Carboplatin/paclitaxel added after early progression on pembrolizumab monotherapy.

For field discussion with HCPs. PROPHET® is intended to be used alongside, not in place of, standard clinical assessment. Individual case results may vary.

ONCOHOST GUIDED ONCOLOGY

OncoHost Inc. | 1110 SE Cary Parkway, Suite 205 | Cary, NC 27518 | oncohost.com
Client Services: 1-855-950-2112 | Fax: 1-919-415-1308 | Email: contact@oncohost.com

PROPHET *NSCLC*™

Case courtesy of MCC

Case Study: PD-L1 95%, PROPHET® POSITIVE, SCORE 9.6

PATIENT PROFILE

77-year-old male

PET CT 07/31/26 imaging demonstrates FDG avid right lower lobe mass suspicious for primary lung malignancy. Multiple FDG avid left supraclavicular and thoracic nodal, bilateral lung and osseous metastases. Possible soft tissue metastasis in the left proximal anteromedial thigh. Decreased right pleural effusion. Brain MRI with 3 brain mets

PATIENT HISTORY

The patient presented with a very high disease burden and poor performance status.

TESTING RESULTS

PD-L1 TPS

95%

NGS

No actionable mutations identified

DIAGNOSIS

Bone biopsy: **poorly differentiated adenocarcinoma**, consistent with a lung primary.

PROPHET*NSCLC*® RESULT

Patient's PROPHET® Result: POSITIVE | Score 9.6/10

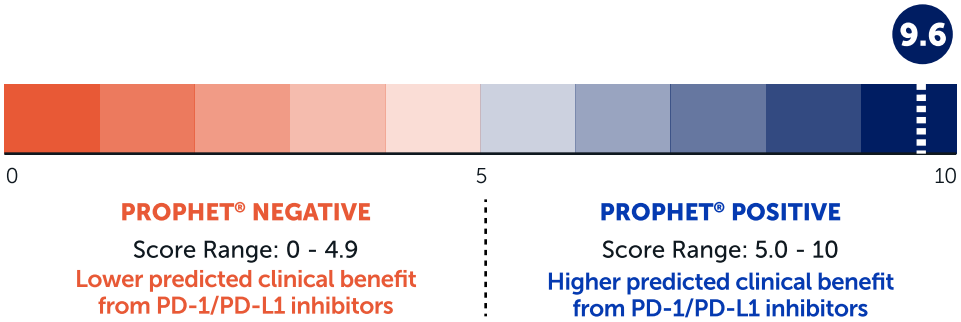

PROPHET® NEGATIVE
Score Range: 0 - 4.9
Lower predicted clinical benefit from PD-1/PD-L1 inhibitors

PROPHET® POSITIVE
Score Range: 5.0 - 10
Higher predicted clinical benefit from PD-1/PD-L1 inhibitors

HOW PROPHET*NSCLC*® INFLUENCED THE TREATMENT DECISION

The PROphet result directly informed the maintenance treatment strategy. Had PROphet returned NEGATIVE, the provider indicated that they would have continued maintenance chemotherapy + pembrolizumab. The **PROPHET® POSITIVE result, 9.6 score** provided confidence to move forward with pembrolizumab monotherapy for maintenance, avoiding additional chemotherapy exposure.

Treatment Decision

Initiated chemotherapy + immunotherapy with a plan to complete three cycles of chemotherapy, then reassess with imaging. If patient has a strong response, will transition to pembrolizumab alone for maintenance therapy.

ONCOHOST GUIDED ONCOLOGY

OncoHost Inc. | 1110 SE Cary Parkway, Suite 205 | Cary, NC 27518 | oncohost.com
Client Services: 1-855-950-2112 | Fax: 1-919-415-1308 | Email: contact@oncohost.com