

# Clinical Effectiveness of a High-Intensity Focused Ultrasound in Skin Lifting

Jiehoon Kim<sup>1</sup>  
Byoung Joon So<sup>2</sup>  
Hwa Jung Ryu<sup>2</sup>

<sup>1</sup>Dr. Kim's Skin & Laser Clinic, Dermatology,  
Suwon, Korea

<sup>2</sup>Department of Dermatology, Korea University  
College of Medicine, Seoul, Korea

## Background and Objectives

Skin laxity is a common complaint of patients who request a skin rejuvenation procedure. In this study, the clinical effectiveness of high-intensity focused ultrasound (HIFU) for the treatment of facial laxity was evaluated.

## Materials and Methods

Nineteen Korean women and one Korean man volunteers were enrolled and first treated with a 4.5-mm, 4-MHz HIFU probe, followed by a 3.0-mm, 7-MHz HIFU probe. A split-face study was performed on one patient. Two blinded, experienced clinicians evaluated pre-treatment and post-treatment (3-months after) paired photographs.

## Results

The results revealed that 16 of the 17 subjects (94%) had clinical improvement post-treatment. In a split-face study, the treated site showed excellent improvement compared to the control site. There were no specific side effects noted.

## Conclusion

In conclusion, HIFU is a useful nonablative method for skin lifting in Asian patients.

## Key words

High-intensity focused ultrasound (HIFU); Skin lifting

Received December 2, 2014  
Revised December 8, 2014  
Accepted December 10, 2014

## Correspondence

Hwa Jung Ryu  
Department of Dermatology, Korea University  
College of Medicine, Incheon-ro 73(Anam-dong  
5ga), Seongbuk-gu, Seoul 136-705, Korea  
Tel: +82-2-920-5470  
Fax: +82-2-928-7540  
E-mail: dermhj@naver.com

© Korean Society for Laser Medicine and Surgery

© This is an open access article distributed under the terms of the Creative Commons Attribution Non-Commercial License (<http://creativecommons.org/licenses/by-nc/3.0>) which permits unrestricted non-commercial use, distribution, and reproduction in any medium, provided the original work is properly cited.

## INTRODUCTION

Skin laxity is a common problem faced by older people, for which they request skin rejuvenation procedures. Until recently, several traditional procedures such as laser ablation, dermabrasion, and chemical peels were the most common treatment options for skin laxity. However, they have various adverse side effects including pigment change, scarring, and infection.<sup>1</sup>

High-intensity focused ultrasound (HIFU) has been used for the treatment of benign and malignant tumors for several years.<sup>2</sup> Recently, new machines have been developed which use HIFU technology for skin lifting. HIFU induces vibration at the molecular level, which generates thermal energy and eventually forms a thermal coagulation zone in the superficial muscular aponeurotic system (SMAS).<sup>3</sup> It is different from other procedures in that the thermal lesion is found in the deep dermal tissue.<sup>3,4</sup>

Non-invasive skin lifting procedures have become more popular in aesthetic medicine. The present study focused on the clinical efficacy and side effects of HIFU for skin tightening and lifting.

## MATERIALS AND METHODS

Nineteen Korean women and one Korean man with wrinkles and skin laxity were enrolled in this study. They were from 28 to 60 years-of-age (mean  $42.5 \pm 7.5$  years). Diagnoses were made on clinical findings. After explaining the purpose and protocol of the study to all the patients, they gave written informed consent to participate in the study, as well as allowed for the use of their photographs

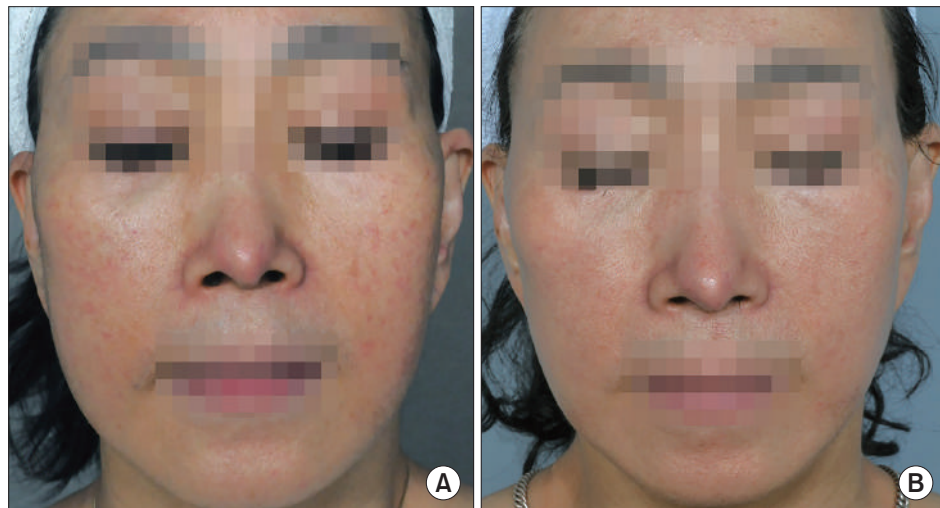
for clinical purposes.

Topical anesthesia cream was applied before starting treatment, and a cooling pack was applied after the treatment session. Patients were treated with HIFU (Doublo™, Hironic, Sungnam, South Korea) using a D4 cartridge (4 MHz, 4.5 mm probe) at  $1.2 \text{ J/cm}^2$ , 200-300 shots and then, additionally treated using a M7 cartridge (7 MHz, 3.0 mm probe)  $0.45 \text{ J/cm}^2$ , 100-150 shots. Multiple passes were made while avoiding stacking of the pulses, with the desired endpoint being mild erythema of the whole face. Feel the orbital rim by touch and operate to the extent that the M7 cartridge does not exceed the orbital rim. The operation should proceed in a fan-shape with eyeball as the center, and the number of operation shot should be between 20 and 40 lines. A split-face study was conducted in one patient (Fig. 3); the left side of this patient's face was treated.

Results for each patient were assessed during a 3-month post-treatment follow-up examination. Digital photographic documentation was obtained under the same conditions (light source, room, and camera) for both pre-and post-treatment assessments. Improvement in skin tightening was assessed with a 5-point scale as follows: 1, little or no improvement (0-10%); 2, noticeable improvement (10-25%); 3, fair improvement (25-50%); 4, good improvement (50-75%); and 5, excellent improvement (>75%). Two independent and experienced dermatologists assessed the skin of patients.

## RESULTS

Among the 20 patients, 17 patients completed the study successfully. Three individuals were lost to follow-up.



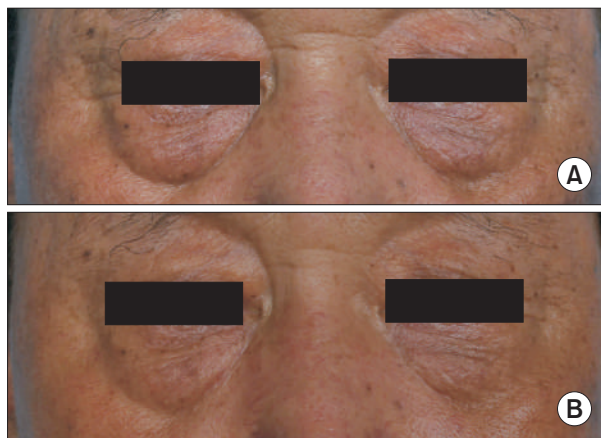
**Fig. 1.** A 54-year-old woman shows excellent post-treatment improvement (B) compared to pre-treatment (A).

Sixteen of the 17 subjects showed clinical improvement 3 months post-treatment. Their average 5-point scale score was 3.6 (mean  $3.6 \pm 1.1$ ). Two patients (12%) were assessed as having noticeable improvement, 3 patients (18%) as having fair improvement, 7 patients (41%) as having good improvement, and 4 patients (24%) as having excellent improvement at the 3-month follow-up visit. One subject (6%) was reported to show little or no improvement. One subject representing excellent improvement in skin laxity is shown in Fig. 1, and outstanding result in periorbital area in Fig. 2. In a split-face study, the treated site showed excellent improvement compared to the control site (Fig. 3).

All subjects reported a painful sensation, and 3 had transient side effects such as erythema and edema. Patients were able to return to their usual activities immediately after the procedure.

## DISCUSSION

Techniques for facial skin rejuvenation have been

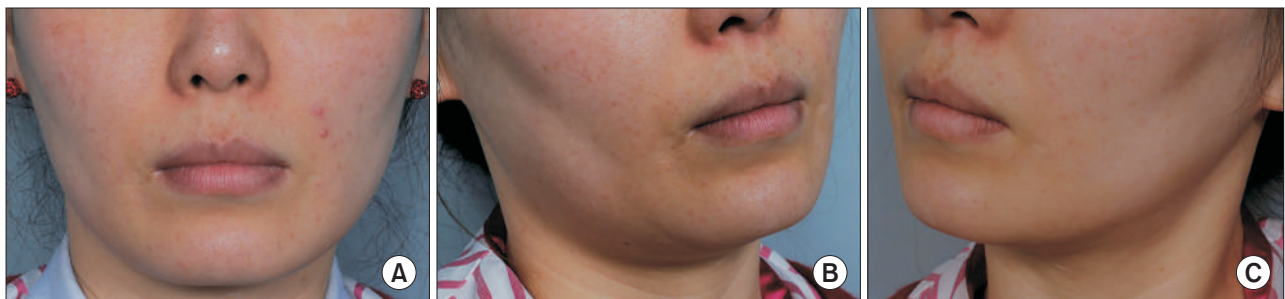

**Fig. 2.** A 60-year-old man shows excellent post-treatment improvement (B) compared to pre-treatment (A).

developed over time. Primarily, these tools focused on the superficial layer of the skin. One of the most popular treatments are ablative and nonablative fractional lasers. It achieves skin rejuvenation by the removal, contraction and remodeling of the epidermis and dermis.<sup>5</sup> Although it is effective in treating skin rejuvenation, patients often experience prolonged erythema, infection, and pigmentary changes.<sup>3</sup> To remedy these shortcomings, other nonablative skin rejuvenation procedures, such as intense pulsed light, radiofrequency and high-intensity focused ultrasound, have been developed. These nonablative skin lifting procedures have shown fewer adverse effects, but are not as effective as ablative skin rejuvenation.<sup>5</sup>

HIFU is a noninvasive, nonablative rejuvenation technique that uses the concept of ultrasound waves, which penetrate the epidermis and induce vibration of cellular molecules, leading to thermal injury and SMAS.<sup>2,4,6</sup> This procedure effectively thickens and shortens the collagen fibers, increases tissue tension because of the elastic properties of collagen, and tightens the skin.<sup>2,4</sup> As a result, HIFU treatment provides minimal undesirable epidermal injury<sup>7</sup> irrespective of the Fitzpatrick skin type.<sup>8</sup> Therefore, HIFU may be helpful in overcoming some of the difficulties encountered with the light-based treatment of darker skin types.

In the present study, two treatment passes were performed using two different probes. The first pass made a thermal coagulation zone that extended from the superficial adipose layer through the SMAS. The second pass created a wider vertical zone of thermal injury while still sparing the epidermis and papillary dermis, which results in effective skin tightening. Our study revealed that 94% of the research subjects described clinical improvement in skin lifting after the procedure. In a previous clinical study performed by Lee et al.,<sup>2</sup> 80% of the subjects were found to describe clinical enhancement with HIFU treatment. Also, HIFU treatment on periorbital



**Fig. 3.** A 38-year-old woman shows excellent post-treatment improvement (C) compared to the control site (B), initial photo before HIFU treatment is shown in (A).

area is widely known as dangerous procedure, but this study shows effectiveness without any side effects.

In conclusion, HIFU is a nonablative useful treatment for skin lifting in Asian patients including periorbital area. It can be a noninvasive method affecting the underlying skin structure with controlled thermal damage in dermatology. Further studies are needed to develop better procedures for skin lifting using HIFU.

## REFERENCES

1. Hassan KM, Benedetto AV. Facial skin rejuvenation: ablative laser resurfacing, chemical peels, or photodynamic therapy? Facts and controversies. *Clin Dermatol* 2013;31:737-40.
2. Lee HS, Jang WS, Cha YJ, Choi YH, Tak Y, Hwang E, et al. Multiple pass ultrasound tightening of skin laxity of the lower face and neck. *Dermatol Surg* 2012;38:20-7.
3. Suh DH, Shin MK, Lee SJ, Rho JH, Lee MH, Kim NI, et al. Intense focused ultrasound tightening in Asian skin: clinical and pathologic results. *Dermatol Surg* 2011;37:1595-602.
4. White WM, Makin IR, Barthe PG, Slayton MH, Gliklich RE. Selective creation of thermal injury zones in the superficial musculoaponeurotic system using intense ultrasound therapy: a new target for noninvasive facial rejuvenation. *Arch Facial Plast Surg* 2007;9:22-9.
5. Atiyeh BS, Dibo SA. Nonsurgical nonablative treatment of aging skin: radiofrequency technologies between aggressive marketing and evidence-based efficacy. *Aesthetic Plast Surg* 2009;33:283-94.
6. MacGregor JL, Tanzi EL. Microfocused ultrasound for skin tightening. *Semin Cutan Med Surg* 2013;32:18-25.
7. Minkis K, Alam M. Ultrasound skin tightening. *Dermatol Clin* 2014;32:71-7.
8. Laubach HJ, Makin IR, Barthe PG, Slayton MH, Manstein D. Intense focused ultrasound: evaluation of a new treatment modality for precise microcoagulation within the skin. *Dermatol Surg* 2008;34:727-34.