

## INFORMATION SHEETS

### SUMMARY

<b>VENOUS MALFORMATIONS.....</b>	<b>2</b>
What is a venous malformation? .....	2
What causes venous malformations? Is it hereditary? .....	2
Is it serious? What are the risks/complications? .....	2
Blood test with D-dimer and fibrinogen measurement.....	2
What treatments are available? .....	3
<b>SUPERFICIAL ARTERIOVENOUS MALFORMATIONS.....</b>	<b>4</b>
What is an arteriovenous malformation (AVM)? .....	4
What causes AVMs? Is it hereditary? .....	4
When do AVMs appear? .....	4
Is it serious? What are the possible complications of a superficial AVM? .....	4
<b>LYMPHATIC MALFORMATIONS OR CYSTIC LYMPHANGIOMAS .....</b>	<b>5</b>
What is a lymphatic malformation (LM)? .....	5
What causes lymphatic malformations? Is it hereditary? .....	5
Is it serious? What are the risks/complications? .....	5
What can be done to limit the complications associated with the presence of a lymphatic malformation? .....	5
How can lymphatic malformations be treated? .....	6
<b>CAPILLARY MALFORMATIONS .....</b>	<b>7</b>
What is a capillary malformation = CM? .....	7
What causes capillary malformations? .....	7
How are capillary malformations diagnosed? Where are they located? .....	7
When should I consult a specialist? .....	7
What developments are possible? .....	7
How can capillary malformations be treated? .....	7
<b>INFANTILE HEAMANGIOMA .....</b>	<b>9</b>
What is an infantile haemangioma? How does it develop? .....	9
What causes haemangiomas? .....	9
How is a haemangioma diagnosed? Where are they located? .....	9
When should a specialist in infantile haemangiomas be consulted? .....	10
How are haemangiomas treated? .....	10
<b>SCLEROSIS OF A VASCULAR MALFORMATION .....</b>	<b>11</b>
What is sclerosis? .....	11
What is the purpose of this? .....	11
How does the operation work? .....	11
What preparation is needed for this type of operation? .....	11
What products are used for sclerosis? .....	12
What happens after sclerosis? .....	12
What are the risks of sclerosis? .....	12
What precautions should be taken after the operation? .....	13
What happens if sclerosis fails? .....	13

## VENOUS MALFORMATIONS

### What is a venous malformation?

This is a vascular anomaly consisting of dysplastic veins, most often localised in a specific location. At this location, the veins have lost their "tube" shape, which allows the normal flow of blood, and form « venous pouches/ lakes » in which the blood stagnates. These pockets will gradually grow with the patient over time, but the location will remain the same. When these pouches/ lakes are located all over the body attending the skin or oropharyngeal mucosae they then take on a bluish colour.

### What causes venous malformations? Is it hereditary?

Venous malformations are congenital, meaning that they are present at birth, although they become symptomatic and visible at different ages.

In the vast majority of cases, these malformations are not hereditary, i.e. the malformation affects only one individual in a family and that individual will not pass the malformation on to his or her children. Recently, somatic mutations have been identified, particularly in the TEK/Tie2 and Plk3 CA genes.

### Is it serious? What are the risks/complications?

In the vast majority of cases, venous malformations are bothersome and sometimes invisible, these are benign lesions, in other words without vital risk. Some can be painful. Certain exceptional forms escape this rule. A coagulation disorder is frequently found in venous malformations, responsible for intra-lesional thrombosis and very rarely for bleeding. This is also the case with venous malformations of the digestive tract, which may be complicated by digestive haemorrhage.

The most frequent symptoms are swelling of the malformation and painful episodes. Venous pouches can become painful because of their size, but also because of thrombosis (formation of clots in the malformation). All everyday situations that increase the pressure inside the veins will lead to a temporary increase in the volume of the pouches and can trigger pain: this is the case with all pushing « Valsalva manoeuvres », prolonged standing, carrying heavy loads, sport activities, but also changes in the weather or the hormonal cycle.

### Blood test with D-dimer and fibrinogen measurement

Venous malformations may be associated with localised intravascular coagulopathy (LICV), reflecting thrombosis within the venous pouches/lakes. This thrombosis may be the cause of painful episodes.

This is reflected in the blood test by an increase in D-dimer levels (> 500 ng/ml). This value is usually normal in patients with no malformation (except in cases of pulmonary embolism, phlebitis, etc.). However, in patients with venous malformations, it is usual to find slightly elevated D-dimer levels without this being worrying or dangerous. We only consider a rise in D-Dimer levels (> 1,500 ng/ml) associated with pain needs to be taken care of.

- In the event of severe pain, anticoagulant treatment with Low Molecular Weight Heparin (LMWH) may be started, for example a 7-10 day course of Lovenox 0.4 mL/day. This can be followed by a course of either Aspirin (2 mg/kg: day) or Kardégic 75 mg /160 mg (depending on the patient's weight) per day for 2-3 months.

In the event of a scheduled invasive procedure within the VM or in another location (surgery, removal of wisdom teeth, childbirth, etc.), we recommend that patients presenting an elevated LICV D-Dimer levels (> 1,500 ng/ml) undergo a treatment with LMWH 10 days prior

and after the procedure. This will avoid the transition to a disseminated intravascular coagulation (DIC).

- ▶ In the event of an emergency procedure and if D-dimer levels are  $> 1,500$  ng/mL, anticoagulant treatment with Heparin IVSE may be initiated 6 hours beforehand.

### What treatments are available?

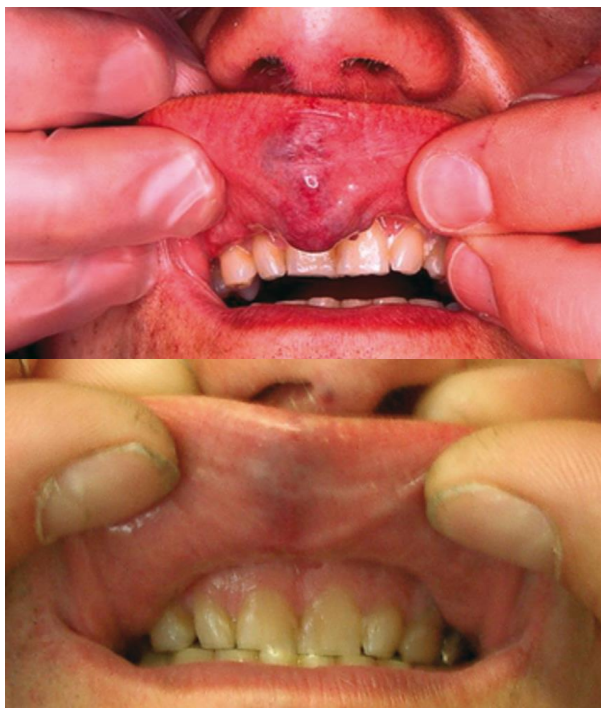Venous malformations are rare diseases. Treatment depends on symptoms and location, and may vary from one team to another.

In our centre, venous malformations are initially treated by medical therapy combining:

- Wearing compression support whenever possible, to facilitate venous drainage and reduce swelling of the pouches . This is usually a class /type II compression garment, which should be worn as often as possible and renewed regularly. Sometimes they need to be tailor customized
- Raising the limb / bed, particularly at night.
- Taking low-dose Aspirin (2 mg/kg/day, i.e. Kardégic 75mg or 160mg) every day for courses of 1 to 3 months. This treatment thins the blood and prevents thrombosis.
- Massage of the venous malformation during painful episodes using Helichrysum oil / Apply icing

If this treatment is not sufficient, we can offer treatment either by **sclerotherapy** (see sheet below), endovenous laser therapy, surgery or a combination of these techniques.

These techniques are not always offered, and when the venous malformation is not very bothersome or too difficult to access, we are content with simple monitoring.



Photographs of a venous malformation of the labial mucosa treated by a laser session.

# SUPERFICIAL ARTERIOVENOUS MALFORMATIONS

## What is an arteriovenous malformation (AVM)?

Arteriovenous malformations are vascular malformations known as "fast flow" malformations.

Normally, arteries and veins are connected by a network of small vessels known as a capillary bed. However, in the case of AVMs, the arteries and veins are connected to each other at multiple points without the aid of this capillary bed, creating what are known as **shunts**. The arteries and veins involved are enlarged and the flow is abnormally high in the veins.

In a child, an AVM looks like a slightly pulsating red spot. It is often confused with an infantile haemangioma (a very common benign childhood tumour) or a "false planar angioma", commonly known as a wine stain. AVMs become clinically more visible as their vascular flow increases. The skin then becomes redder and small flutters can be felt.

## What causes AVMs? Is it hereditary?

AVMs are congenital vascular anomalies, which means that they are present from birth, but will be more or less visible.

In the vast majority of cases, these malformations are not hereditary, i.e. the malformation affects only one individual in a family and that individual will not pass the malformation on to his or her children. They may be linked to sporadic non-hereditary somatic mutations (*Map2k1*, *Kras*, *Braf*, etc.). In rare cases, however, they may be hereditary and linked to a genetic mutation that can be passed on to offspring (*Rasa 1* and *EPHB4* mutations);

No food, medication or activity taken during pregnancy is responsible for the development of an arteriovenous malformation.

## When do AVMs appear?

AVMs are the result of a defect in the formation of arteries, veins and capillaries during embryogenesis, at the beginning of embryonic life (1st trimester of pregnancy). At birth, they may not be visible, even though they are clearly present.

They may appear much later in childhood, adolescence or adulthood. Certain factors can cause them to develop, in particular hormonal factors in women (puberty, the birth control pill, especially highly dosed in oestrogen, pregnancy) and traumatism.

## Is it serious? What are the possible complications of a superficial AVM?

Arteriovenous malformations evolve unpredictably over time, and may increase in size or become more symptomatic after a hormonal change or trauma.

The following symptoms and complications are possible:

- Pain
- Change in skin colour with increase in volume of the malformation
- Ulcerations
- Bleeding
- Exceptionally, a risk of cardiac insufficiency due to increased blood flow in the AVM.

# LYMPHATIC MALFORMATIONS OR CYSTIC LYMPHANGIOMAS

## What is a lymphatic malformation (LM)?

Lymphatic malformations are spaces that are also called fluid pouches because they contain lymphatic fluid, most of which is lemon-yellow in colour.

MLs probably appear during the formation of the lymphatic network, which is a system made up of vessels pouches and tubes. It is satellite to the veins and is distributed throughout the body, with the exception of the brain.

These may be large pouches (macrocysts) or multiple small pouches (microcysts or tissue) or a mixed form (macro and microcysts).

ML is very often superficial, located directly under the skin. The skin may be dotted with small vesicles which may blacken as a result of bleeding.

Some ML may also be located deeper down, in the muscles for example, or even bones and may be found in all parts of the body. Sometimes there are episodes of swelling or enlargement of the parts of the body where it is located: the neck, cheek, lips, tongue, etc.

They may also be associated with combined syndromes or venous malformations (veno-lymphatic malformations).

## What causes lymphatic malformations? Is it hereditary?

The development of lymphatic malformations is often sporadic (without cause), but sometimes somatic mutations are found, particularly in the PIK3CA gene. These are congenital malformations, developing in the embryo, approximately between the 7th and 8th week of pregnancy (1st trimester).

Under no circumstance are the parents responsible. No food, medication or activity taken during pregnancy is responsible for the appearance of a lymphatic malformation.

## Is it serious? What are the risks/complications?

In the vast majority of cases, lymphatic malformations are embarrassing and sometimes unsightly, but benign, in other words without any vital risk. Symptoms are linked to inflammatory flare-ups complicating :

- Bleeding inside the lymphatic pouch
- Infection of the lymphatic pouches with an increase in the size of the lesion, secondary to a locoregional infection (for example: angina, dental infection, all infections that develop in the region of the lymphatic pouches)
- Acute infections (very often manifested by a discharge of liquid from the surface of the skin)

## What can be done to limit the complications associated with the presence of a lymphatic malformation?

Lymphatic malformations can increase during infectious episodes.

The aim is therefore to limit these infectious episodes:

For ear infections in the head and neck region, good oral and dental hygiene is essential. It is important to monitor children's health and treat them for ear infections as soon as the first symptoms appear.



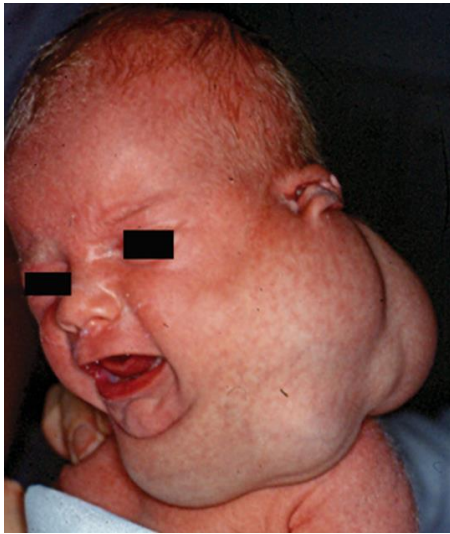In the event of an inflammatory outbreak of lymphatic malformation, treatment with antibiotics combined with short-term corticosteroid therapy for 7-10 days is prescribed. A search is made for the infection entry point in order to treat the cause of the flare-up.

### How can lymphatic malformations be treated?

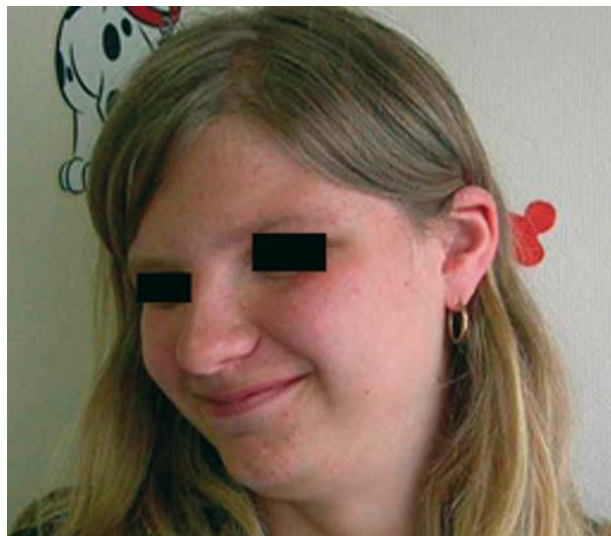Different treatments are available depending on the location, size and appearance of the pouches: **sclerotherapy**, is a procedure to reduce the size of the pouches ; or surgery if sclerotherapy is difficult to carry out or has not been effective. Endovenous laser treatment can be efficient on the vesicles. Some patients benefit from medical treatment such as Rapamycine.

If there are few or no symptoms, treatment may consist of simple monitoring.

Further information is available on the PNDS on [cystic lymphatic malformations](#).



Infant with a large cervical lymphatic malformation.



The same child after 9 sessions of sclerotherapy.

## CAPILLARY MALFORMATIONS

### What is a capillary malformation = CM?

Capillaries (the smallest vessels in the body) can dilate in the superficial part of the skin, a condition known as capillary malformation.

They are red, sometimes pink, flat and well-defined. They are also known as "wine spots" in everyday language.

Often visible from birth, the size of these vessels will gradually increase with age, which may explain why the spot takes on a darker colour. These lesions persist throughout the individual's life.

### What causes capillary malformations?

The cause of the development of this malformation is unknown, but somatic mutations in the GNAQ/GNA11 genes have recently been identified.

Capillary malformations are congenital skin lesions. They are therefore present from birth. Capillaries are formed during embryogenesis, i.e. at the start of embryonic life (1st trimester of pregnancy).

Under no circumstances are parents responsible. No food, medication or activity ingested during pregnancy is responsible for the appearance of a capillary malformation.

### How are capillary malformations diagnosed? Where are they located?

These malformations can occur anywhere on the body.

Diagnosis is generally made on clinical examination. Ultrasound with a Doppler technique is sometimes used to visualise the blood vessels.

### When should I consult a specialist?

In newborns, close monitoring is required during the first few months of life, as this angioma planus may be associated with other vascular malformations (AVM) . It is then said to be CM AVM

If the capillary malformation covers :

- A part of the forehead or upper eyelid, it is necessary to complete the assessment with an MRI or brain scan to look for any vascular malformations in the eye and brain.
- Part of a limb (arm or leg), we need to make sure that the veins and arteries are normal.

If there are no other associated signs and the evolution is stable, it is an isolated flat angioma. In this case, there is no serious factor and it is more of a cosmetic problem.

### What developments are possible?

If the capillary malformation is isolated, it can sometimes develop into a thickening of the surrounding skin and the appearance of fleshy skin buds (botriomycomas), which can be unsightly and/or cause bleeding.

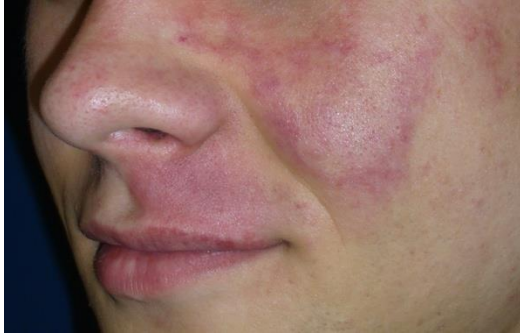### How can capillary malformations be treated?

If the capillary malformation causes significant aesthetic discomfort, pulsed dye laser treatment may be suggested. This laser produces energy that is almost totally absorbed by the haemoglobin contained in the abnormally dilated blood vessels under the skin, causing their

destruction. A cooling jet reduces the temperature of the skin a fraction of a second before each pulse to reduce the risk of burns.

This is done under local anaesthetic, and you may feel a painful sensation like a rubber band.

In certain cases, such as significant tissue hypertrophy, the appearance of pyogenic granulomas or botriomycomas, surgical intervention may be proposed.



Photograph taken after a pulsed dye laser session on the central part of the capillary malformation.



## INFANTILE HEAMANGIOMA

### What is an infantile haemangioma? How does it develop?

Infantile haemangiomas are common vascular tumours. It is the most common benign tumour in young children, affecting between 4 and 10% of newborns. They are more common in little girls.

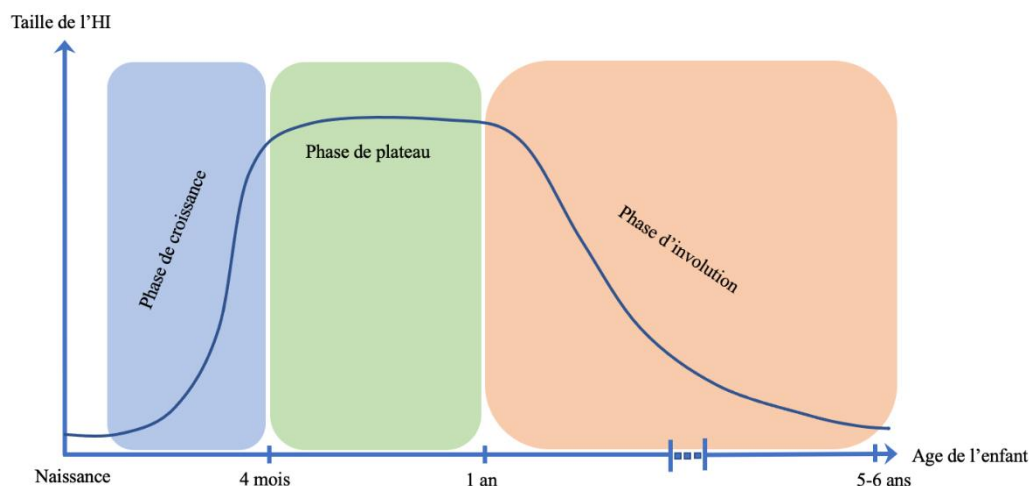
Infantile haemangiomas are linked to the proliferation of endothelial cells. This proliferation begins after birth, often in the first few days of life.

At birth, the skin is usually normal, sometimes pink or even red or anaemic (lighter in colour).

This lesion goes through three phases:

- Proliferation phase
- Stability phase
- Involution phase

Regression of the haemangioma is complete in 50% of patients by the age of 5, and in 70% of cases by the age of 7. By the age of 10-12 years, involution of the tumour is almost complete. At the end of the course, residual fatty tissue or a reddish discolouration of the skin may persist.



### What causes haemangiomas?

The cause of the development of this benign tumour is unknown.

Under no circumstances are parents responsible. No food, medication or activity taken during pregnancy is responsible for the appearance of a haemangioma.

### How is a haemangioma diagnosed? Where are they located?

Around 60% of haemangiomas are located in the head and neck region. Around 25% are found on the trunk and 15% on the arms or legs.

Haemangiomas can be single (80% of cases) or multiple (20%). They may be on the surface of the skin or just under the skin.

In most cases (90% of cases), the diagnosis of infantile haemangioma can be made on the basis of the child's history, clinical examination and early photographs.

A further examination (ultrasound or MRI) is sometimes necessary for diagnosis or to explore the depth of the tumour.

### **When should a specialist in infantile haemangiomas be consulted?**

As it is the most common benign tumour, in the majority of cases haemangiomas do not require any follow-up. However, it is necessary to consult a specialist if the haemangioma :

- is located on or around certain parts of the body: the eye, nose, mouth, ear, buttocks, chest, face and neck
- is making very rapid progress
- leads to skin ulcerations, minimal bleeding or skin superinfections
- is of multiple location

### **How are haemangiomas treated?**

Most haemangiomas do not require medical treatment or follow-up. Unsightly sequelae may sometimes require correction by surgery or pulsed dye laser.

However, if there is a risk of permanent unsightly sequelae, particularly in the periorificial areas of the face, hyperalgesic ulceration or functional repercussions, medical treatment with Propranolol may be introduced in the first few months of life.

## **SCLEROSIS OF A VASCULAR MALFORMATION**

These scleroses are essentially used for vascular malformations with slow flow: venous or lymphatic.

### **What is sclerosis?**

This procedure involves injecting a sclerosing agent directly into the venous malformation / pouch to "burn" its inner lining and induce resorption of the cavity following an inflammatory reaction and thrombosis, leading to gradual retraction. It is performed under fluoroscopy and ultrasound mostly

### **What is the purpose of this?**

The aim of sclerosis is to limit painful symptoms and reduce lesion volume. However, it is very rare for the malformation to disappear completely. The aim of treatment is patient clinical improvement, not 100% disappearance of the Imaging.

### **How does the operation work?**

This is a technically simple procedure that involves puncturing the malformation/ Pouch through the skin using a small-gauge needle.

The vascular cavities are opacified with a contrast medium to ensure that the needle is in the correct position. The appearance of the fluid and the relationship of the malformation to the surrounding normal vessels are analysed.

Some products, such as alcohol, are very painful to inject and require a general anaesthetic. In other cases, a local anaesthetic may suffice.

### **What preparation is needed for this type of operation?**

Given the need for a general anaesthetic, it is essential to have an anaesthetic consultation within 2 months of the intervention (no less than 48 hours before the intervention). A blood sample will be taken for a coagulation study and a pre-operative check-up. It is performed under fluoroscopy and ultrasound mostly

In most cases, you will be admitted to hospital the evening before or to a day hospital. You must not eat, drink or smoke after midnight. The morning of the procedure :

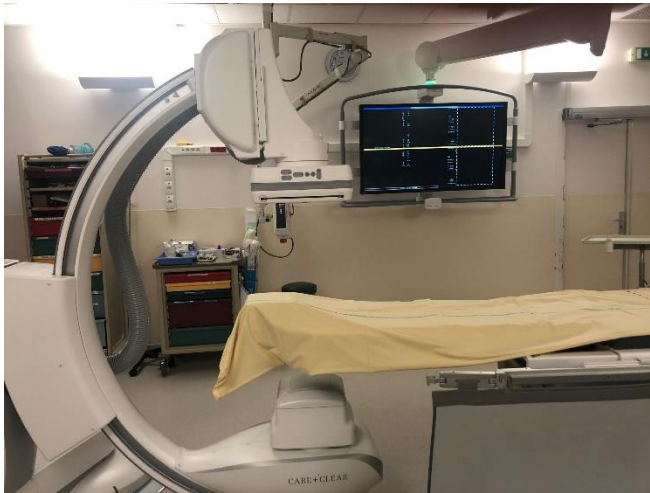You will take an aseptic shower,

You will be taken to the operating theatre half an hour before your procedure, depending on the operating schedule,

A drip is usually inserted in the operating theatre,

Here, the anaesthetic team and radiology technicians will work with you and the interventional radiologist.

In the case of treatment and general anaesthesia for children, parental authorisation signed by both parents is required.



*Photograph of the operating room: the patient lies on the table and the C-arm is positioned close to the area to be sclerosed so that the product can be seen in real time.*

### **What products are used for sclerosis?**

There are several, each with its own advantages and disadvantages. The most commonly used products are Ethanol (pure alcohol) and Aetoxiscélér foam, Bléomycine but other products can also be used.

The sclerosis doctor will choose the most suitable product for you.

### **What happens after sclerosis?**

You will be taken to the recovery room for close monitoring by the anaesthetic team for 2-3 hours, before being taken back up to the inpatient area.

The patient is usually hospitalised for 24 to 48 hours after the sclerosis procedure, to ensure that the pain is controlled by the painkiller treatment. In fact, the after-effects are often marked by an increase in symptoms, with an increase in malformations volume, which appears much firmer and discreetly inflammatory, with small areas of reddish or bluish colouration and a slightly "sleepy" sensation in certain areas of the skin or muscles, which disappear after several days/weeks.

The intensity of this pain varies from case to case. Local application of ice bladders to the sclerosing site is sometimes necessary. If this is insufficient, painkillers and/or steroids may be prescribed for a few days.

This symptomatology will gradually disappear and the effectiveness in terms of volume or pain will be assessed after three months.

### **What are the risks of sclerosis?**

It is a treatment that has been shown to be effective, but it must be carried out in a specialised environment with a team used to dealing with these lesions and complications.

In the majority of cases, these are minor and transitory complications such as skin discolouration or "blisters". Occasionally, they can be more serious, such as :

- skin necrosis in the area of the malformation, if this involves the superficial part of the skin. If this necrosis occurs, local care may be required until the skin heals.
- nerve complications with loss of sensitivity in a skin area or loss of motor function; these complications are very rarely permanent.

- venous complications such as "phlebitis / Thrombosis", in the draining veins of the malformation or at a distance, which should be investigated by Doppler ultrasound if there is clinical doubt. These complications require anti-coagulant treatment.

Major complications are exceptional. They only occur in cases of venous malformation (this does not apply to lymphatic malformations). They are as follows

- remote migration of a blood clot (lung, heart or brain)
- air migration when using Aetoxisclérol "foam"
- migration of too much alcohol, which can lead to :
  - cardiac rhythm disorders, which may or may not be reversible (leading to death),
  - transient pulmonary hypertension,
  - haemolysis, with red coloured urine, but of no consequence in cases of normal renal function.

In addition, neuroradiology examinations use X-ray equipment that emits X-rays. These treatments are not indicated for pregnant women unless absolutely necessary. X-ray doses vary according to the length of the procedure, its complexity and your build. For particularly long examinations, skin lesions are likely to appear. These lesions are essentially redness similar to sunburn or temporary hair loss. In this case, we recommend that you contact the neuroradiology department, which will take the appropriate measures for your follow-up.

### **What precautions should be taken after the operation?**

It is advisable to rest for 2 to 3 days after leaving hospital. It is therefore often necessary to take time off work. Resumption of school or professional activities is essentially guided by the intensity of residual pain.

The same applies to resuming sport, obviously avoiding any direct impact during the first 15 days, as this could exacerbate the pain.

Pain-relieving and/or anti-inflammatory treatment will be systematically prescribed and adapted according to the intensity of the pain. This treatment should not usually exceed 5 to 7 days. There are no medical contraindications.

You will be seen again in consultation 2 to 3 months after the procedure, to assess its effectiveness.

### **What happens if sclerosis fails?**

If the improvement in symptoms is present but insufficient, it is quite possible to repeat the sclerosis procedure under the same conditions to obtain a satisfactory result.

In the event of repeated failure, the indication for surgical treatment should be discussed with the care team during a multidisciplinary consultation.