


☐

I'm not robot


reCAPTCHA

I am not robot!

Anatomical position quiz with answers pdf. Anatomical position quiz. Anatomical position test.

Which answer describes the "Anatomical Position"? Standing erect, facing observer, arms at side, palms facing forward Which statement is correct? The hip is superior to the shoulder Mrs. Jones is walking toward you. You are looking at her from a _____ view? Which statement is correct? The knee is lateral to the hip The skin is considered superficial. The left big toe is considered contralateral to the left ankle. The axial portion of the body includes the head, neck, thorax, and pelvis. Tissues - cells - organs - organ systems. To avoid extinction of a species, living organisms need to adapt to their environment. Direction F on the image refers to the area closer to the feet, also known as... Inferior. According to the anatomical position, which is standard for referencing body parts, an area nearer to the back (direction B) is referred to as... Posterior. Here's a breakdown of the key terms: * Anterior: The front side of the body, closer to the head. * Posterior: The back side of the body, opposite the anterior parts. * Superior: A position higher or closer to the head compared to another part of the body. * Inferior: A position lower or farther from the head compared to another part of the body. * Medial: A position closer to the midline of the body. * Distal: The opposite of proximal, describing a position farther from the point of attachment of a limb.

Name: _____

Anatomical Position

1. structure is closer to the head or higher than another structure

2. structure closer to the feet or lower than another structure

3. structure is more in front than another structure

4. structure is more behind than another structure

5. structure is close to the medial line

6. structure other away from the medial line than the other structure

7. references the limbs and the structure is closer to the median plane or he root of the limb than the structure

8. references he limbs and the structure is further away from the median plane or the root of the limb than the structure

9. plane that divides the body into unequal left and right parts and parallel to the medial line

10. plane that divides the body into equal left and right sides

11. divides the body into front and back, (anterior and posterior)

12. divides the body into upper and lower parts. (superior and inferior)

A. medial

B. posterior

C. inferior

D. anterior

E. sagittal plane

F. lateral

G. frontal plane

H. proximal

I. distal

J. transverse plane

K. medial line

L. superior

You are looking at her from a _____ view? Which statement is correct? The knee is lateral to the hip The skin is considered superficial. The left big toe is considered contralateral to the left ankle. The axial portion of the body includes the head, neck, thorax, and pelvis. Tissues - cells - organs - organ systems. To avoid extinction of a species, living organisms need to adapt to their environment. Direction F on the image refers to the area closer to the feet, also known as... Inferior. According to the anatomical position, which is standard for referencing body parts, an area nearer to the back (direction B) is referred to as... Posterior.

NAME: _____
LAST NAME FIRST

REVIEW SHEET

1

EXERCISE

The Language of Anatomy

Surface Anatomy

1. Match each of the following descriptions with a key region, and record the key letter or term in front of the description.
Key: 1. head 2. upper 3. middle 4. lower
A. anterior aspect of knee
B. distal
C. proximal to the hip
D. superior
E. distal
F. proximal to the head
G. distal
H. proximal to the head
I. proximal to the head
J. proximal to the head
K. proximal to the head
L. proximal to the head
M. proximal to the head
N. proximal to the head
O. proximal to the head
P. proximal to the head
Q. proximal to the head
R. proximal to the head
S. proximal to the head
T. proximal to the head
U. proximal to the head
V. proximal to the head
W. proximal to the head
X. proximal to the head
Y. proximal to the head
Z. proximal to the head

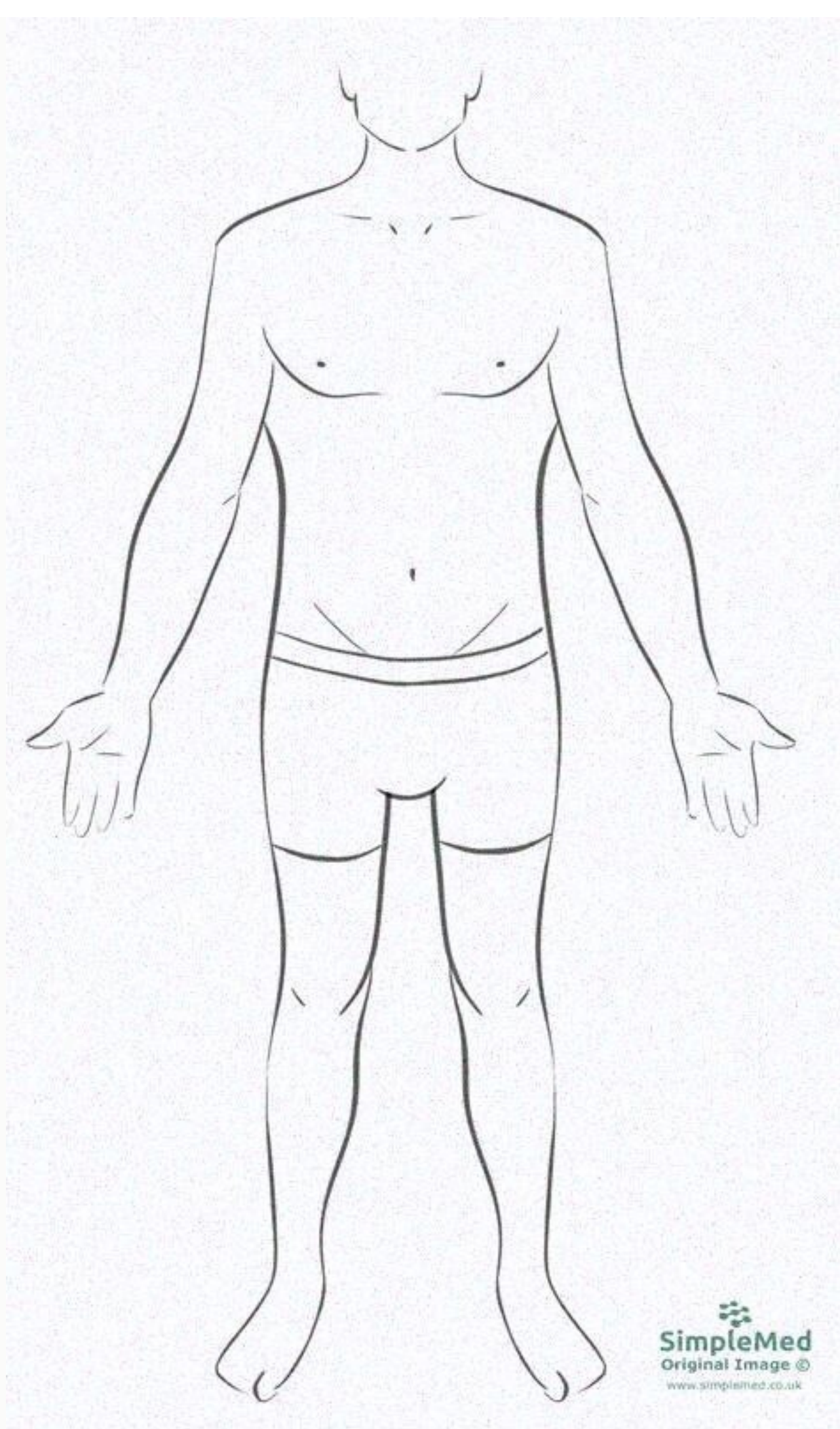
2. Indicate the following body areas on the accompanying diagram by placing the correct key letter at the end of each line.
Key:
A. head
B. neck
C. upper
D. middle
E. lower
F. anterior
G. posterior
H. proximal
I. distal
J. medial
K. lateral
L. superior
M. inferior
N. proximal to the head
O. proximal to the head
P. proximal to the head
Q. proximal to the head
R. proximal to the head
S. proximal to the head
T. proximal to the head
U. proximal to the head
V. proximal to the head
W. proximal to the head
X. proximal to the head
Y. proximal to the head
Z. proximal to the head

3. Classify each of the letters in the key of question 2 above into one of the four body regions indicated below. Insert the appropriate key letters in the empty boxes.
A. head B. neck C. upper D. middle E. lower F. anterior G. posterior H. proximal I. distal J. medial K. lateral L. superior M. inferior N. proximal to the head O. proximal to the head P. proximal to the head Q. proximal to the head R. proximal to the head S. proximal to the head T. proximal to the head U. proximal to the head V. proximal to the head W. proximal to the head X. proximal to the head Y. proximal to the head Z. proximal to the head

Body Orientation, Direction, Planes, and Sections

4. Describe completely the standard human anatomical position. Stand erect, facing forward, arms at side, palms facing forward
Distal, proximal, superior, inferior, medial, lateral

Which answer describes the "Anatomical Position"? Standing erect, facing observer, arms at side, palms facing forward Which statement is correct? The hip is superior to the shoulder Mrs. Jones is walking toward you. You are looking at her from a _____ view? Which statement is correct? The knee is lateral to the hip The skin is considered superficial. The left big toe is considered contralateral to the left ankle. The axial portion of the body includes the head, neck, thorax, and pelvis. Tissues - cells - organs - organ systems. To avoid extinction of a species, living organisms need to adapt to their environment. Direction F on the image refers to the area closer to the feet, also known as...



Which answer describes the "Anatomical Position"? Standing erect, facing observer, arms at side, palms facing forward Which statement is correct?

The hip is superior to the shoulder Mrs. Jones is walking toward you. You are looking at her from a _____ view?

Which statement is correct? The knee is lateral to the hip. The skin is considered superficial. The left big toe is considered contralateral to the left ankle. The axial portion of the body includes the head, neck, thorax, and pelvis. Tissues - cells - organs - organ systems. To avoid extinction of a species, living organisms need to adapt to their environment.

Direction F on the image refers to the area closer to the feet, also known as... Inferior. According to the anatomical position, which is standard for referencing body parts, an area nearer to the back (direction B) is referred to as... Posterior.

Name KEY LE

Anatomical terminology Quiz

Body Directions

Use the following word bank to label the diagram below.

A. anatomical position	B. caudal	C. cranial
D. diaphragm	E. distal	F. dorsal surface
G. lateral	H. medial	I. midline
J. palmar <u>surface</u>	K. plantar surface	L. proximal

The diagram shows a human figure in anatomical position. The following labels are placed on the figure:

- 1. A bracket on the right side of the head, spanning from the forehead to the back of the head.
- 2. A horizontal line across the chest, passing through the sternum.
- 3. A horizontal line across the waist, passing through the umbilicus.
- 4. An arrow pointing upwards from the feet towards the head.
- 5. An arrow pointing downwards from the head towards the feet.

1. G
2. I
3. I
4. B
5. C

Use the above word bank, match the correct term with its description.

<u>I</u> 6. center, vertical line which divides the body into symmetrical and equal right and left halves	
<u>H</u> 7. toward or at the midline of the body; on the outside of	
<u>E</u> 8. farther from the origin of a body; part of the point of attachment of a limb to the body trunk	
<u>B</u> 9. away from the head end or toward the lower part of a structure	
<u>K</u> 10. pertaining to the sole of the foot	

Which answer describes the "Anatomical Position"? Standing erect, facing observer, arms at side, palms facing forward Which statement is correct?

The hip is superior to the shoulder Mrs. Jones is walking toward you. You are looking at her from a _____ view? Which statement is correct? The knee is lateral to the hip The skin is considered superficial.

Positional & Directional Terms

Body Planes

- **Anterior** (ventral)
 - Pertaining to the front (belly side) of the body
- **Posterior** (dorsal)
 - to the back of the body
- **Deep**
 - Away from the surface
- **Superficial**
 - On the surface
- **Proximal**
 - Near the point of attachment to the trunk or near the beginning of a structure
- **Distal**
 - Far from the point of attachment to the trunk or far from the beginning of a structure
- **Inferior** (caudal)
 - Below another structure
- **Superior** (cephalic)
 - Above another structure
- **Medial**
 - Pertaining to the middle or near the medial plane of the body
- **Lateral**
 - Pertaining to the side
- **Supine**
 - Lying on the back (face up, palm up)
- **Prone**
 - Lying on the belly (face down, palm down)

Which statement is correct? The knee is lateral to the hip The skin is considered superficial. The left big toe is considered contralateral to the left ankle. The axial portion of the body includes the head, neck, thorax, and pelvis. Tissues - cells - organs - organ systems. To avoid extinction of a species, living organisms need to adapt to their environment.

Direction F on the image refers to the area closer to the feet, also known as... Inferior.

According to the anatomical position, which is standard for referencing body parts, an area nearer to the back (direction B) is referred to as... Posterior. Here's a breakdown of the key terms: * Anterior: The front side of the body, closer to the head. * Posterior: The back side of the body, opposite the anterior parts. * Superior: A position higher or

closer to the head compared to another part of the body. * Inferior: A position lower or farther from the head compared to another part of the body. * Medial: A position closer to the midline of the body. * Distal: The opposite of proximal, describing a position farther from the point of attachment of a limb. These terms help describe the relationships

From different parts of the body and are essential for understanding human anatomy. The outermost layer of the skin is called epidermis, serving as a primary barrier against external threats.

Again, the correct answer is B. When referring to a position closer to the body's surface, we say it's "superficial". This term often describes injuries or conditions affecting the outer layers of the skin, like superficial burns that only affect the epidermis.