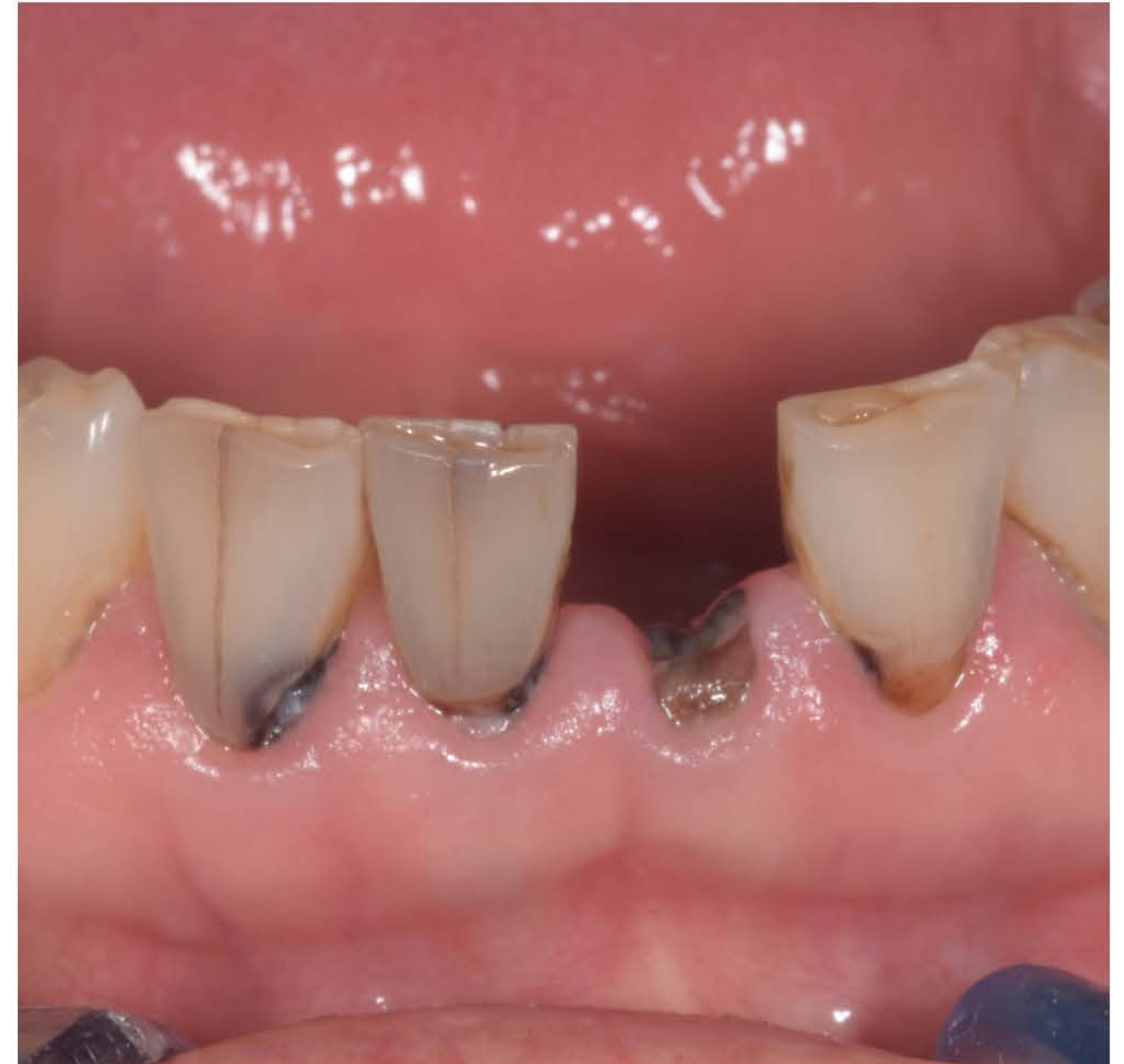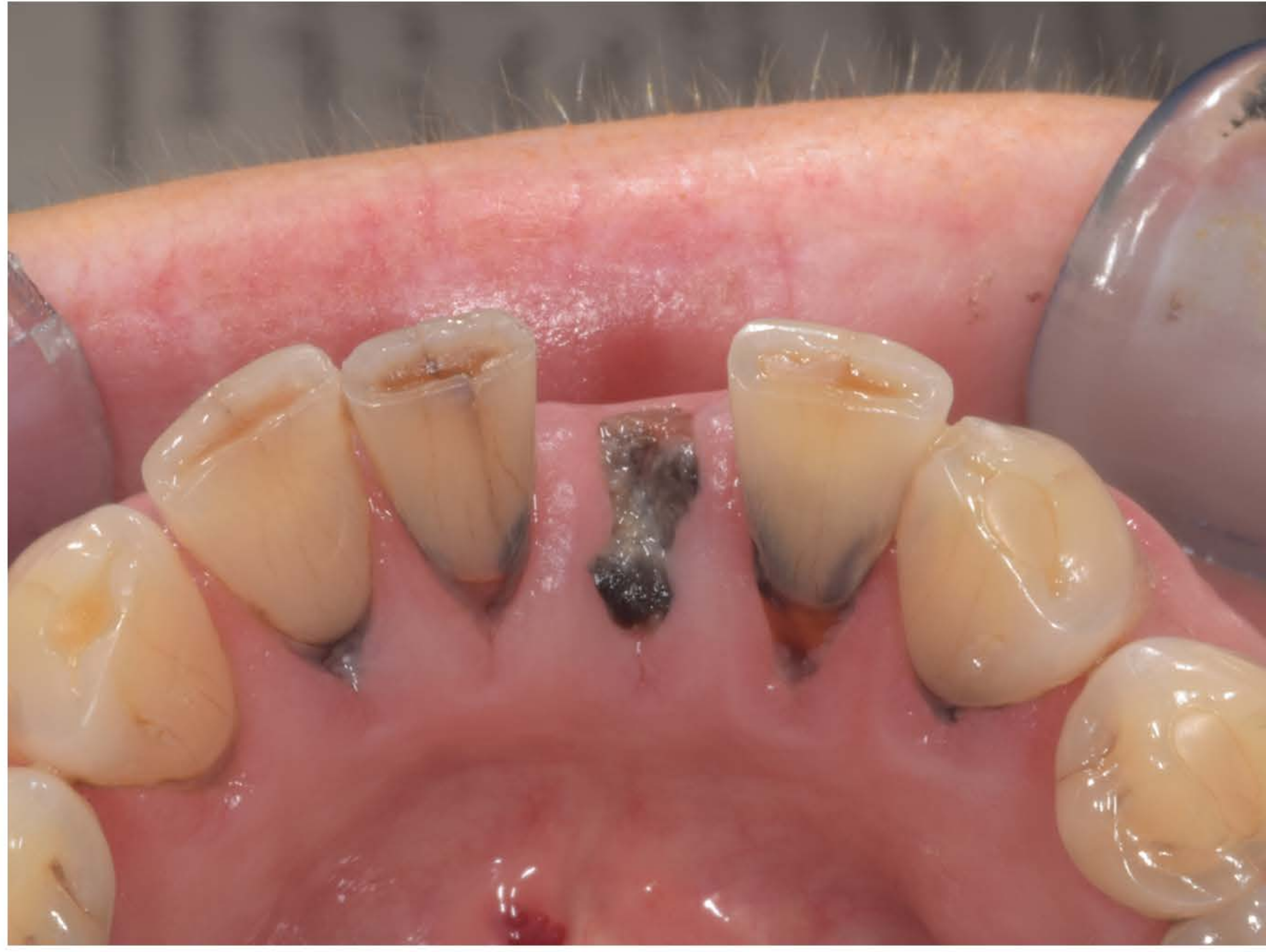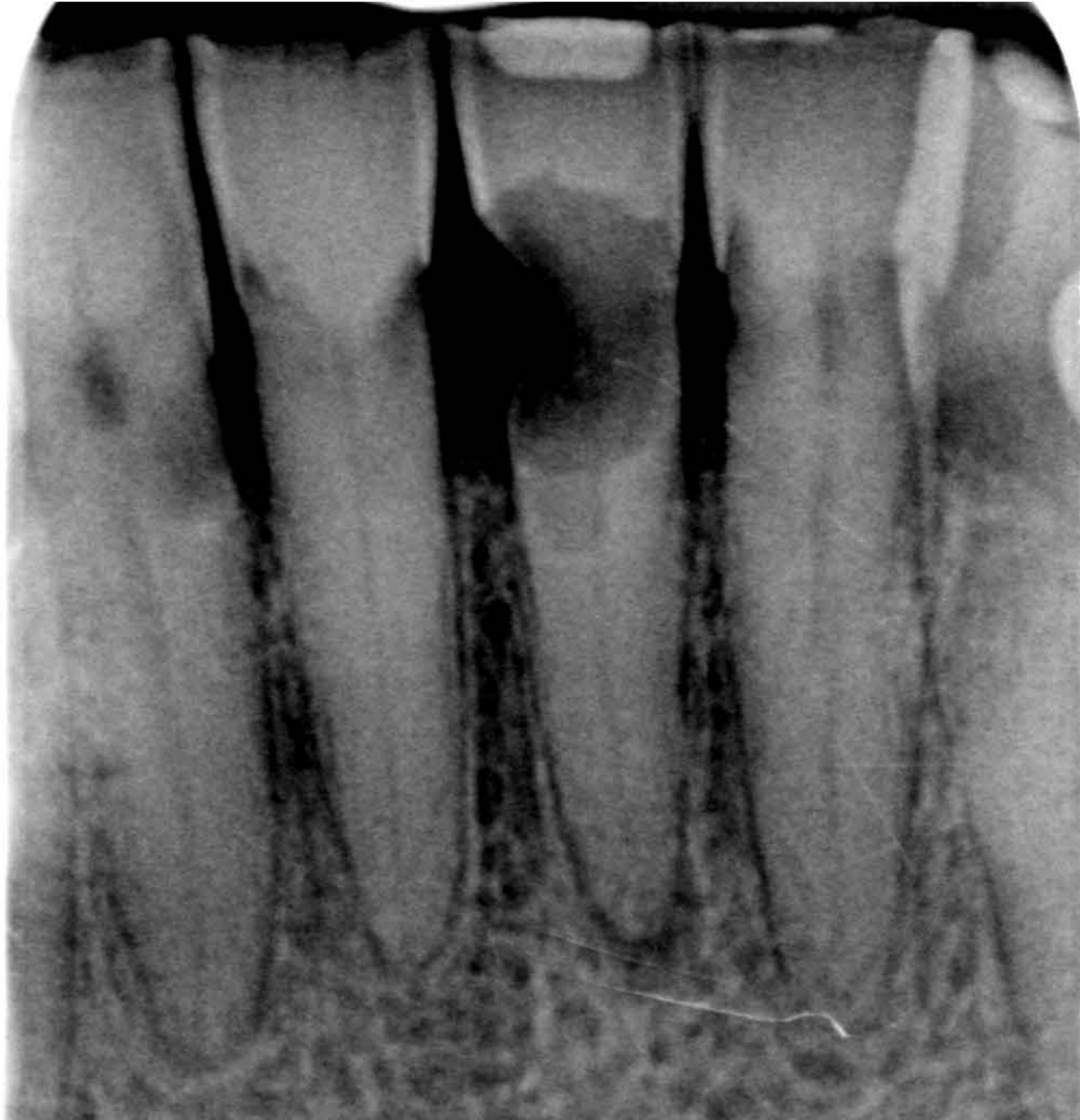


Dr. Alessandro Fasano ITALY

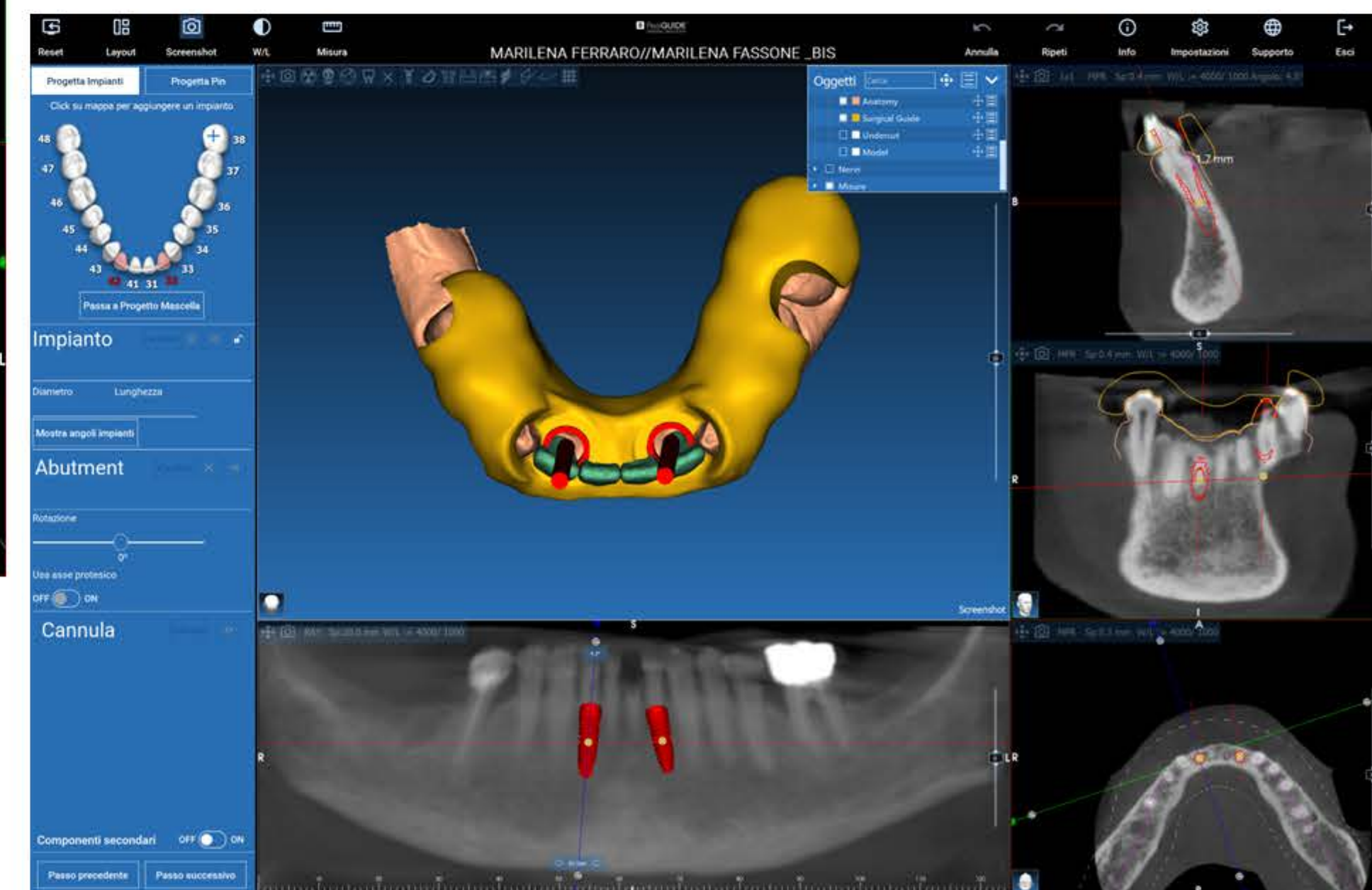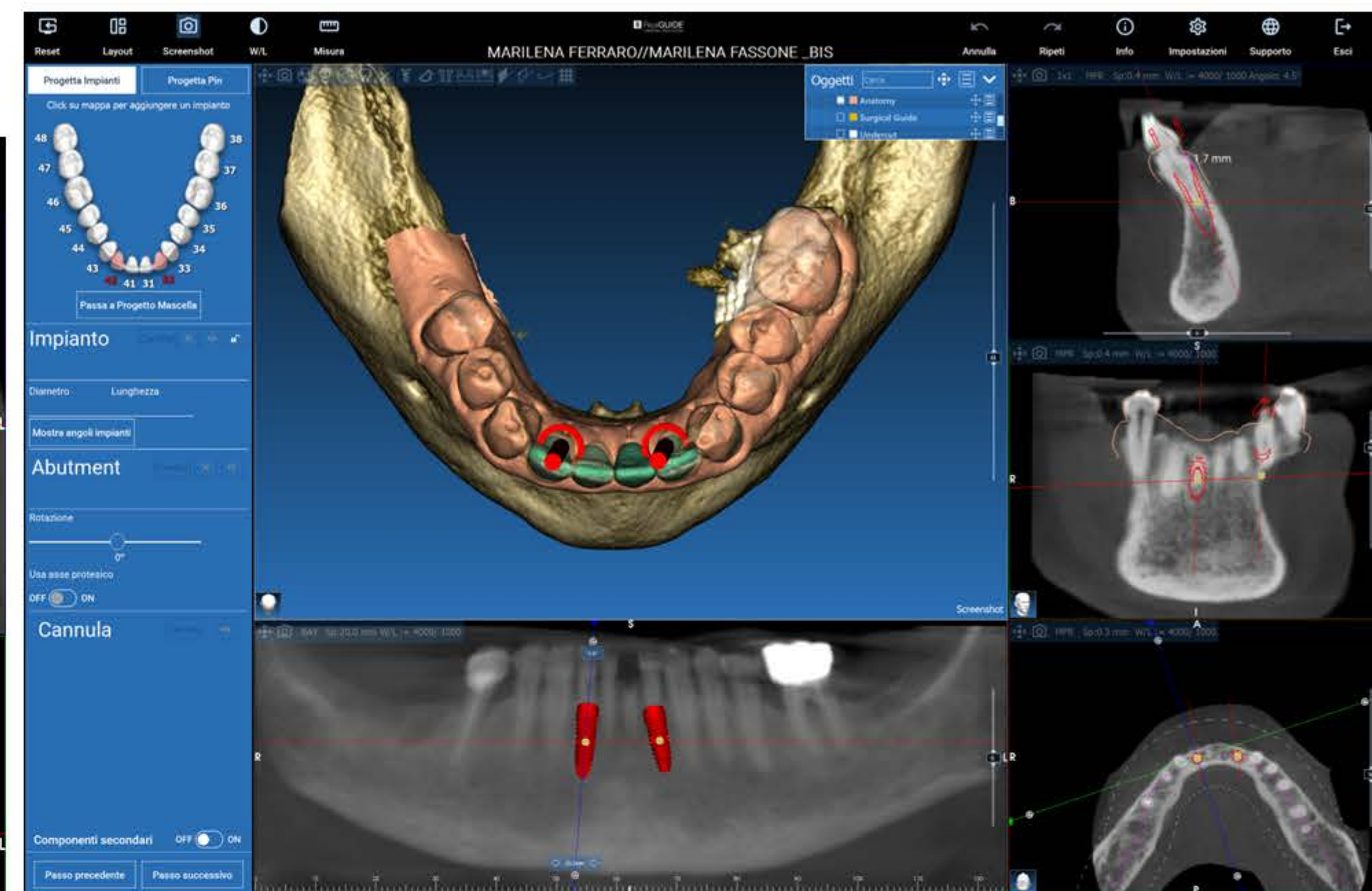
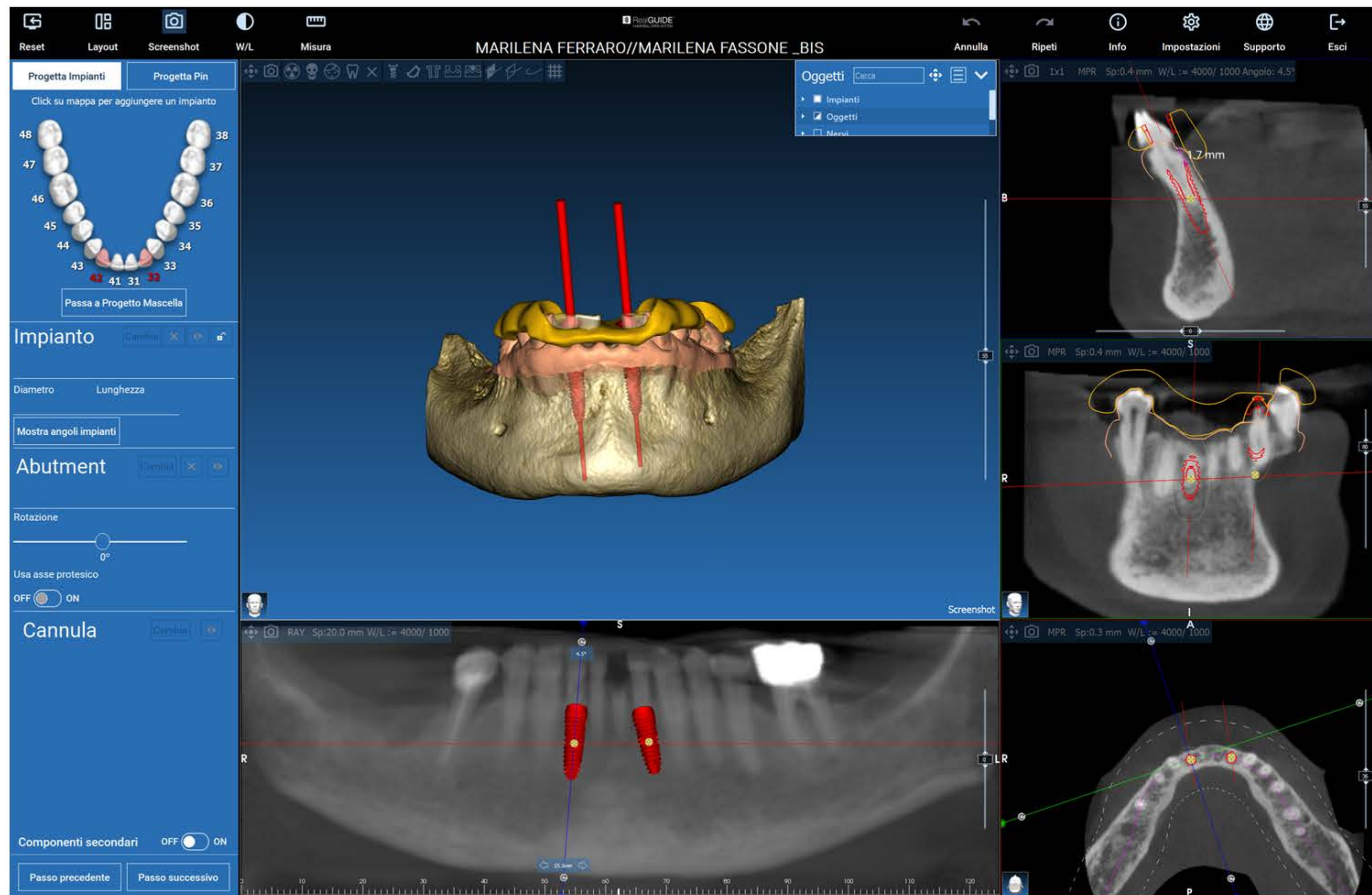
- Patient 78 years old
- Medical history: ten years ago was treated for pharynx tumor by means of radiotherapy, the tumor went into remission but with a big damage to the mouth.
- In the last two years she has been operated on the heart for valve problems
- The patient is given many medications including anticoagulant.
- Dental history: the patient is losing teeth in lower jaw due to destructive caries. She was subjected to conservative treatment, for the large number of carious lesion, but in the lower mandibular group, we have decided on an immediate replacement with guided surgery.
- The surgery has been programmed, with the suspension two days before (under the advice of the cardiologist) of the anticoagulant drugs, a prophylaxis was also done with amoxicillin and clavulanic acid one day before the surgery and for a week after, painkillers were also administered.



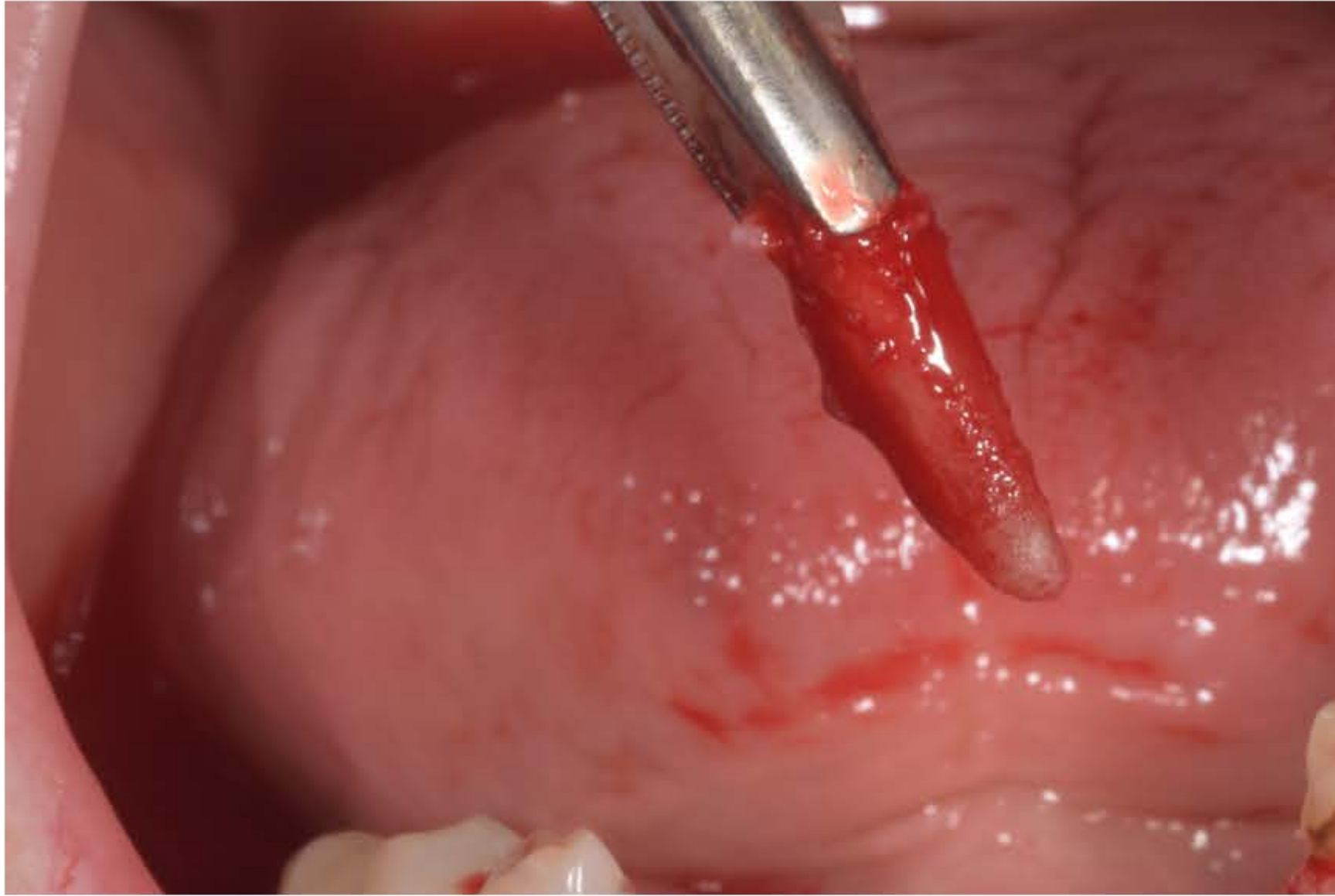
Situation at the base line



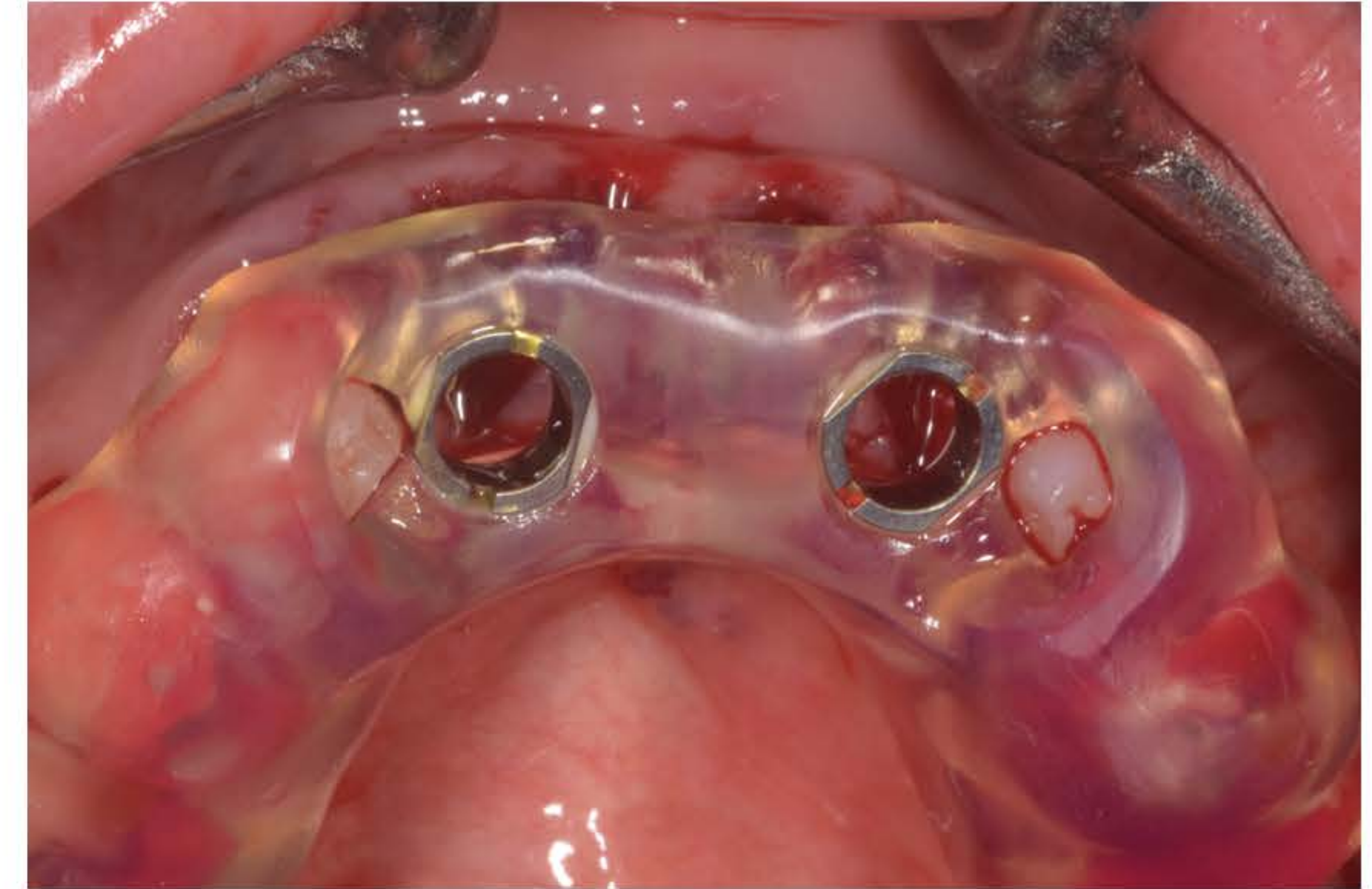
The digital project



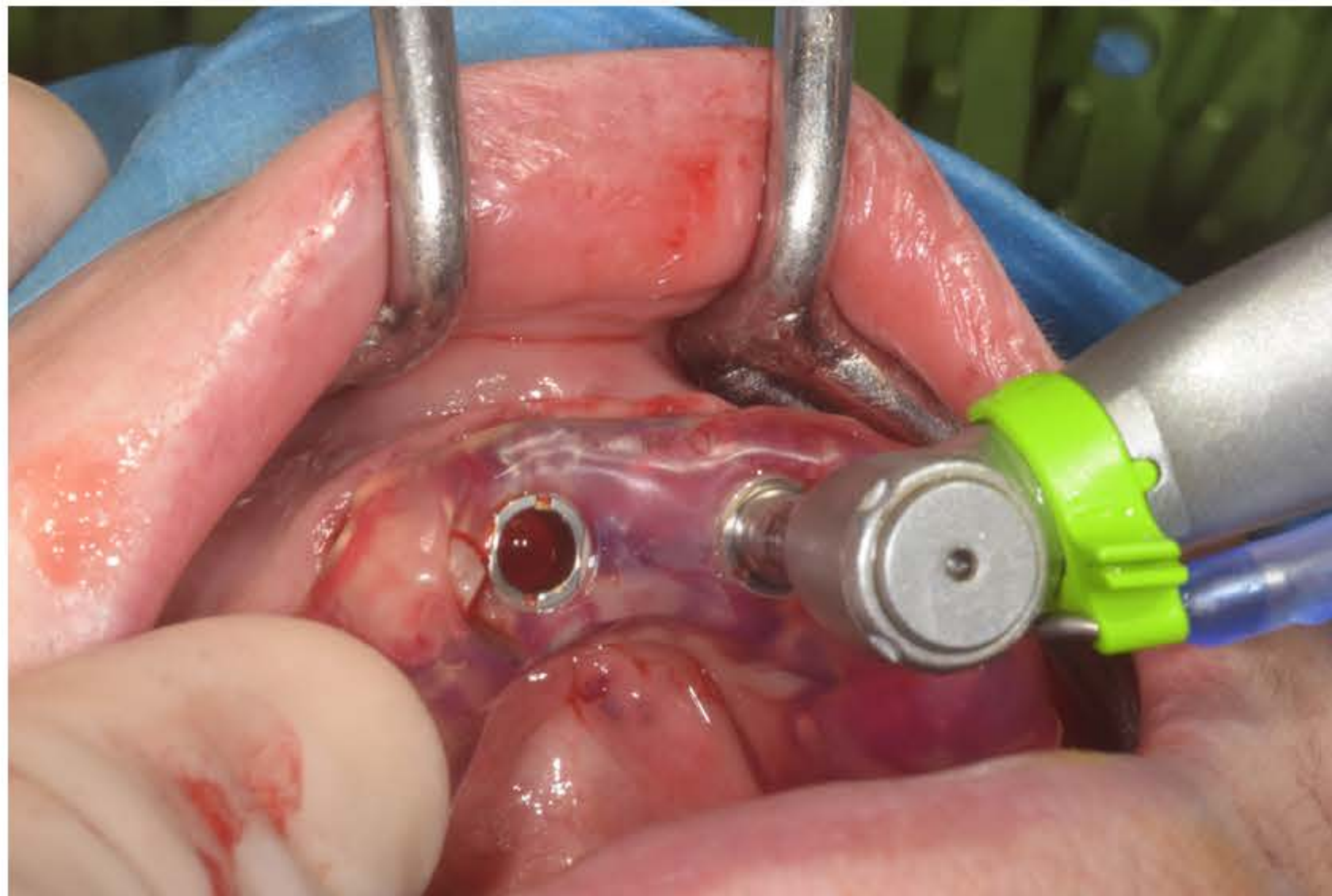The extraction



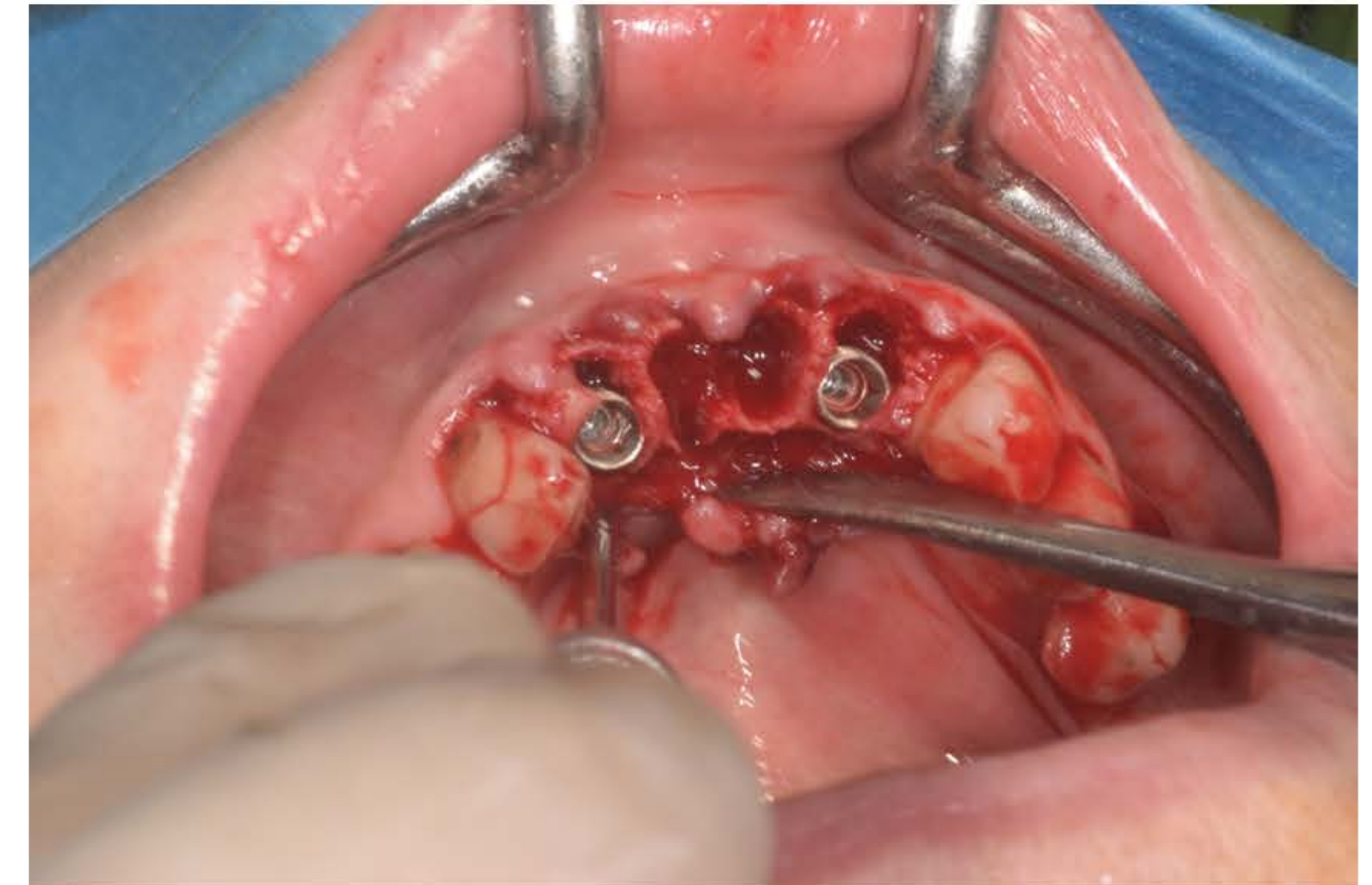
The housing of the surgical guide




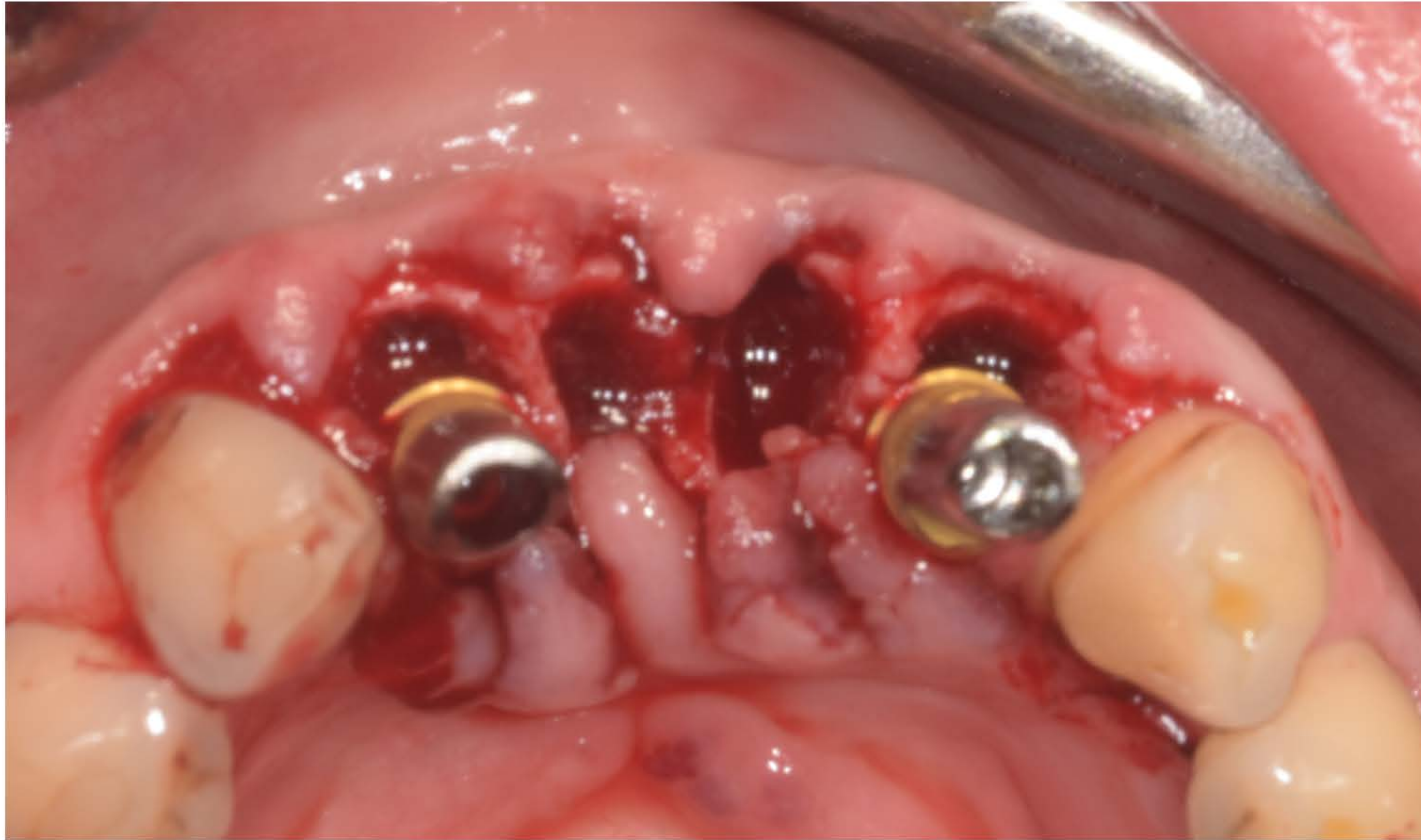
The positioning of the implants IS II Active



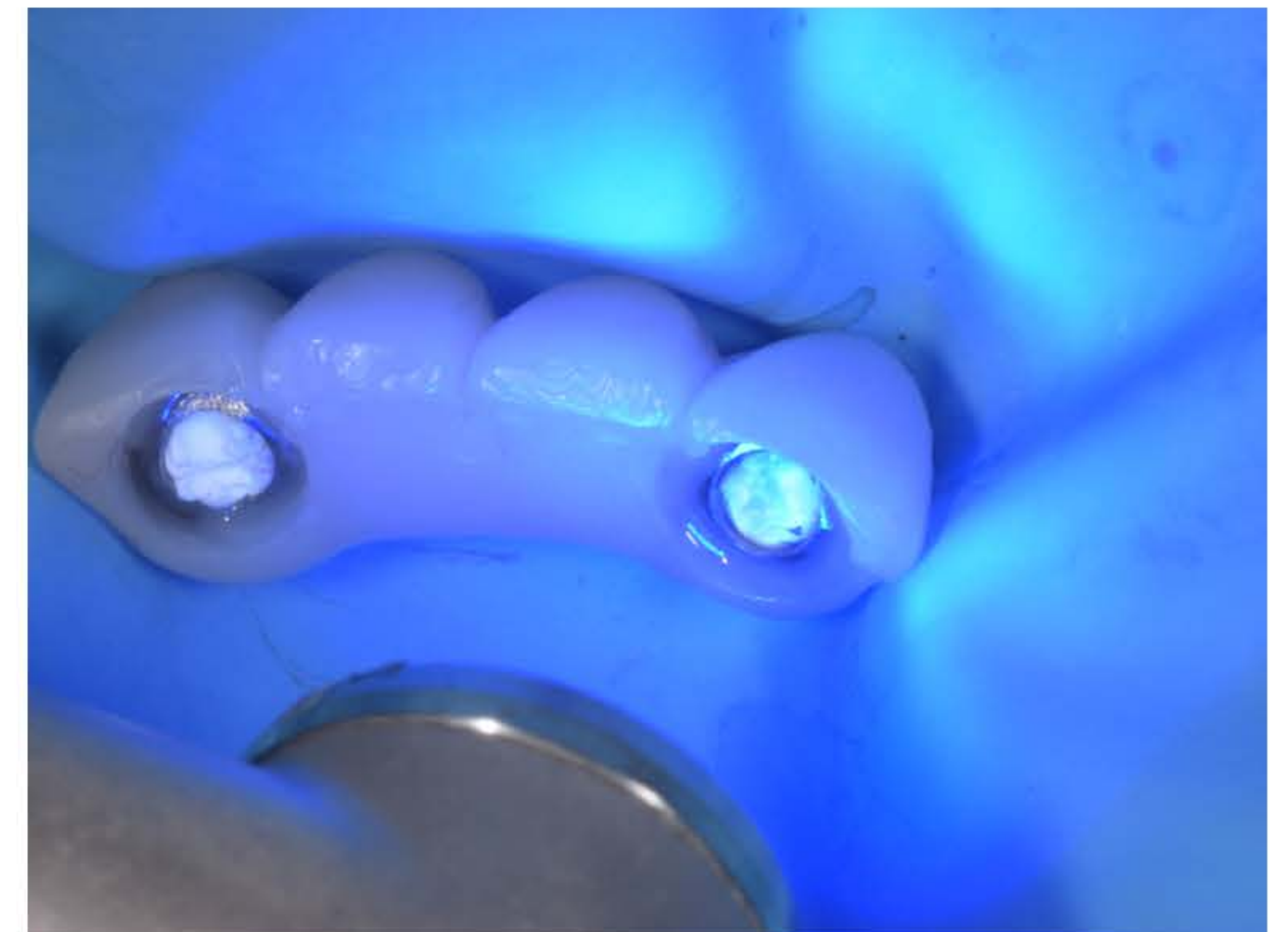Then implants just positioned



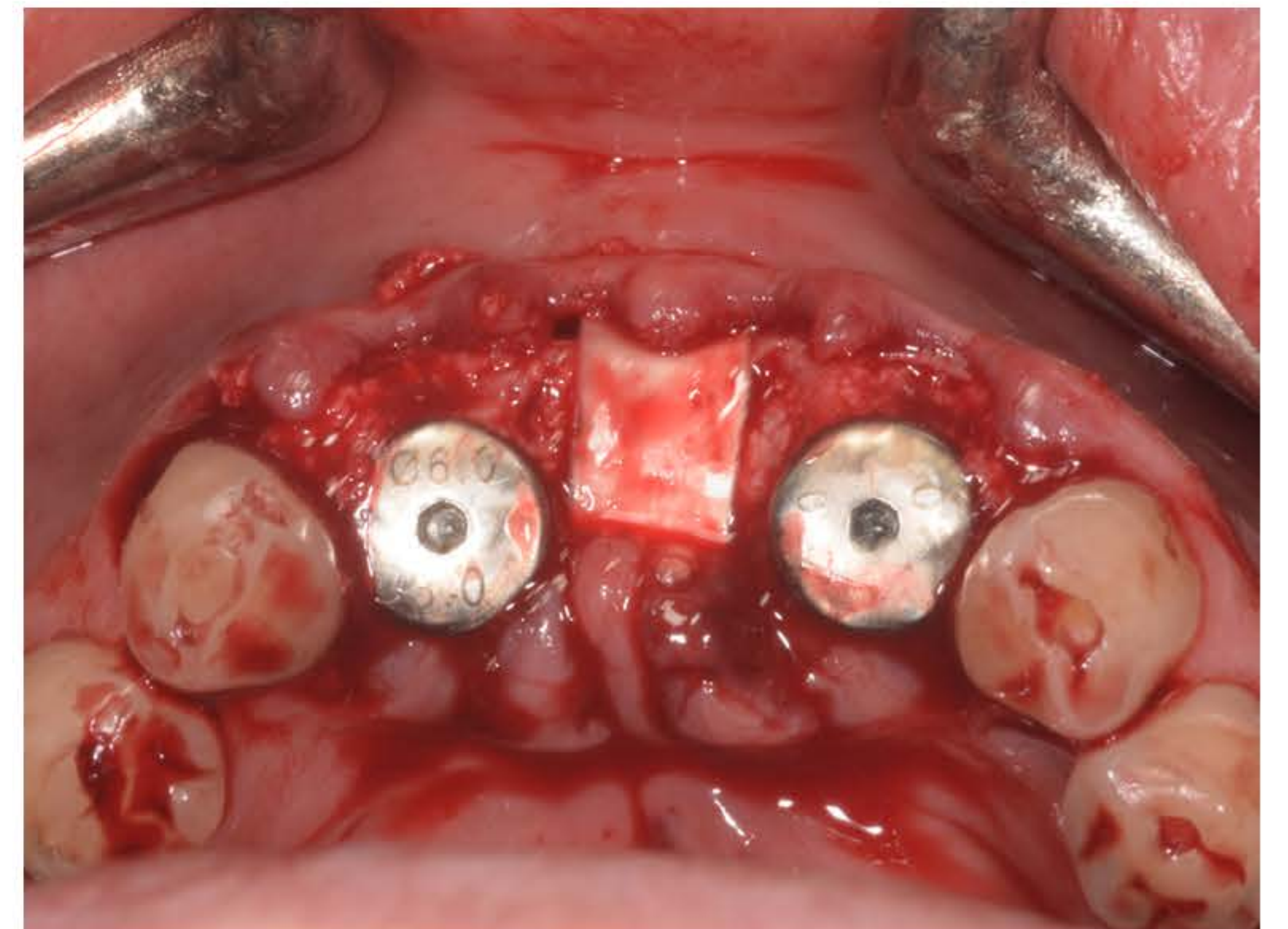
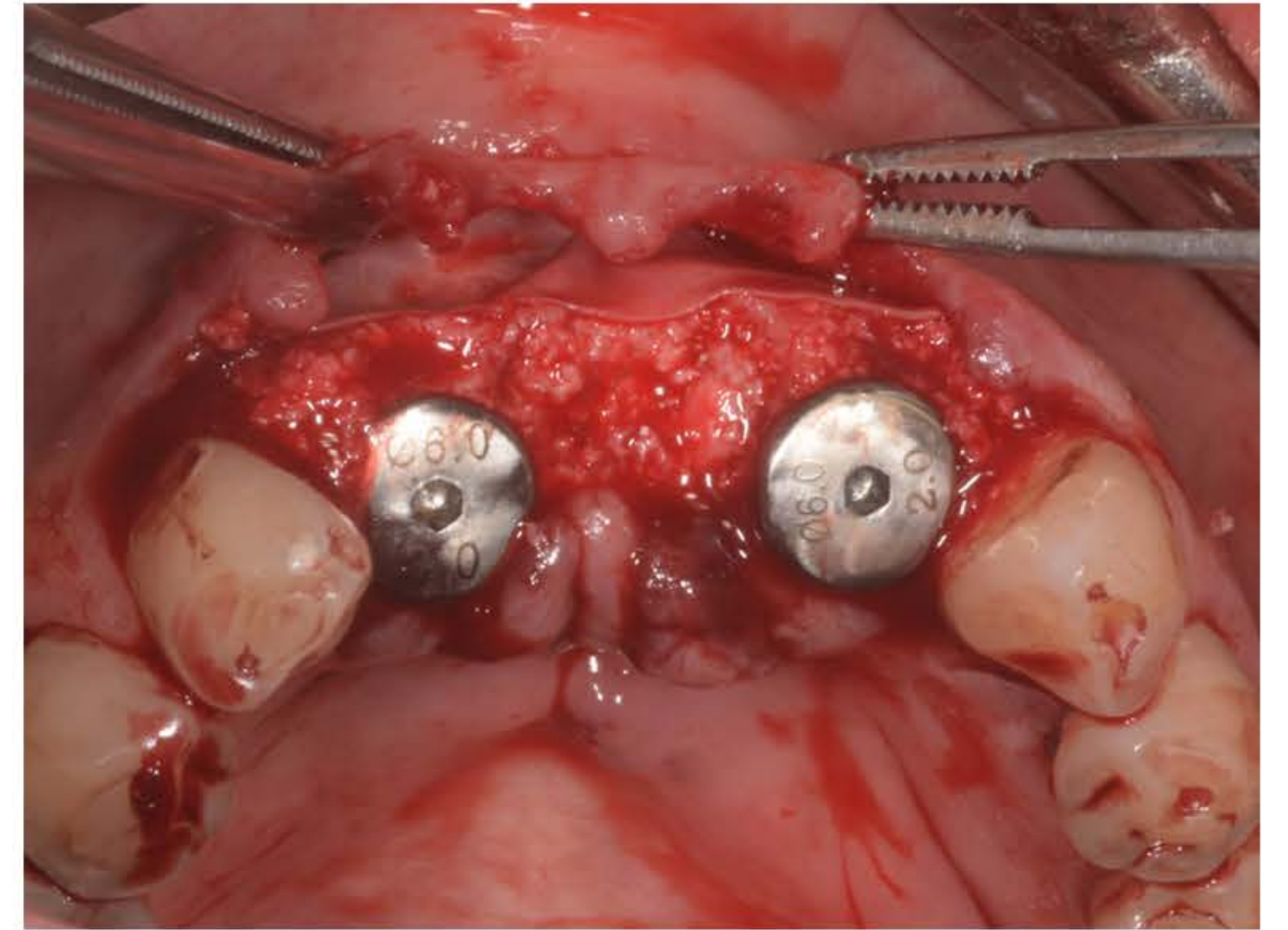
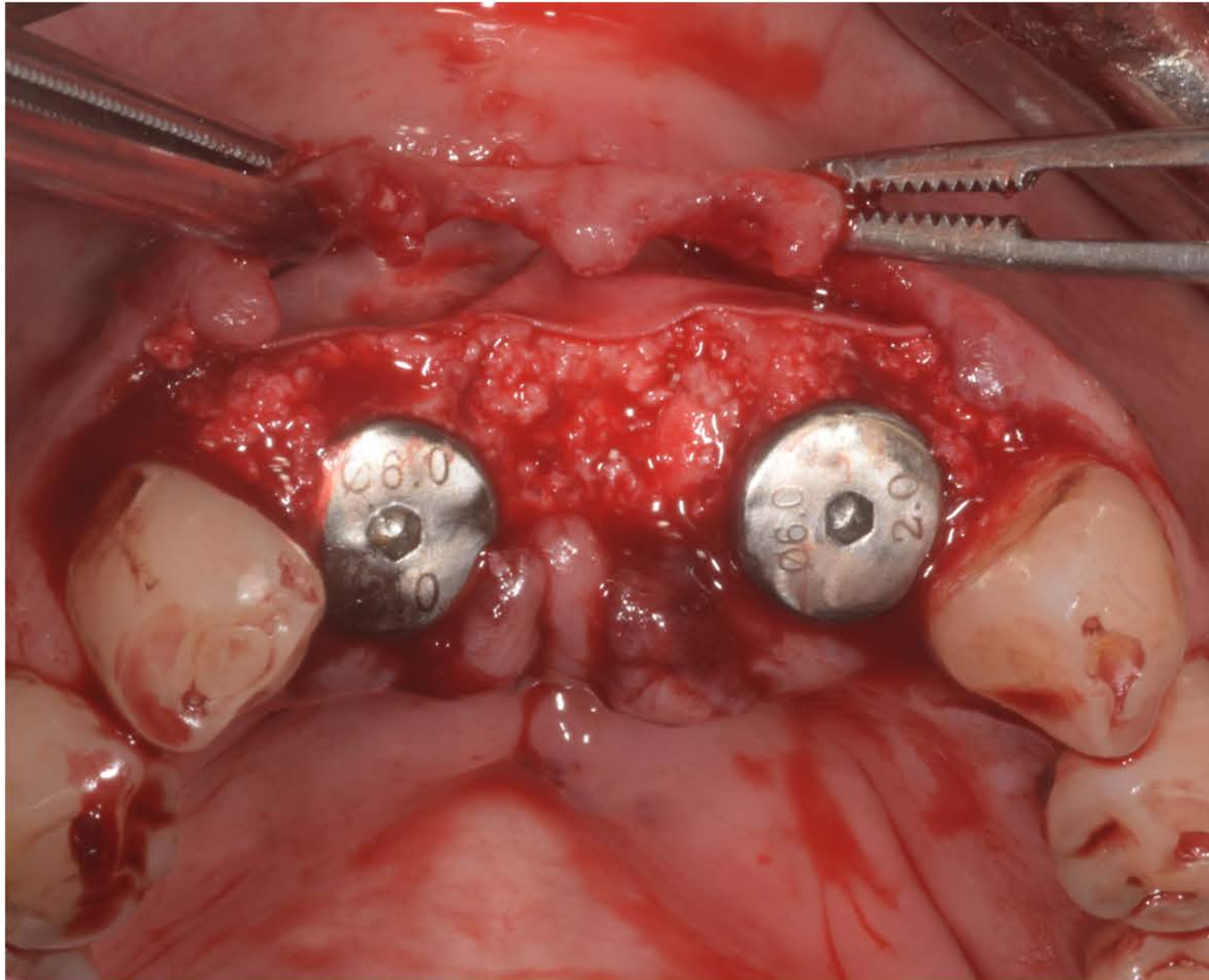
The passage for the construction of a temporary prosthesis by adhesive dentistry



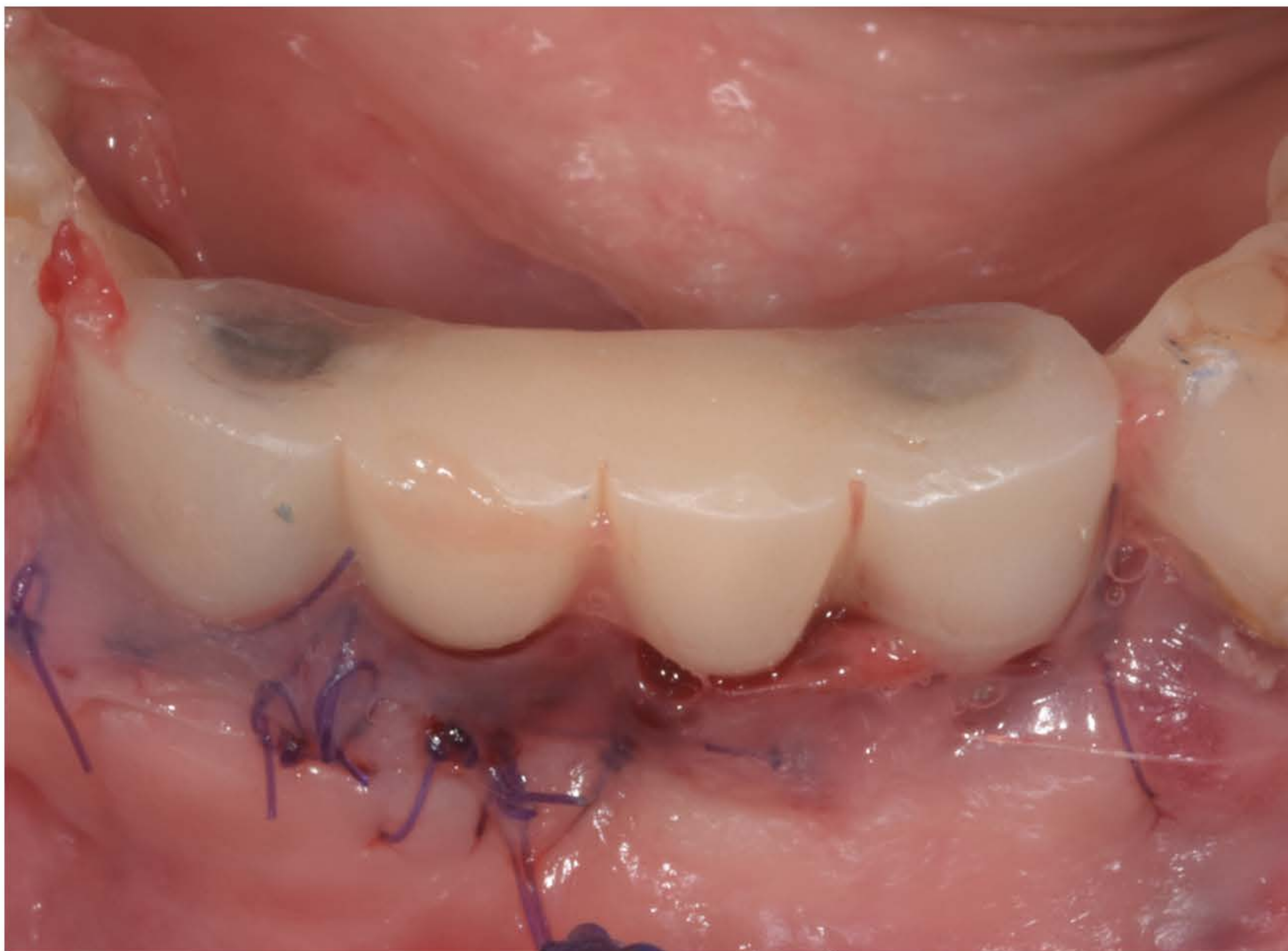The polymerization



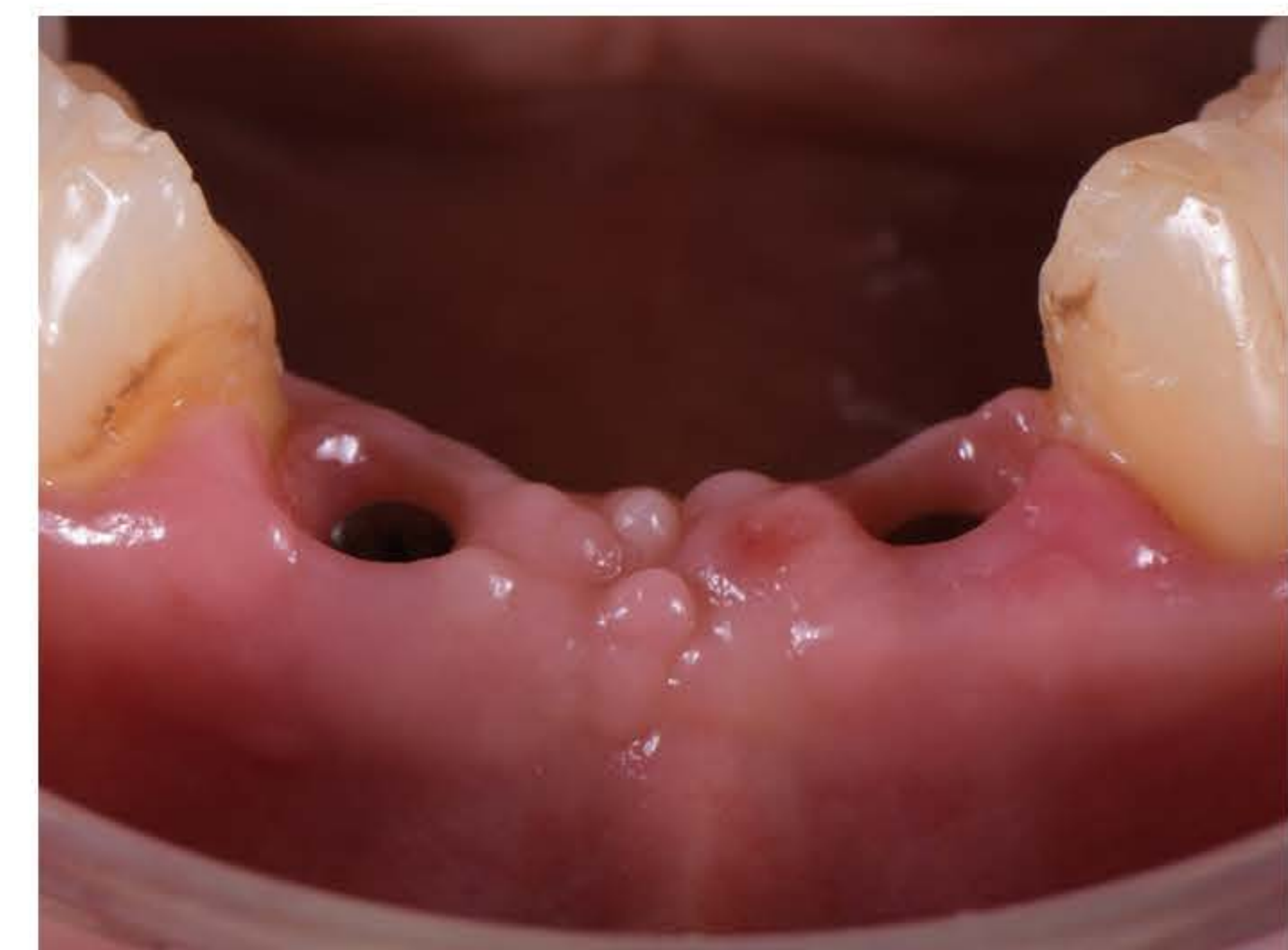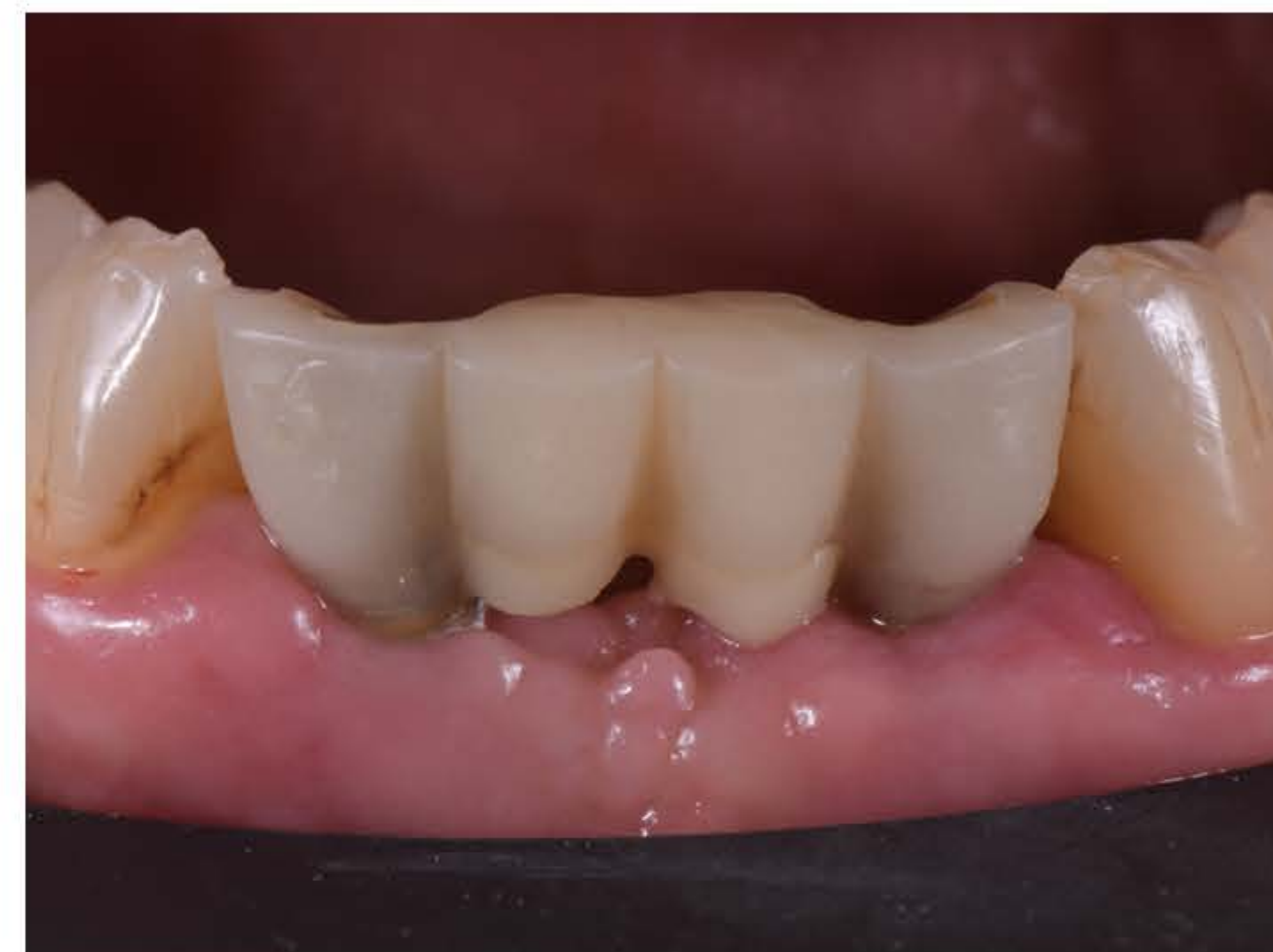The management of the hard and soft tissue with deproteized bovine bone, readsorbable cross linked collagen membrane and fibrin glue "Tissel Baxter"



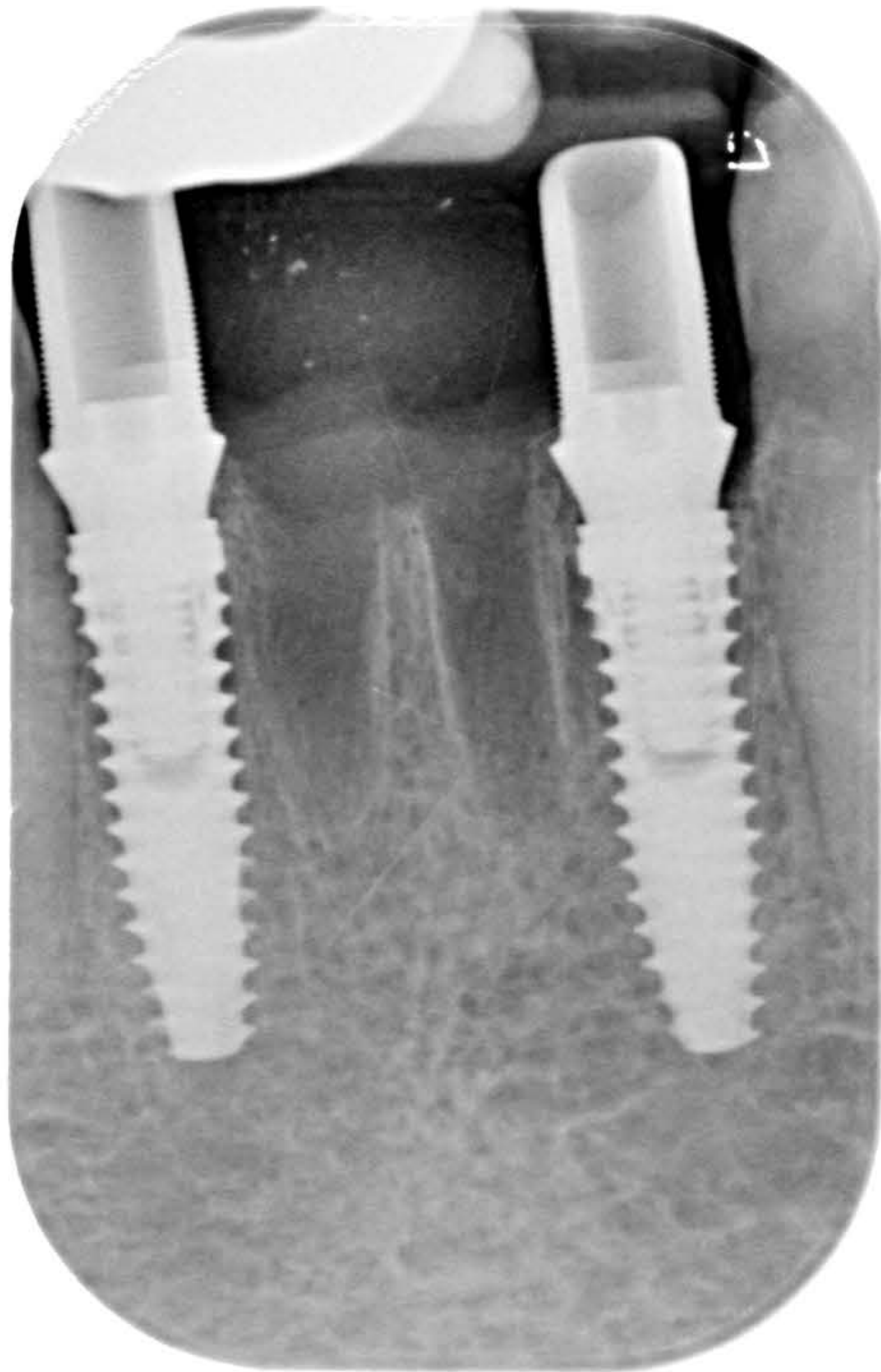
Just finished the surgery



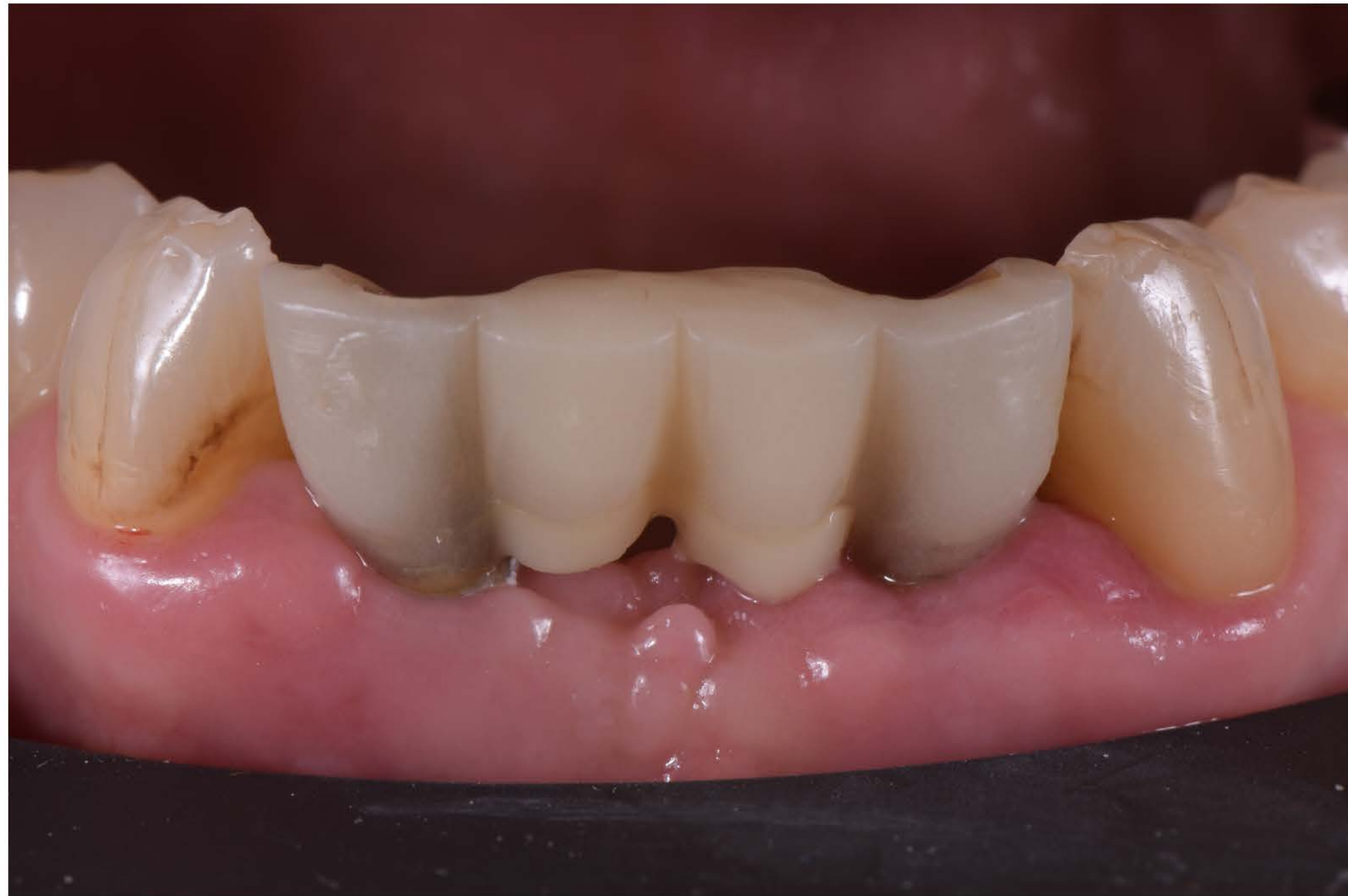After four month



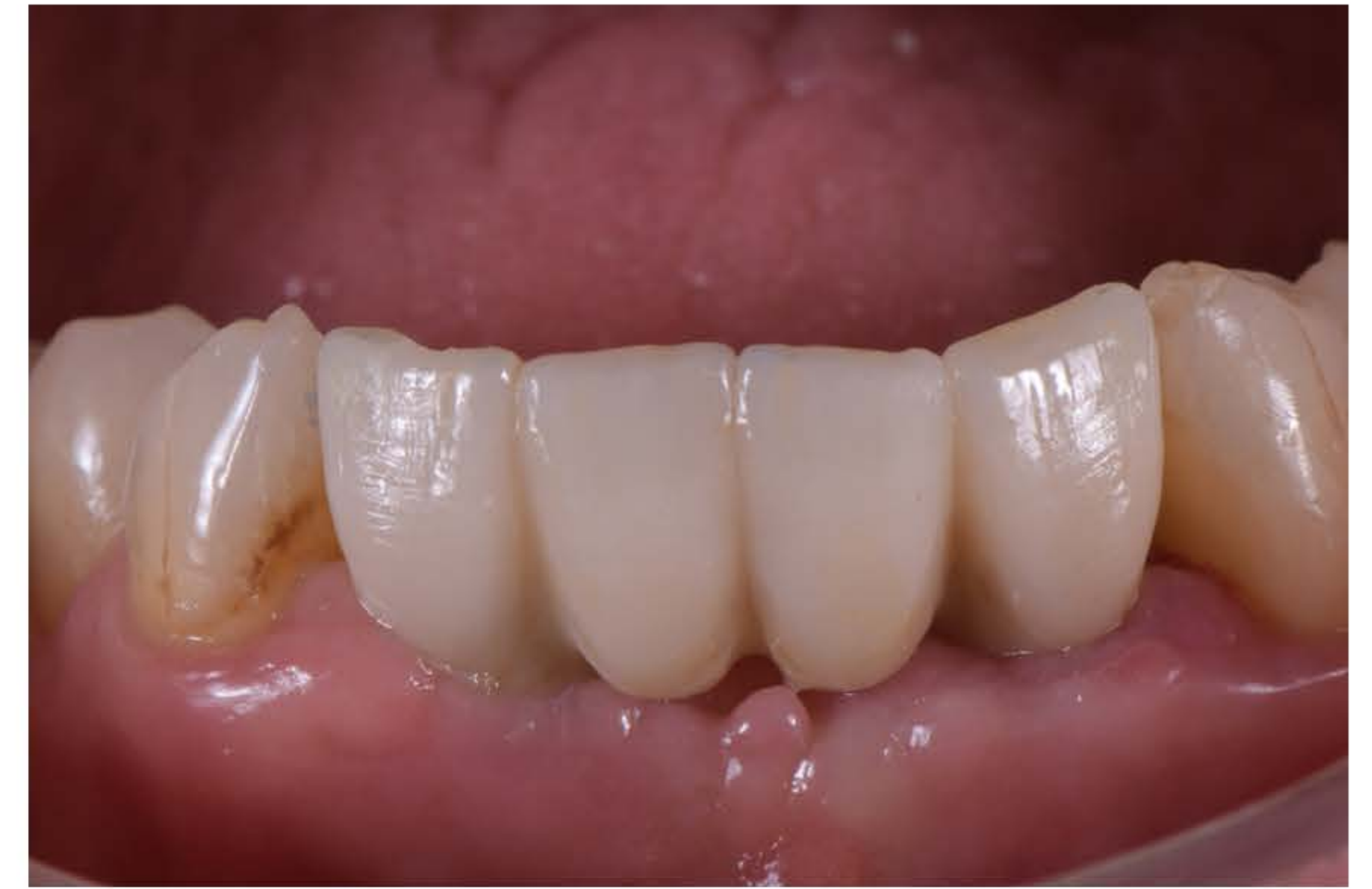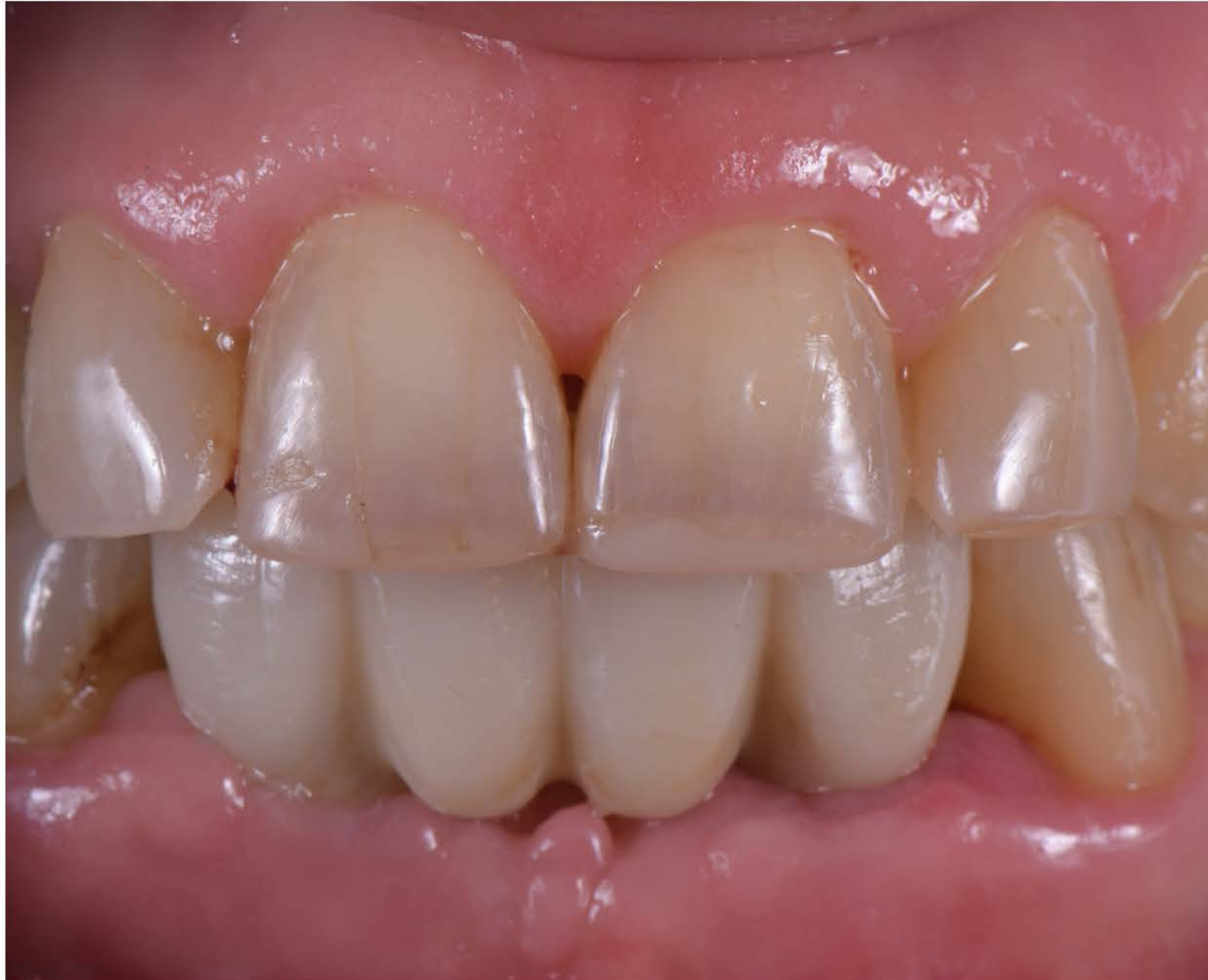Rx control



The temporary after four month



Case finished after six month



Xr control

