

*Full rehabilitation with
Neobiotech*

Dr. Irakli Chachua, MD, PhD

Prosthodontist, Implantologist

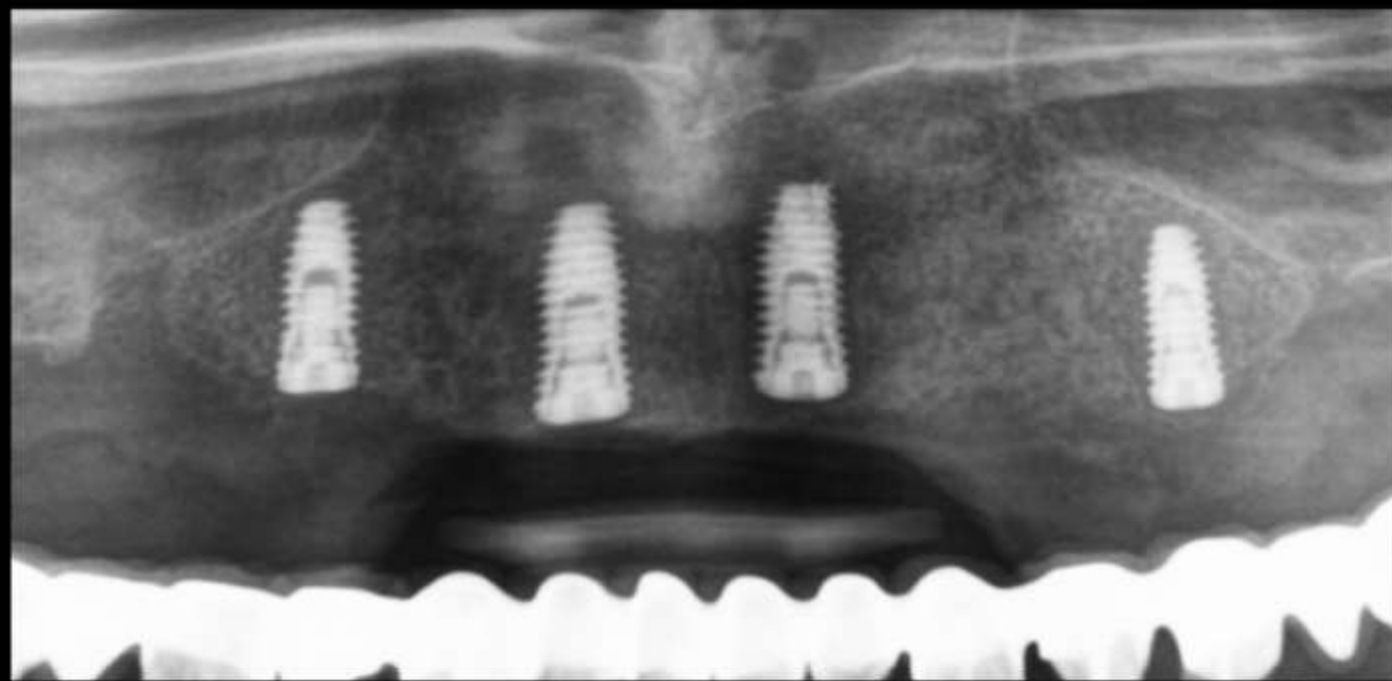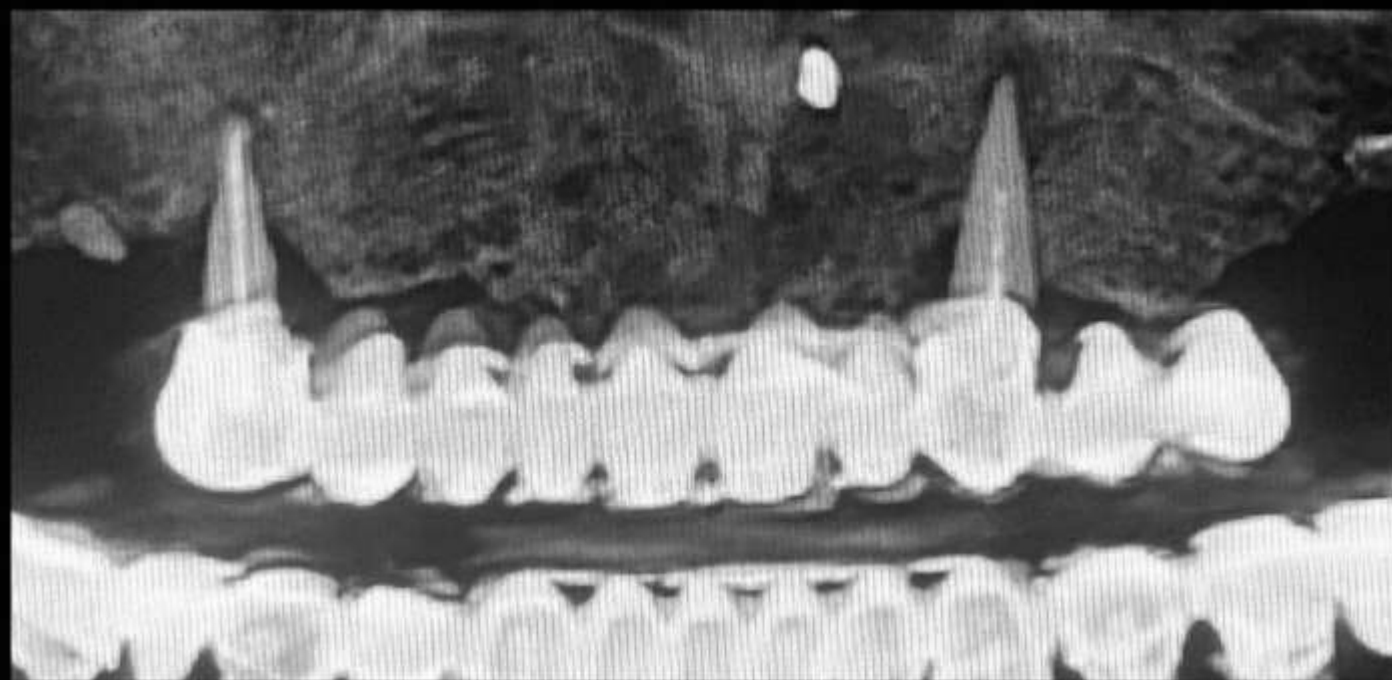
ZEPPELIN

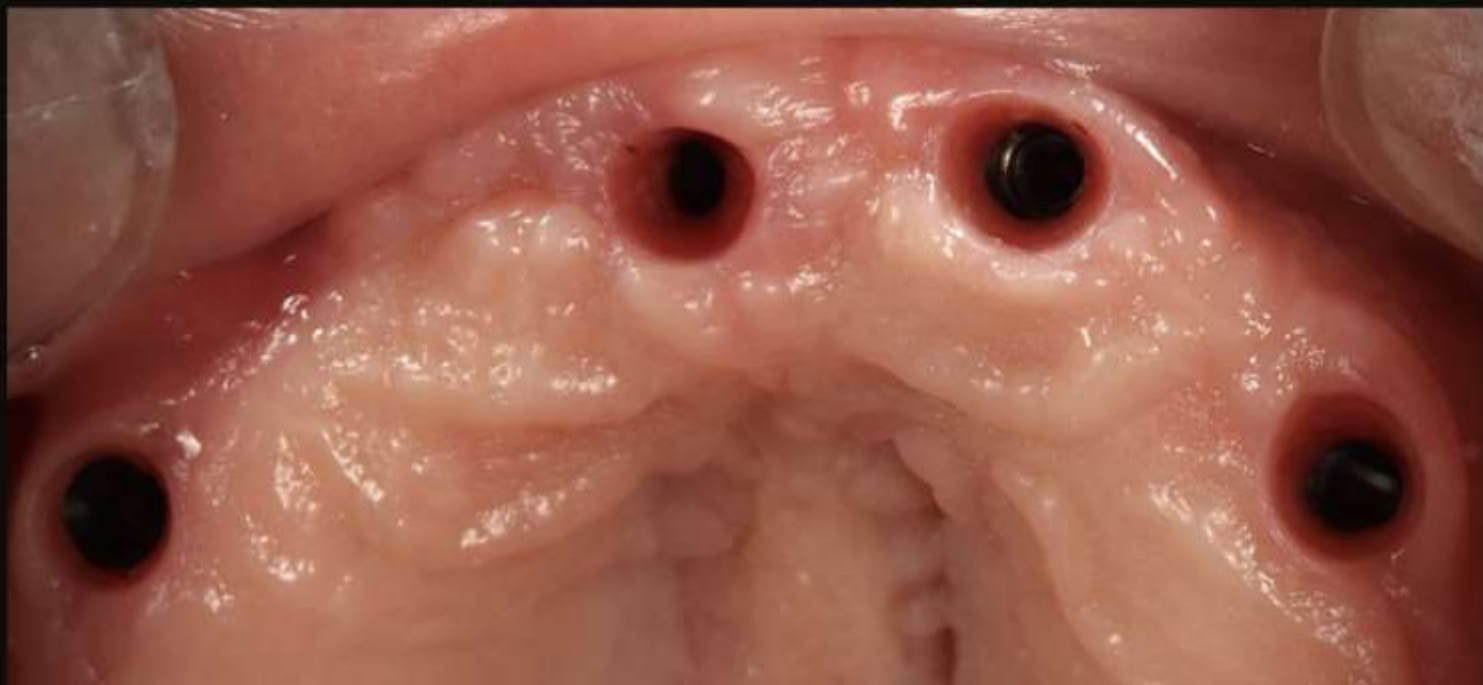
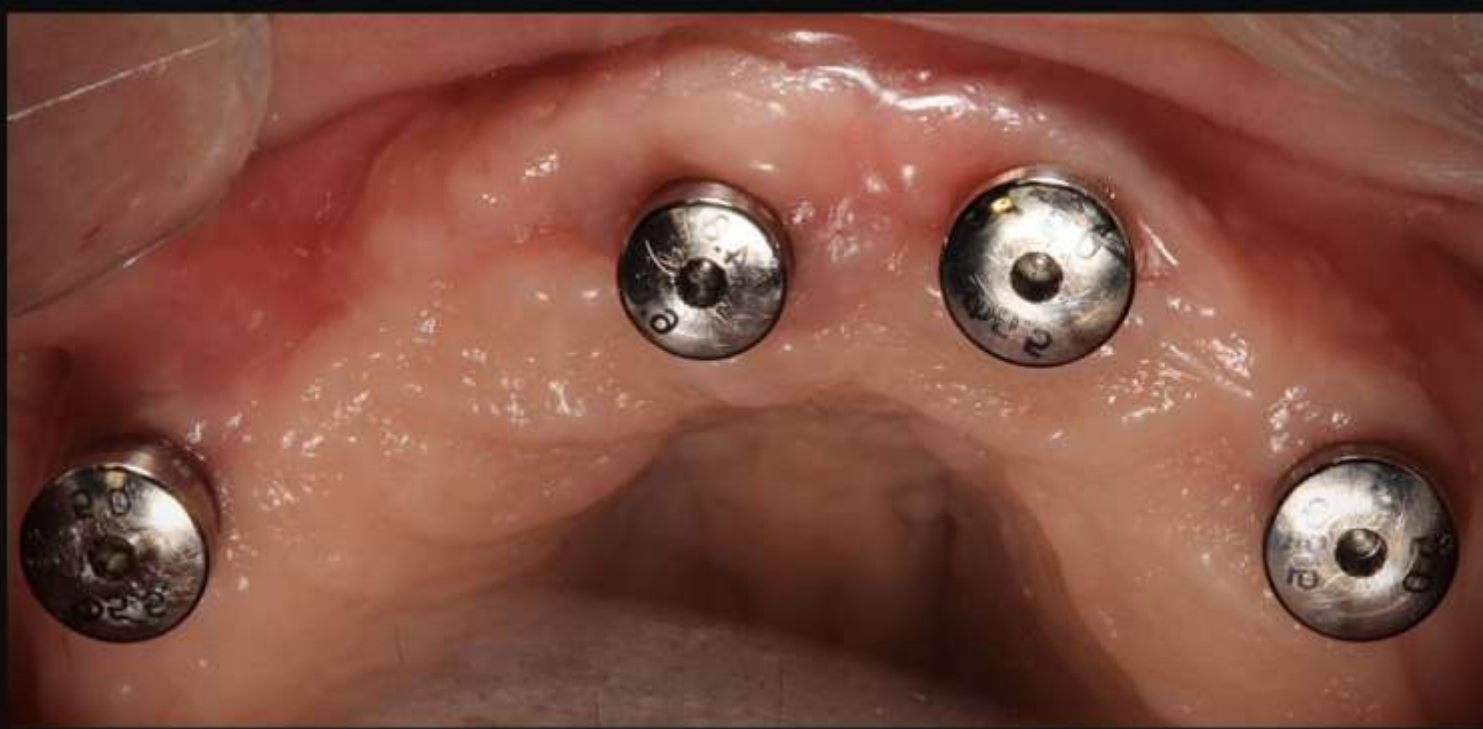Dental Clinic

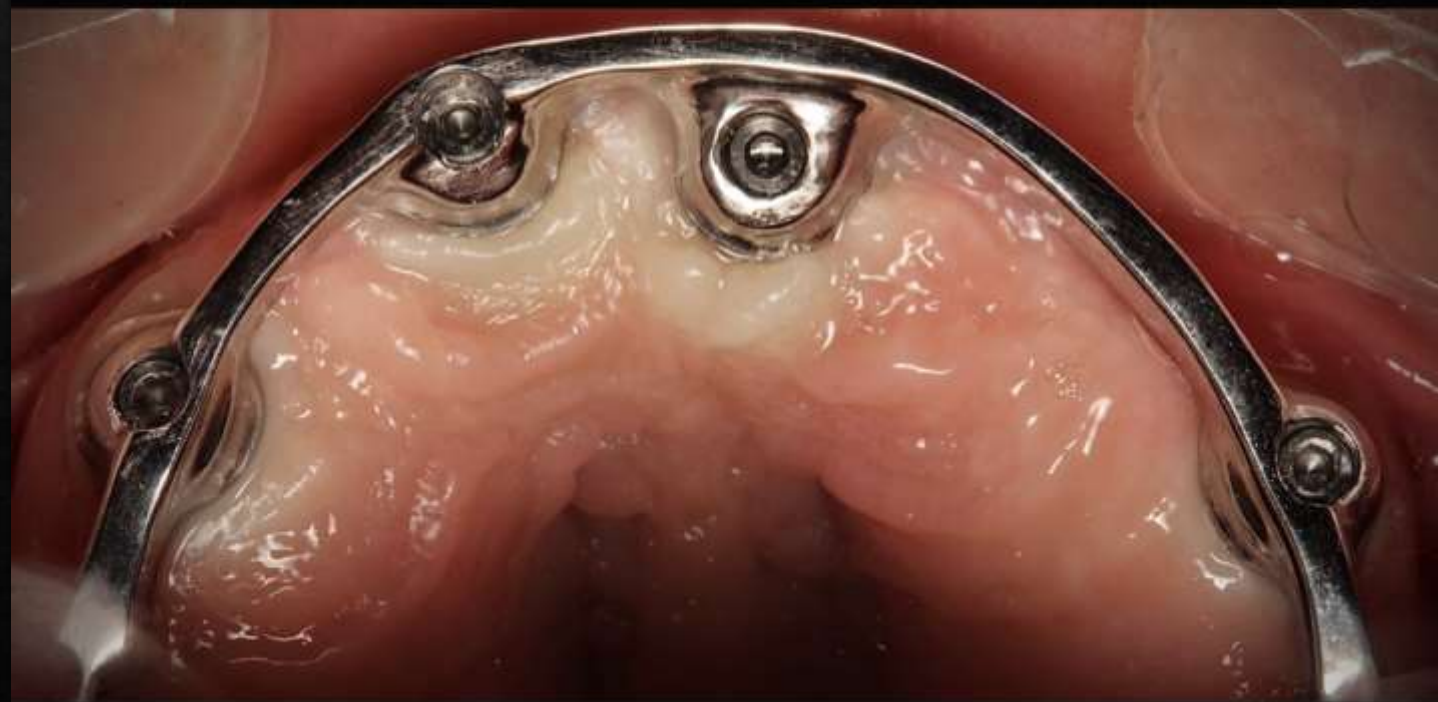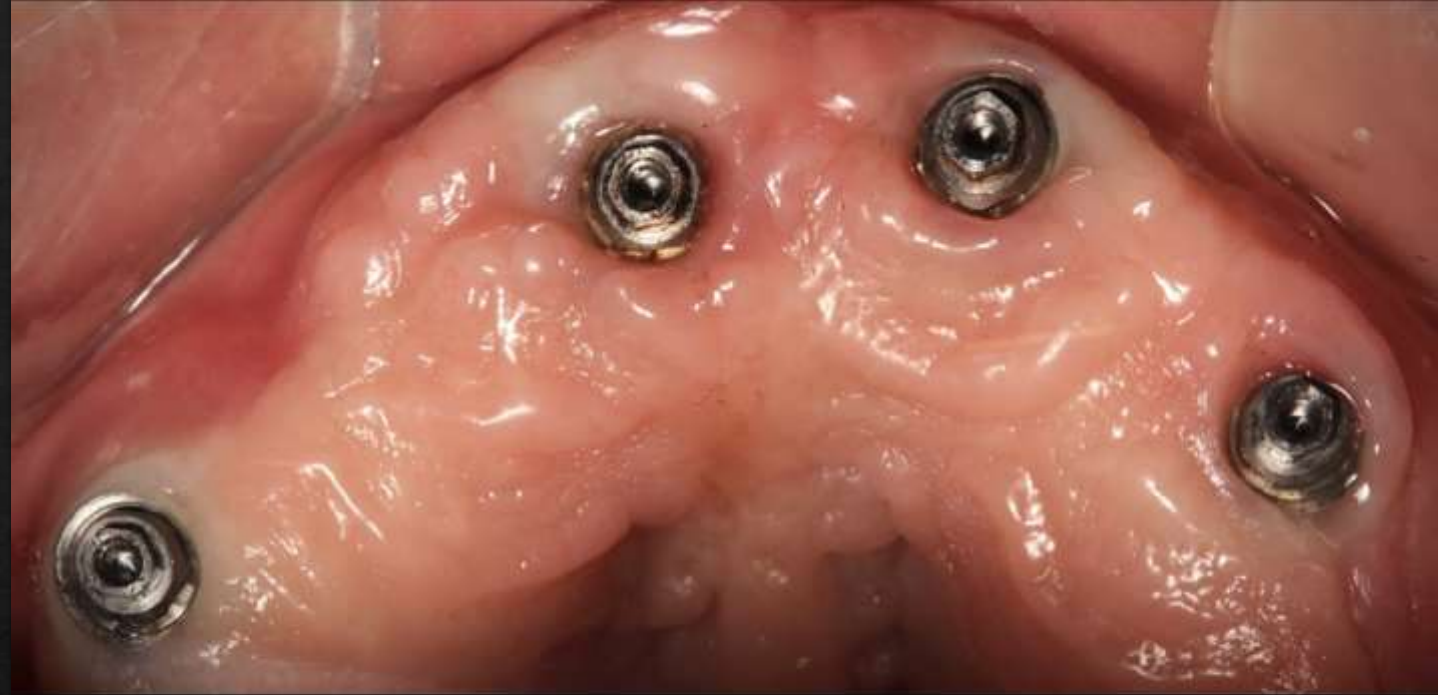Tbilisi, Georgia

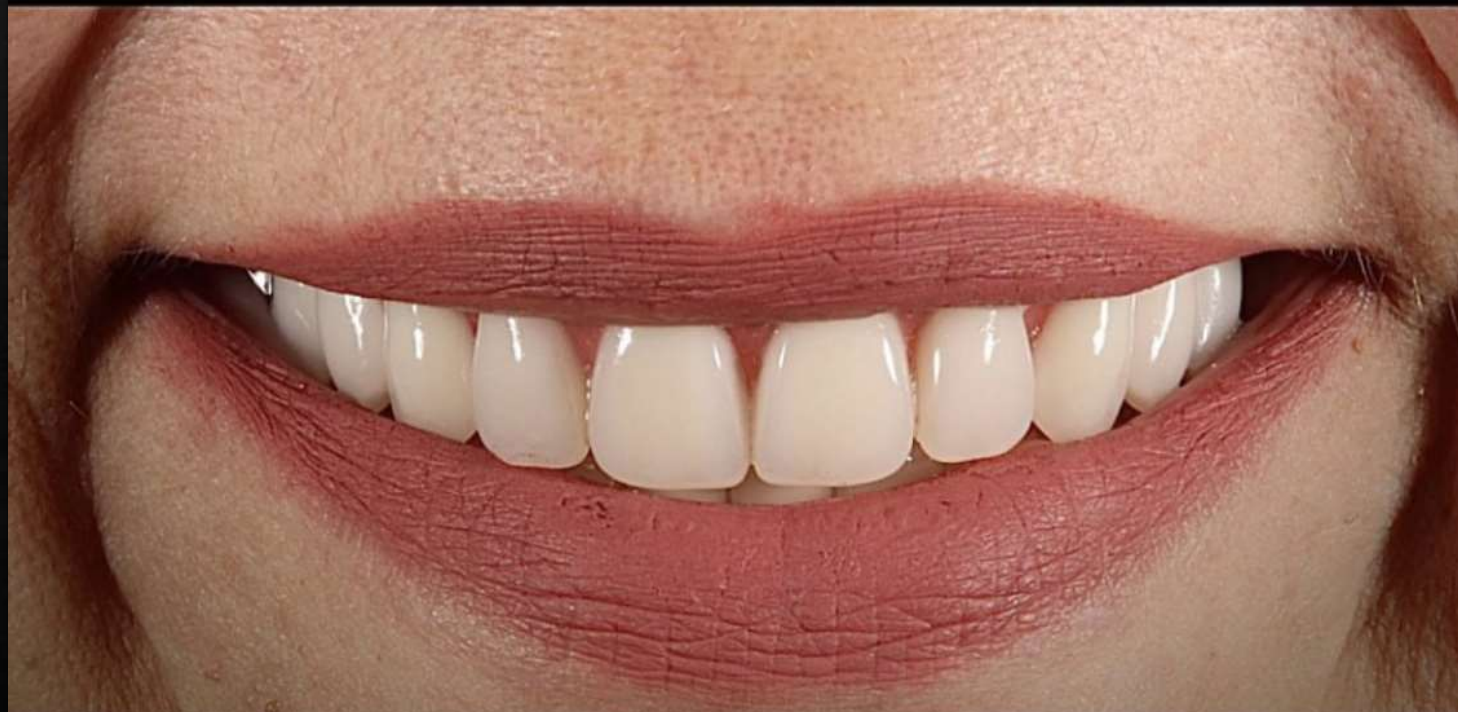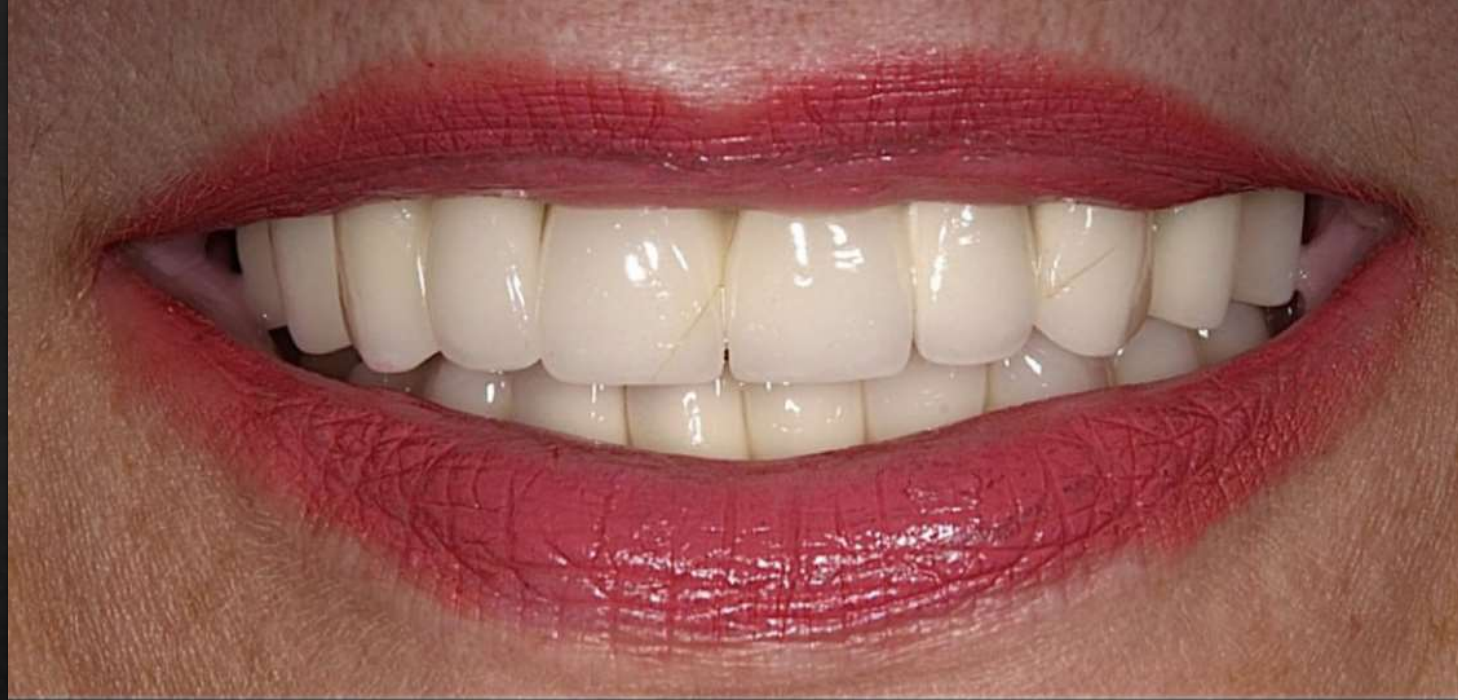Case 1

- ◇ Patient 62 y.o
- ◇ Female
- ◇ Heavy smoker
- ◇ No general health condition
- ◇ Esthetical and functional problems on upper jaw
- ◇ TREATMENT PLAN:
- ◇ Patient refused to have a bilateral sinus lifting
- ◇ 4 Implants on maxilla
- ◇ Removable denture on implants







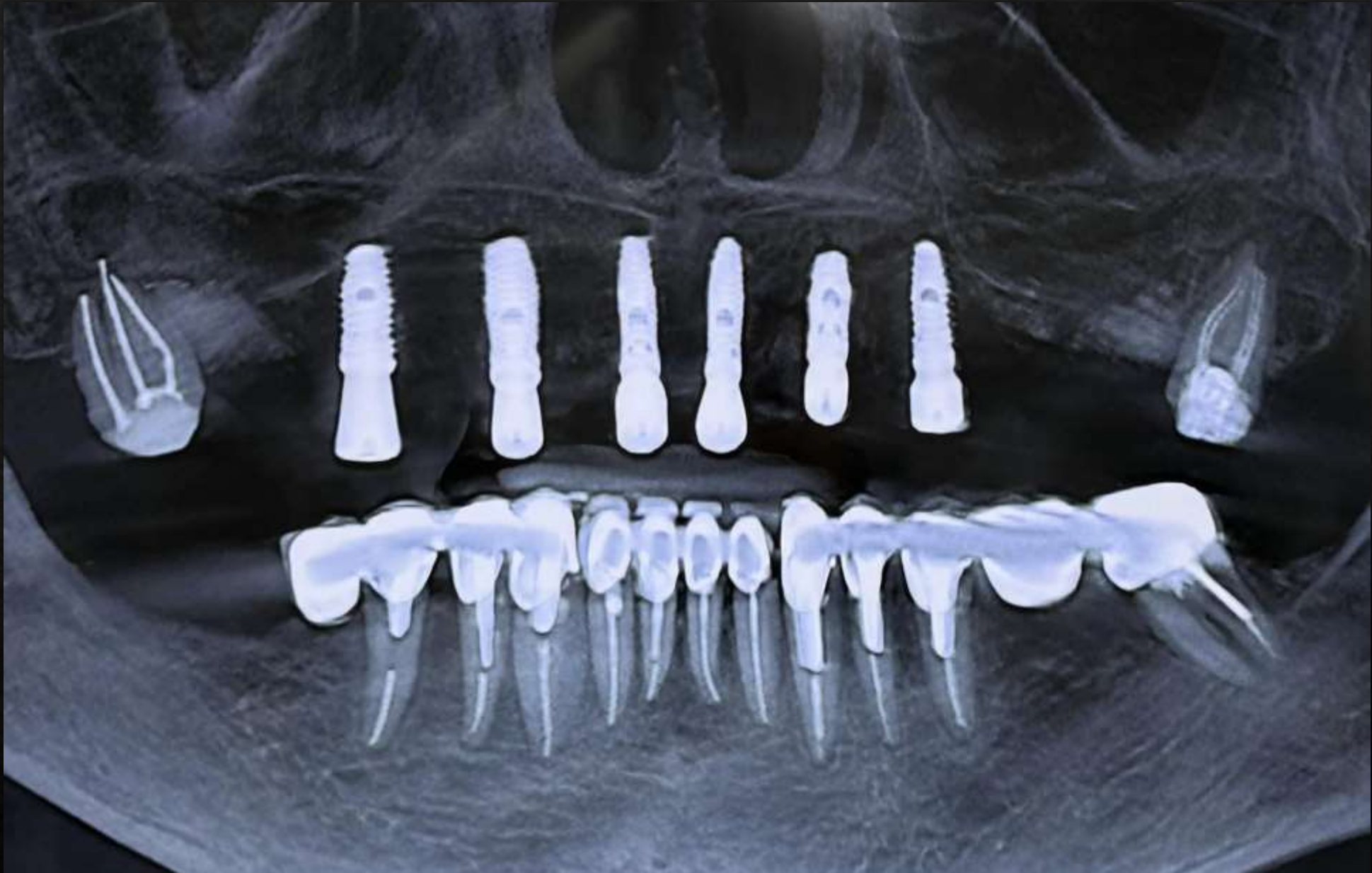


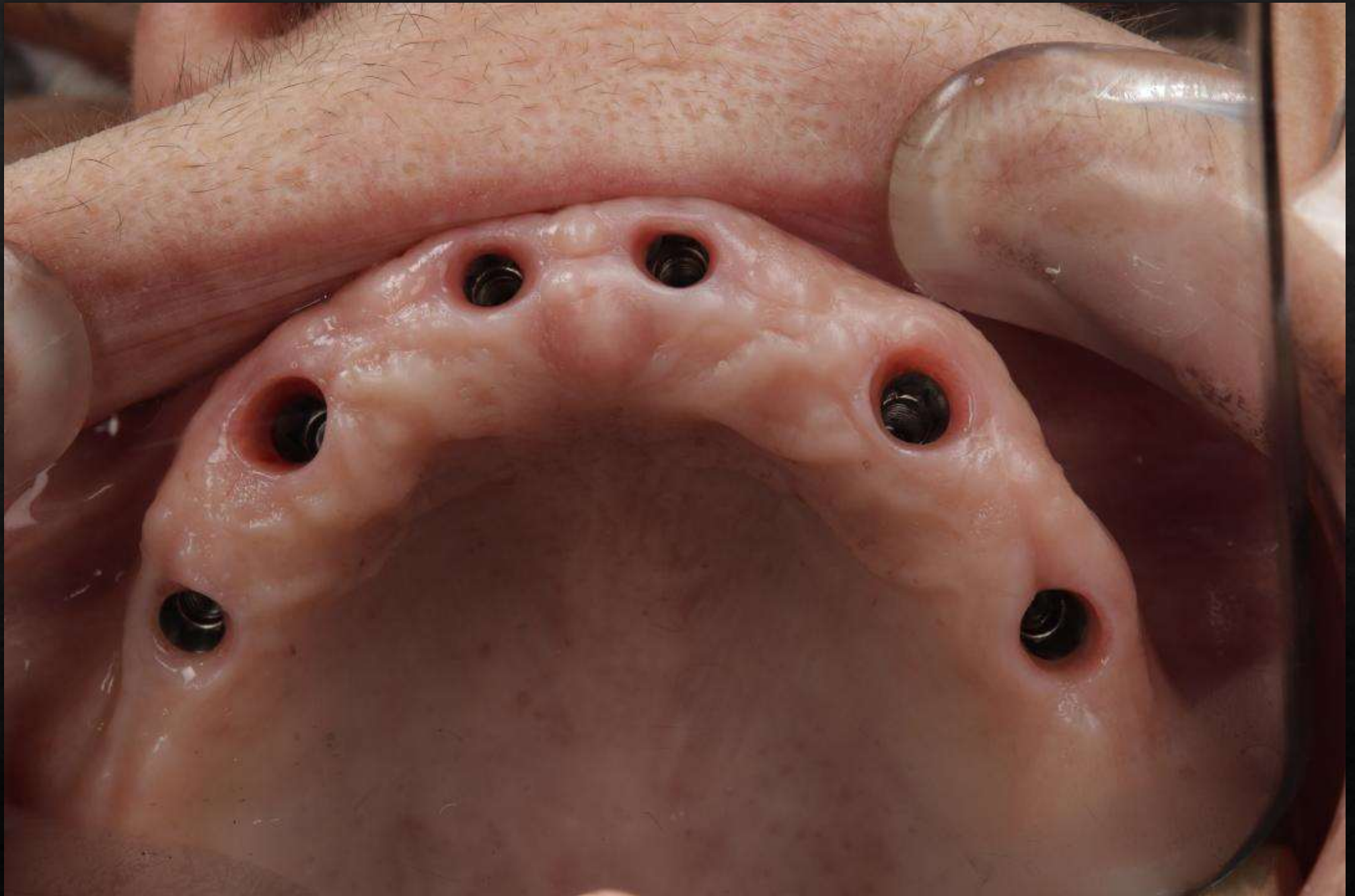Case 2

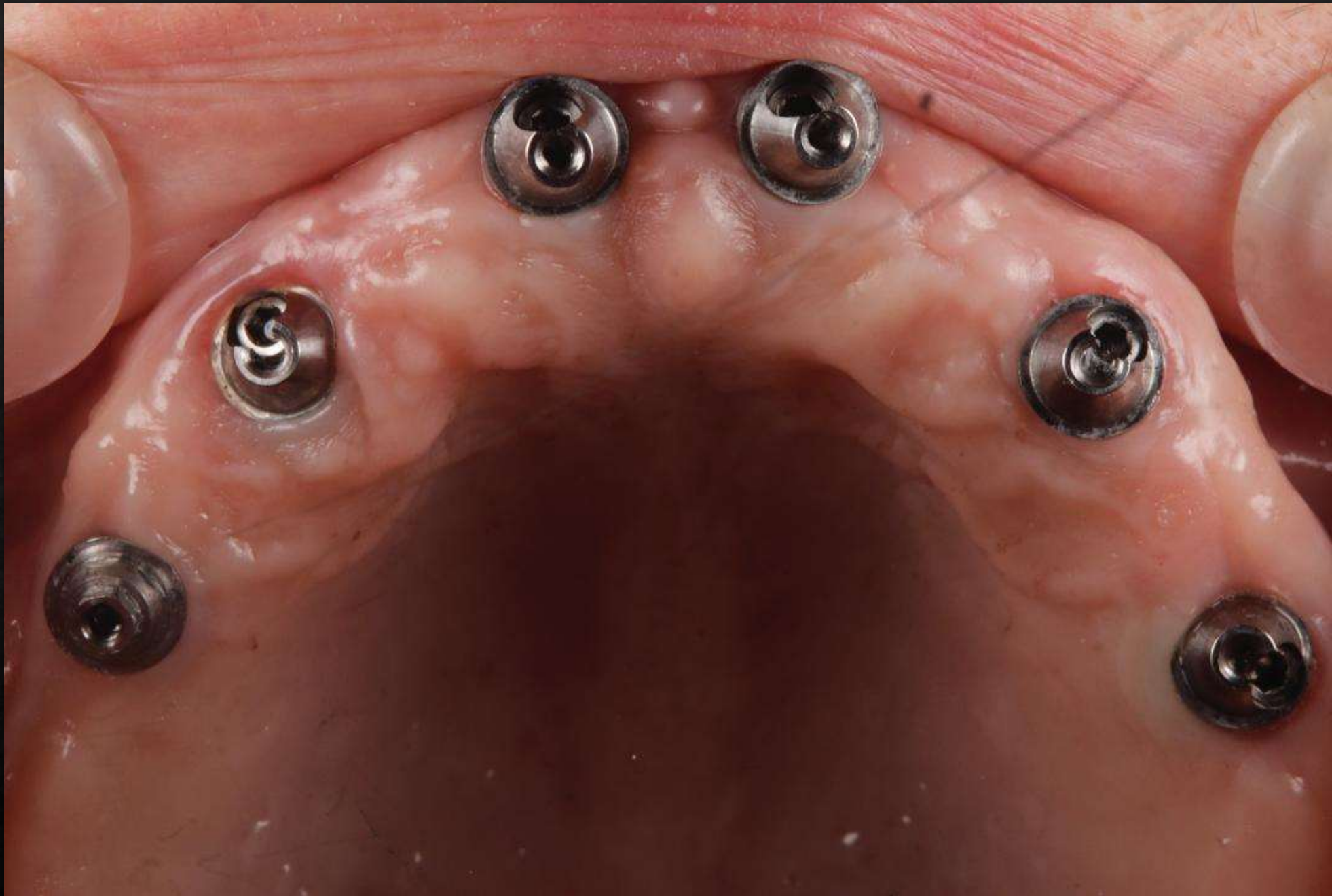- ◇ Patient 55 y.o
- ◇ Non smoker
- ◇ No general health condition
- ◇ Used to have a removable denture

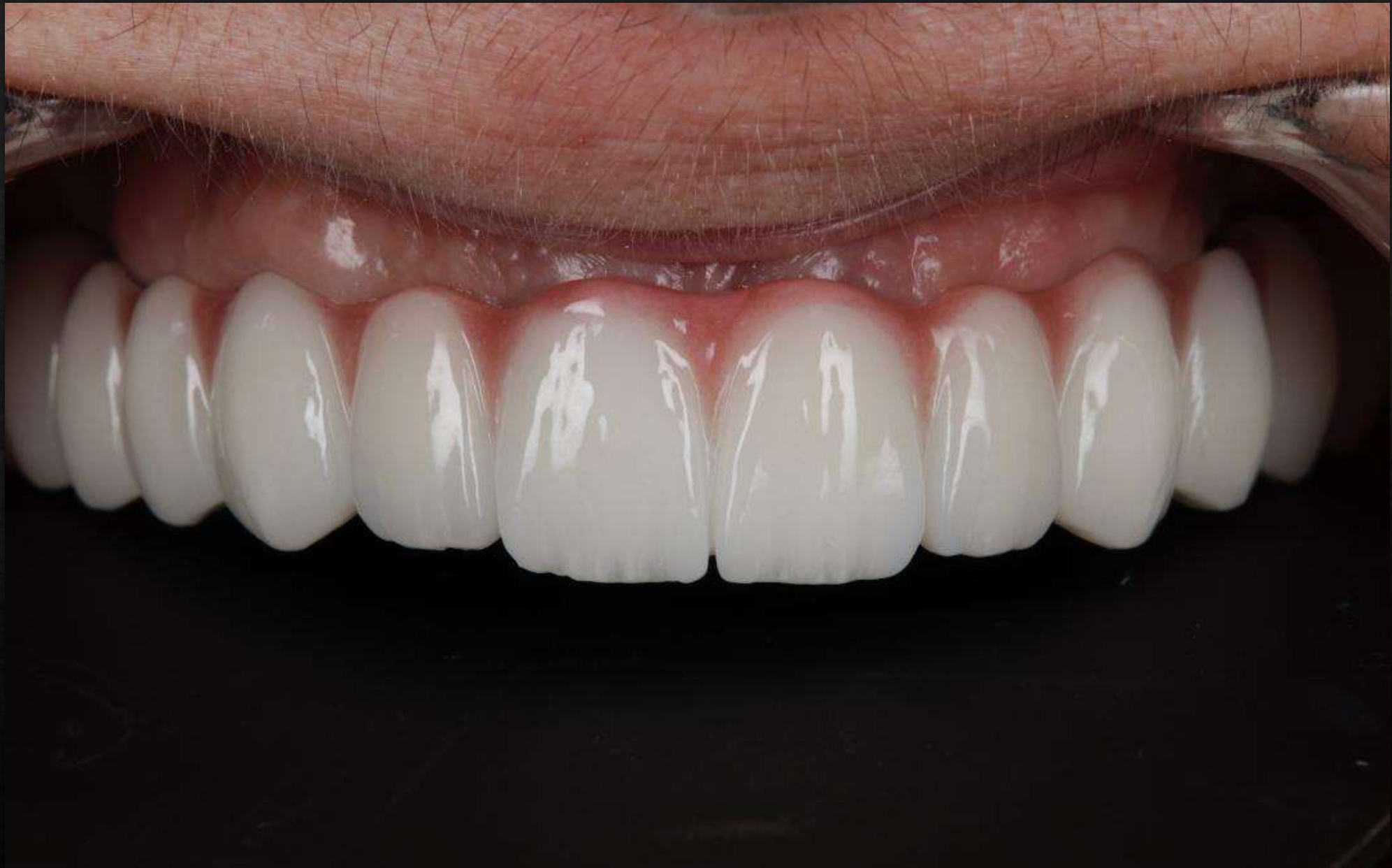Treatment plan

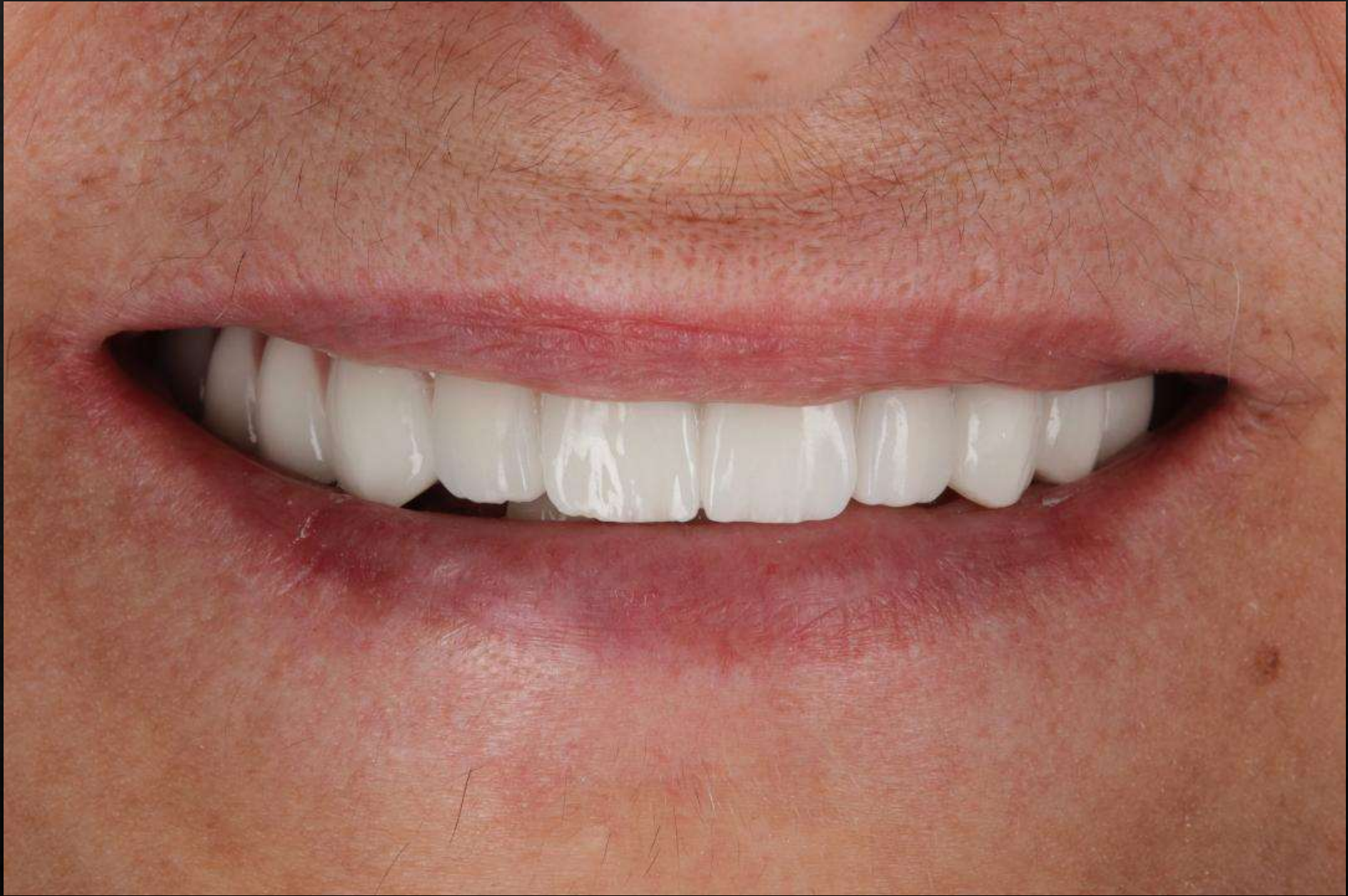- ◇ 6 implants
- ◇ Multiunits
- ◇ Zirconium crowns on titanium bar fixed on implants









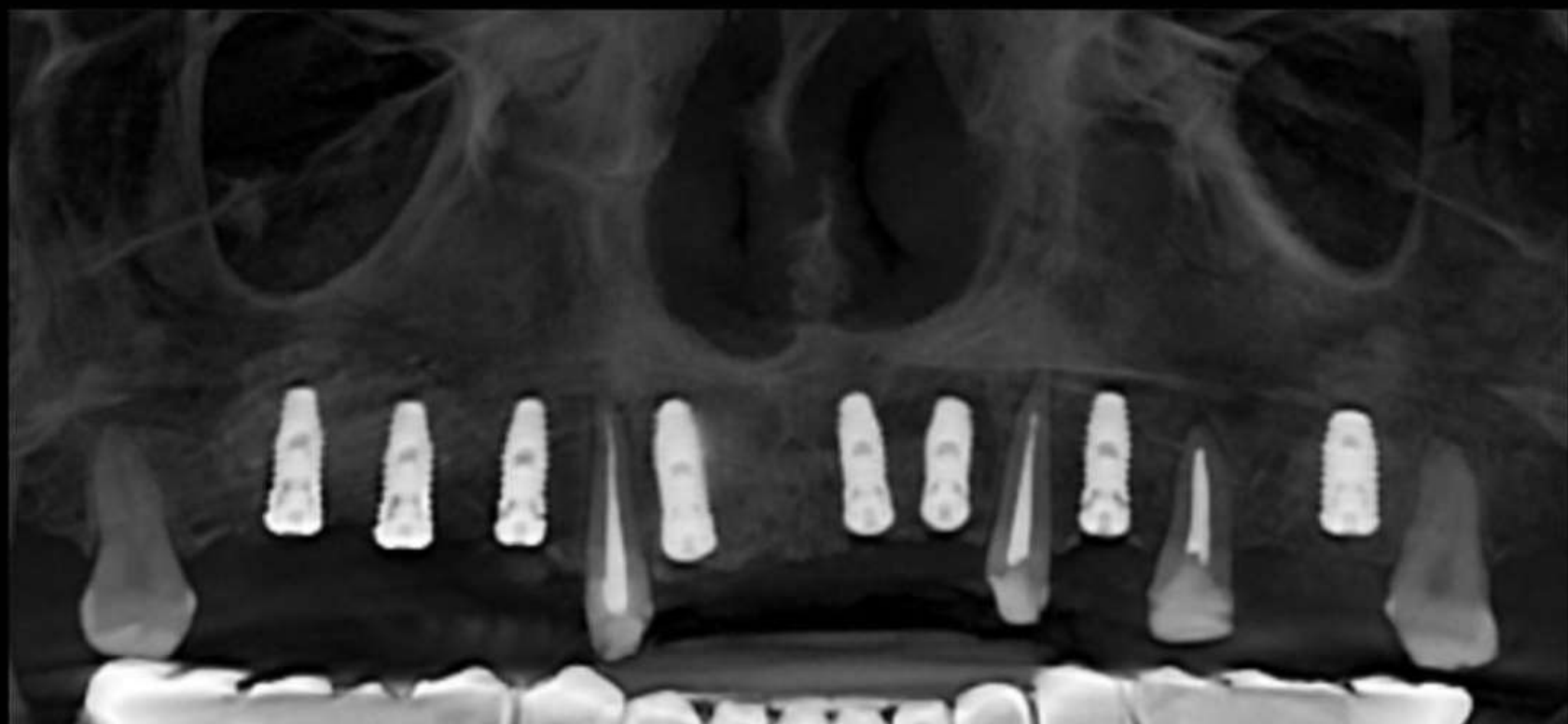
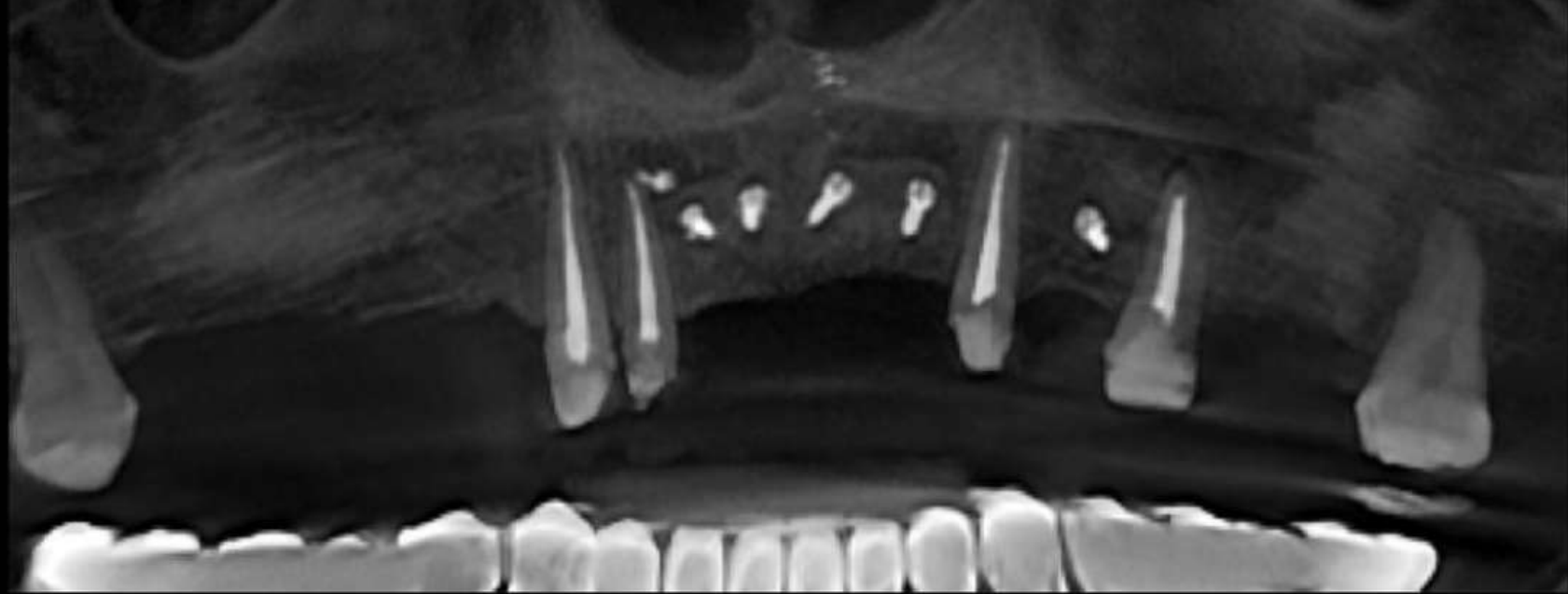
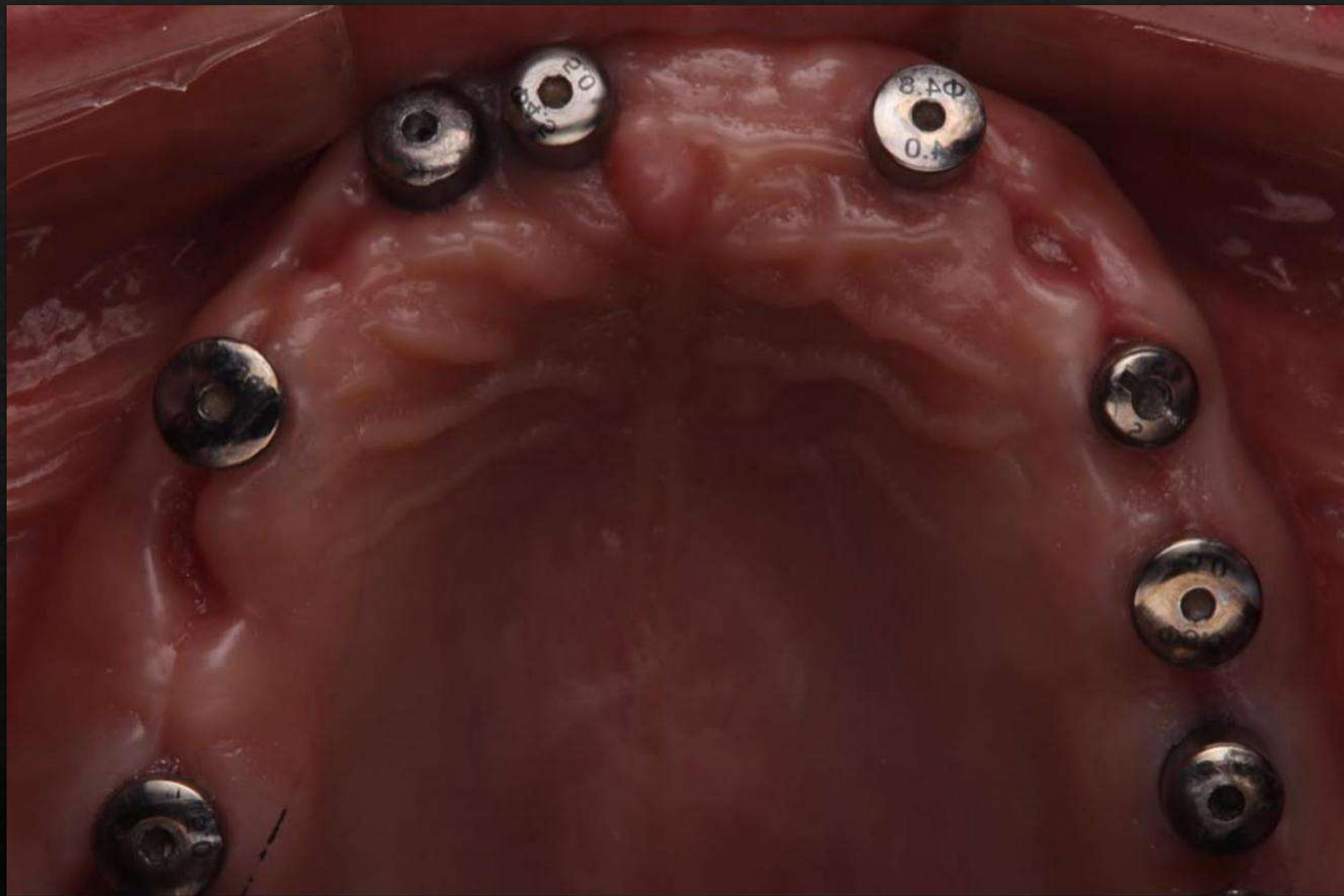
Case 3

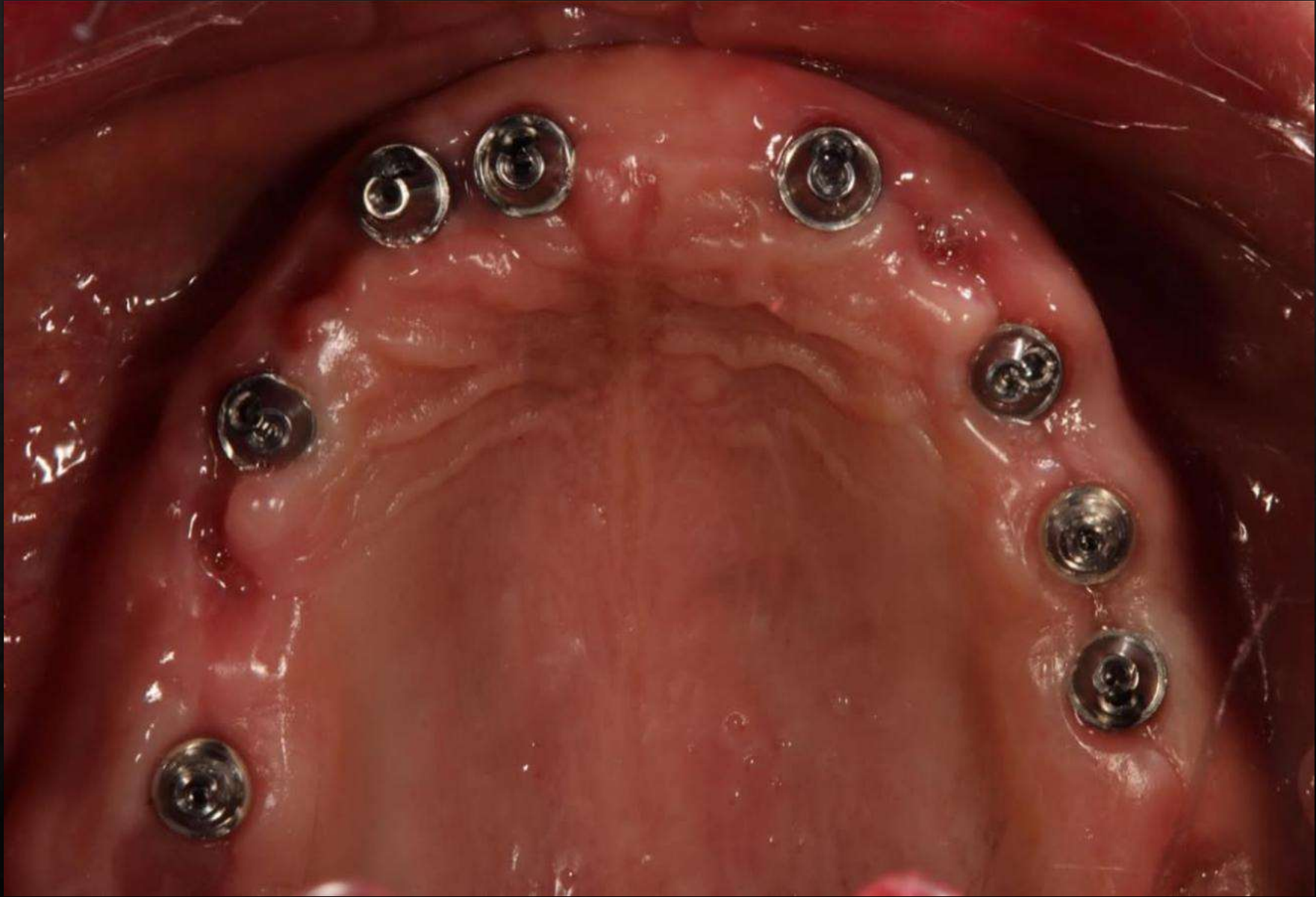
- ◇ Patient 25 y.o.
- ◇ Heavy smoker
- ◇ Female
- ◇ Failure of dental treatment in the past
- ◇ Esthetical and functional discomfort
- ◇ Partial adentia

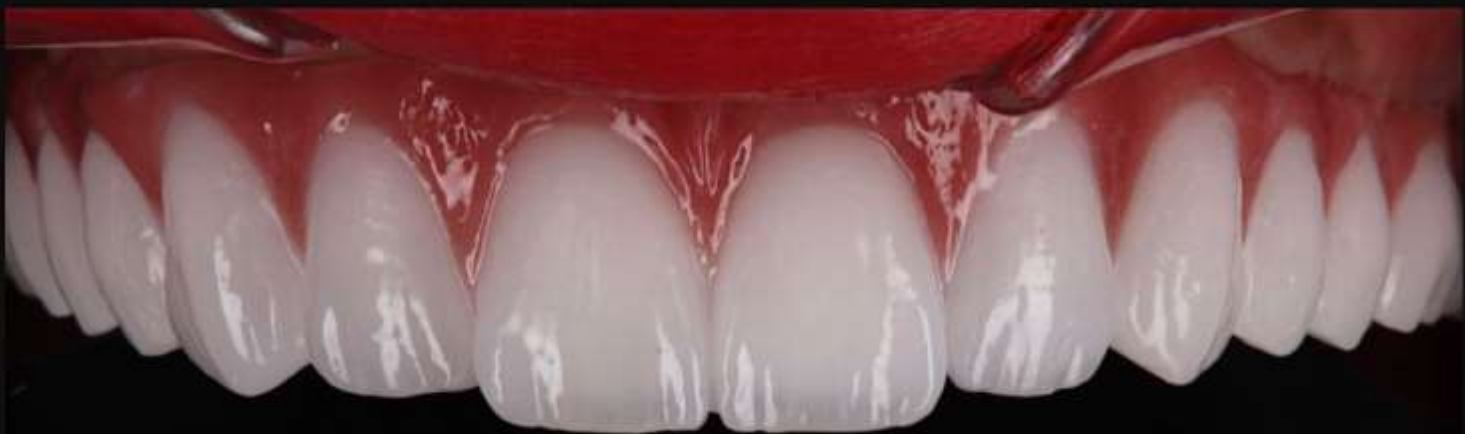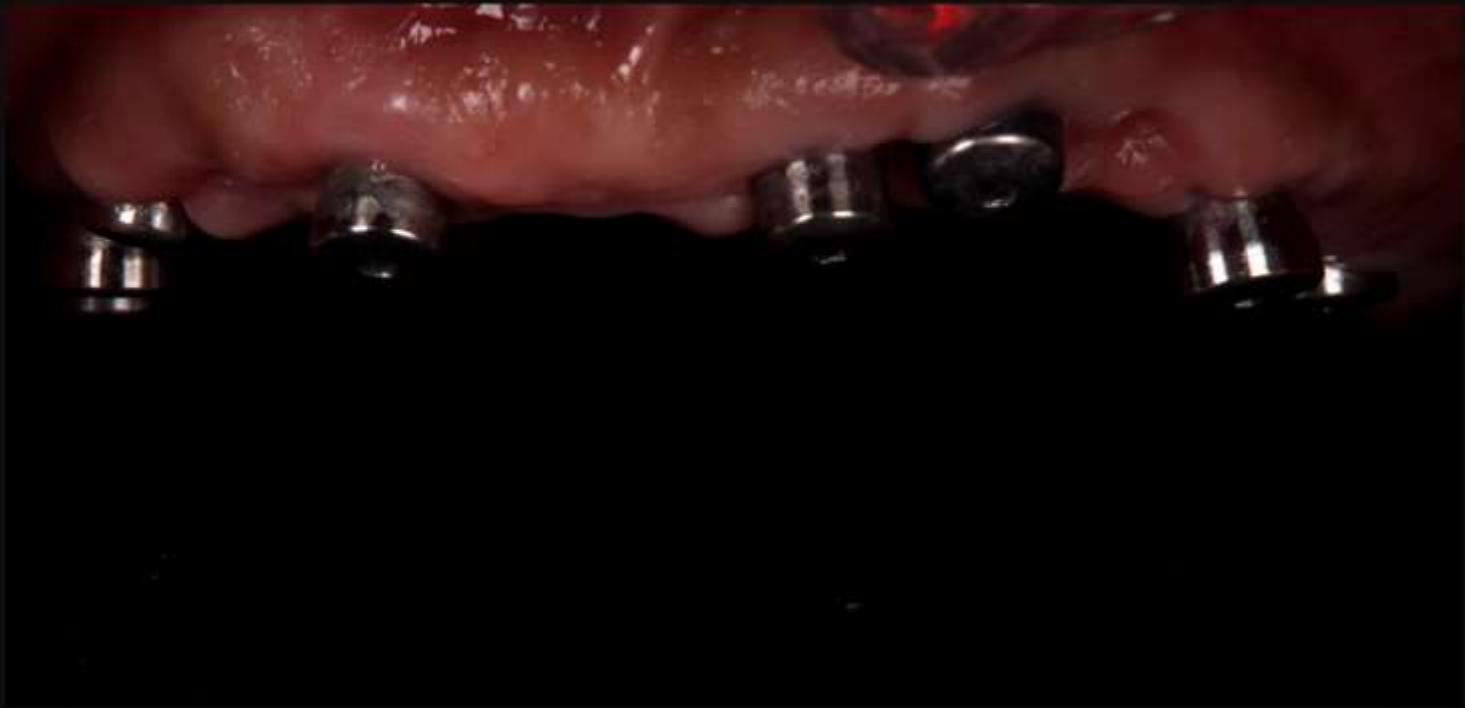Treatment plan

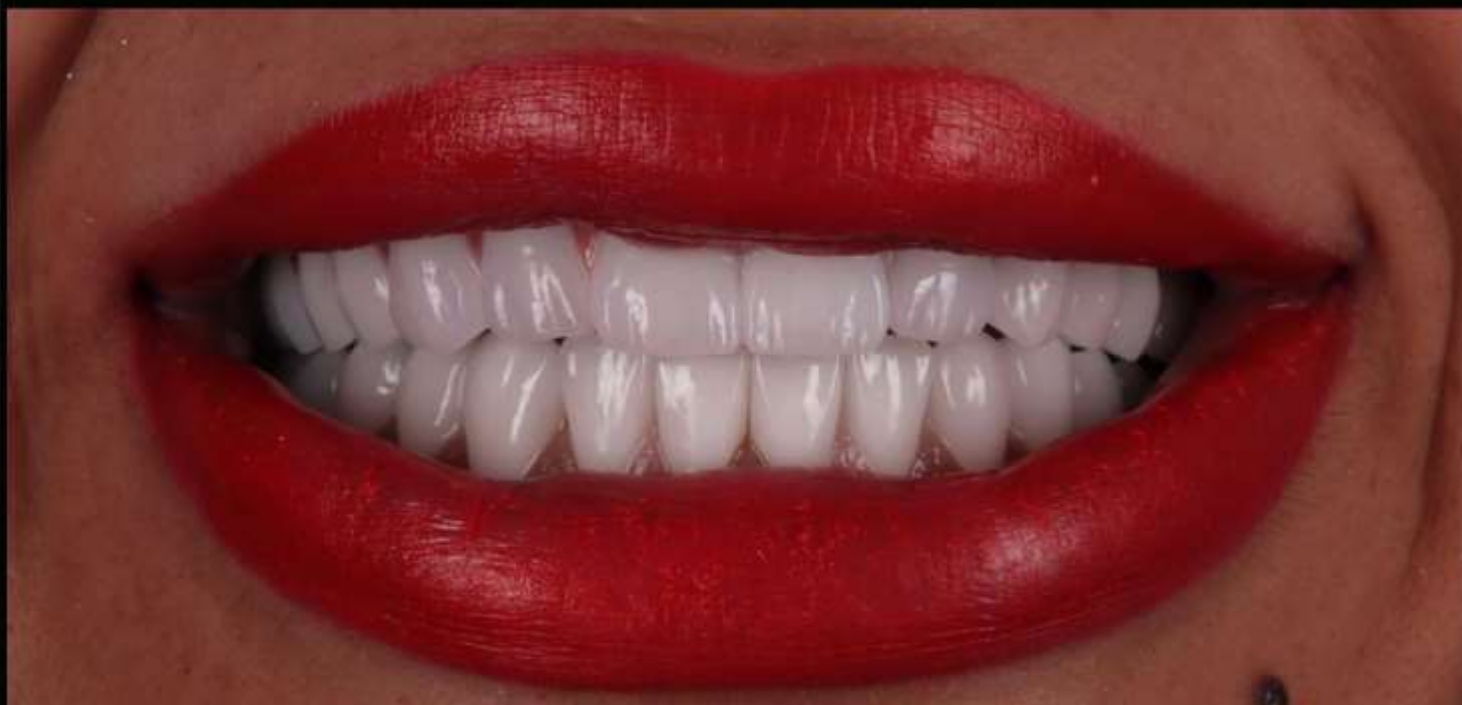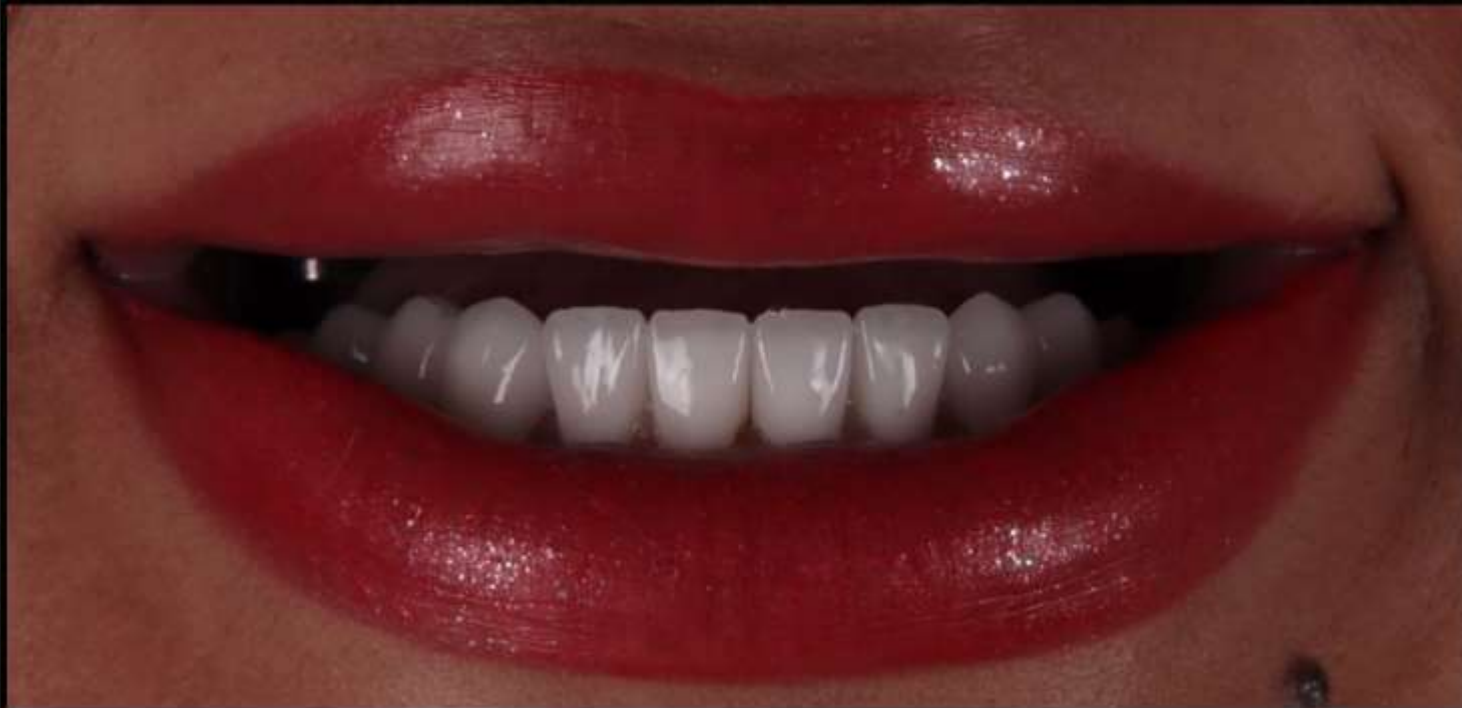- ◇ Bilateral sinus lifting
- ◇ GBR on maxilla
- ◇ Implantation
- ◇ Multi units
- ◇ Zirconium crowns on titanium bar fixed on implants

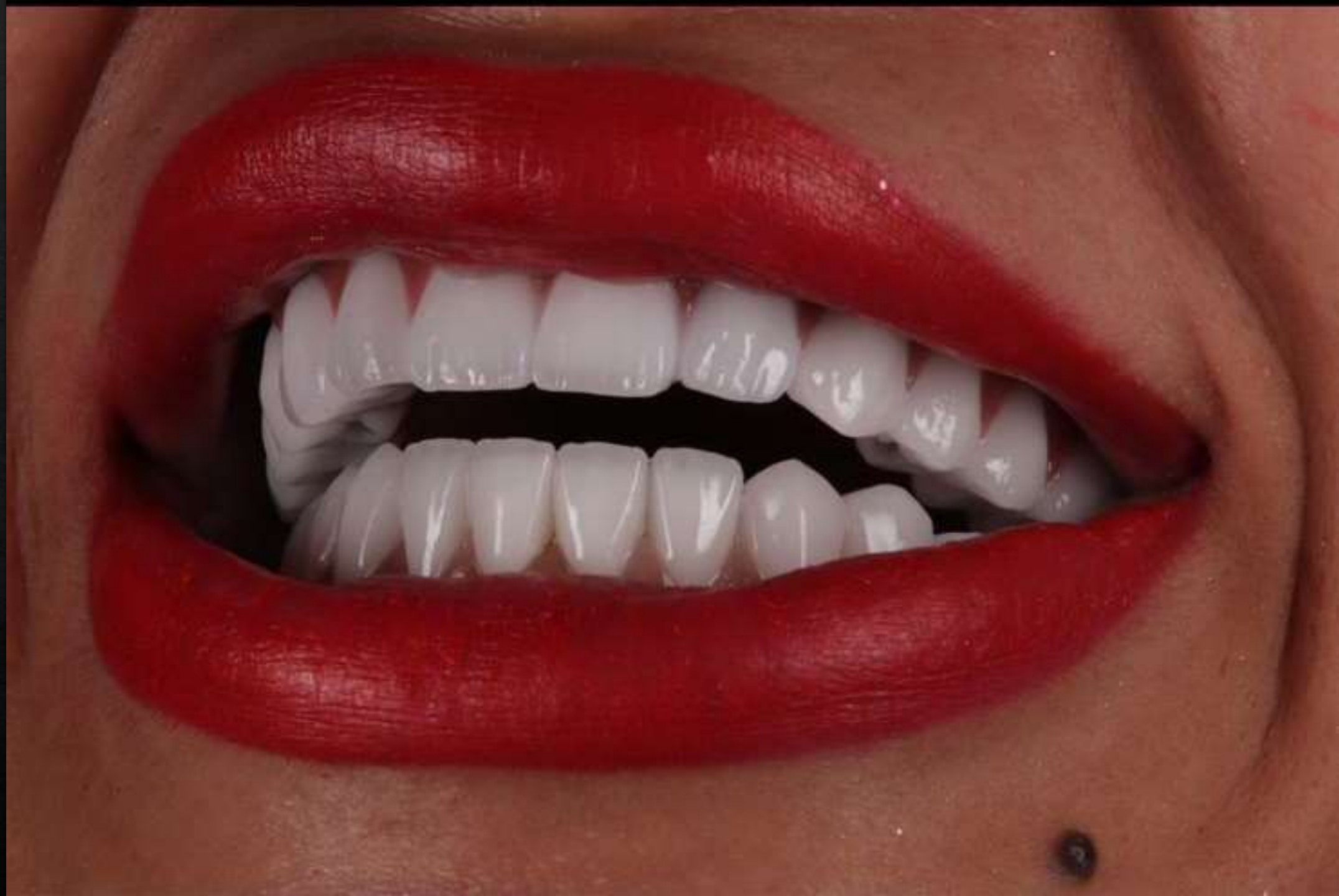


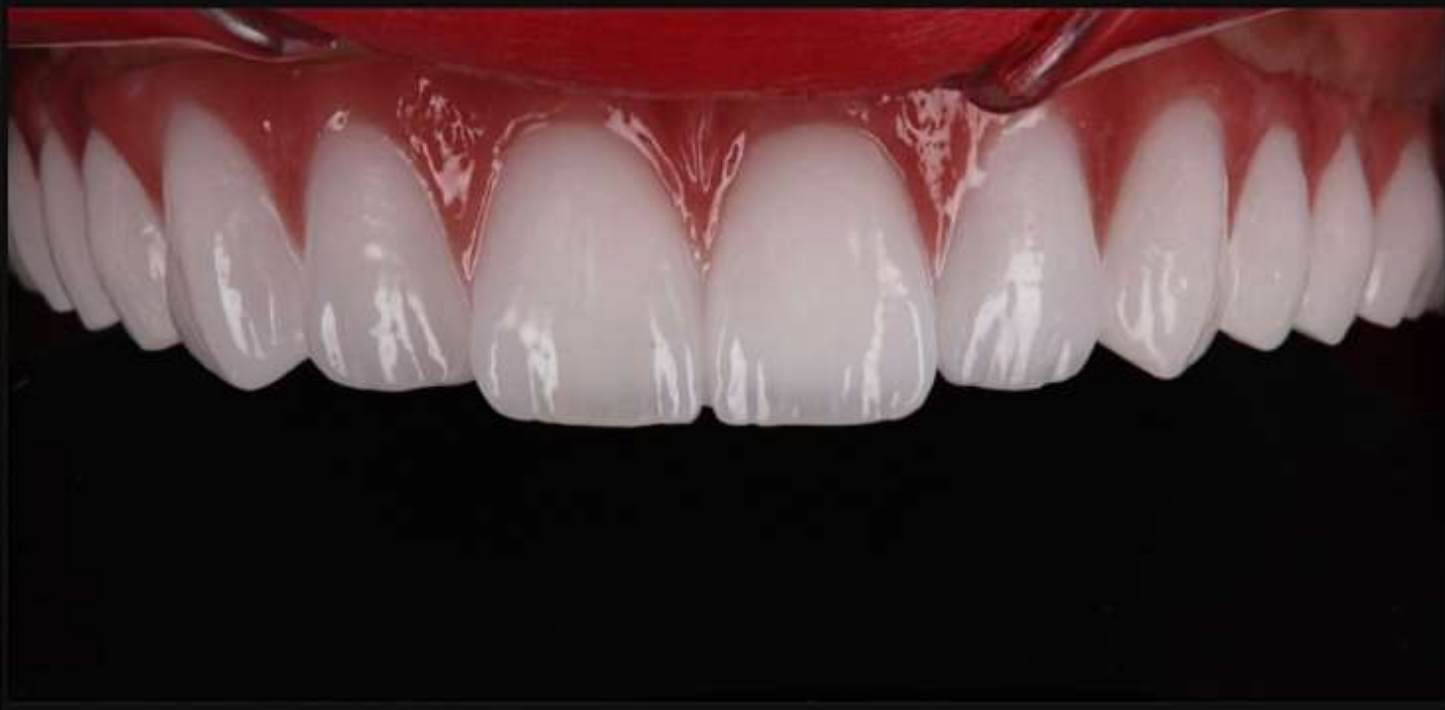
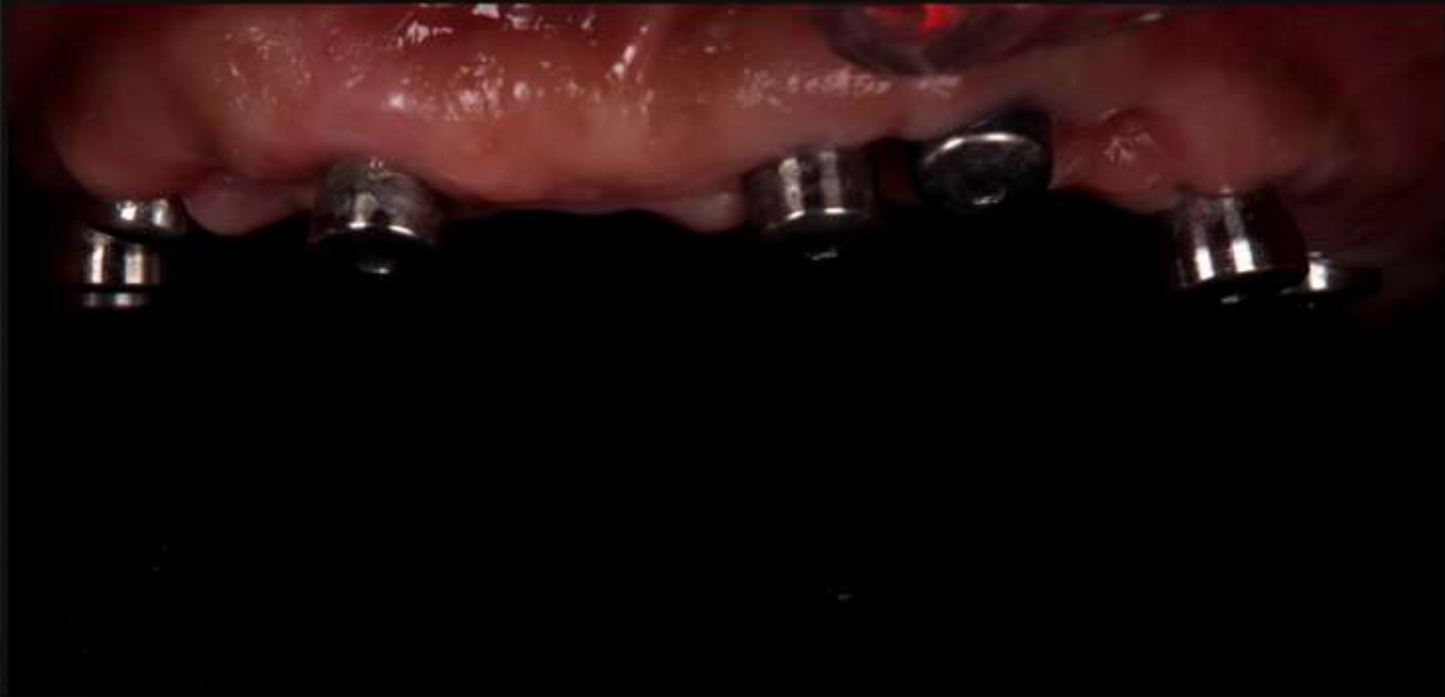







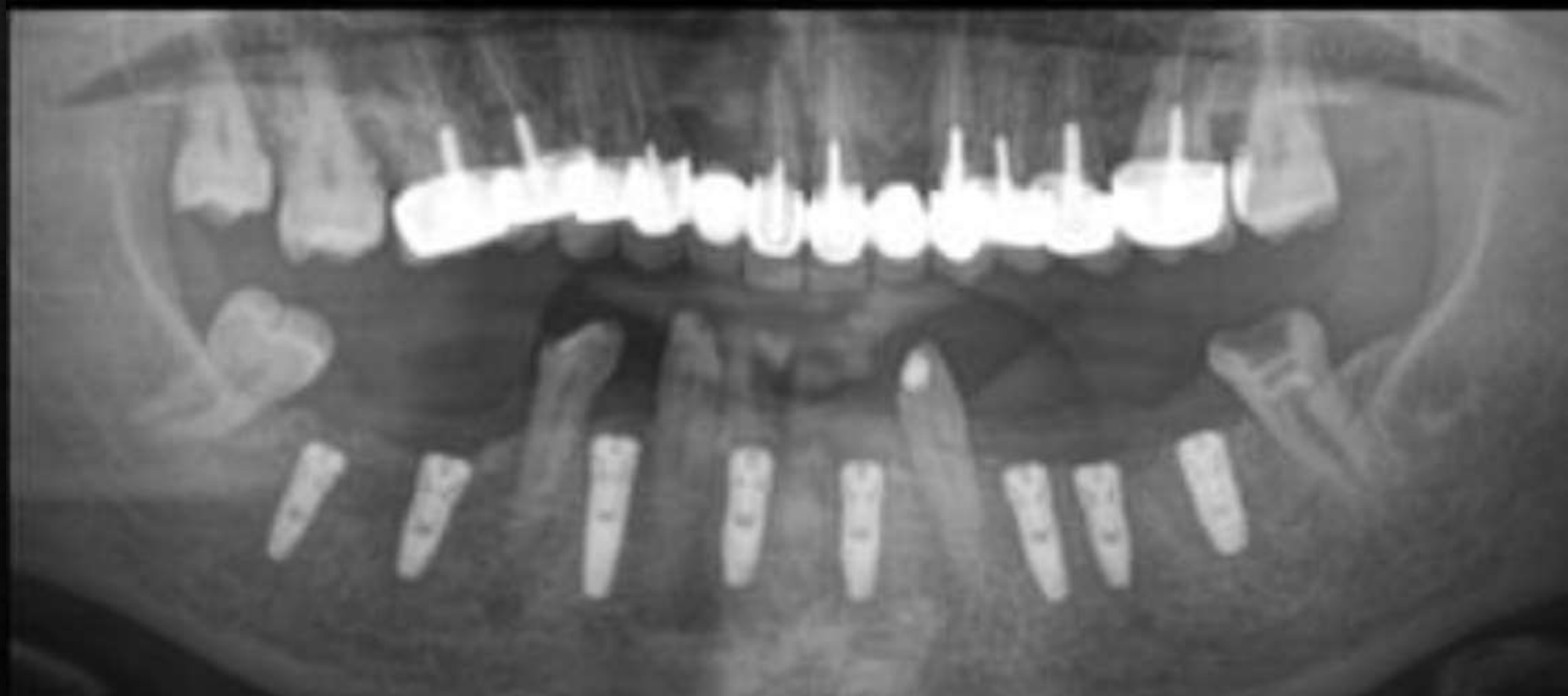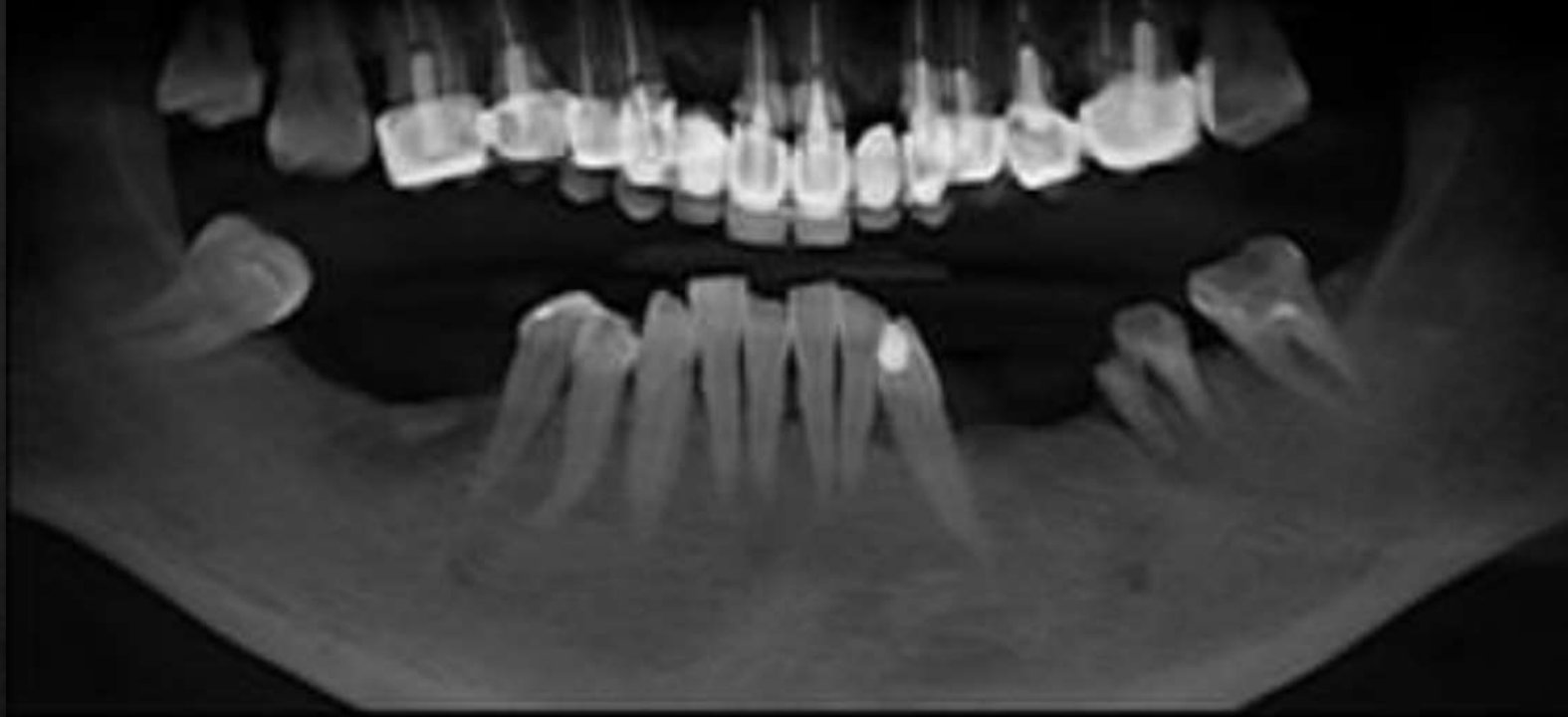


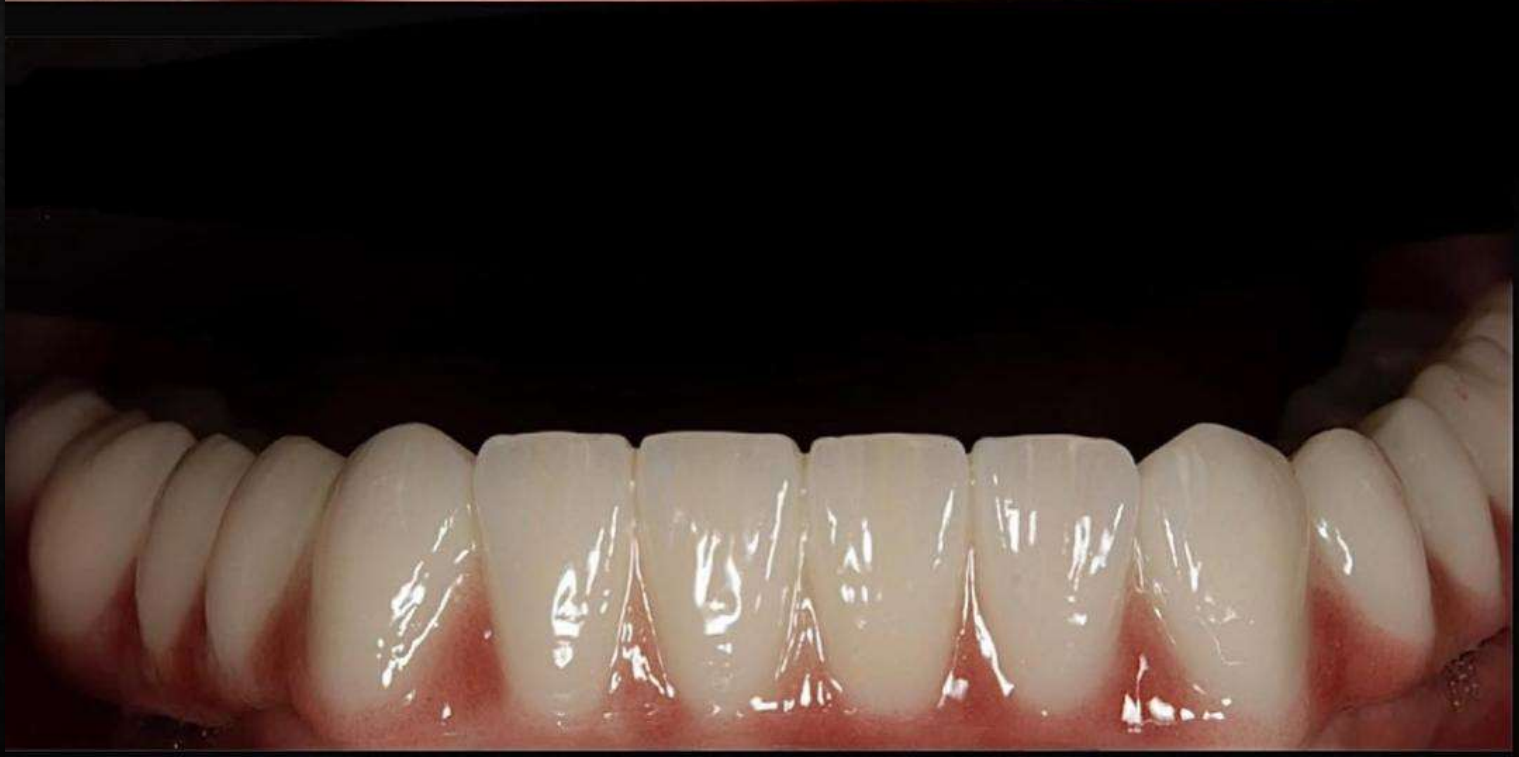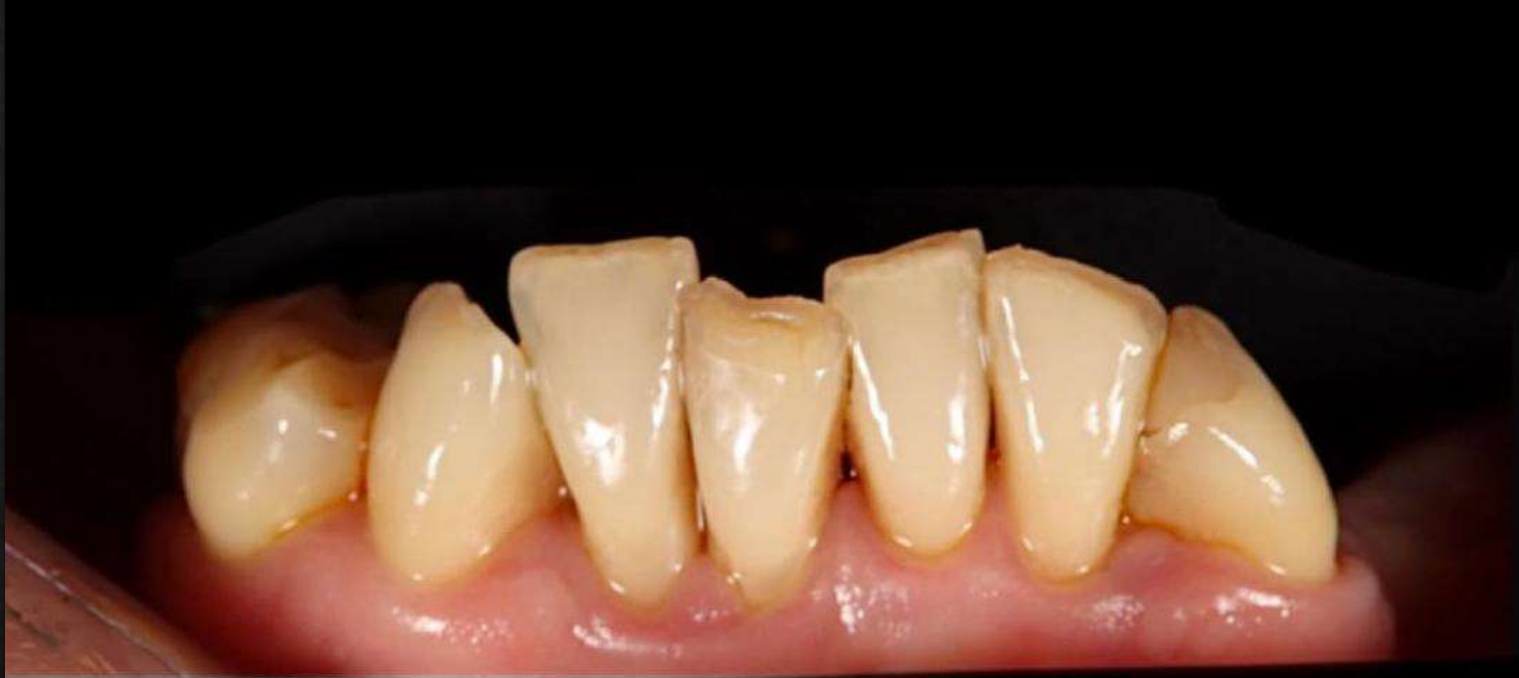Case 4

- ◇ Patient 53 y.o.
- ◇ Female
- ◇ Failure of dental treatment in the past
- ◇ Esthetical and functional discomfort
- ◇ Partial adentia

Treatment plan

- ◇ Implantation
- ◇ Multi units
- ◇ Zirconium crowns on titanium bar fixed on implants



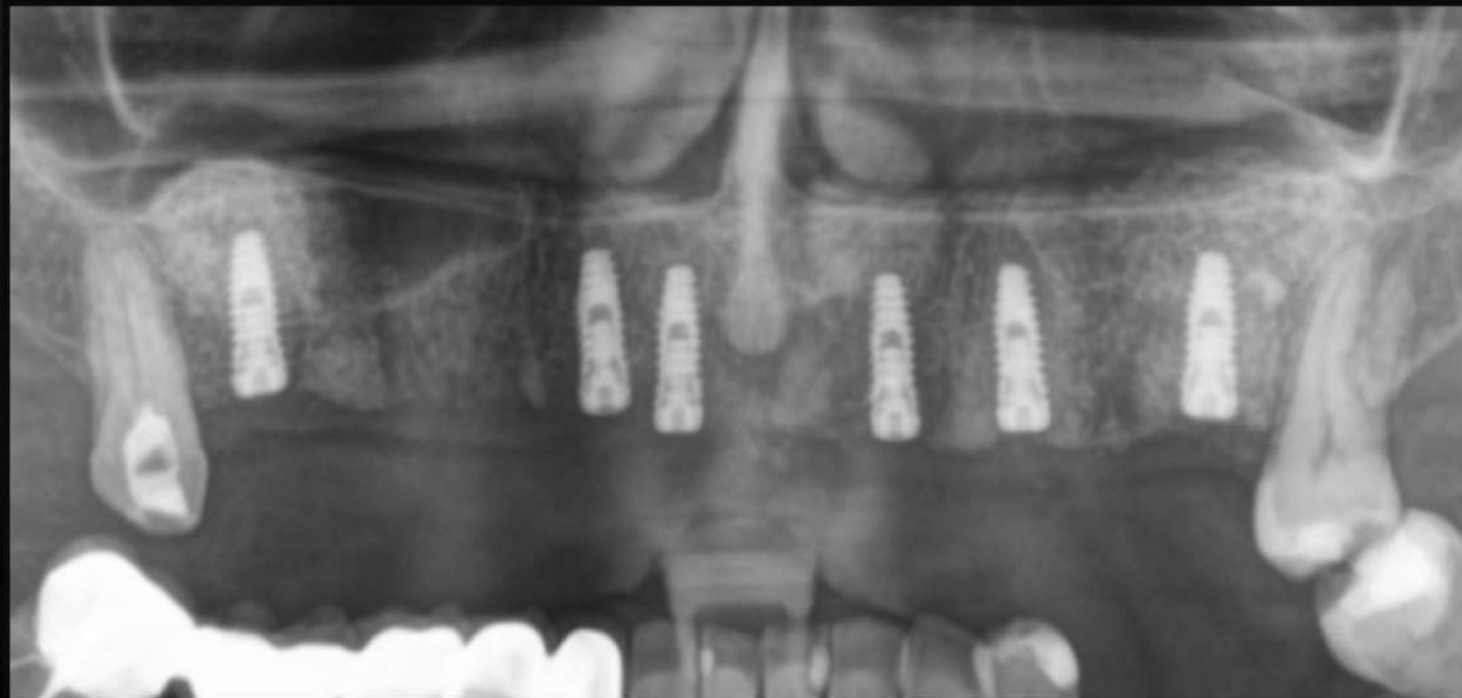
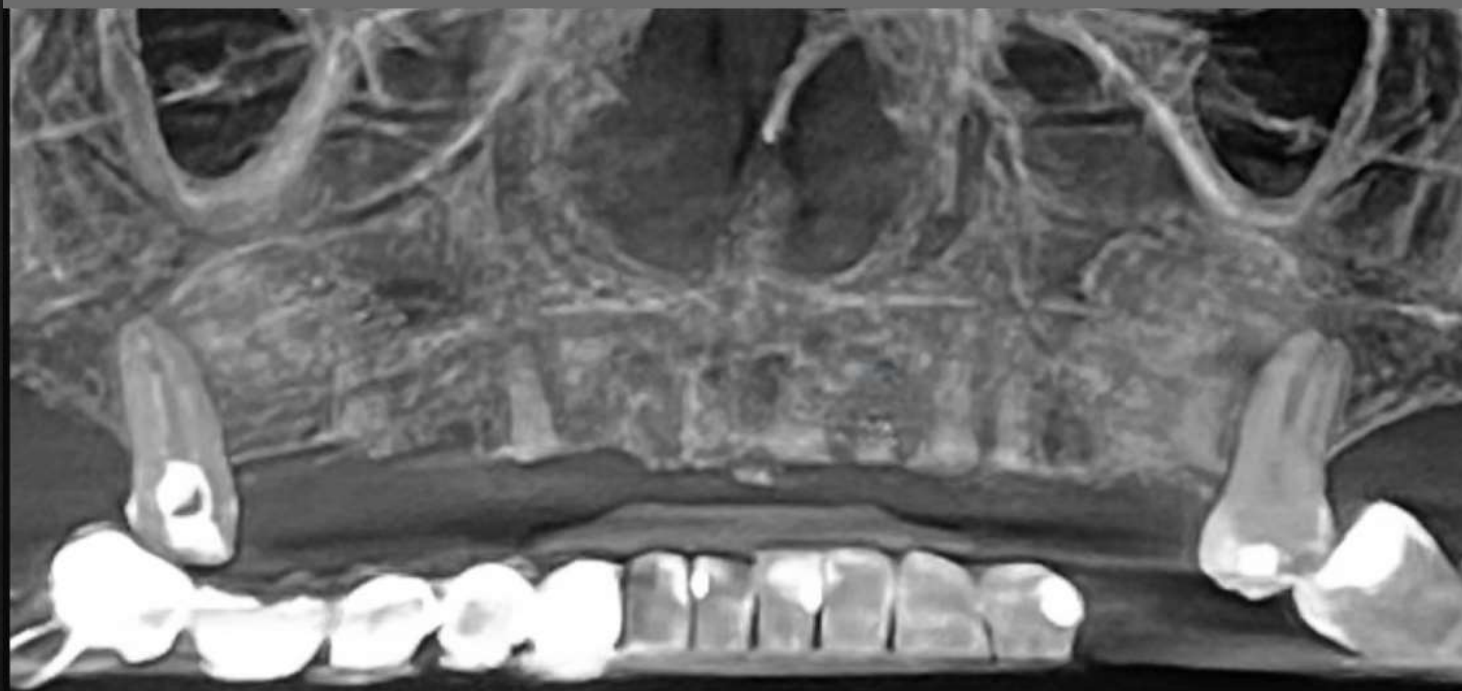
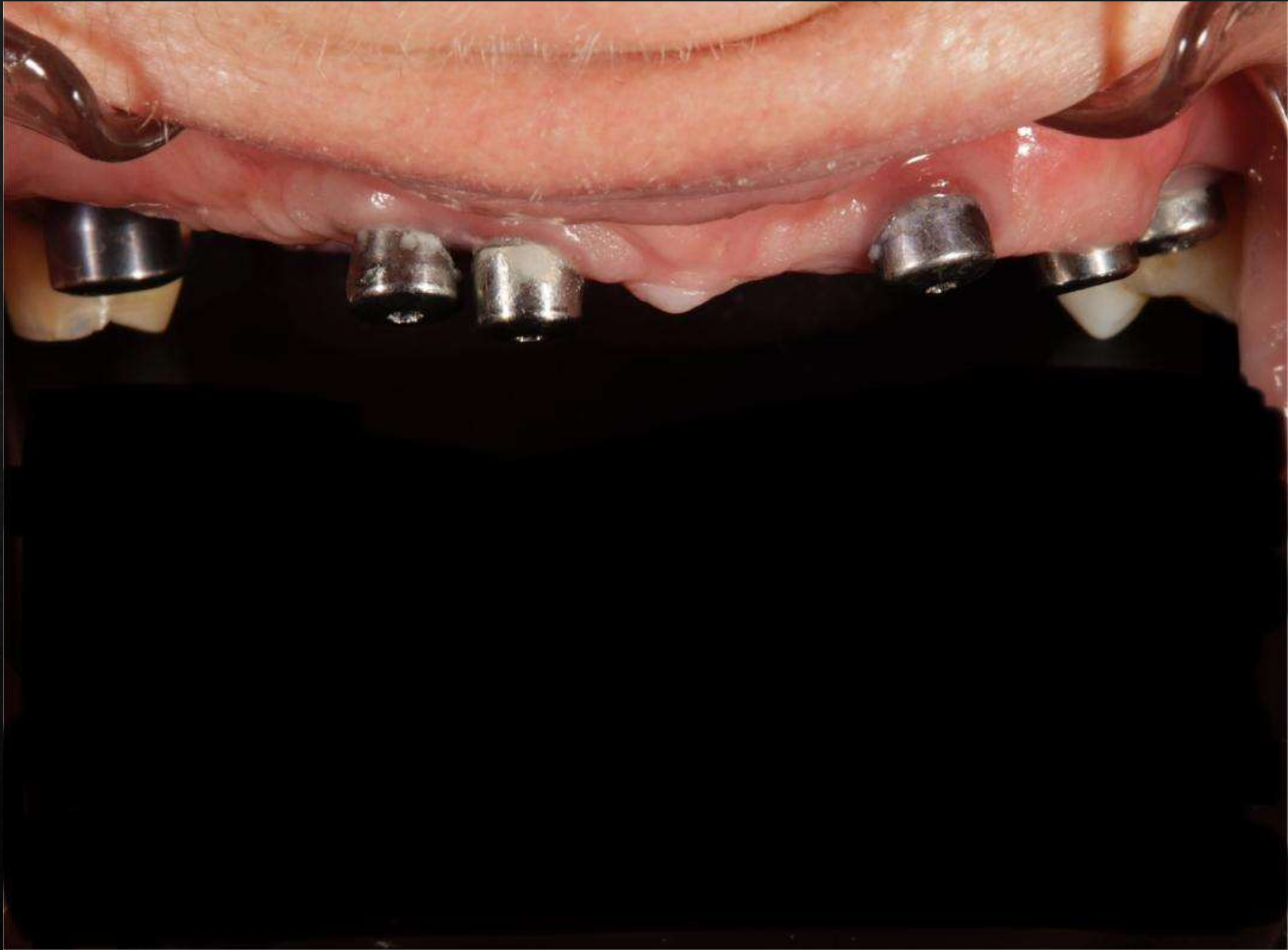Case 4

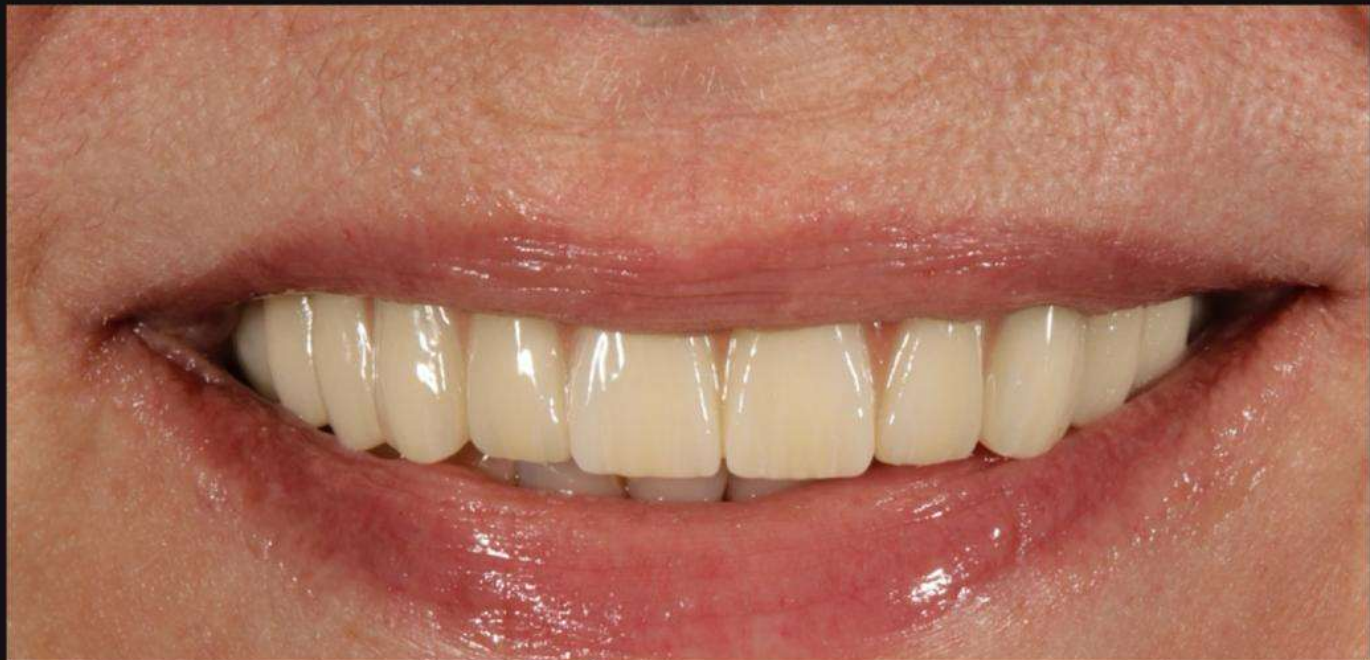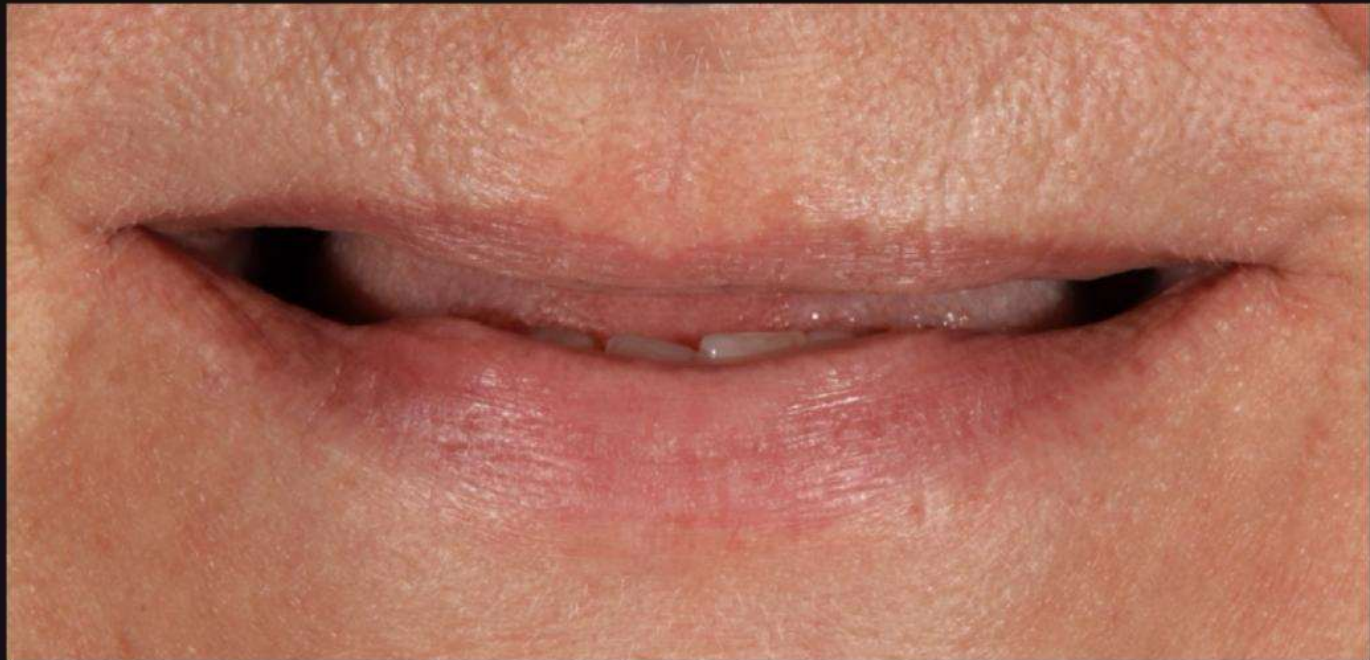- ◇ Patient 65 y.o.
- ◇ Female
- ◇ Failure of dental treatment in the past
- ◇ Esthetical and functional discomfort
- ◇ Partial adentia

Treatment plan

- ◇ Implantation
- ◇ Multi units
- ◇ Zirconium crowns on titanium bar fixed on implants

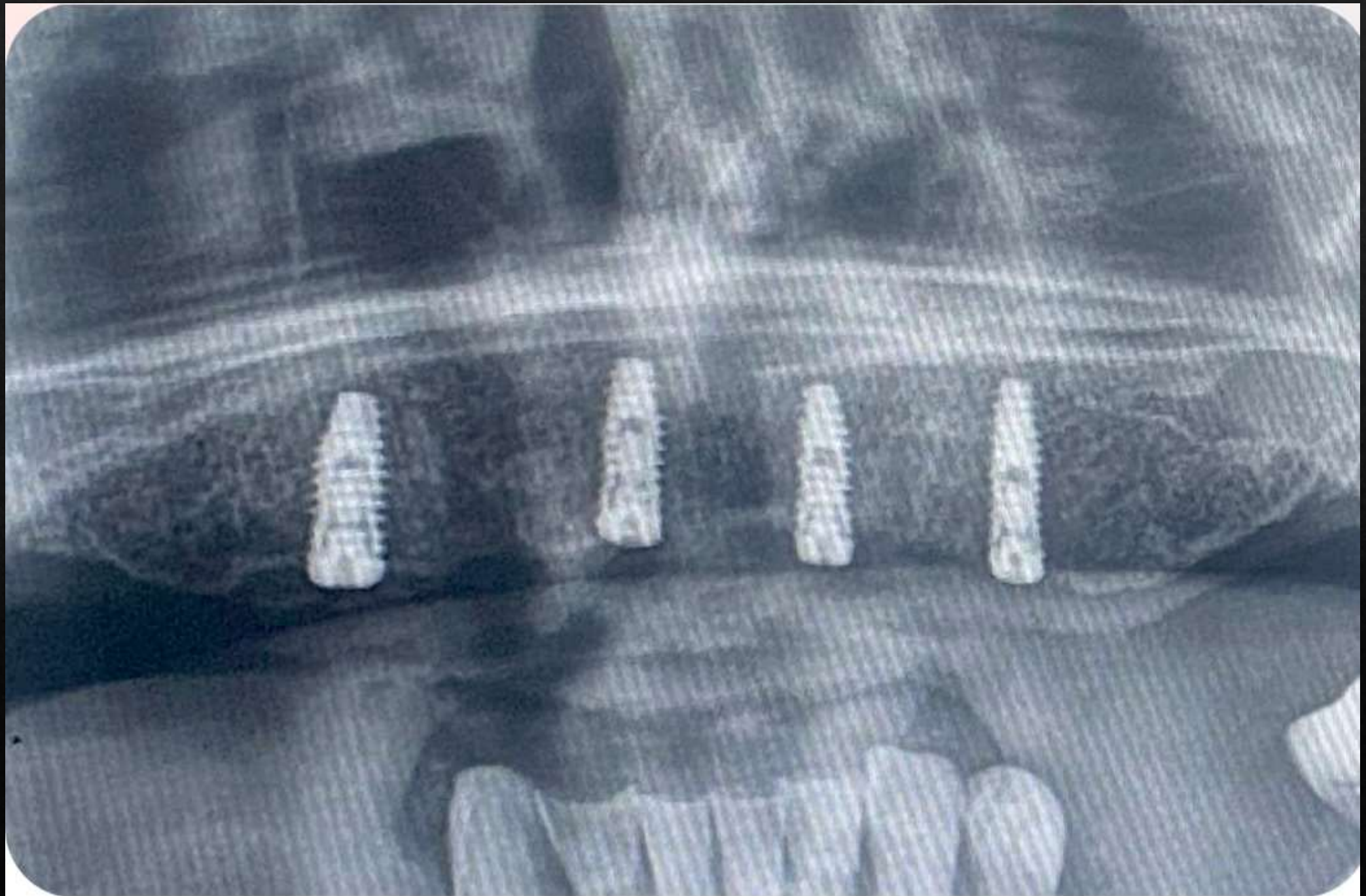


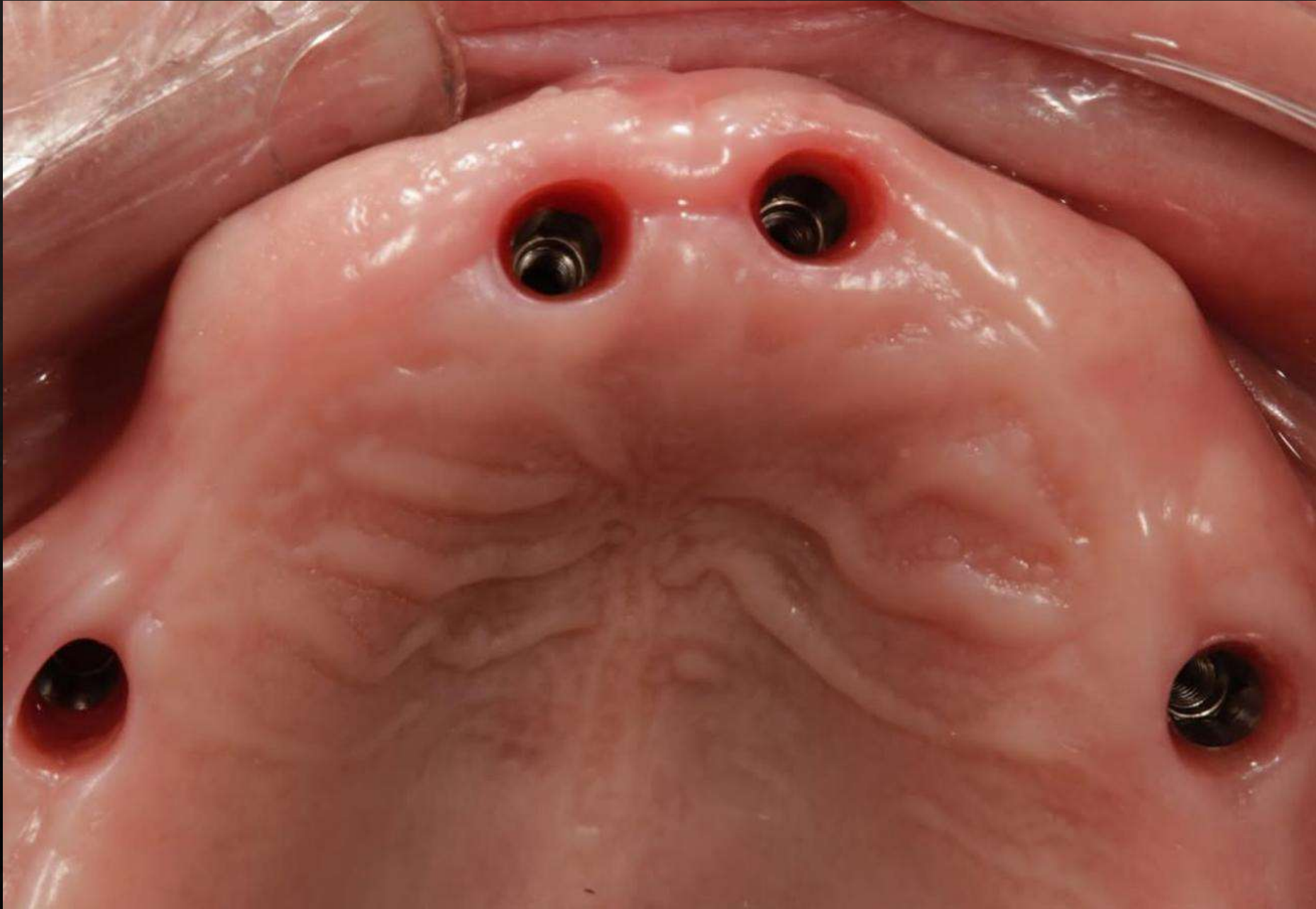


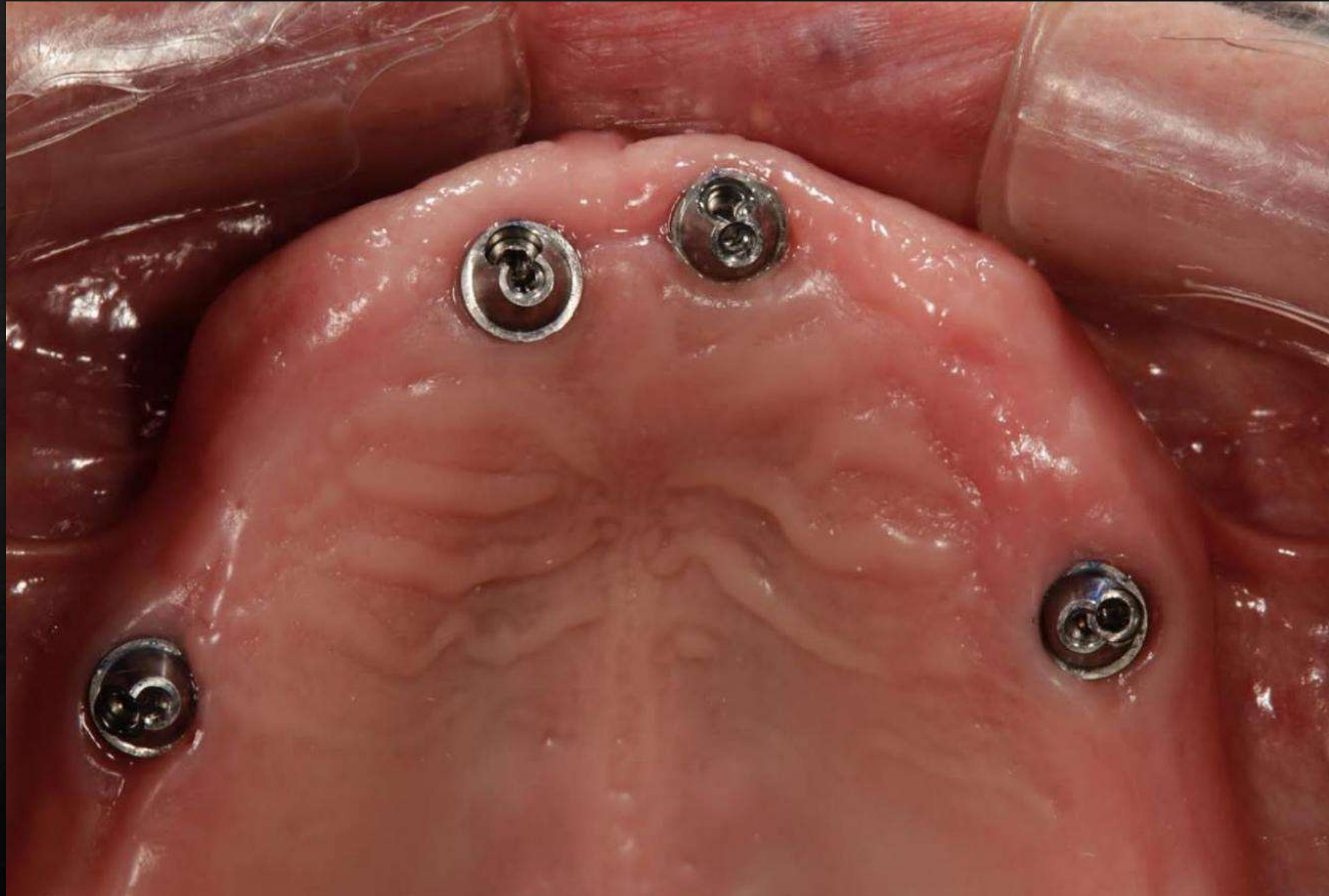

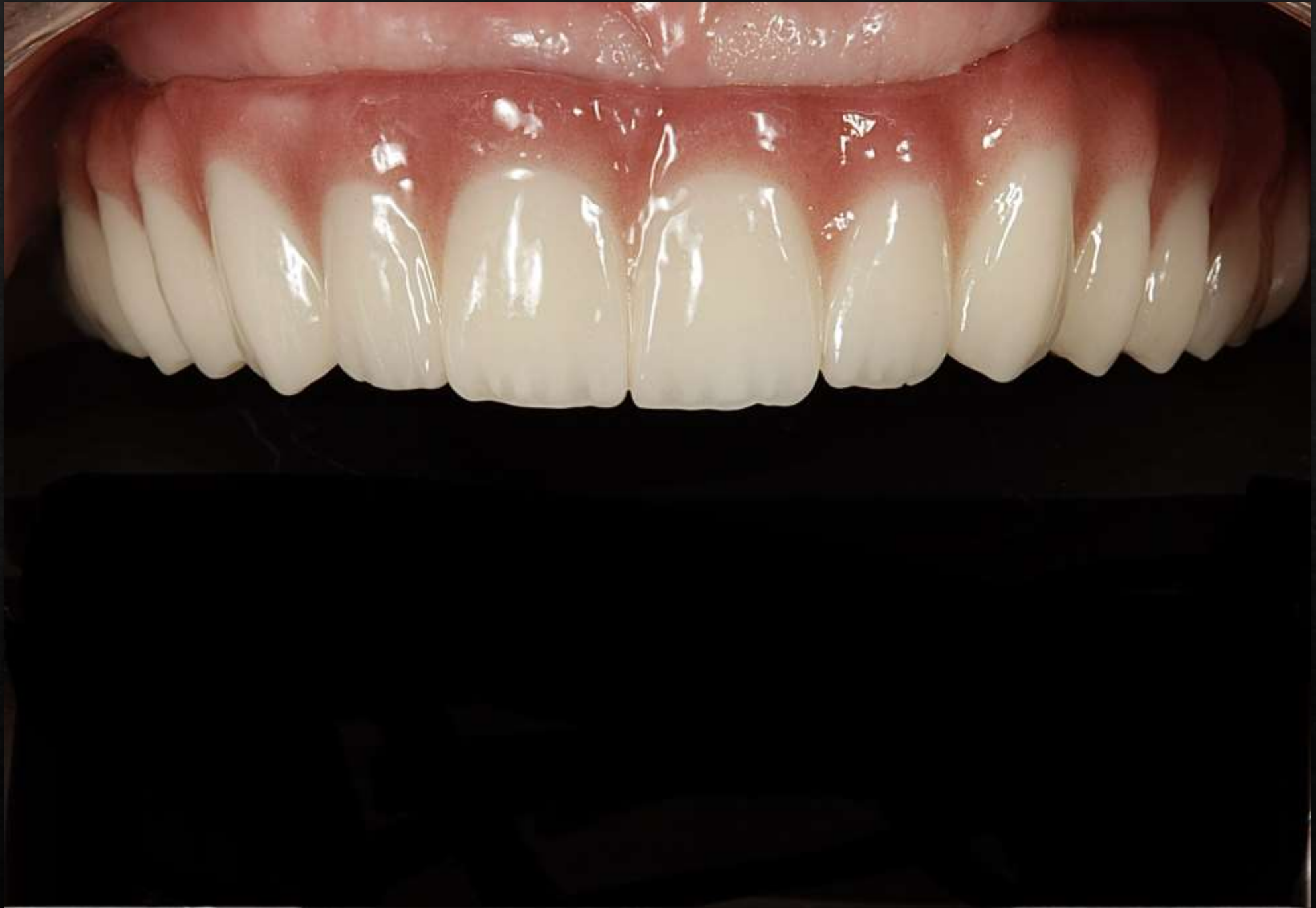Case 5

- ◇ Patient 70 y.o
- ◇ Female
- ◇ Non smoker
- ◇ No general health condition
- ◇ Esthetical and functional problems on upper jaw
- ◇ TREATMENT PLAN:
- ◇ Patient refused to have a bilateral sinus lifting
- ◇ 4 Implants on maxilla
- ◇ Removable denture on implants



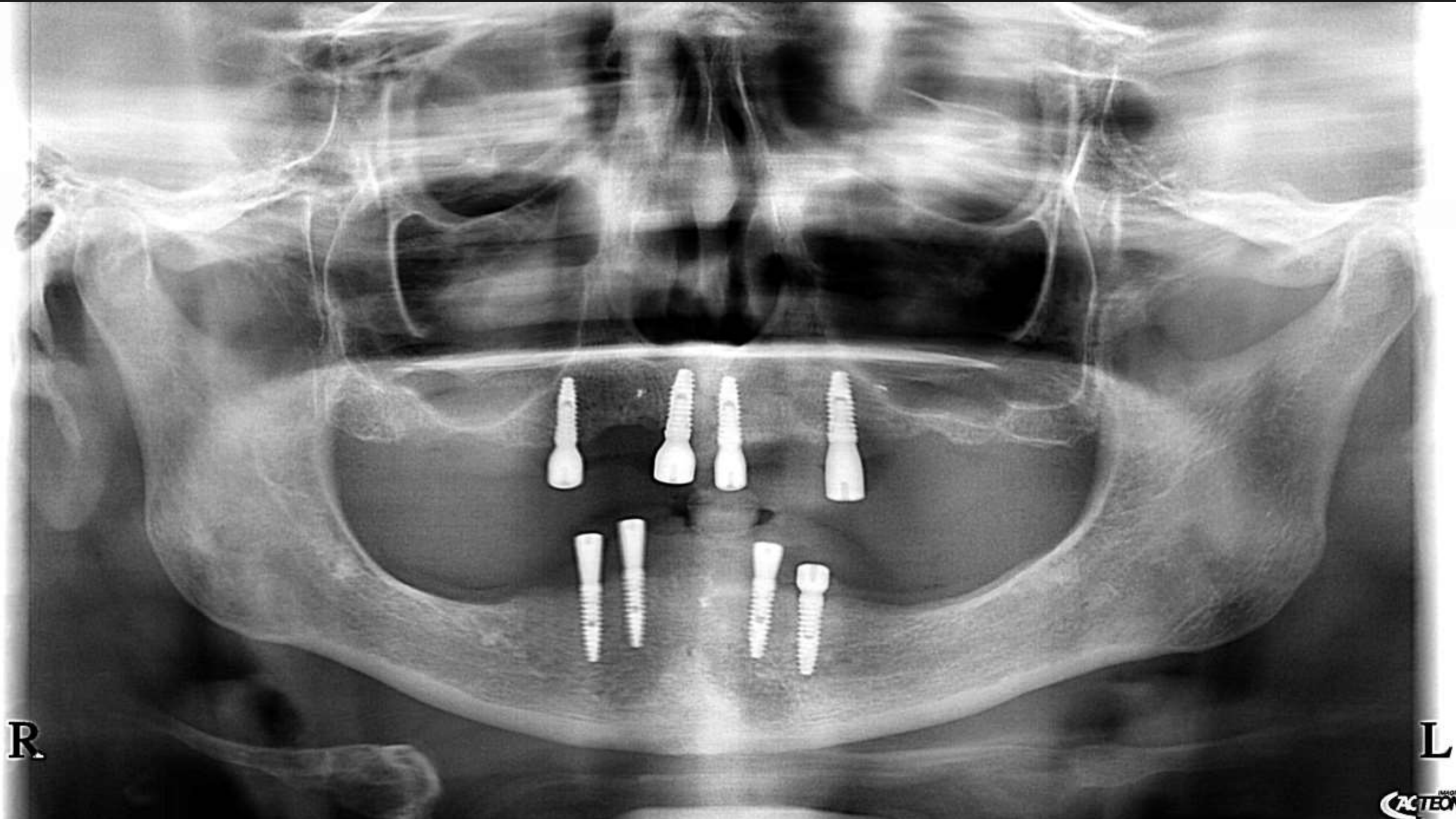






Case 6

- ◇ Patient 68 y.o
- ◇ Female
- ◇ Non smoker
- ◇ No general health condition
- ◇ Esthetical and functional problems on upper jaw
- ◇ TREATMENT PLAN:
- ◇ Patient refused to have a bilateral sinus lifting
- ◇ 4 Implants on maxilla
- ◇ Removable denture on implants



R

L

R

L



