

# VILEX Reconstruction & Arthrodesis

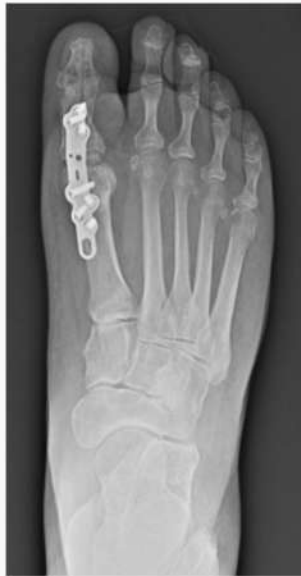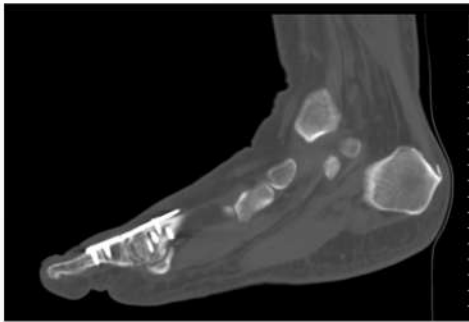
## ALPHALOK™ RECON

CASE STUDY



### Patient History

- 60 YO M, HX OA
- S/P two failed 1st MTPJ AD by another providers.
- Vitamin D Deficiency
- CT Showed Non-Union



### Surgical Plan

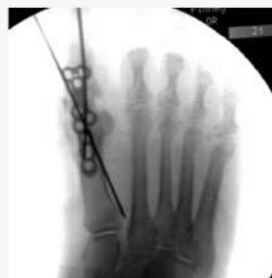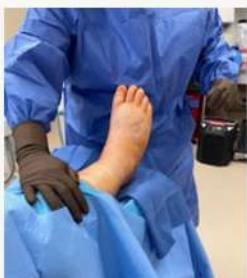Discussed Staged Surgery

#### Stage 1

- Hardware removal, bone biopsy to rule out infection.
  - *Infection labs wnl. Biopsy negative.*

#### Stage 2

- Revisional 1st MTPJ fusion with calcaneal autograft, cortical bone graft wedge.
  - ALPHALOK Recon Revisional MTPJ Plate, 3.5mm screws (locking x7, non-locking x1), 1.2mm k-wire, 2cc bio, 12mm allopure wedge.



Dr. Sofie Pinney  
DPM, FACFAS

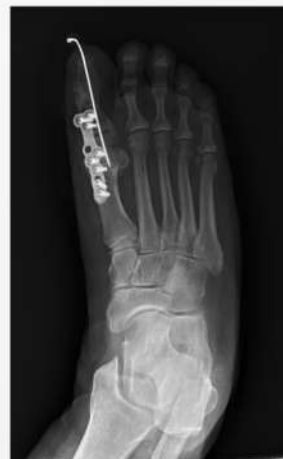Cynthiana, KY

Dr. Sofie Pinney, DPM, FACFAS, is a paid consultant for Vilex, LLC. Vilex provided financial support for this case study.

These results are specific to this individual only. Individual results and activity levels after surgery vary and depend on many factors including age, weight, and prior activity levels. There are risks and recovery times associated with surgery, and there are certain individuals who should not undergo surgery.

This case study is a publication of Vilex, LLC.

### Post-Op



### 4-Month Post-Op

