



THE CARDIOVASCULAR CENTER
OF FLORIDA

2025 Cardiovascular
Center Of Florida
Annual
Symposium

Contemporary Options for Less Invasive Cardiac Surgery

Steven J. Hoff, MD, FACS, FACC, FHRS

November 1, 2025

Consultant/Peer trainer-Atricure
Consultant/Peer trainer-Medtronic

Objectives

- Discuss Minimally Invasive Options for the Treatment of:
 - Coronary Artery Disease
 - Valve Disease
 - Arrhythmias
- Discuss Emerging Technologies
- Discuss Clinical Trials

Surgery for Coronary Artery Disease

OPCAB

MIDCAB

Multivessel MICS CAB

Hybrid Coronary Revascularization

Robotic-assisted MIDCAB

Surgery for Valve Disease

Minimally Invasive/Robotic Mitral Valve Repair/Replacement

Minimally Invasive Aortic Valve Replacement

Surgery for Arrhythmia

Atrial fibrillation ablation

Thoracoscopic epicardial ablation

Subxiphoid epicardial ablation-convergent procedure

Left atrial appendage ligation-Atriclip

Inappropriate sinus tachycardia (IST) ablation

Ventricular tachycardia (VT) ablation

Laser-assisted lead extraction/Complex lead management

Structural Heart Surgery

- OPCAB
- MIDCAB
- Multivessel MICS CAB
- Hybrid Coronary Revascularization
- Robotic-assisted MIDCAB

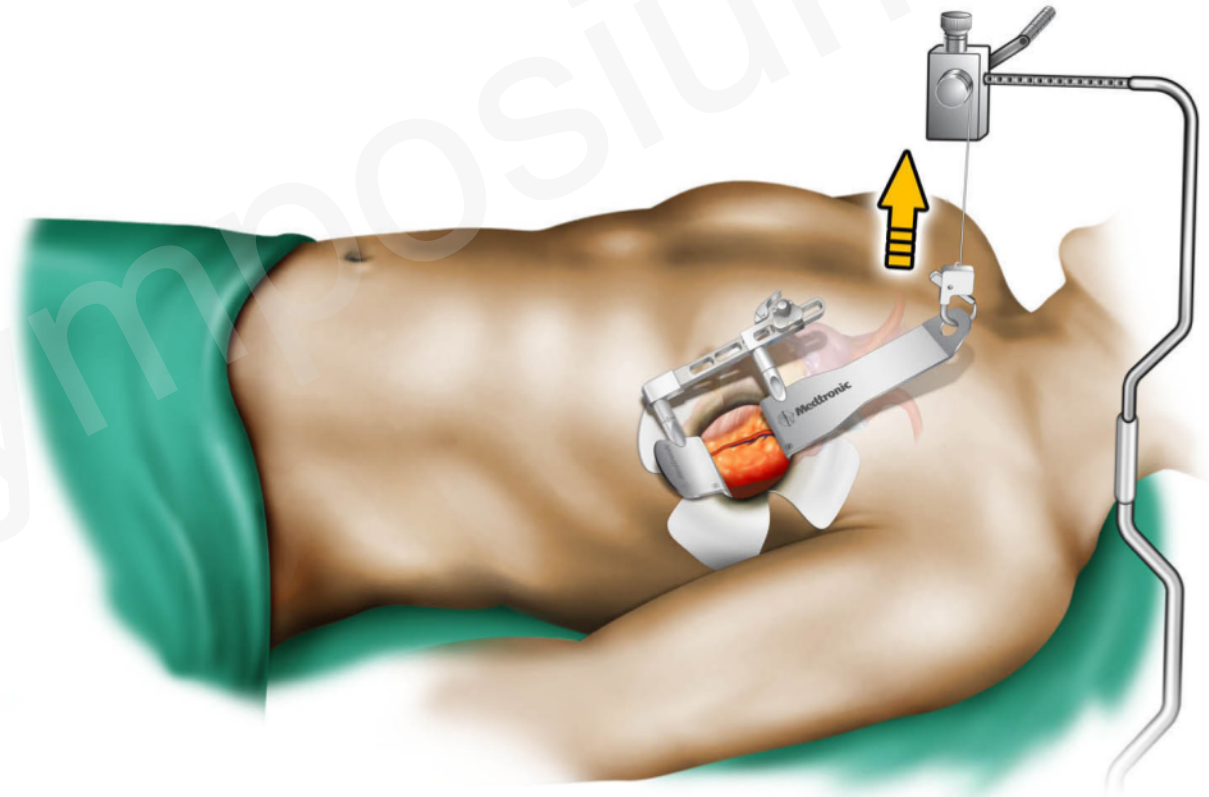
- Global myocardial ischemia
- Renal insufficiency
- Systemic inflammatory response
- Impairment of lung function
- Coagulopathy
- Fluid retention
- CVA
- Neurocognitive deficit

- Complete coronary revascularization
- Less physiologic impact
- Lower mortality
- Fewer complications
 - Less bleeding
 - Lower transfusion rates
 - Less renal, pulmonary, and neurologic impact
- Shorter recovery time

- High risk
 - Prohibitive risk → high risk
 - High risk → lower risk
- Low risk
 - Low risk → even lower

MIDCAB/MICS CAB

- LIMA harvest with specially designed retractor
- Harvest under direct vision with standard cautery/instruments
- Distal anastomosis standard off-pump technique, instruments
- Single or multi-vessel bypass
- Robotic assistance becoming more common



- LIMA-LAD (MI/Off-pump/Sternal-sparing)
- +/- Completion arteriogram
- PCI /DES to non-LAD territories
- “Best of both worlds”
- Combines durability of CAB to critical LAD territory with minimal invasiveness of PCI

Minimally Invasive Aortic Valve Replacement

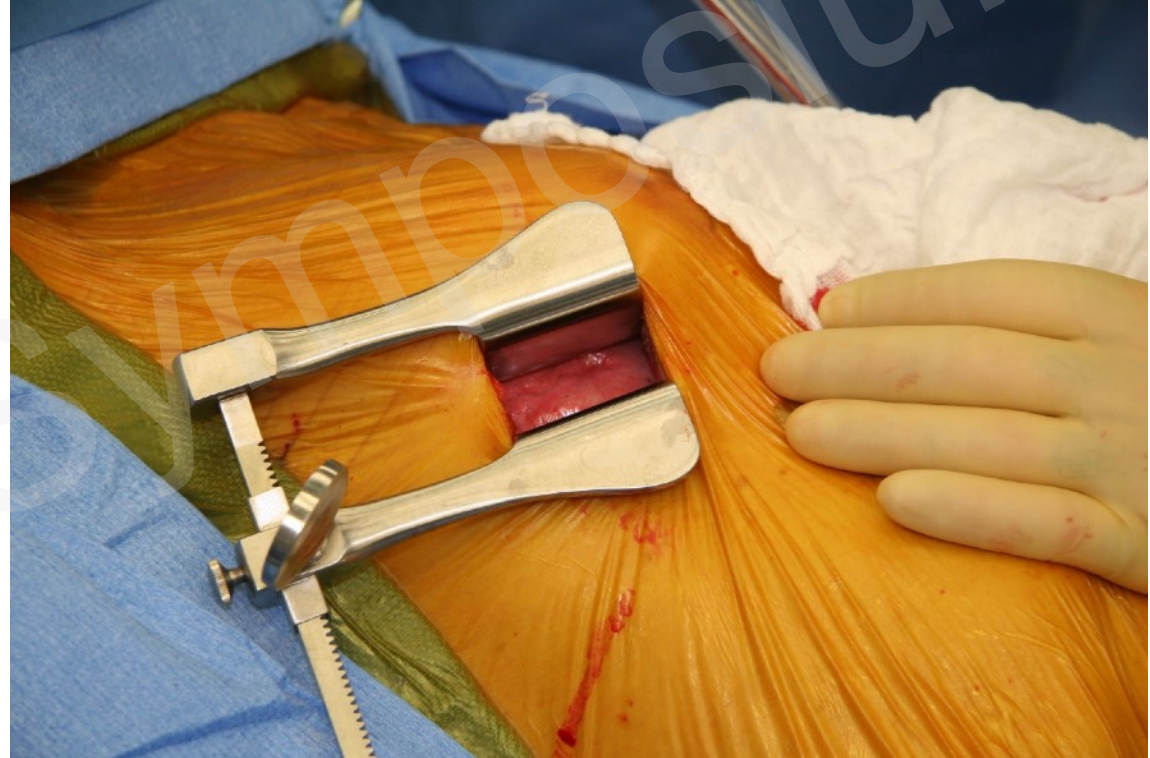Minimally Invasive Mitral Valve Repair/Replacement

Robotic Mitral Valve Repair/Replacement

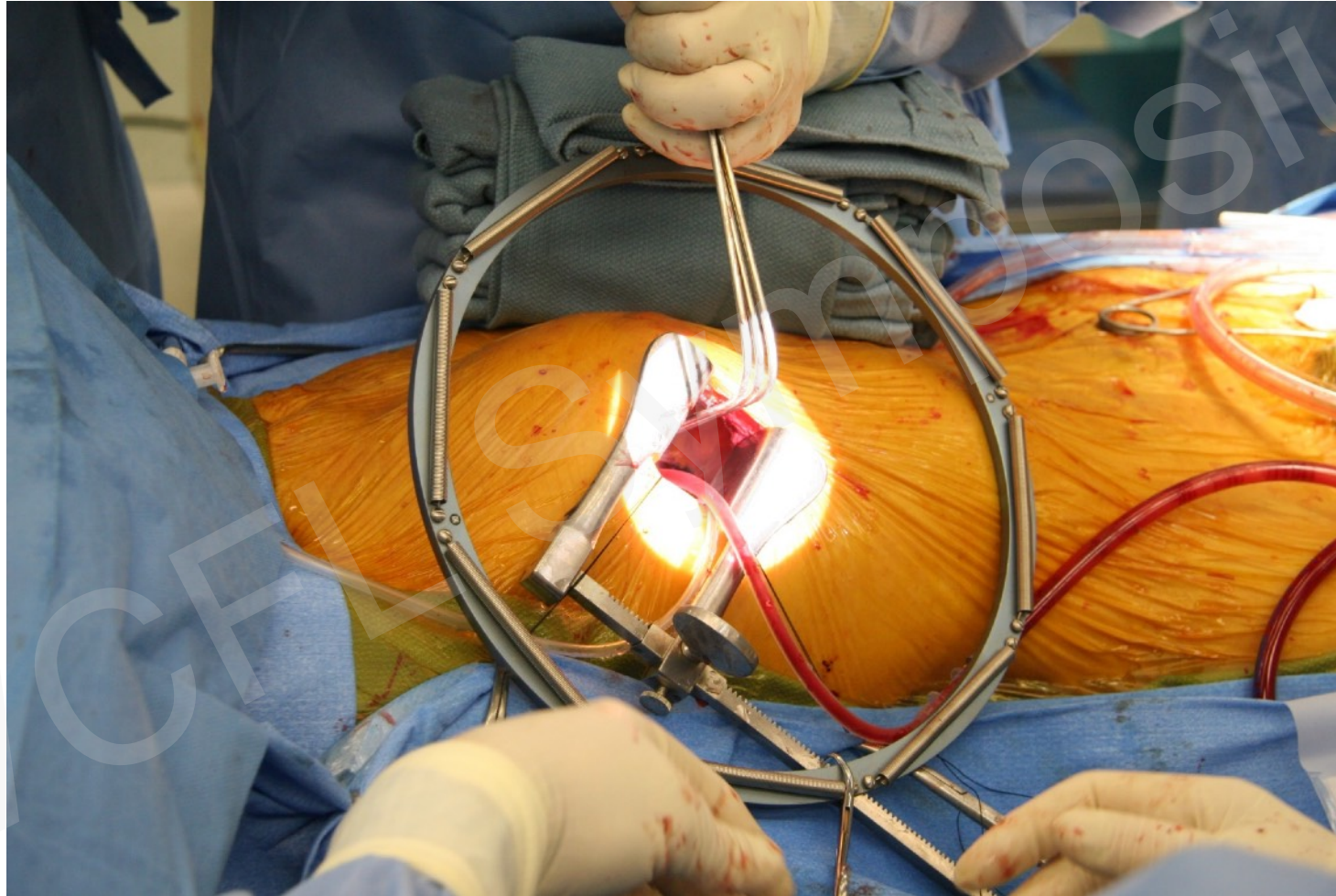
Structural Heart Surgery

- Small right thoracotomy
- Direct vs femoral cannulation for CPB
- Excellent direct visualization
- Minor modifications in techniques/instrumentation
- Minimal physiologic impact
- Reduced morbidity/mortality

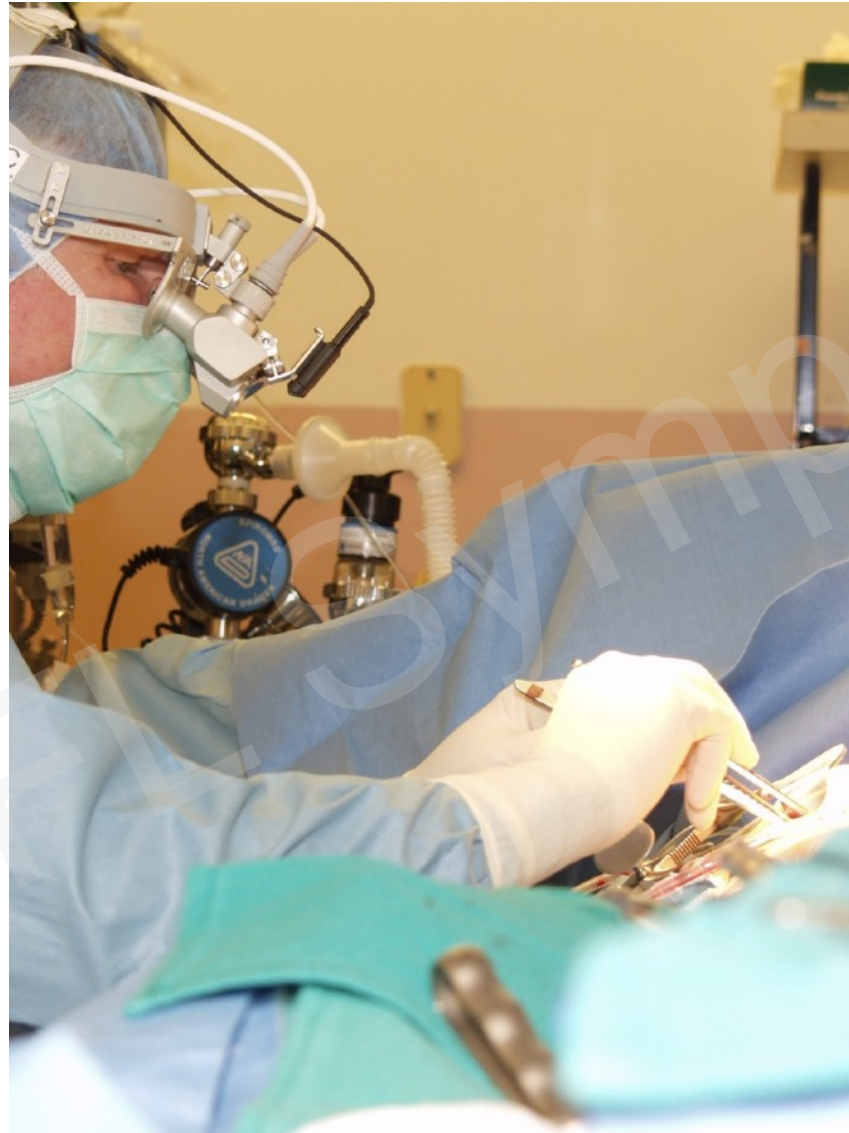- Right Thoracotomy for Minimally Invasive Mitral Approach



Minimally Invasive Mitral Valve Repair/Replacement

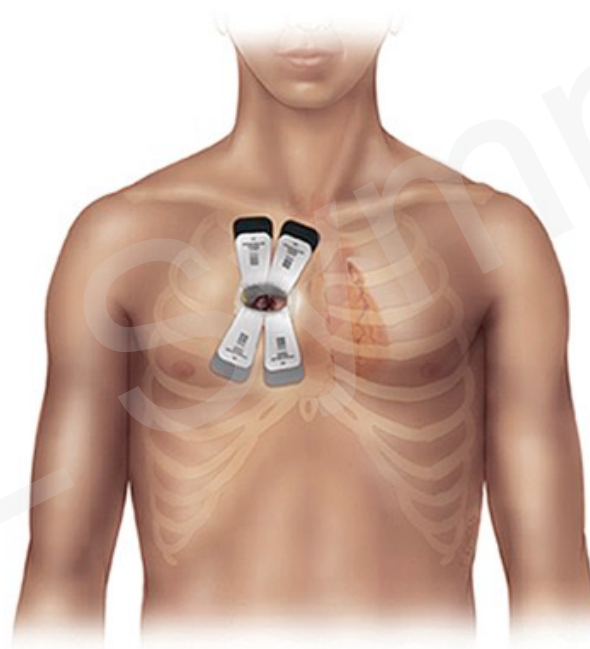


Minimally Invasive Mitral Valve Repair/Replacement



- Mitral Valve Repair/Replacement
- Tricuspid Valve Repair/Replacement
- Atrial Septal Defect Repair
- Left Atrial Myxoma Resection
- Maze Procedure

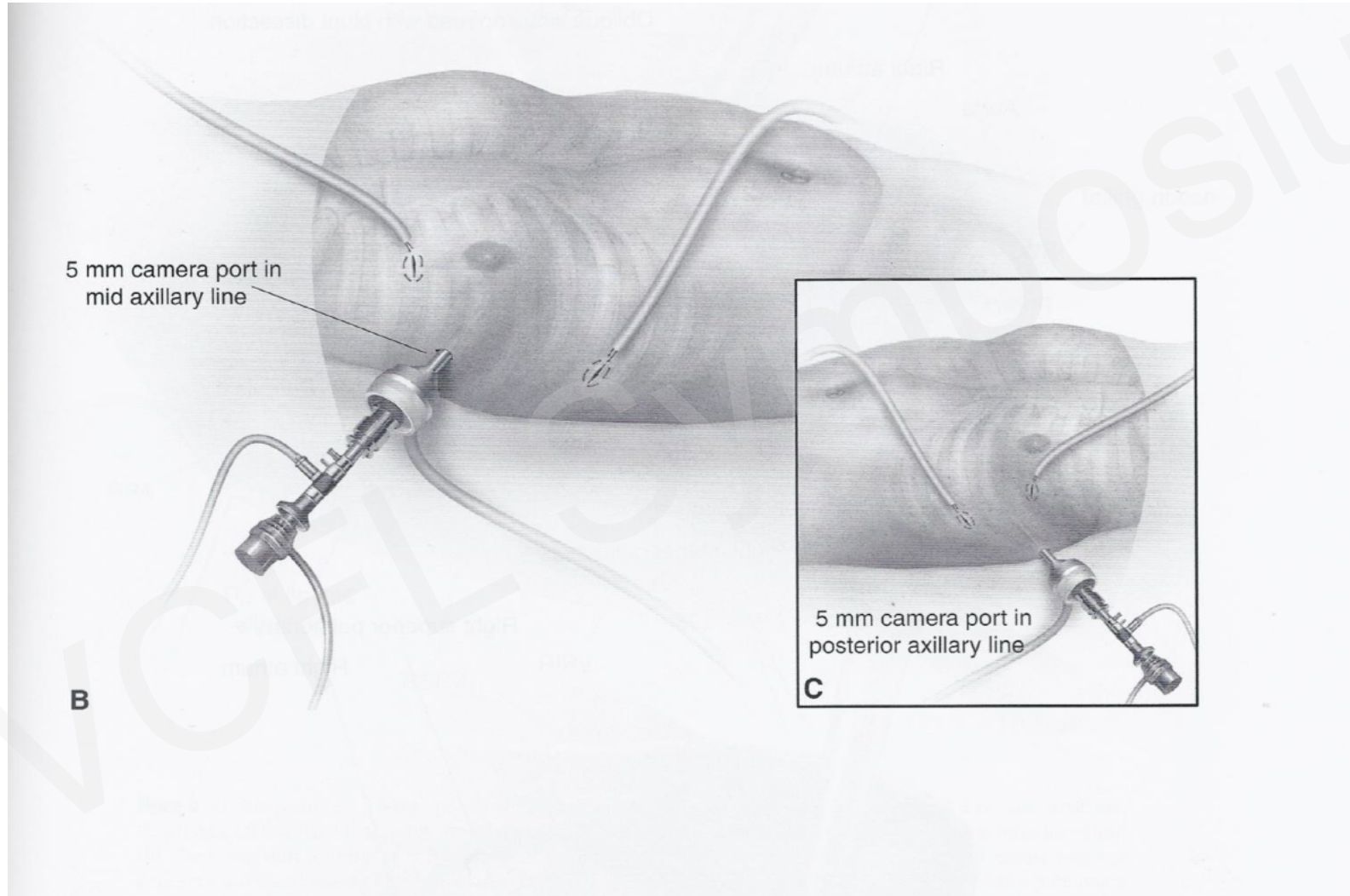
Minimally Invasive Aortic Valve Replacement



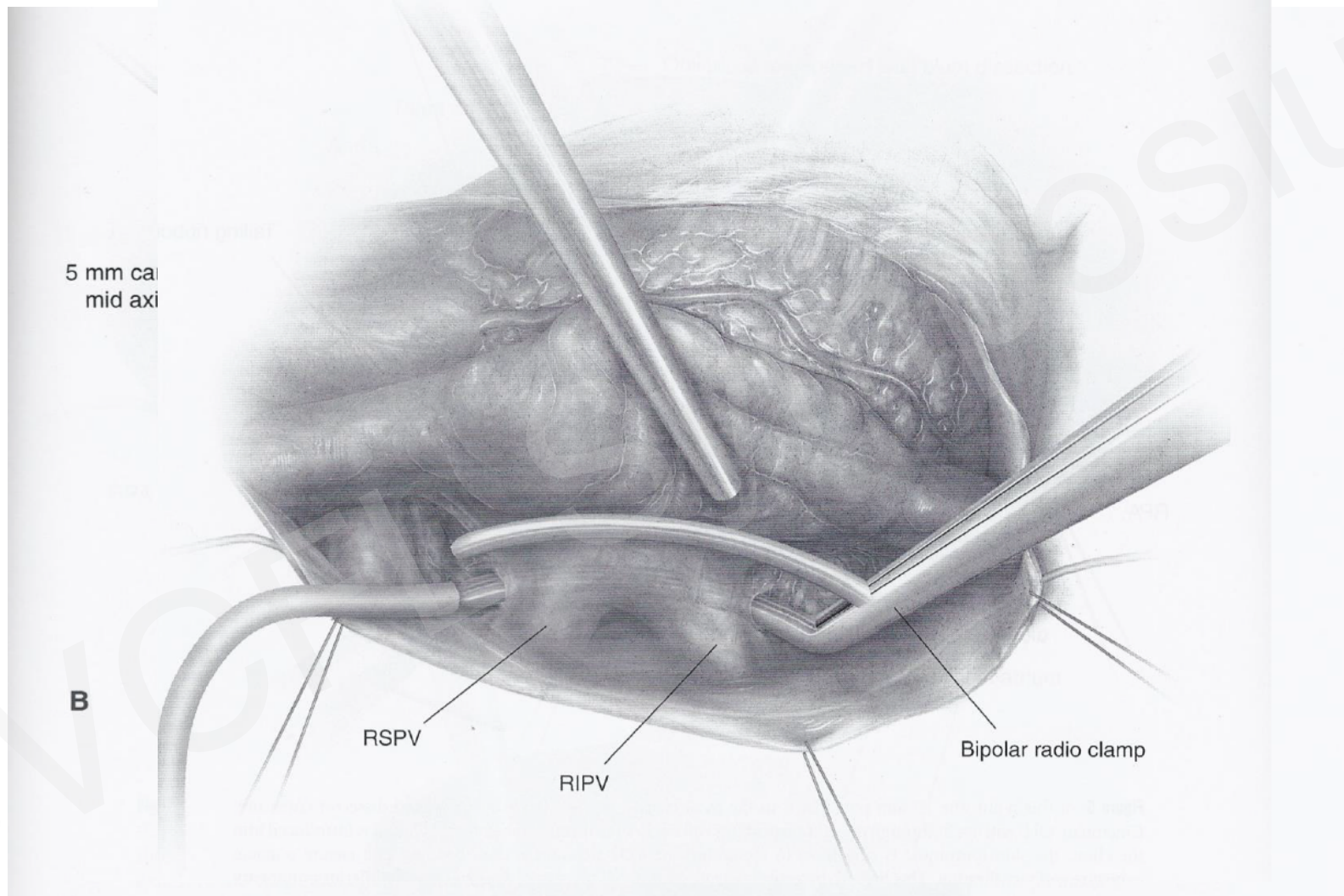
- Hybrid Ablation for Atrial Fibrillation
 - Bilateral Thoracoscopy
 - Subxyphoid
- Thoracoscopic LAA Ligation
- Hybrid Ablation for Ventricular Tachycardia
- Hybrid Ablation for Inappropriate Sinus Tachycardia

- Surgical lesions robust
- Managing the LA appendage a must
- Rigorous epicardial testing with follow-up endocardial testing/ablation ensures full thickness and complete lines
- Mitral and tricuspid lines often challenging epicardially, simpler endocardially with guidance
- Ideal approach for Sx Persistent/LSP

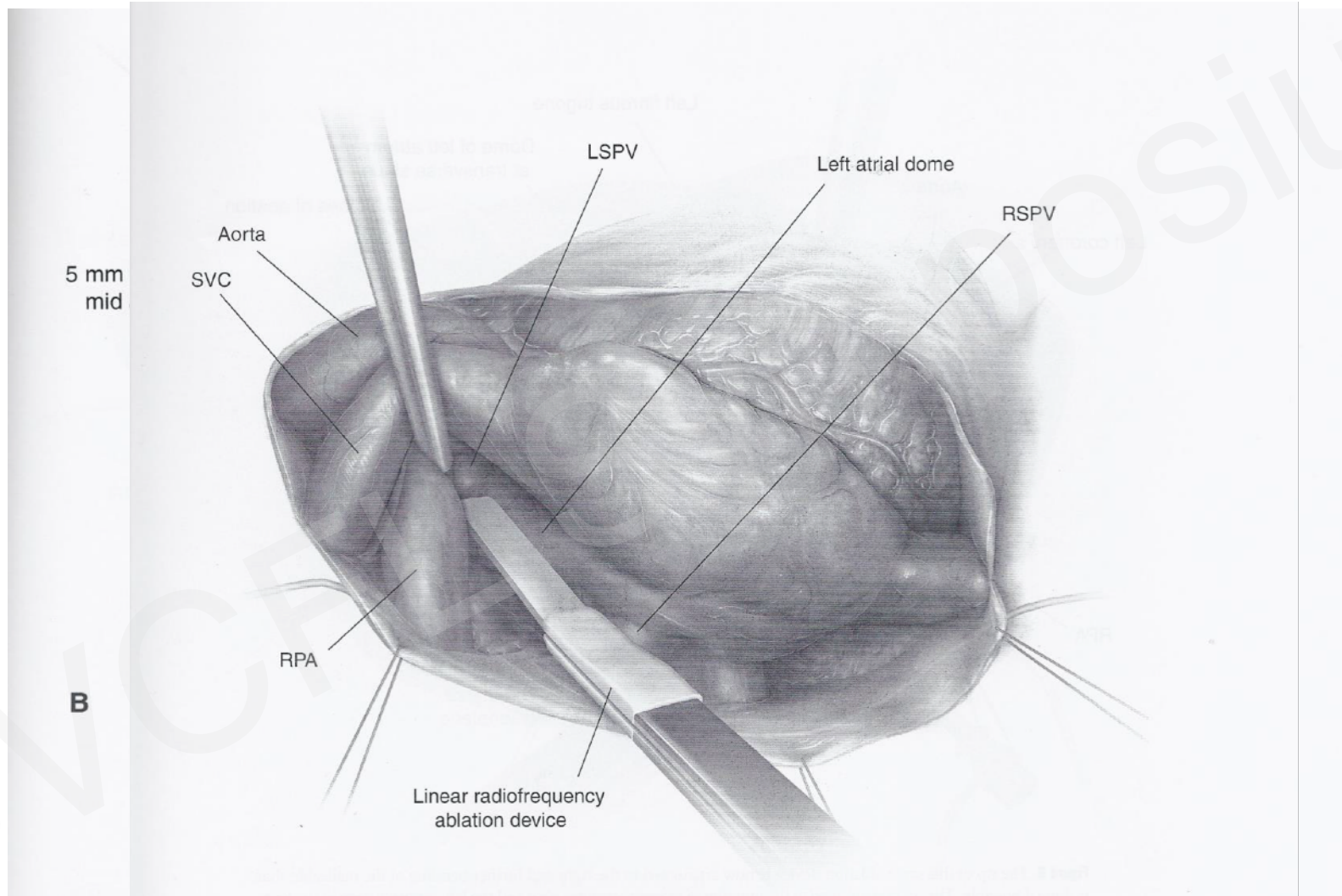
Thoracoscopic Epicardial Ablation for Atrial Fibrillation



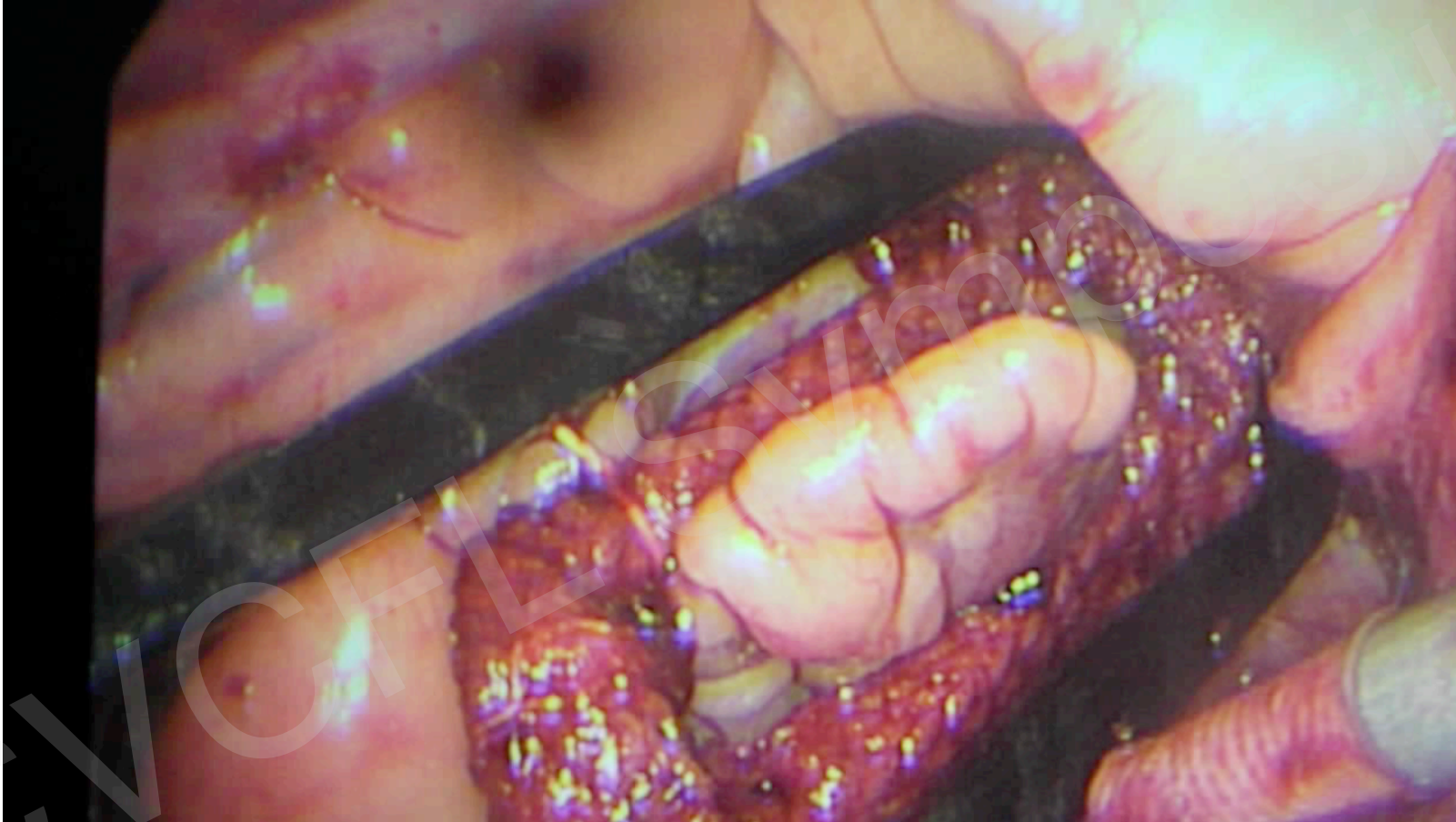
Thoracoscopic Epicardial Ablation for Atrial Fibrillation



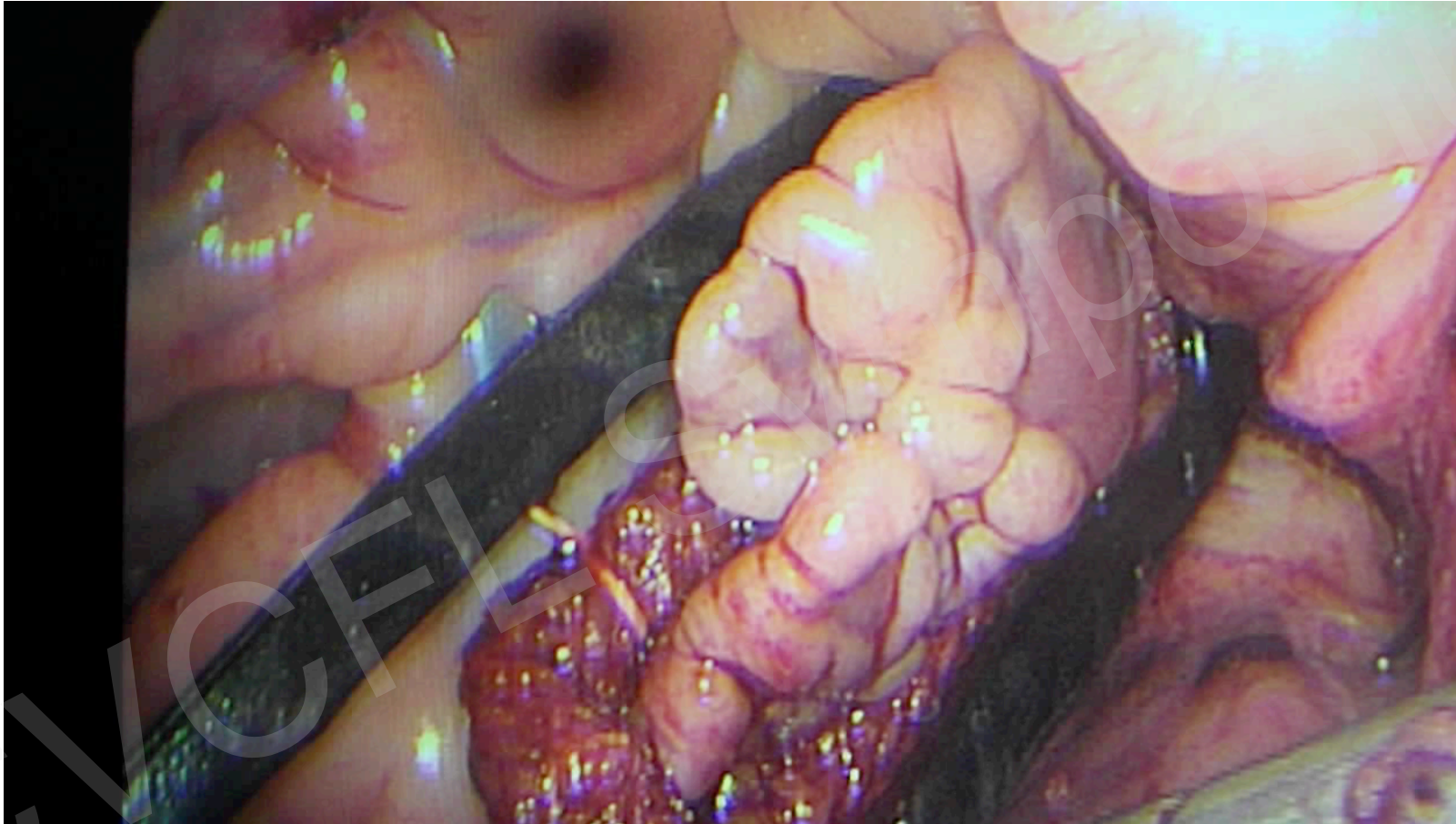
Thoracoscopic Epicardial Ablation for Atrial Fibrillation



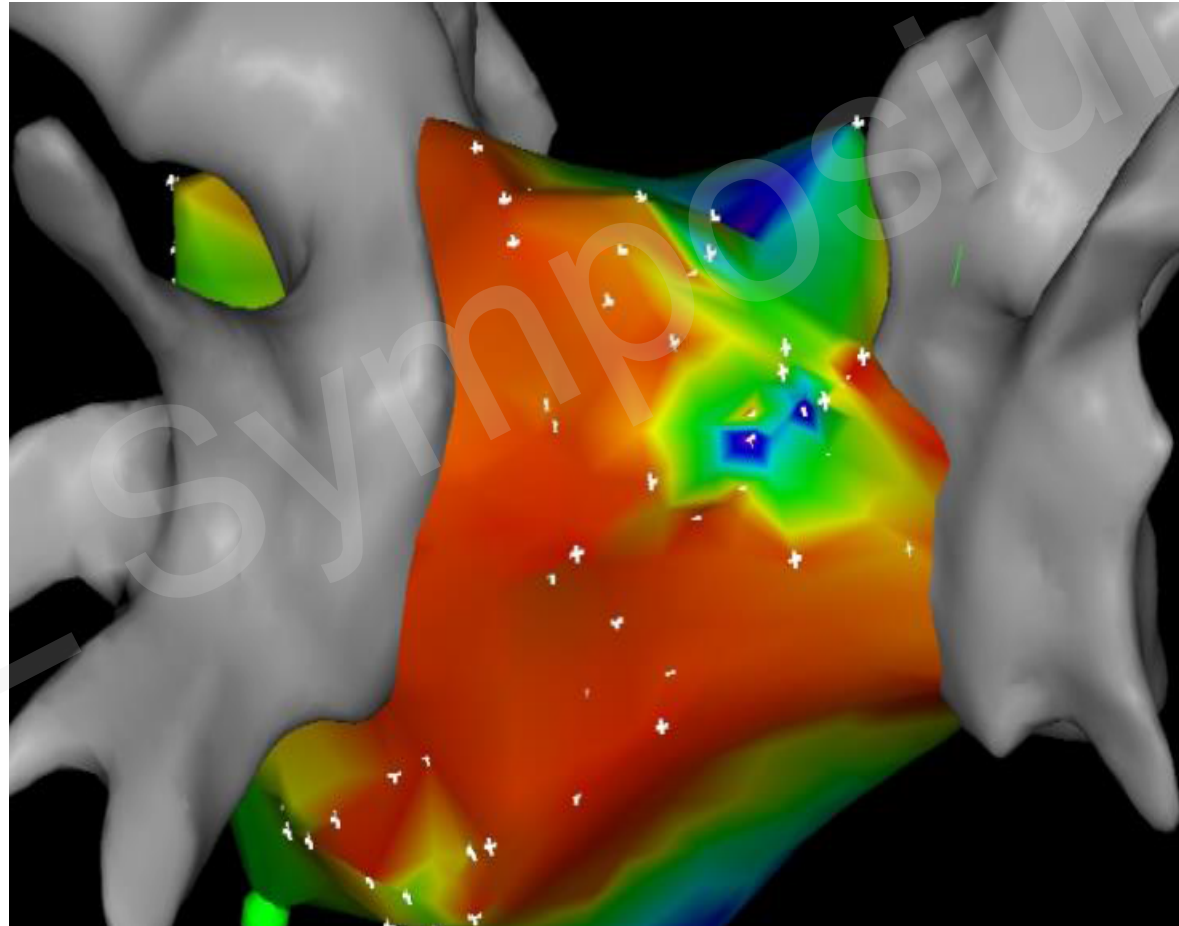
Atriclip on LAA



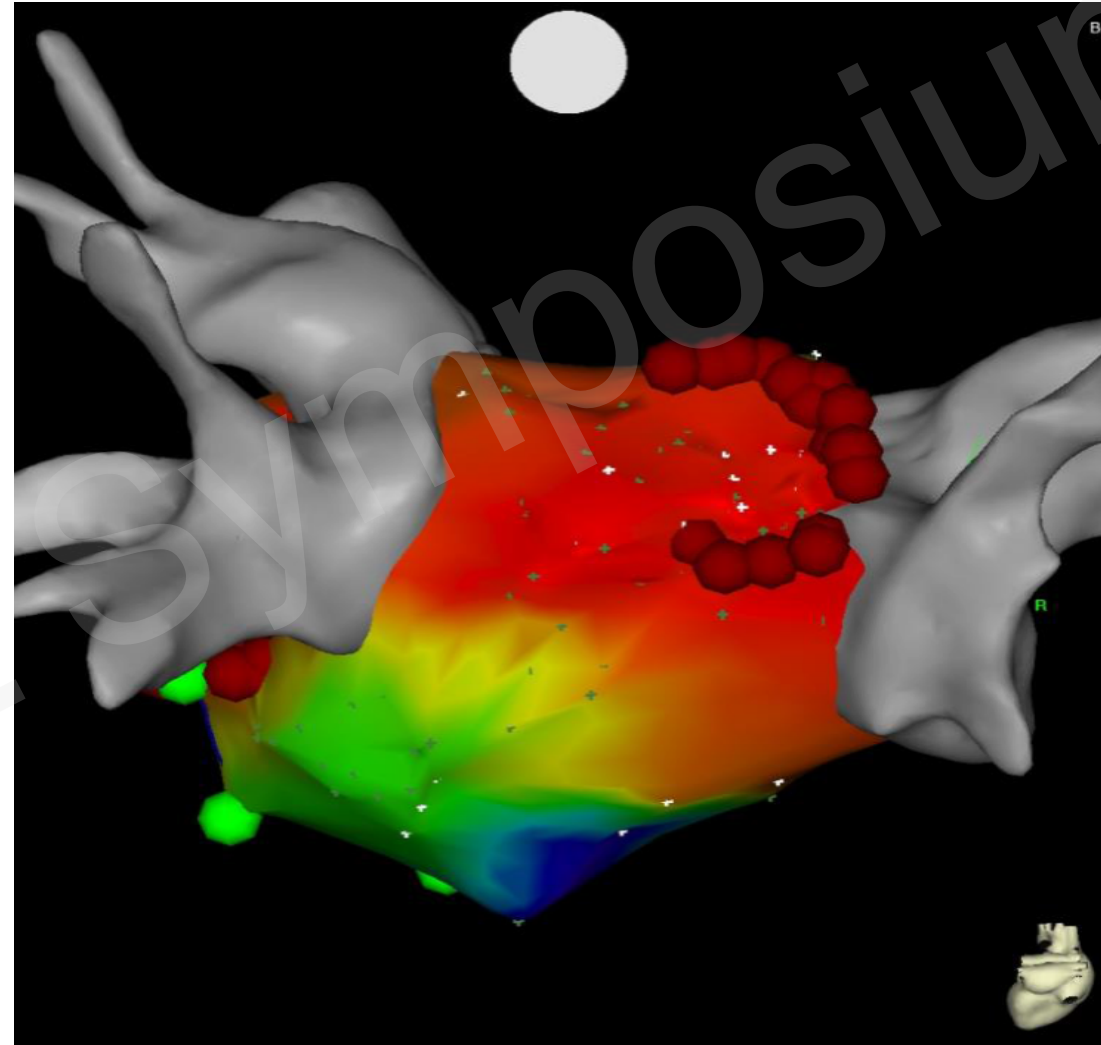
Atriclip on LAA

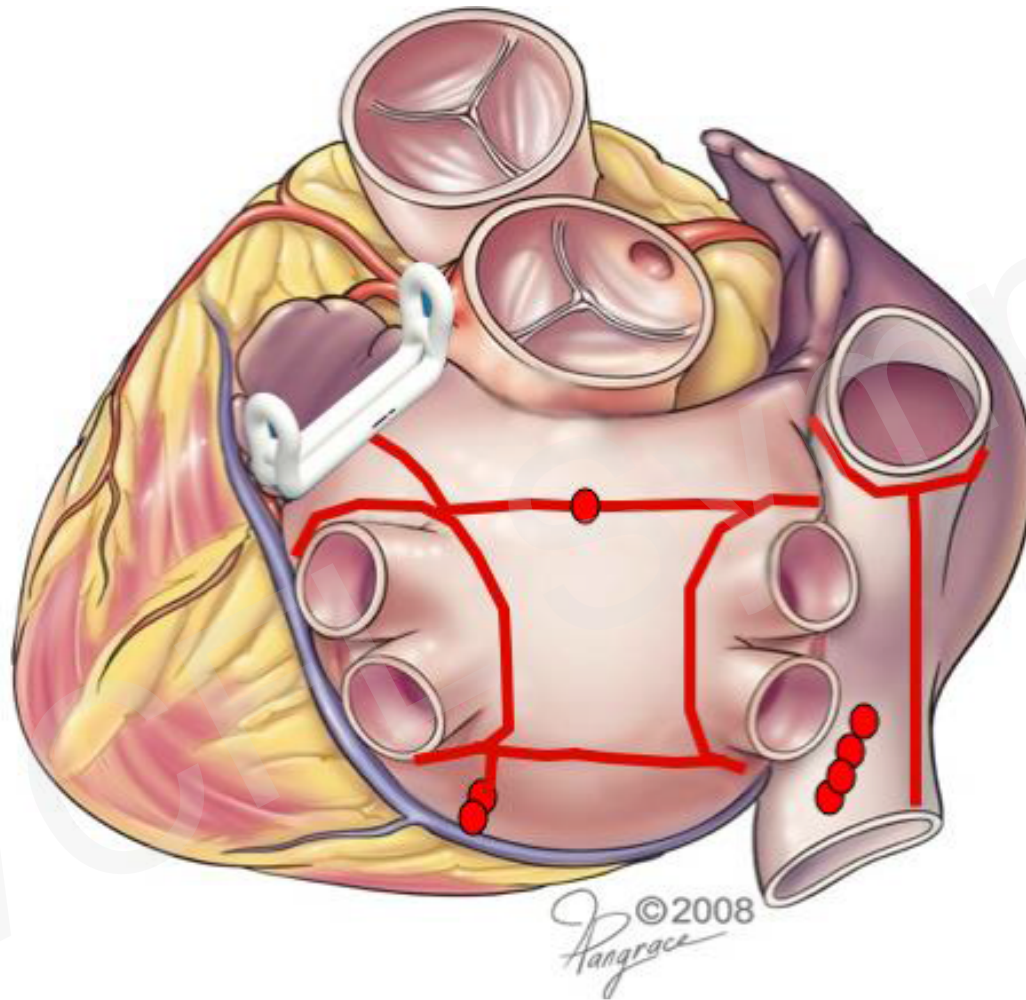


Carto voltage
map showing
isolated
posterior LA
except in area
of incomplete
block along
Superior
connecting line



Voltage map
showing
completion
of superior
connecting
line resulting
in isolated
posterior LA
as well as mitral
isthmus line





“This is a Maze lesion set”

James Cox, MD
2016

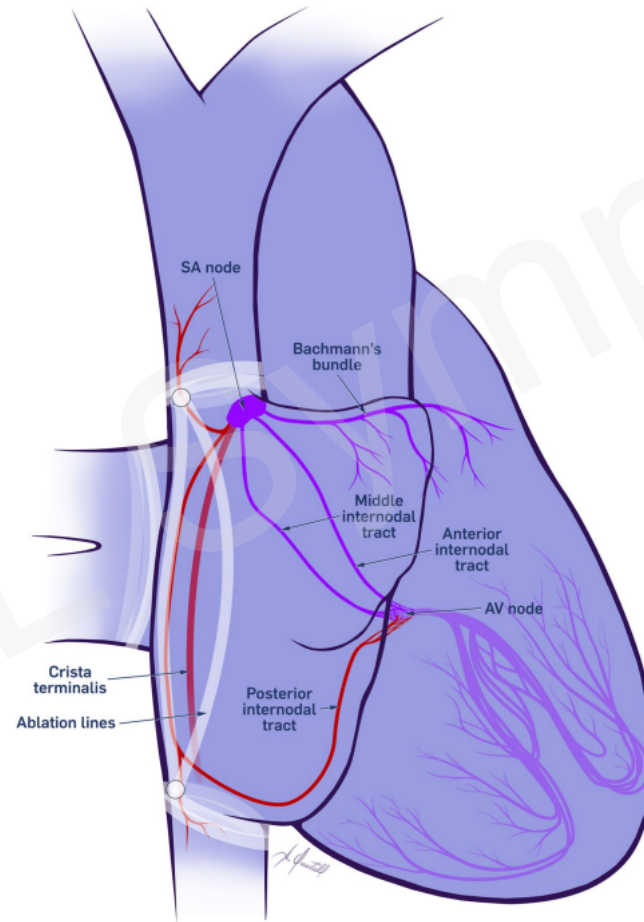
- Thoracoscopic LAA ligation
- Hybrid Ablation for Ventricular Tachycardia
- Hybrid Ablation for Inappropriate Sinus Tachycardia
- Laser-assisted lead extraction/Complex lead management

- IST is a prevalent and debilitating condition resulting in sudden and profound episodes of inappropriate sinus tachycardia.
- Common symptoms are fatigue, dizziness, presyncope, syncope.
- Commonly in healthy young women, 50% are health care workers.
- Symptoms result in significant loss of quality of life.

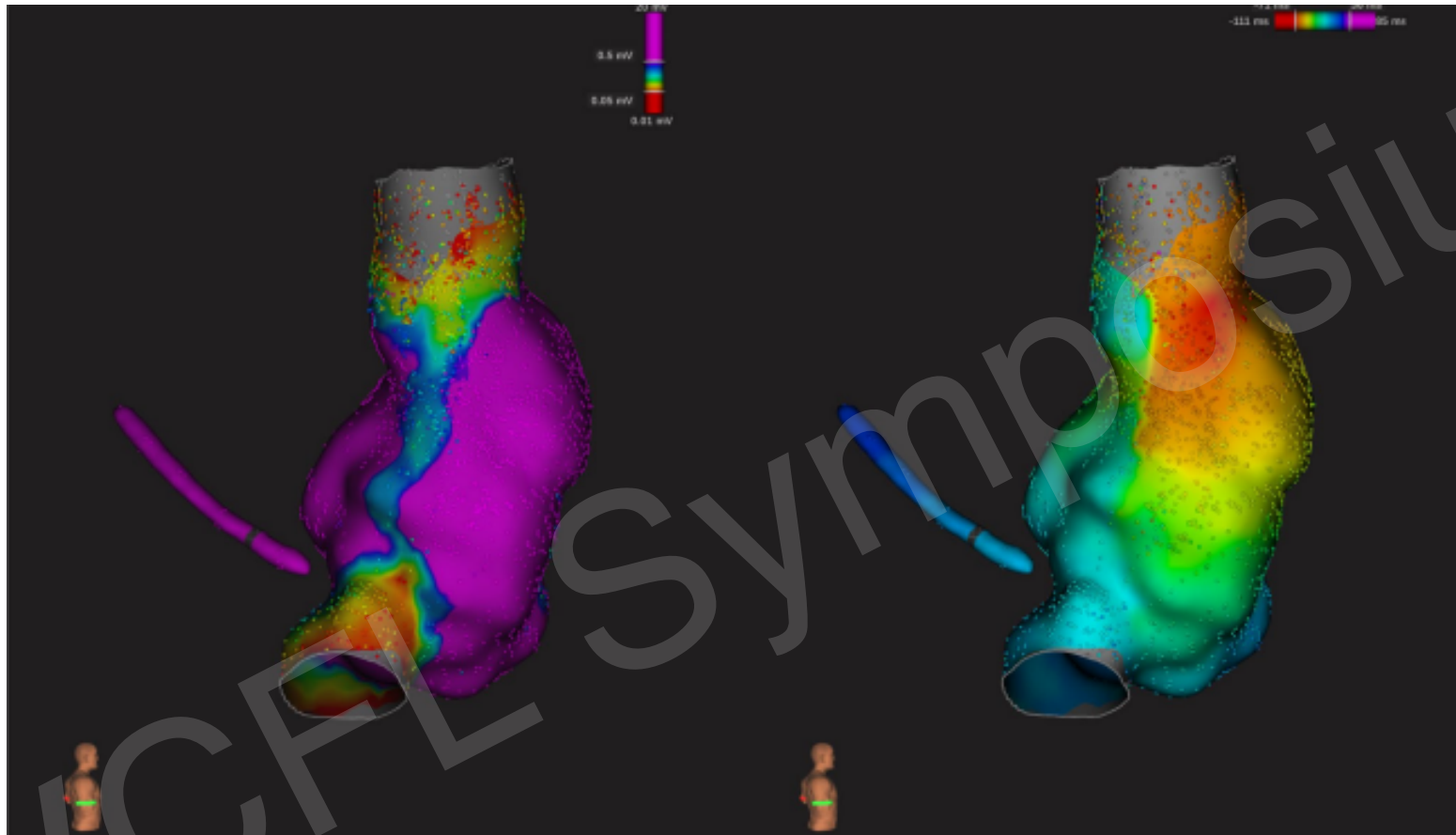
- Abnormality is mapped to crista terminalis in SAN complex, an epicardial structure.
- Attempts to map and ablate endocardially associated with high failure rate, phrenic nerve palsy, and SN dysfunction requiring permanent pacing.
- Group in Belgium developed hybrid epi/endo mapping/ablation strategy with excellent success and extremely low complication rates.

- R thoracoscopy
- Endocardial mapping of SAN complex with chemical induction of IST (Isuprel)
- Mark SAN/crista
- Epicardial ablation of R PVI/ crista terminalis
- Repeat endocardial mapping/attempts to induce IST

Hybrid IST Ablation



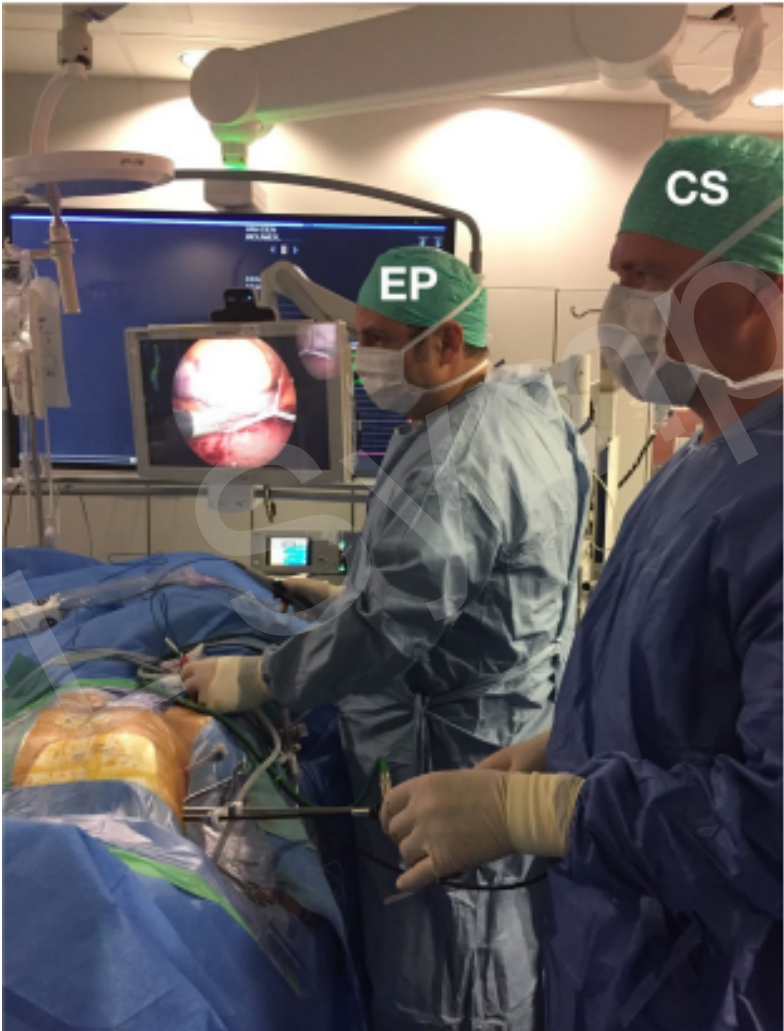
Post-ablation Electroanatomic Mapping



Left-Isolation of SVC/IVC (red) and Christa Terminalis (lateral blue line)
Right-Preservation of site of earliest activation SA node-red)



Hybrid IST Ablation



- Minimally invasive/hybrid approaches have become commonplace/standard of care
- UCF-HCA Heart Institute offers a broad range of these state-of-the-art procedures
- Safe and effective alternatives for the treatment of CAD, valve disease, and arrhythmias
- An integrated multi-disciplinary approach provides optimal evidence-based care to patients
- UCF-HCA Heart Institute is involved in international clinical research in the field of hybrid therapies