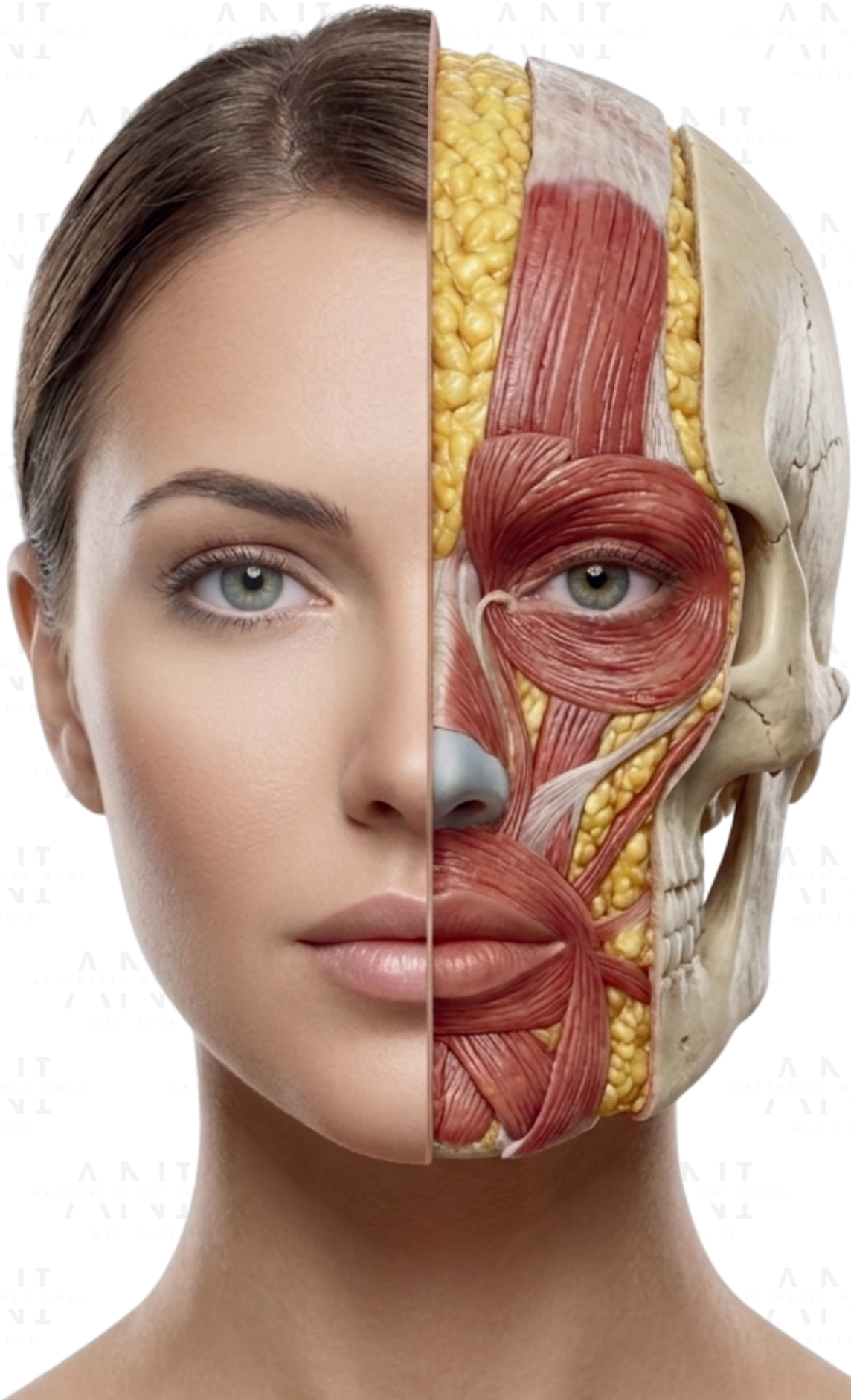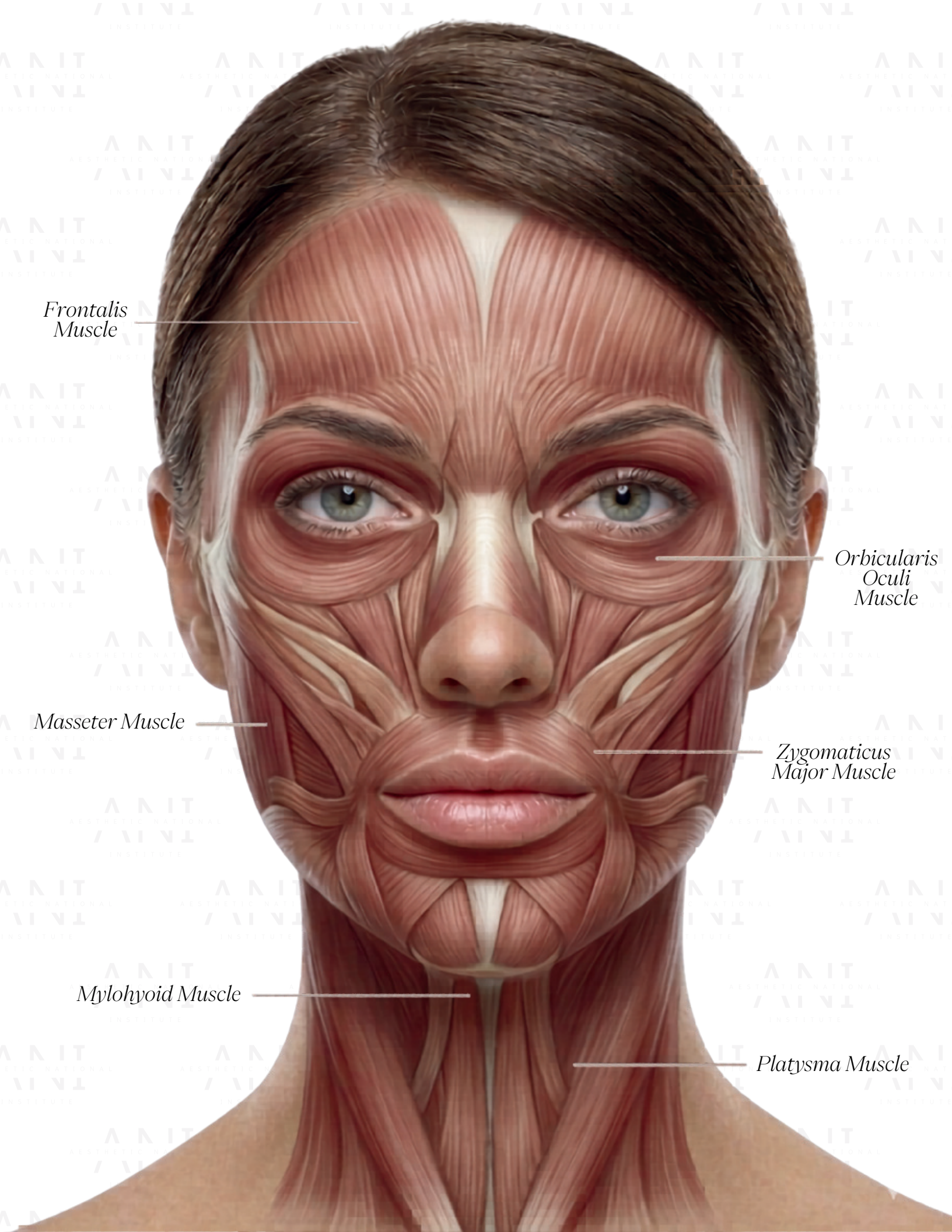


Clinical Reference Charts





Frontalis Muscle

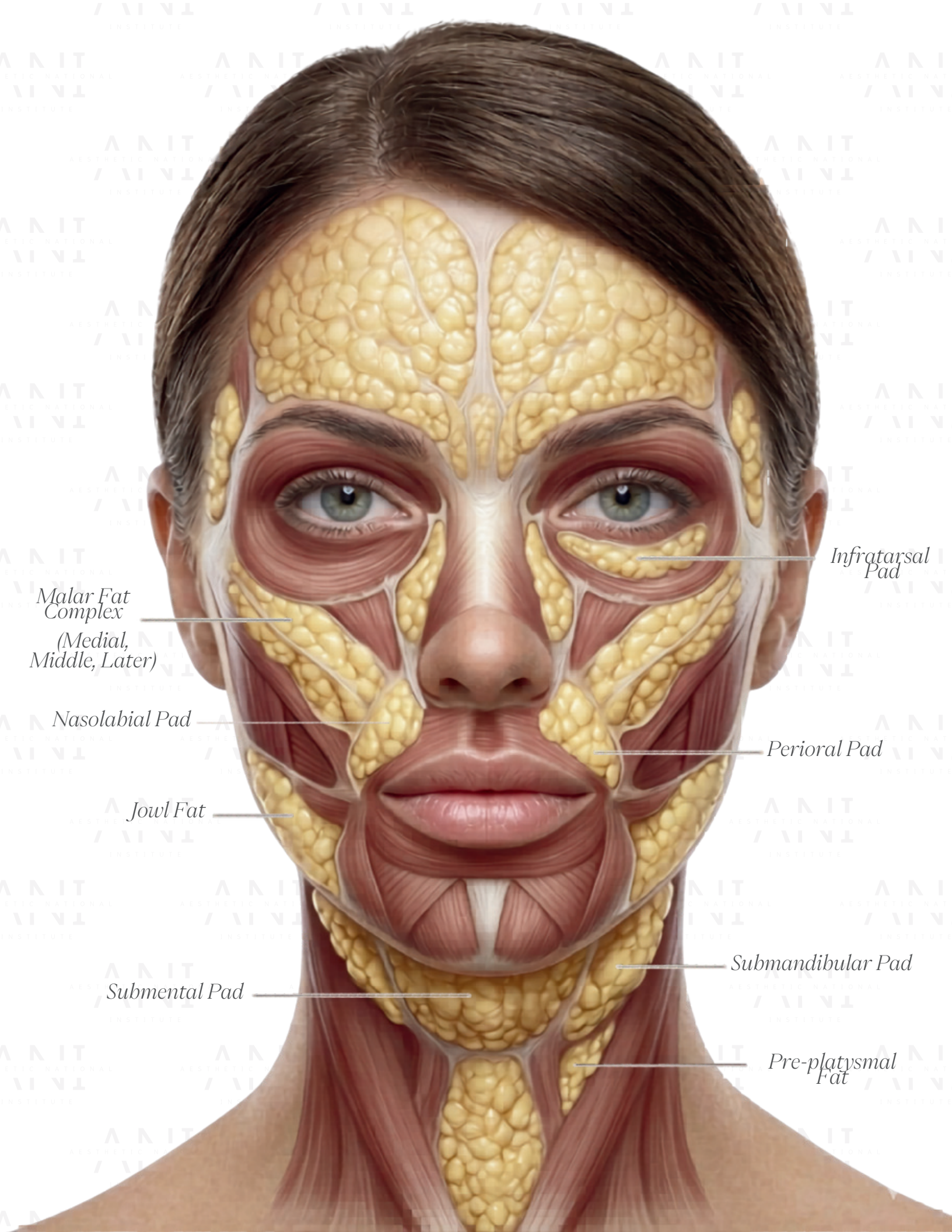
Orbicularis Oculi Muscle

Masseter Muscle

Zygomaticus Major Muscle

Mylohyoid Muscle

Platysma Muscle



*Malar Fat Complex
(Medial, Middle, Later)*

Nasolabial Pad

Jowl Fat

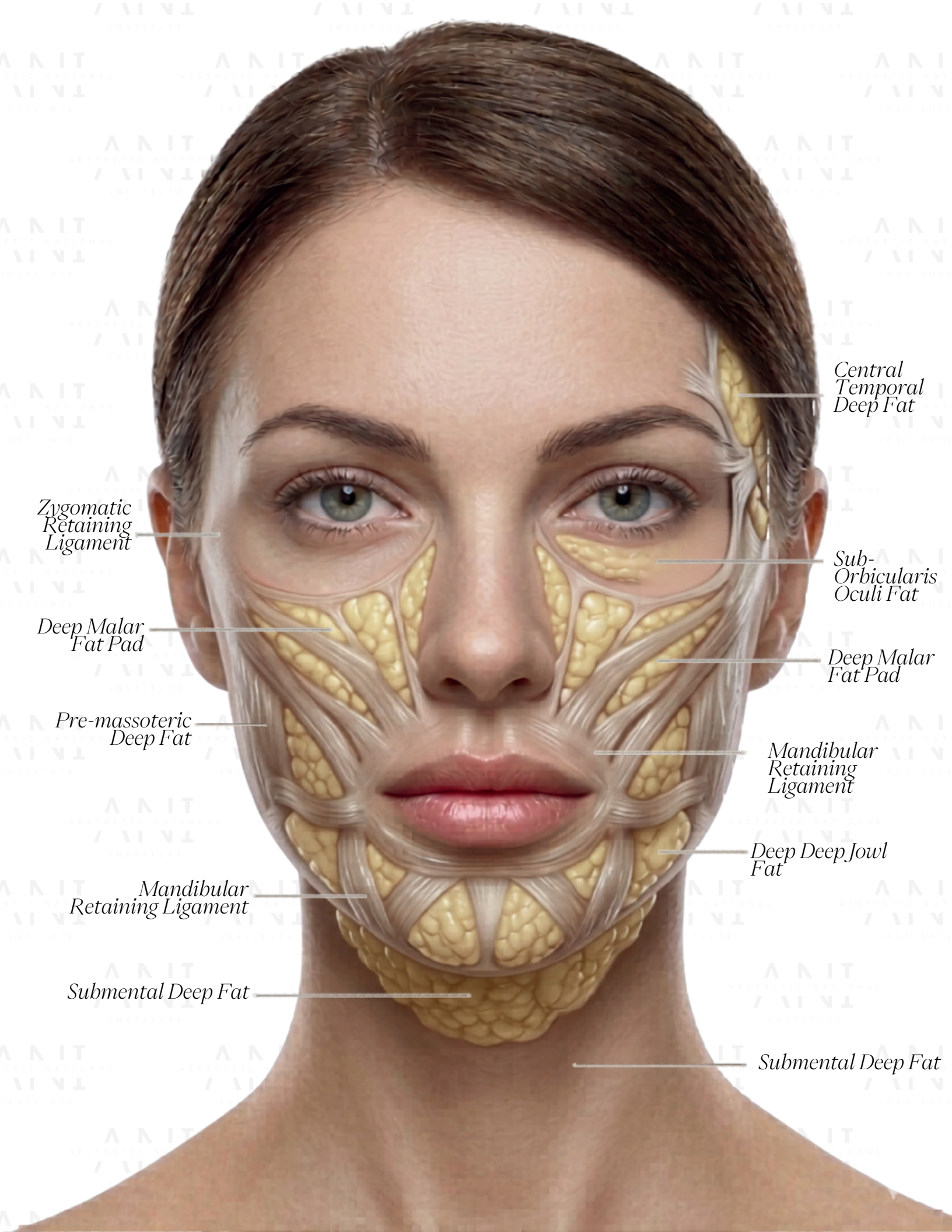Submental Pad

Infratarsal Pad

Perioral Pad

Submandibular Pad

Pre-platysmal Fat



*Central
Temporal
Deep Fat*

*Zygomatic
Retaining
Ligament*

*Sub-
Orbicularis
Oculi Fat*

*Deep Malar
Fat Pad*

*Deep Malar
Fat Pad*

*Pre-massoteric
Deep Fat*

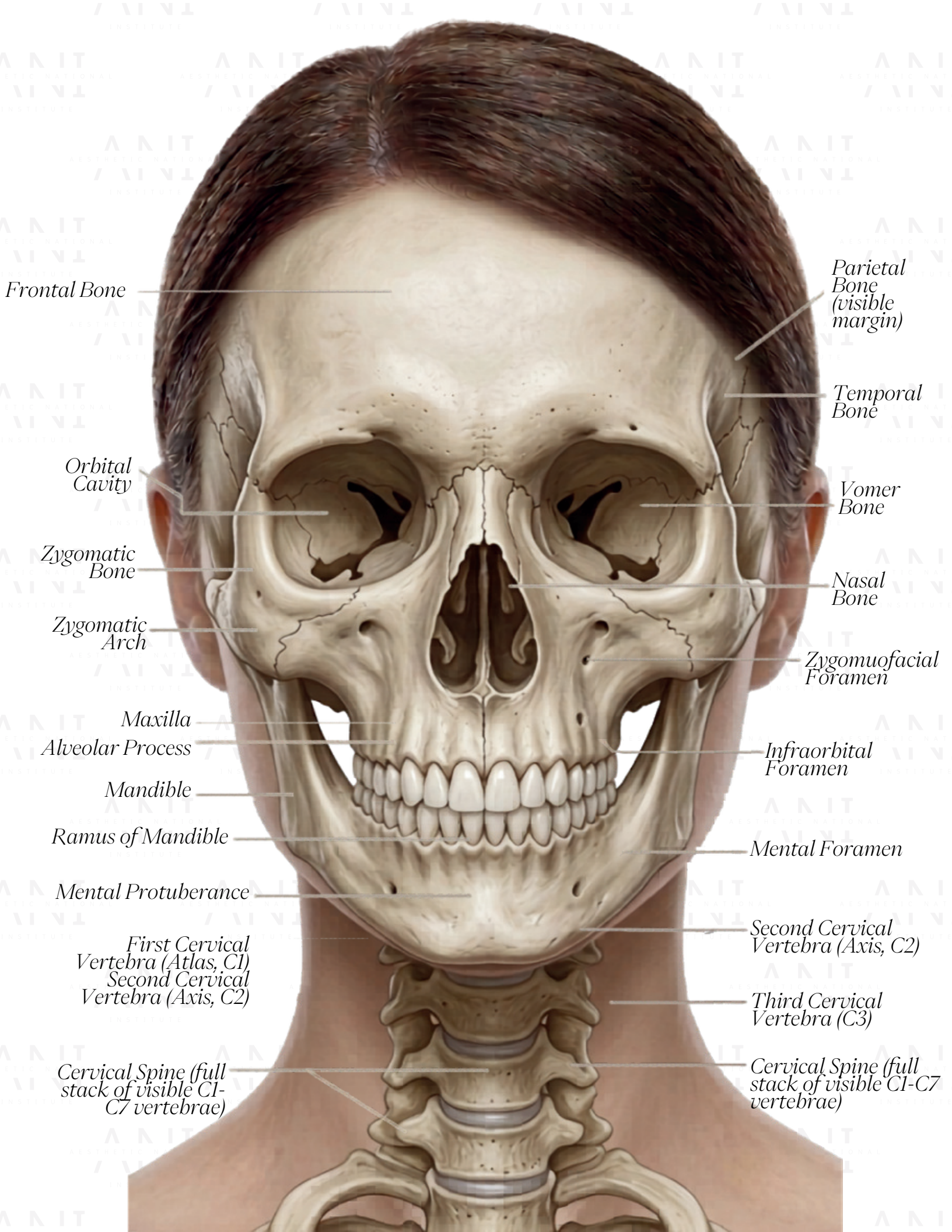
*Mandibular
Retaining
Ligament*

*Deep Deep Jowl
Fat*

*Mandibular
Retaining Ligament*

Submental Deep Fat

Submental Deep Fat



Frontal Bone

Parietal Bone (visible margin)

Temporal Bone

Orbital Cavity

Vomer Bone

Zygomatic Bone

Nasal Bone

Zygomatic Arch

Zygomuofacial Foramen

Maxilla

Alveolar Process

Infraorbital Foramen

Mandible

Ramus of Mandible

Mental Foramen

Mental Protuberance

*First Cervical Vertebra (Atlas, C1)
Second Cervical Vertebra (Axis, C2)*

Second Cervical Vertebra (Axis, C2)

Third Cervical Vertebra (C3)

Cervical Spine (full stack of visible C1-C7 vertebrae)

Cervical Spine (full stack of visible C1-C7 vertebrae)