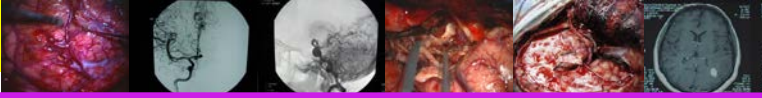


# Spinal Dysraphism

Jerome M. Volk III, M.D.

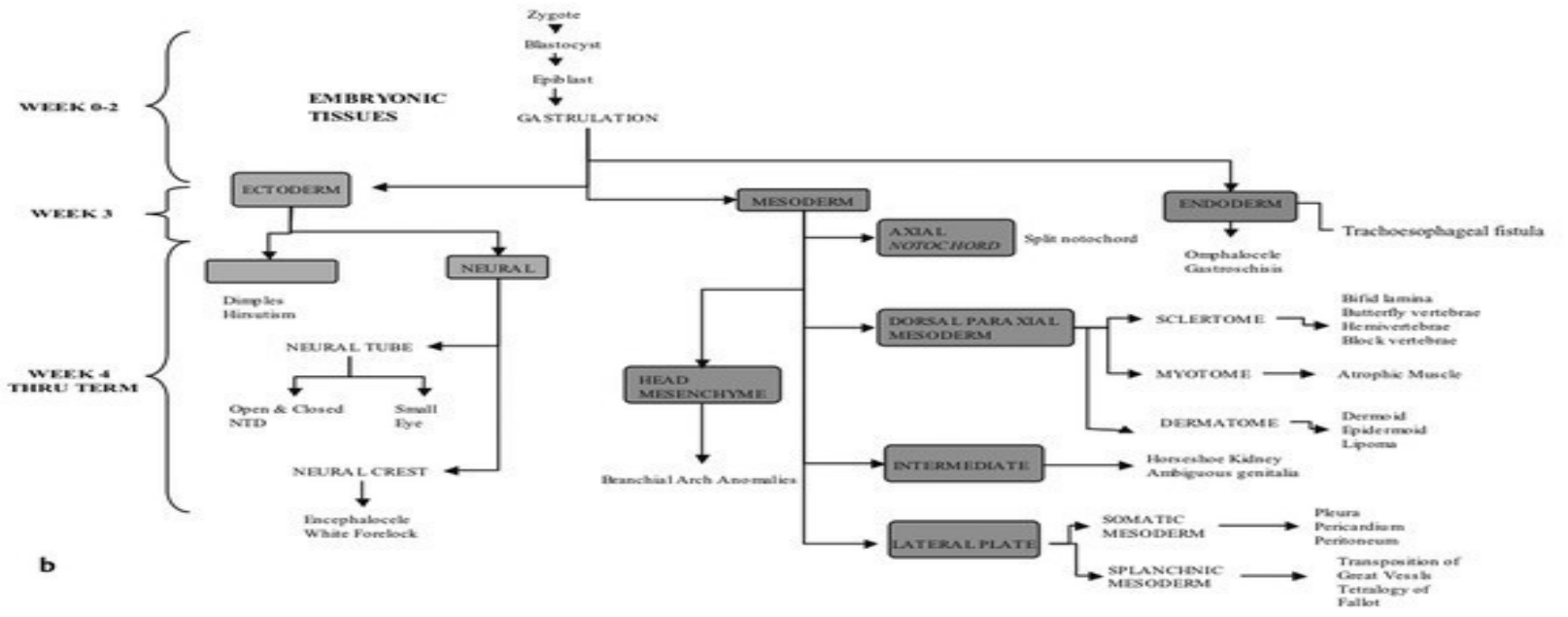
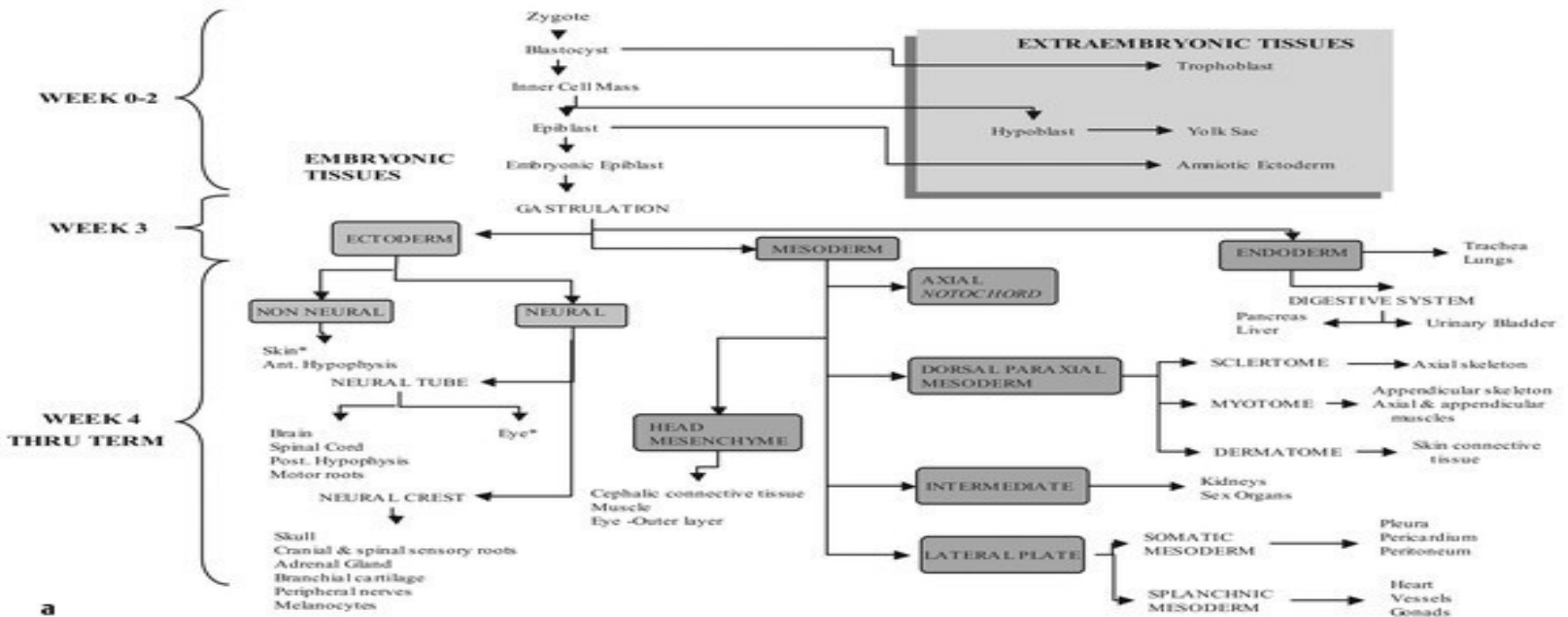
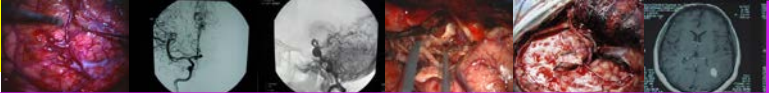
Assistant Professor-LSUHSC Department of  
Neurosurgery

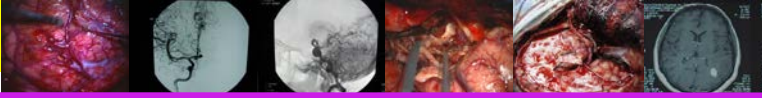
Children's Hospital of New Orleans Department of  
Neurosurgery



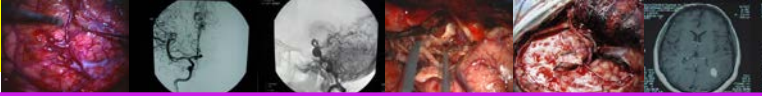
# Disclosure

- Nothing to disclose



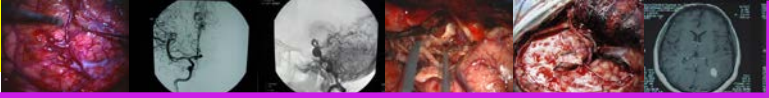

# Open Neural Tube Defect

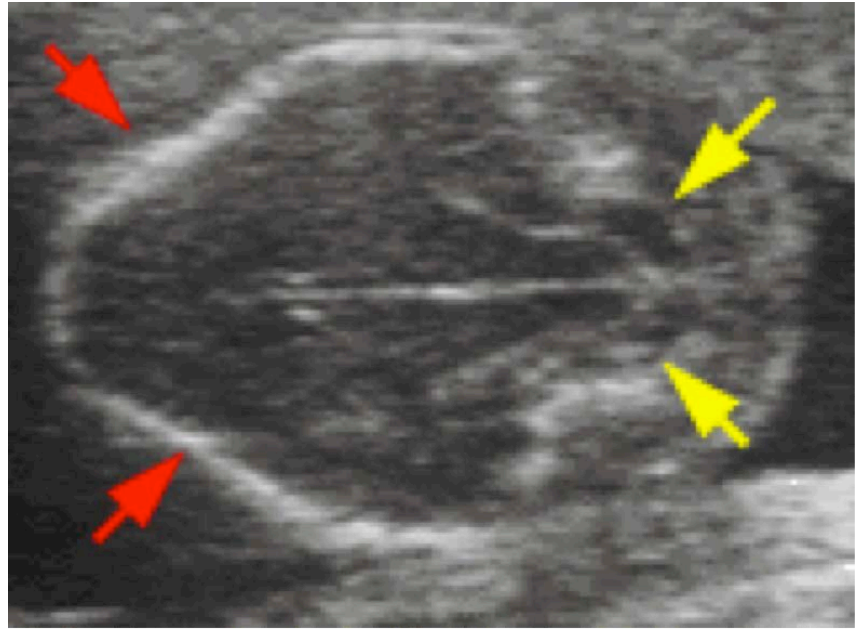
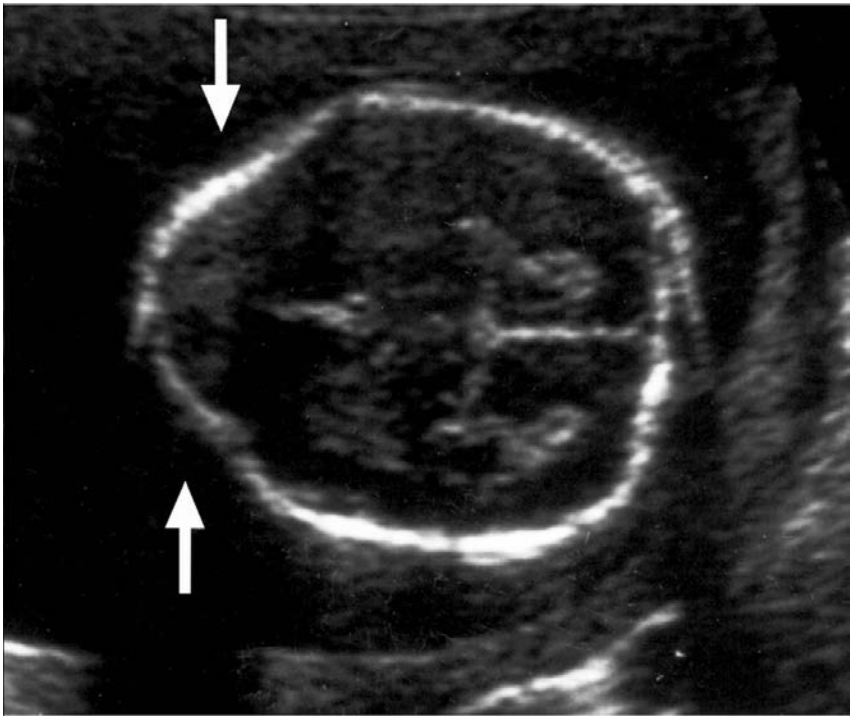


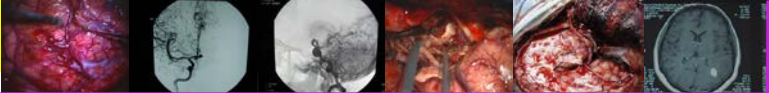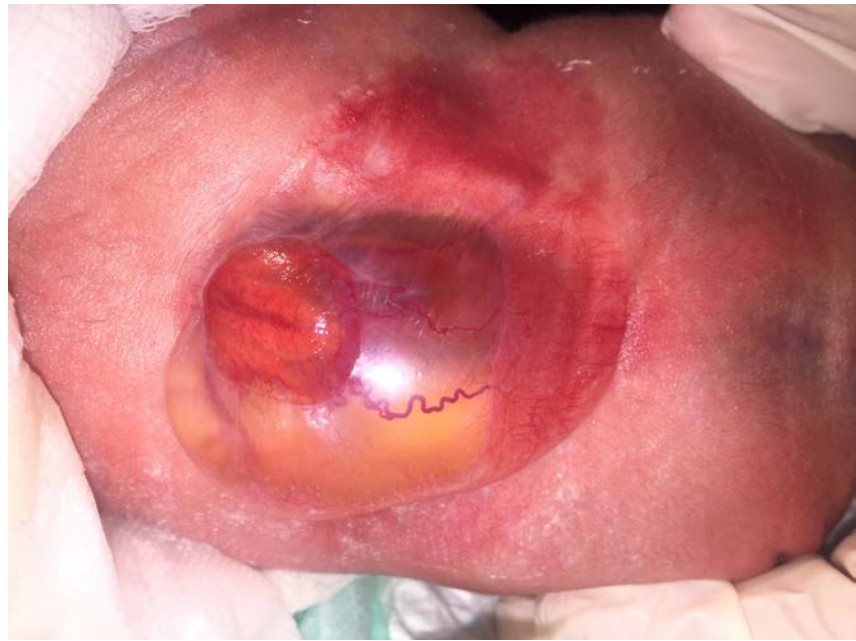
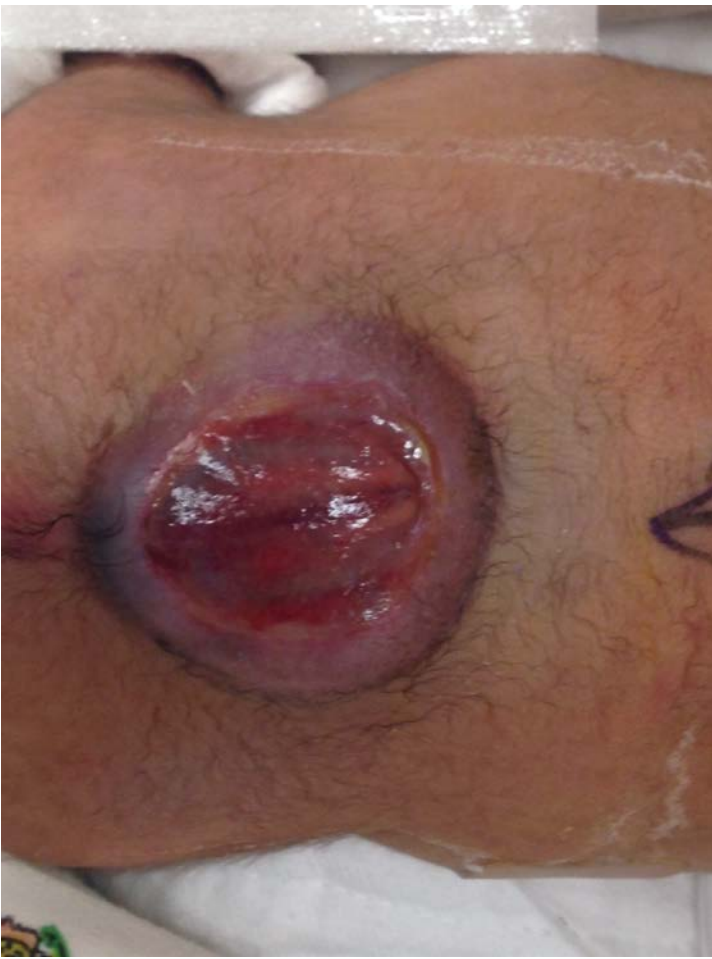# Myelomeningocele

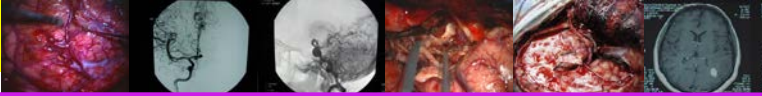
- Myelomeningocele is an example of open neural tube defect.
- It is a defect in primary neurulation.
- It can be seen on prenatal labs with a high alpha-fetaprotein and acetylcholinesterase.
- Can also be seen on prenatal ultrasound.
  - Lemon sign
  - Banana sign



# Myelomeningocele

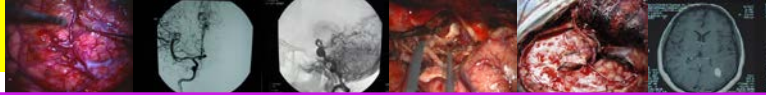






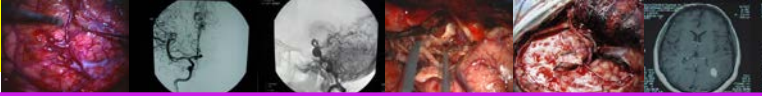
# Myelomeningcele

- The incidence is 0.7-0.8 per 1,000 live births.
- The overall lifetime mortality is 24-60%
  - Usually because of the Chiari II malformation and unrecognized shunt malfunction.
- A normal IQ is seen in 70-75% of patients.
- Roughly 60% of patients will require a VP shunt.
  - That number is significantly reduced from previous reports of close to 80%



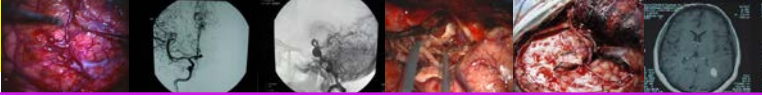
# Myelomeningocele

- There are three management schemes for myelomeningocele:
  - Initial stabilization and closure of the myelomeningocele
  - Assessment and treatment of hydrocephalus.
  - Long term management of shunt malfunction, Chiari II, tethered cord, syringomyelia



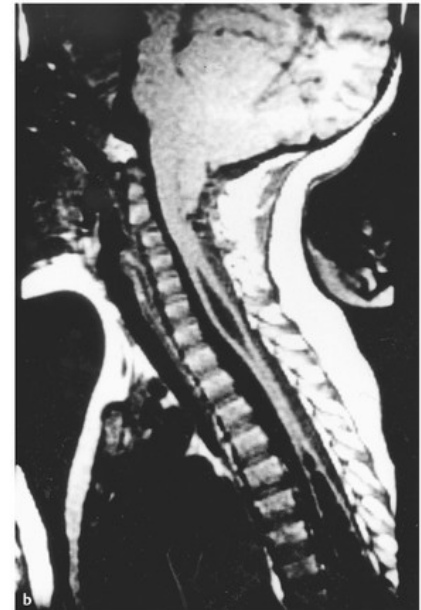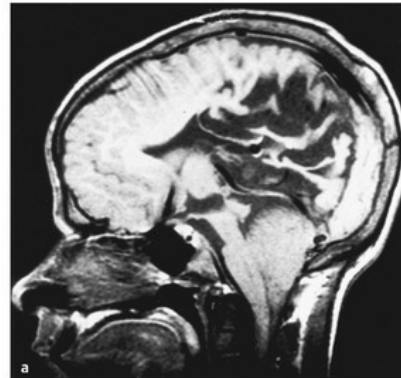
# Myelomeningocele

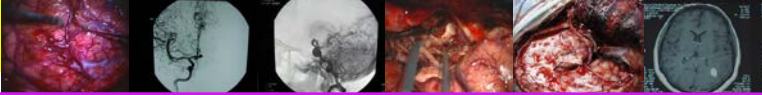
- Initial Management:
  - Closure within 48-72 hours
  - Prophylactic antibiotic coverage (ampicillin and gentamicin)
  - Head Ultrasound
  - Renal Ultrasound
  - X-ray of spine (babygram)
  - Keep the defect covered with moist non-adhesive dressing
  - Dedicated muscle group testing to determine the affected level.



# Myelomeningocele

- Chiari II malformation:
  - Caused by underdevelopment of the posterior fossa bone and crowding by the structures of the rhombencephalon (Unified Theory)
    - Herniation of the brainstem, cerebellar vermis, 4<sup>th</sup> ventricle through the foramen magnum
      - Lower cranial neuropathies
      - Swallowing dysfunction
      - Disordered breathing





# Myelomeningocele

- Prenatal closure before 26 weeks gestation compared to postnatal closure.
  - Delivered at 37 weeks
- The study showed decreased shunt rate and a better functional outcome in the prenatal surgery group.
- There was an increase in pre-term labor in the prenatal group though.

*The* **NEW ENGLAND**  
**JOURNAL** *of* **MEDICINE**

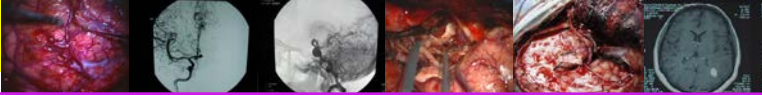
ESTABLISHED IN 1812

MARCH 17, 2011

VOL. 364 NO. 11

A Randomized Trial of Prenatal versus Postnatal Repair  
of Myelomeningocele

N. Scott Adzick, M.D., Elizabeth A. Thom, Ph.D., Catherine Y. Spong, M.D., John W. Brock III, M.D., Pamela K. Burrows, M.S., Mark P. Johnson, M.D., Lori J. Howell, R.N., M.S., Jody A. Farrell, R.N., M.S.N., Mary E. Dabrowiak, R.N., M.S.N., Leslie N. Sutton, M.D., Nalin Gupta, M.D., Ph.D., Noel B. Tulipan, M.D., Mary E. D'Alton, M.D., and Diana L. Farmer, M.D., for the MOMS Investigators\*



# Myelomeningocele

JNS PEDIATRICS

CLINICAL ARTICLE

J Neurosurg Pediatr 16:613-620, 2015

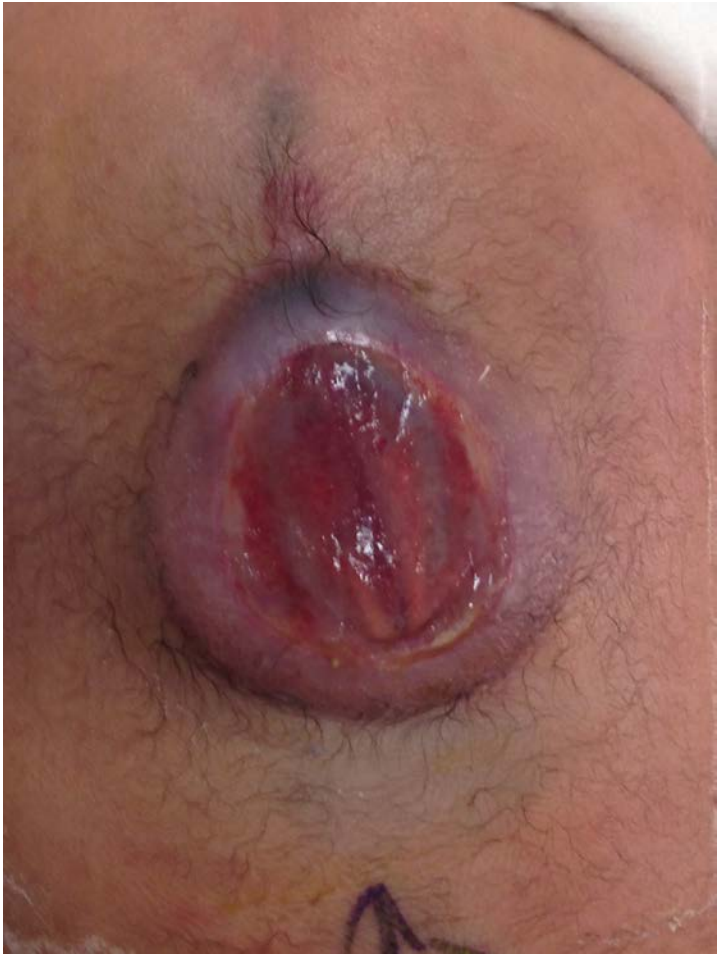## Prenatal surgery for myelomeningocele and the need for cerebrospinal fluid shunt placement

Noel Tulipan, MD,<sup>1</sup> John C. Wellons III, MD, MSPH,<sup>1</sup> Elizabeth A. Thom, PhD,<sup>2</sup>  
Nalin Gupta, MD, PhD,<sup>3</sup> Leslie N. Sutton, MD,<sup>4</sup> Pamela K. Burrows, MS,<sup>2</sup> Diana Farmer, MD,<sup>5</sup>  
William Walsh, MD,<sup>6</sup> Mark P. Johnson, MD,<sup>7</sup> Larry Rand, MD,<sup>8</sup> Susan Tolivaisa, BS,<sup>9</sup>  
Mary E. D'Alton, MD,<sup>10</sup> and N. Scott Adzick, MD,<sup>7</sup> for the MOMS Investigators

- During prenatal counseling, care should be exercised in recommending prenatal surgery when the ventricles are 15 mm or larger because prenatal surgery does not appear to improve outcome in this group.

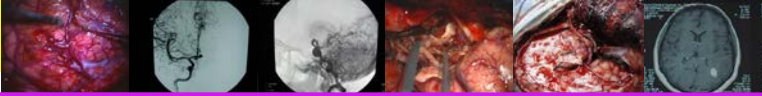


# Myelomeningocele



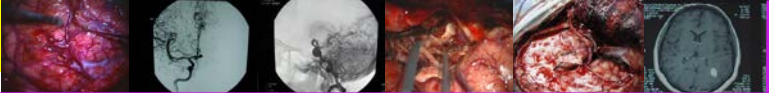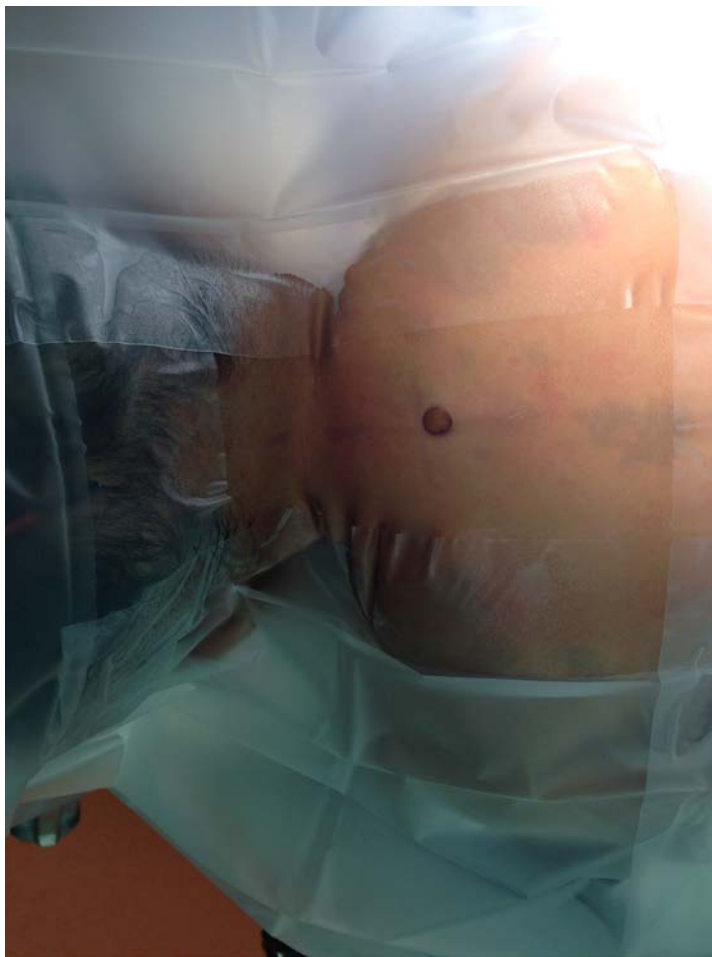
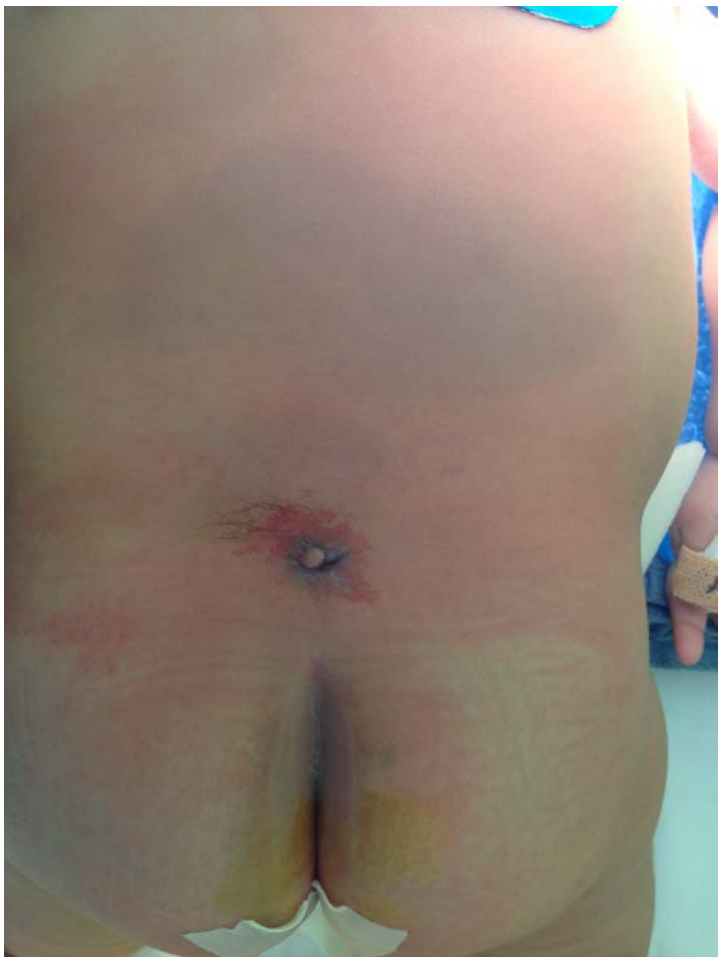

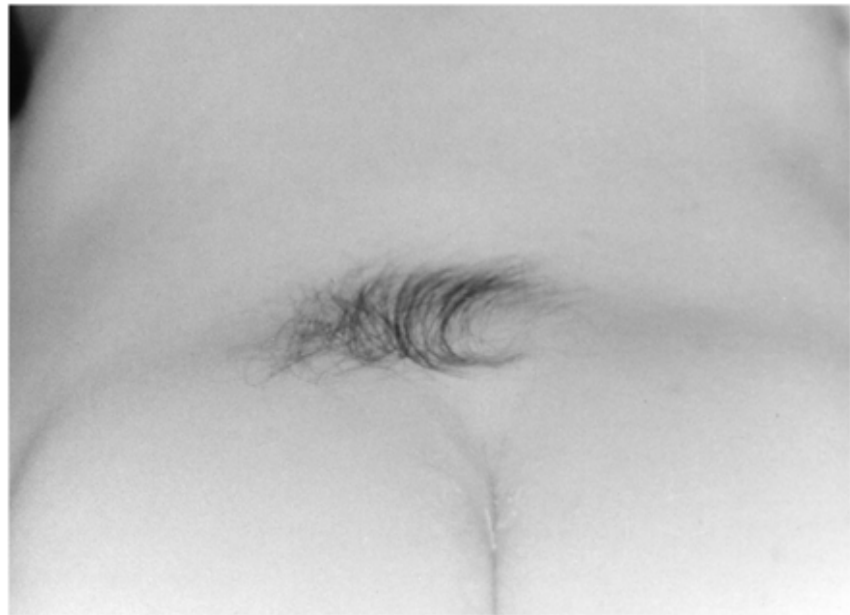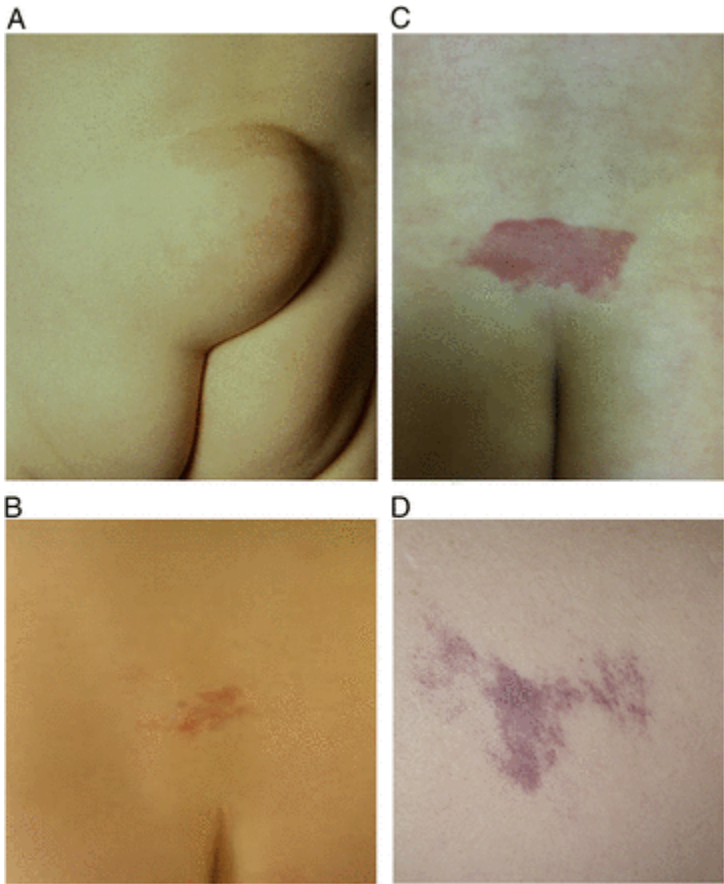
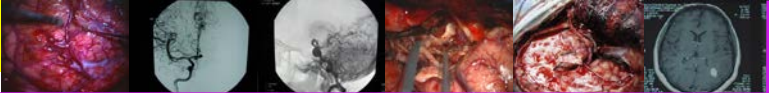
# Closed Neural Tube Defects

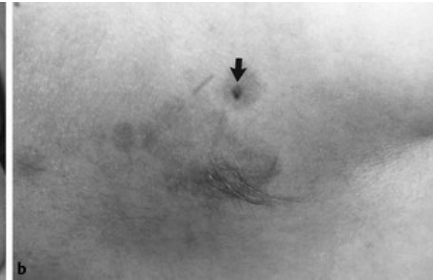
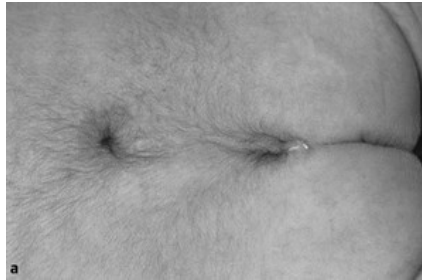
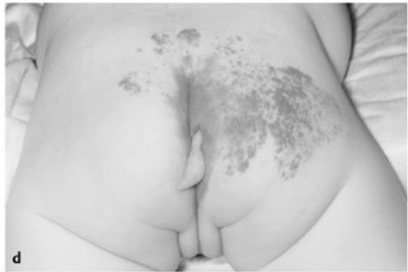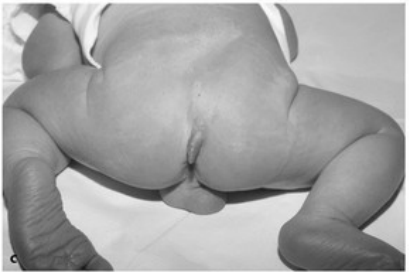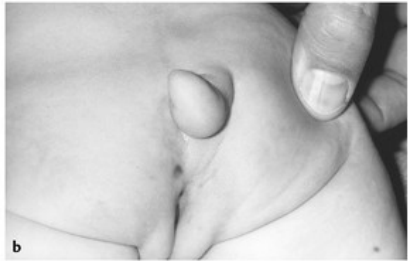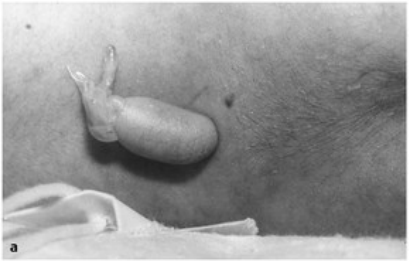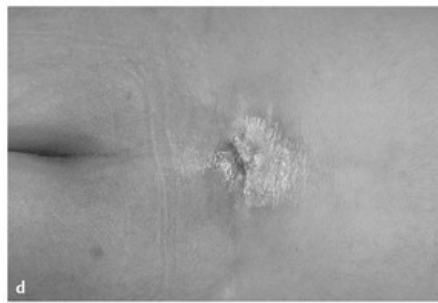
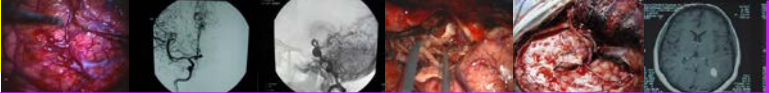
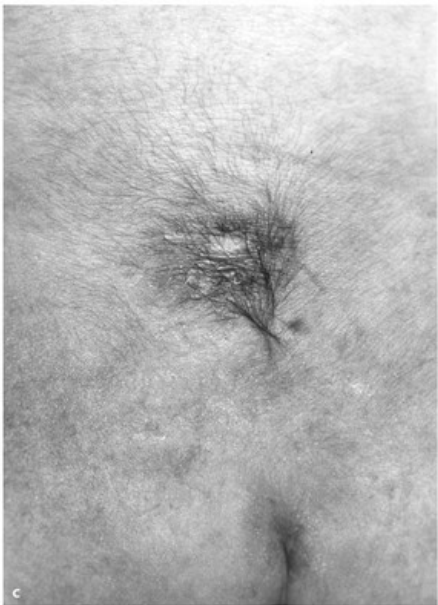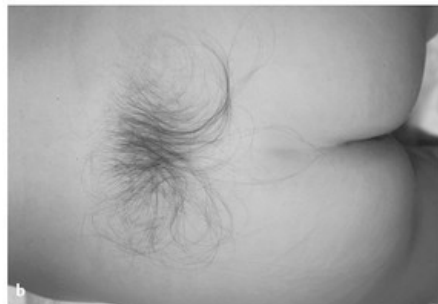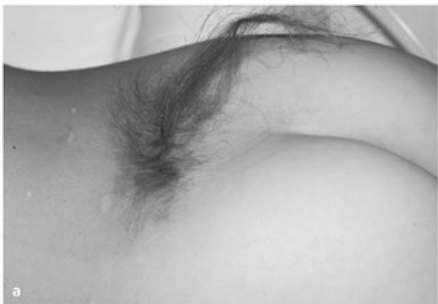# Cutaneous Markers

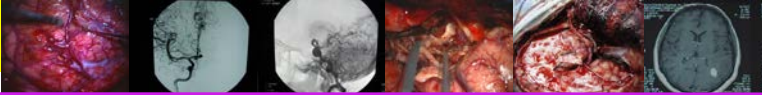
- Cutaneous markers are seen in the general population 3% of the time; however, 80% of patients with spinal dysraphism have cutaneous markers.
  - It is very common for two or more of these markers to coexist.
- Cutaneous markers occur:
  - In the midline of the back
  - Above the level of the coccyx
  - Commonly overlies the spinal lesion



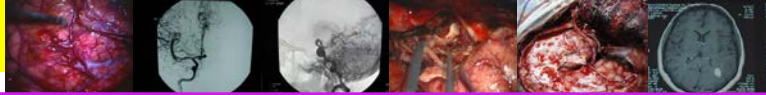




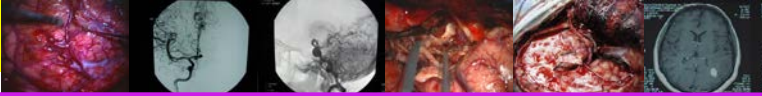




- Neurologic  
Presentation:
  - Lower extremity weakness
  - Muscle Atrophy
  - Radicular pain
  - Abnormal gait
- Orthopaedic:
  - Leg length discrepancy
  - Foot deformities
- Urologic:
  - Recurring UTI
  - Change or regression

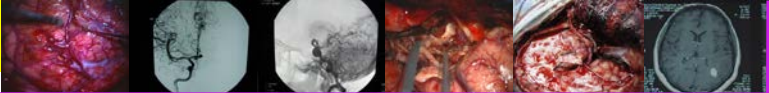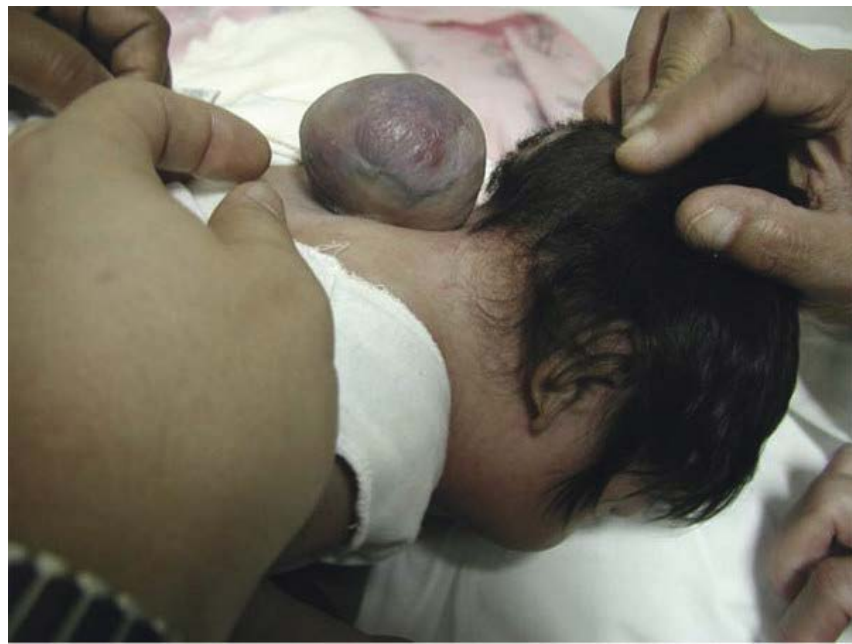
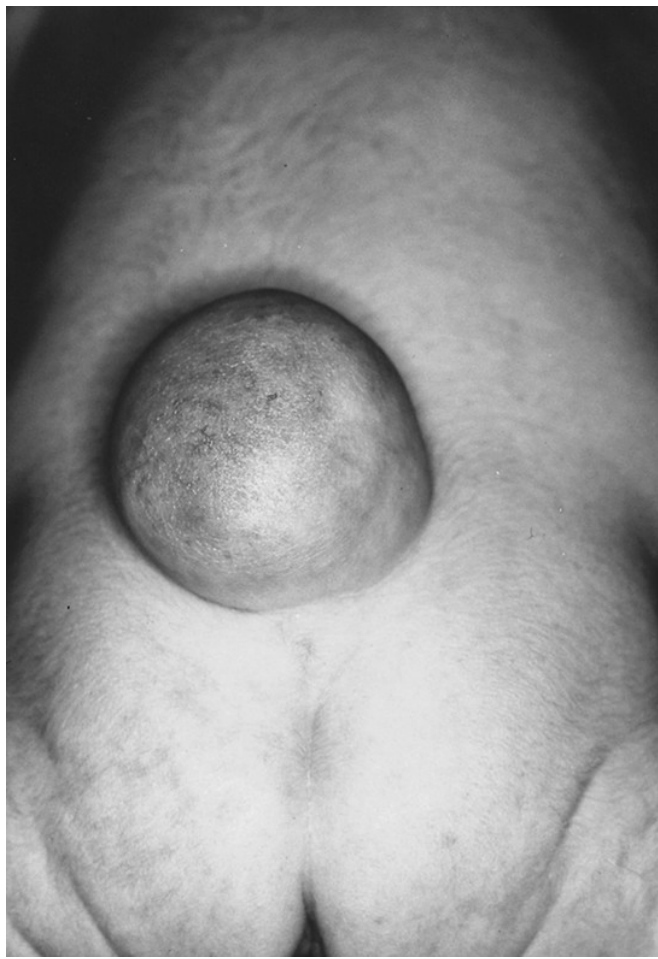

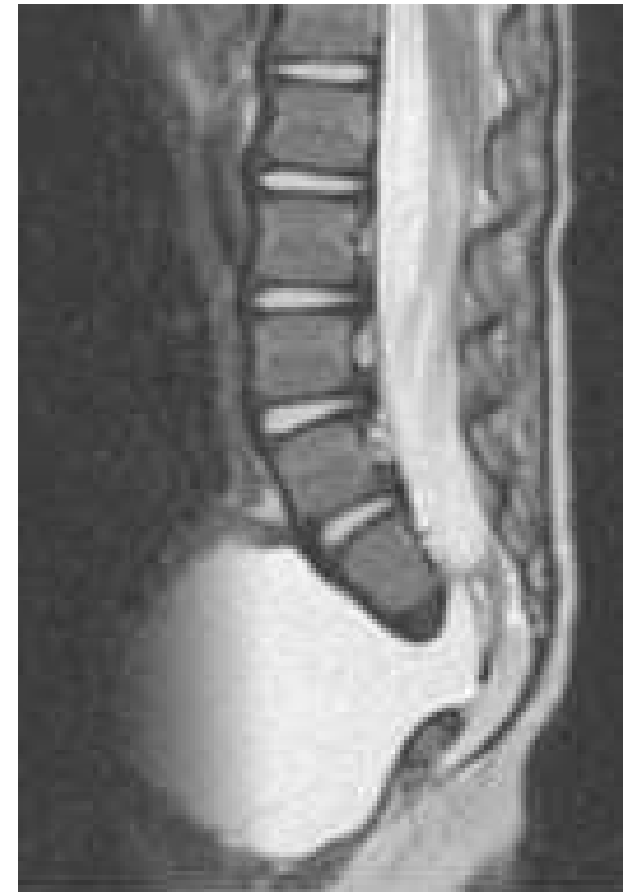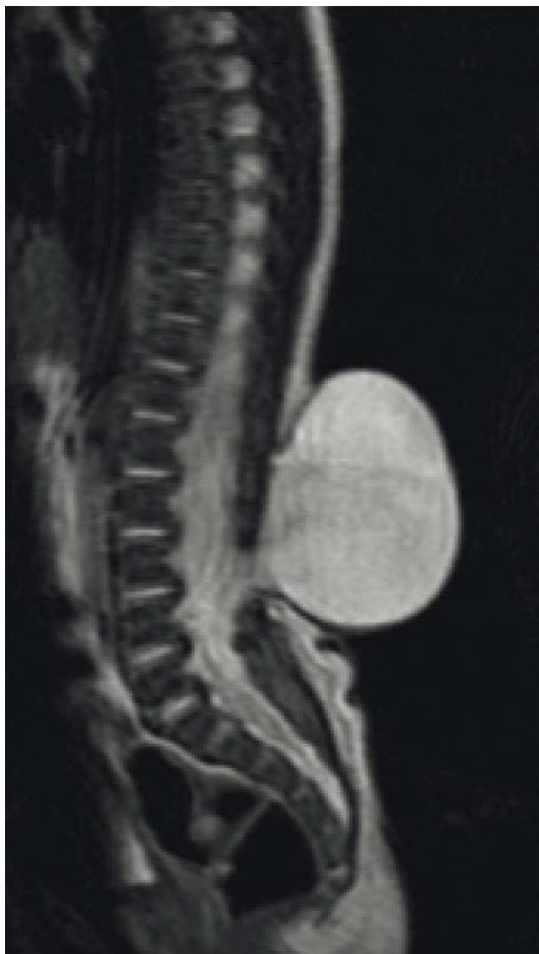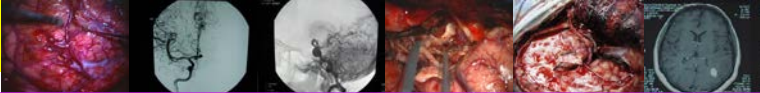
- Imaging:
  - MRI is the study of choice
  - Ultrasound can be useful to find the level of the conus in children less than 6 months
  - CT can be an adjunct in those diseases with bony abnormalities



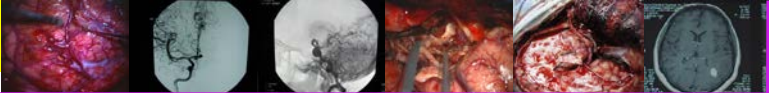
# Meningocele

- Congenital herniation of the dura and arachnoid through a bony defect in the spine.
  - Nerve roots can be involved, but typically not the spinal cord.
- Incidence is 0.3-0.4 per 1,000 births.
- Can be anterior or posterior
  - Posterior meningoceles- secondary neurulation
  - Anterior meningoceles- mesenchymal abnormalities.

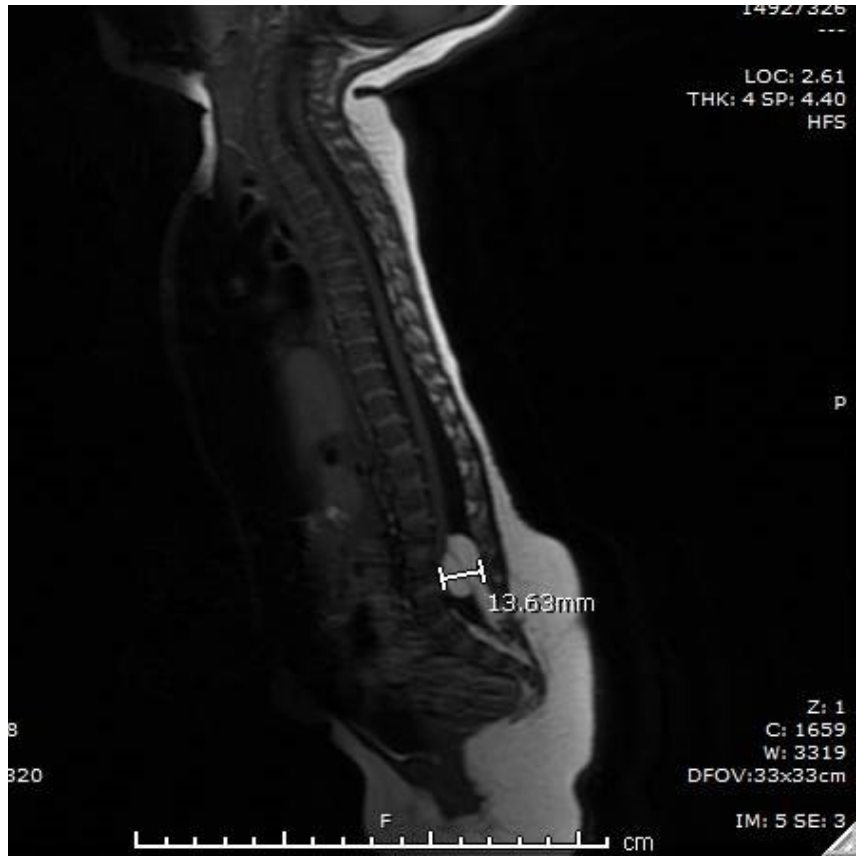
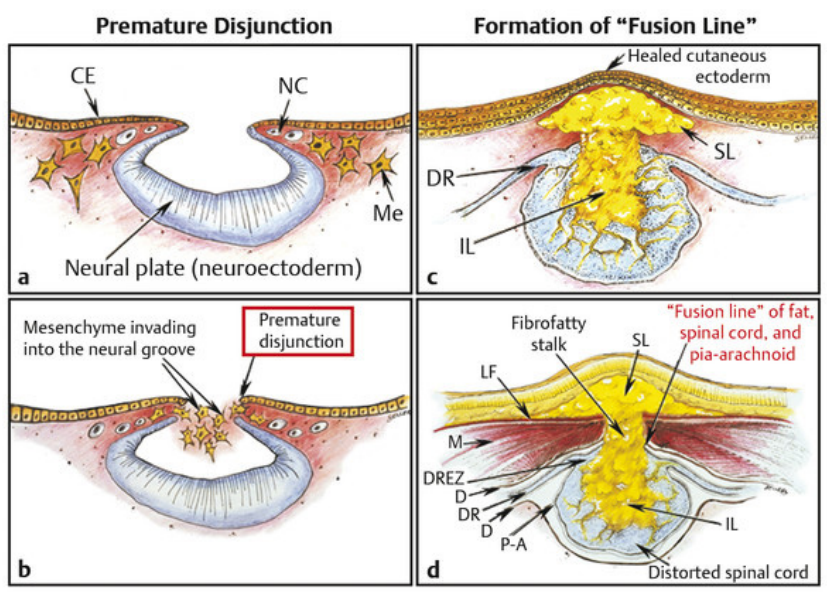


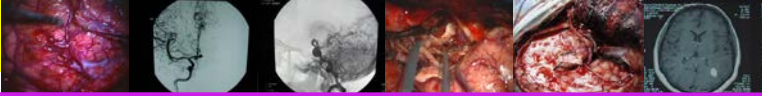


A



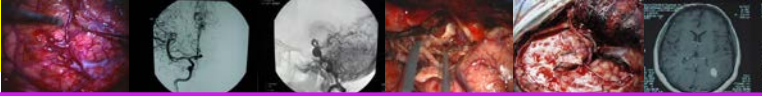
# Spinal Lipoma





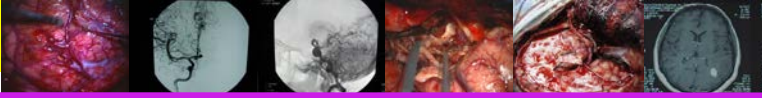
# Spinal lipoma

- Classification:
  - Dorsal:
    - Lipoma–cord interface is entirely on the dorsal surface of the lumbar spinal cord, always sparing the distal conus
  - Terminal:
    - Unlike the dorsal and transitional types, terminal lipomas insert into the caudal extremity of the conus without blending with the spinal cord or its root entry zones



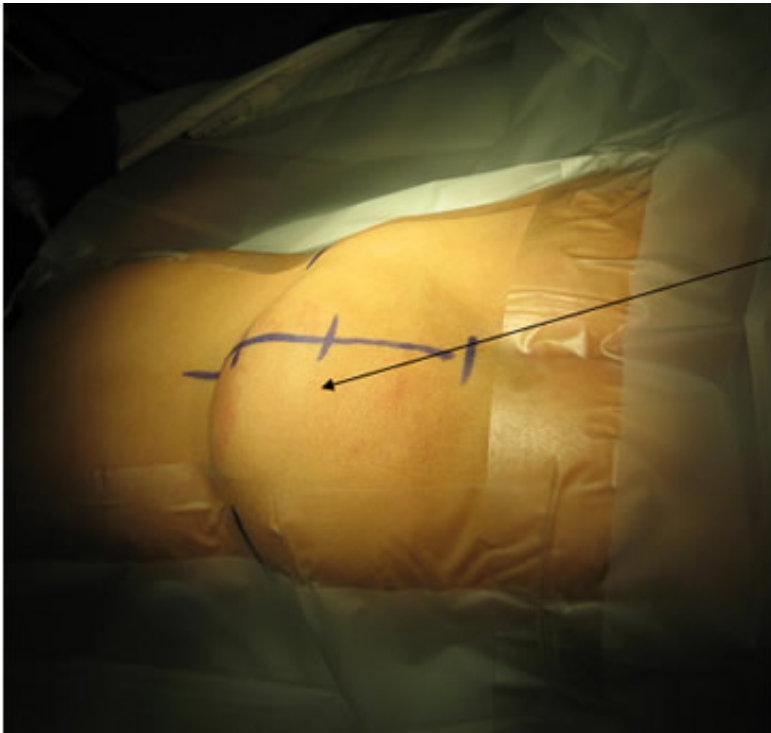
# Spinal Lipoma

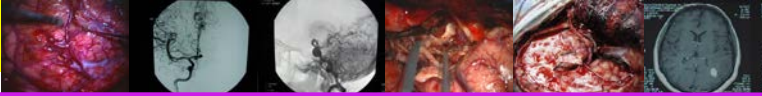
- Classification:
  - Transitional:
    - The lipoma–cord interface thus created may be undulating and tilted so that the neural placode is rotated to one side or even spun into a parasagittal edge-on orientation, but the neural tissue is always ventral to this interface
  - Chaotic:
    - Its caudal portion is *ventral* to the neural placode and does engulf neural tissue and nerve roots



# Spinal Lipoma

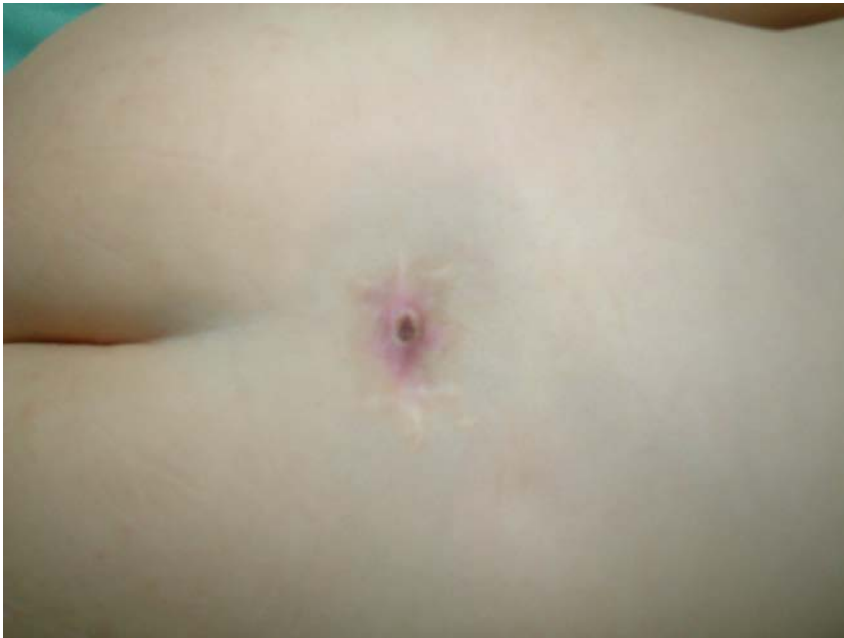- Treatment:
  - Two schools of thought:
    - Operate prophylactically to prevent symptoms.
      - Usually around 3 months of age
      - Preferred method in America
    - Wait until the patient is symptomatic.
      - Preferred method in Europe

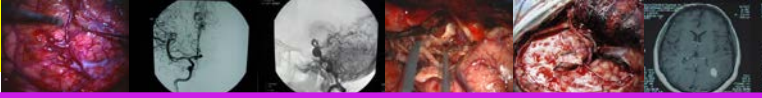




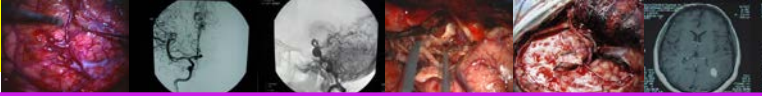
# Dermal Sinus Tract

- Usually seen in one in every 2500 births.
- Children are usually neurologic normal at birth but there is increased risk of deficit with age if untreated

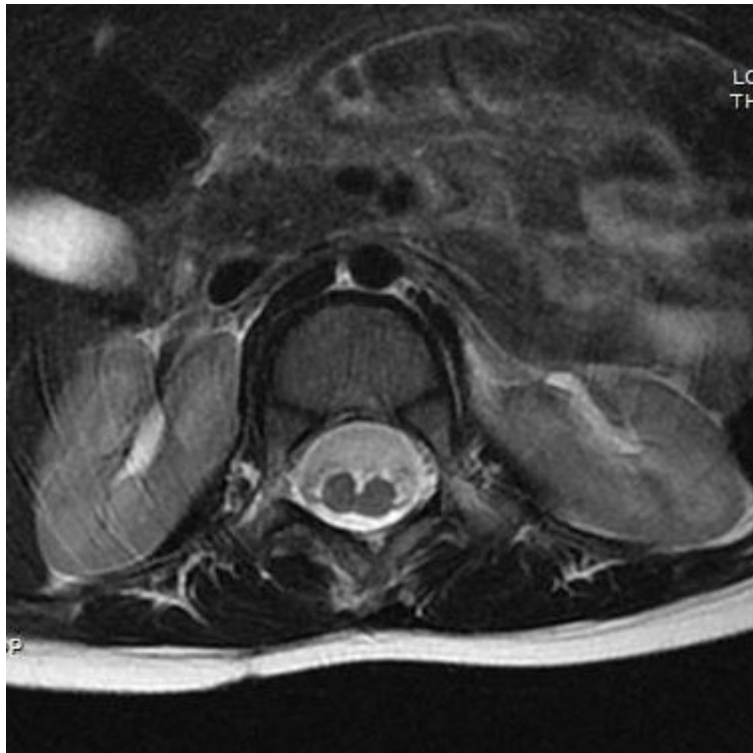



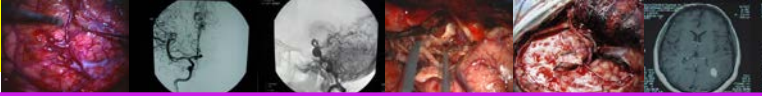
- Although there is no consensus about the timing of surgery in uncomplicated, asymptomatic patients with dermal sinus tracts, it seems logical to proceed with surgery whenever the infant is physiologically ready for the procedure.



# Split Cord Malformation

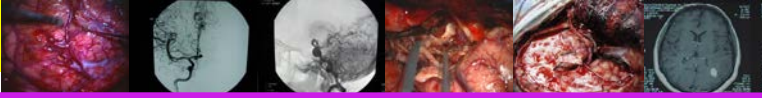


- SCMs can be divided into two main types, classically termed *diastematomyelia*.
- Usually present with a Faun's tail.



# Split Cord Malformation

- Type 1 SCM consists of two hemicords separated by an osteocartilaginous median septum, each housed in a separate dural sheath.
- Type 2 SCM consists of two hemicords contained within the same dural envelope and separated by a fibrous septum.



Thank you