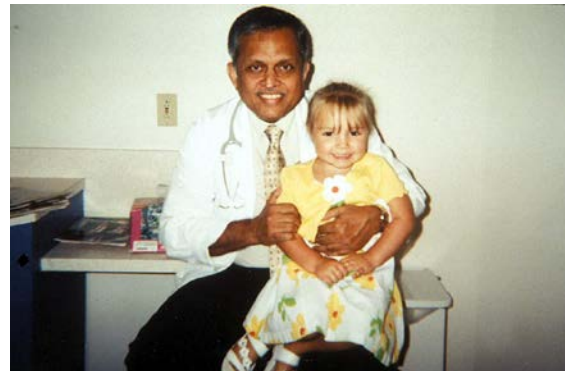

Evaluation Of Bleeding Disorders /AAP Baton Rouge

Raj Warriar

Evaluation and approach to management of a bleeding child



Raj Warriar
Ochsner /Tulane/LSU
Manipal University
University Of Queensland

Objectives

- Describe the physiologic process of blood clotting
- Summarize the importance of accurate history, through P/E and basic clinical lab test in making a diagnosis
- List common and severe bleeding disorders in Children
- Formulate plans for referral and continued care

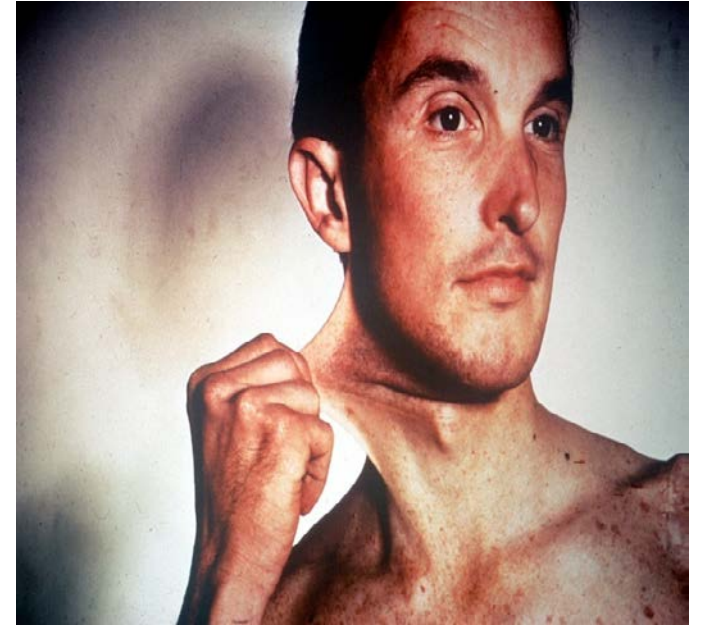- No conflict of Interest

Disclosure

- Nothing to disclose in relation to this presentation at this time

Coagulation

- Vessel wall
- Platelets
- Coagulation cascade
- Fibrin clot
- Fibrinolysis



Bleeding Vs. Thrombosis

Bleeding

- ↓ Procoagulant factors (e.g. F II, V, VII, VIII, IX, X, XI, XII)
- Thrombocytopenia
- Vessel wall damage
- ↑ Fibrinolytic potential (↑ tPA or plasminogen or ↓ inhibitors)

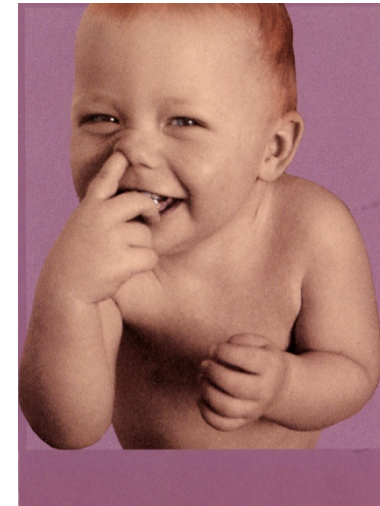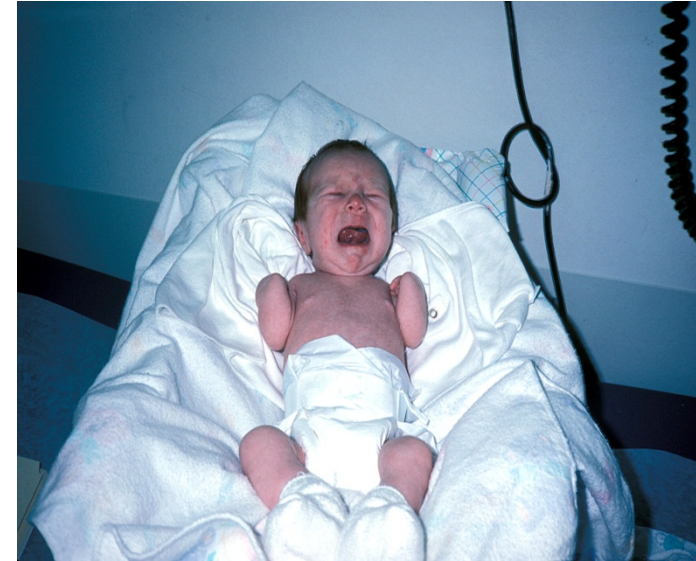Thrombosis

- ↑ Procoagulant factors (e.g. F II, V, VII, VIII, IX, X, XI, XII)
- ↓ Natural anticoagulants (AT, Protein C, S)
- Thrombocytosis
- Vasculitis
- ↓ Fibrinolytic potential

Abnormal Bleeding

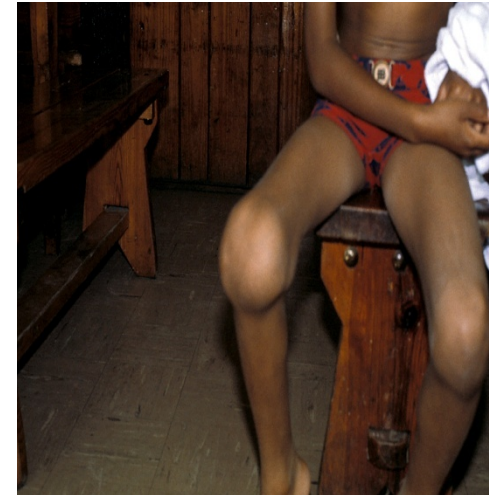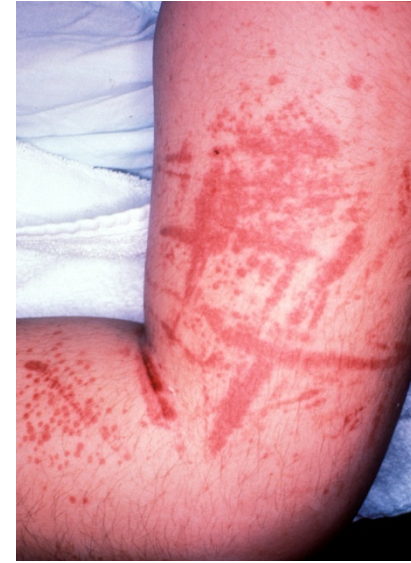History

- Spontaneous Vs Induced
- Congenital Vs Acquired
- Nature and site of bleeding
- Circumcision, dental extraction
- Epistaxis, Menorrhagia



Abnormal Bleeding

- Hemarthrosis, hematoma - FVIII, IX
- Petechial, mucosal bleeds
 - Platelets
 - Vascular
 - Aspirin



Family History

X-Linked Recessive -
FVIII, IX

VWD - auto dominant

Females with
Hemophilia – Turner's,

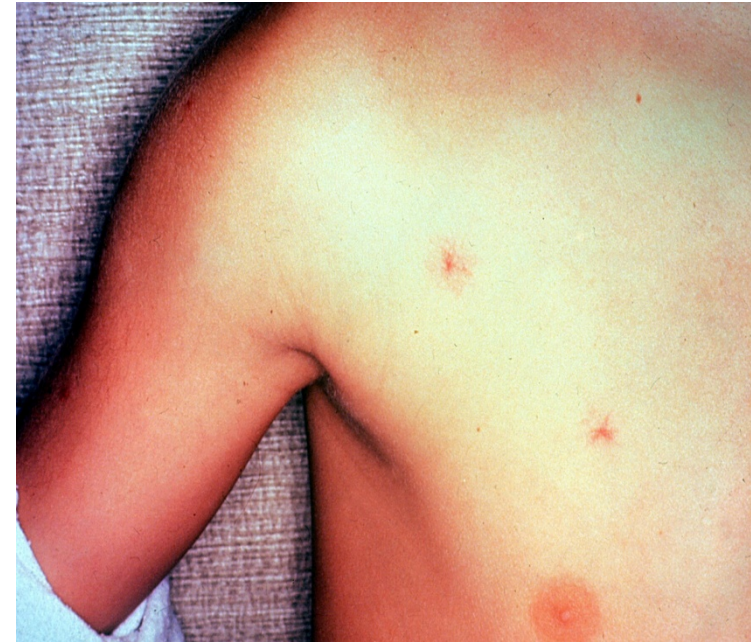Lyon's Hypothesis,

Testicular Feminization,

Carrier and patient
having a baby!

Physical Examination

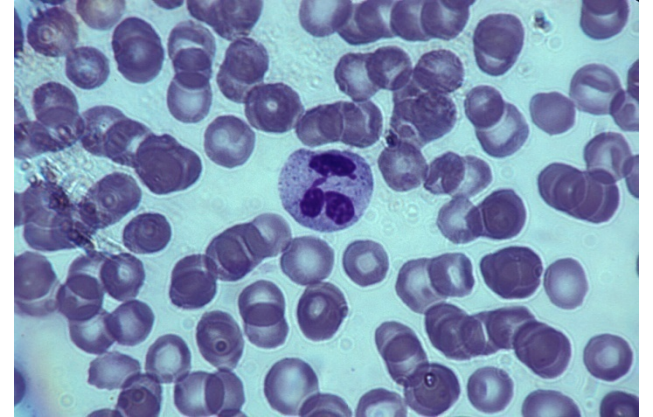
- Pallor
- Organomegaly
- Adenopathy
- Hemarthrosis
- I.C. Hge



Laboratory

Screening Tests

- CBC, Smear
- Platelet count
- B.T- not popular
- PFA
- P.T., P.T.T,



Lab - confirmatory

- Prolonged PTT work up –

Dilution or mixing studies

Lupus anticoagulant

DRVVT , PNP

Self limited , no risk of bleeding

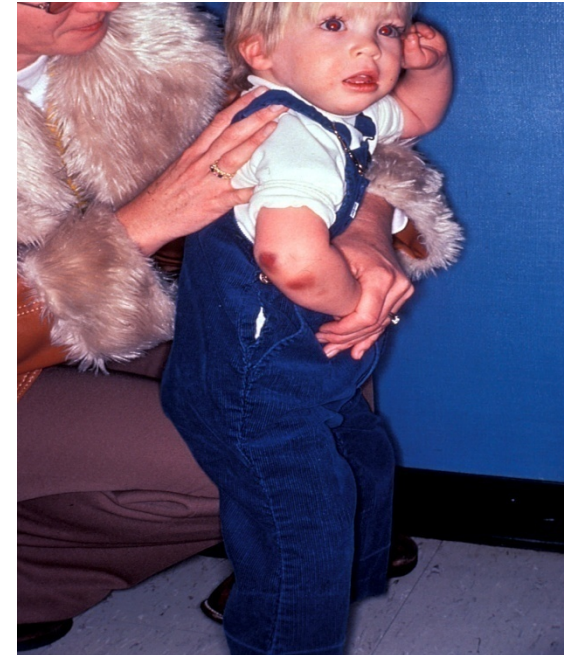?Hypercoagulable

Lab - confirmatory

- Factor assays - VIII, IX
- Platelet aggregation - VWD
- Fibrinogen, FSP, smear
D-Dimer -DIC
- vW Antigen, vW activity
Ristocetin Co-Factor
- vW Multimer
- Genetic study
- Bone Marrow
- Call your friendly Peds
Hematologist

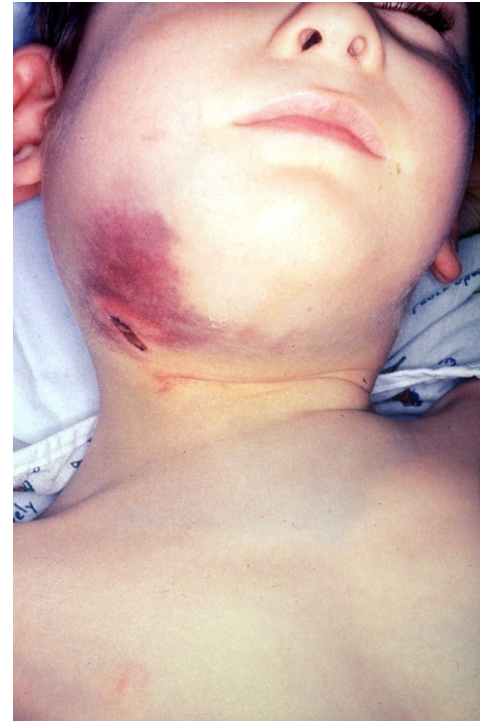Case Studies

- Family H/O maternal uncles, easy bleeders
- Hemarthrosis
- Normal CBC, Platelets, PT
- Increased PTT
- Dx – Factor 8 or 9 deficiency



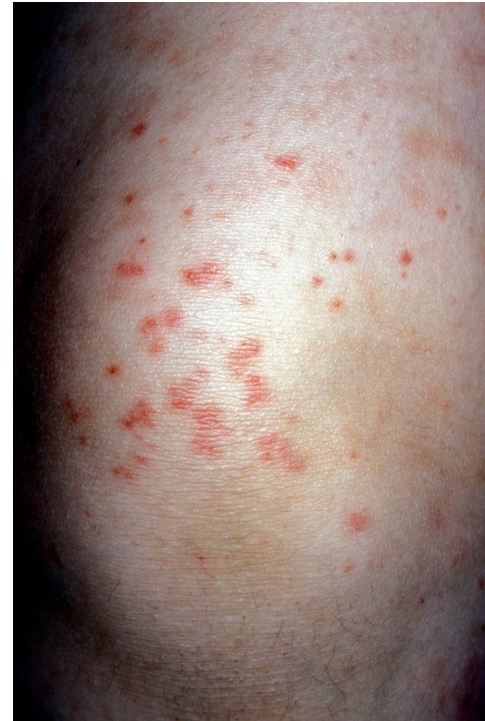Case Study

- Boy 16 yrs old, Bleeding following T &A
- Increased PTT, Normal CBC, Plts, PT
- DX-? VWD, Mild Factor 8 deficiency



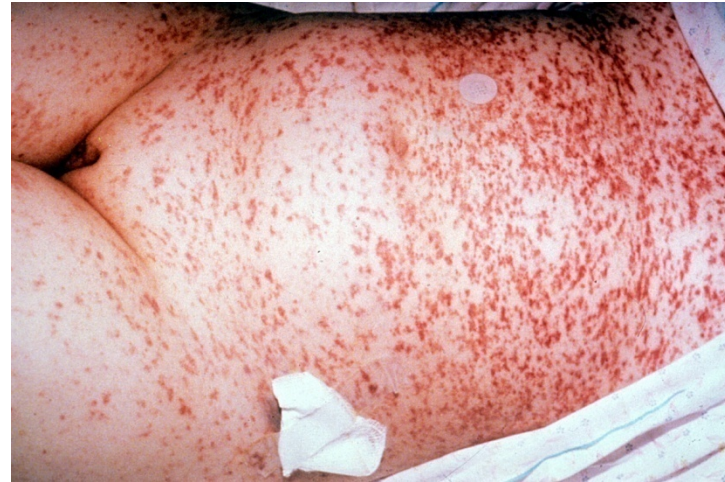- 14 year old white female
h/o antipyretics
- Mucosal bleeding
- Normal PT, PTT
- High BT, Normal CBC
- Further tests? Diagnosis?

Case Study (B)



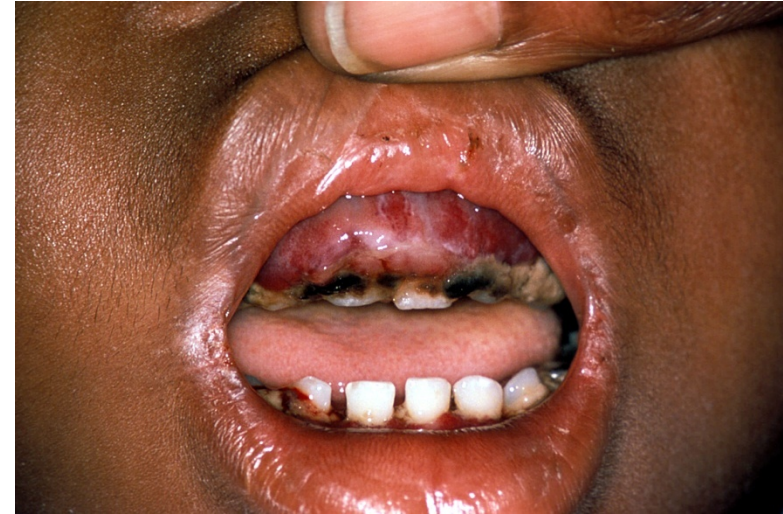Case Study

- 6 yr old white female
- Acute onset of
Petechia, Purpura
- H/O viral infection
- Normal CBC, platelet -
low
- Mega thrombocytes +
- ? Bone marrow
needed - DX ?



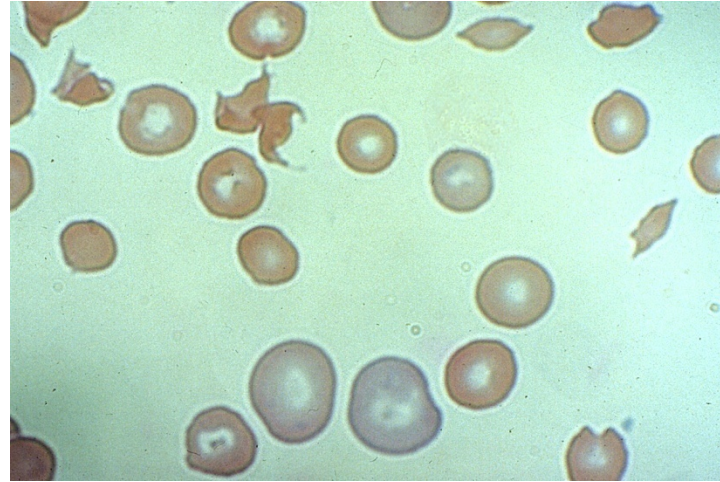
D/D Bleeding

- Leukemia, malignancies
- DIC - Sepsis
- HSP
- EBV - Thrombocytopenia
- Vasculitis - SLE
- Drugs
- Aplastic or Hypoplastic



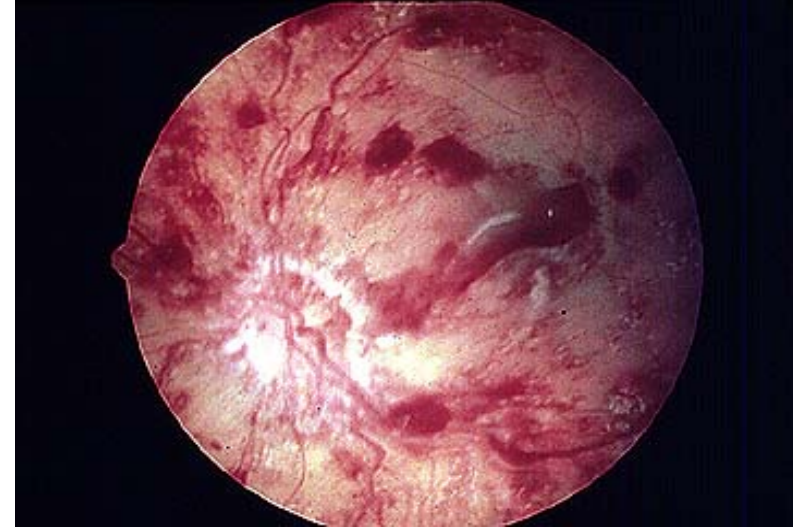D/D Bleeding disorders

- ITP
- TTP
- HUS
- Storage Disorders
- Hemangiomas – Kasabach-Merritt
- Child Abuse

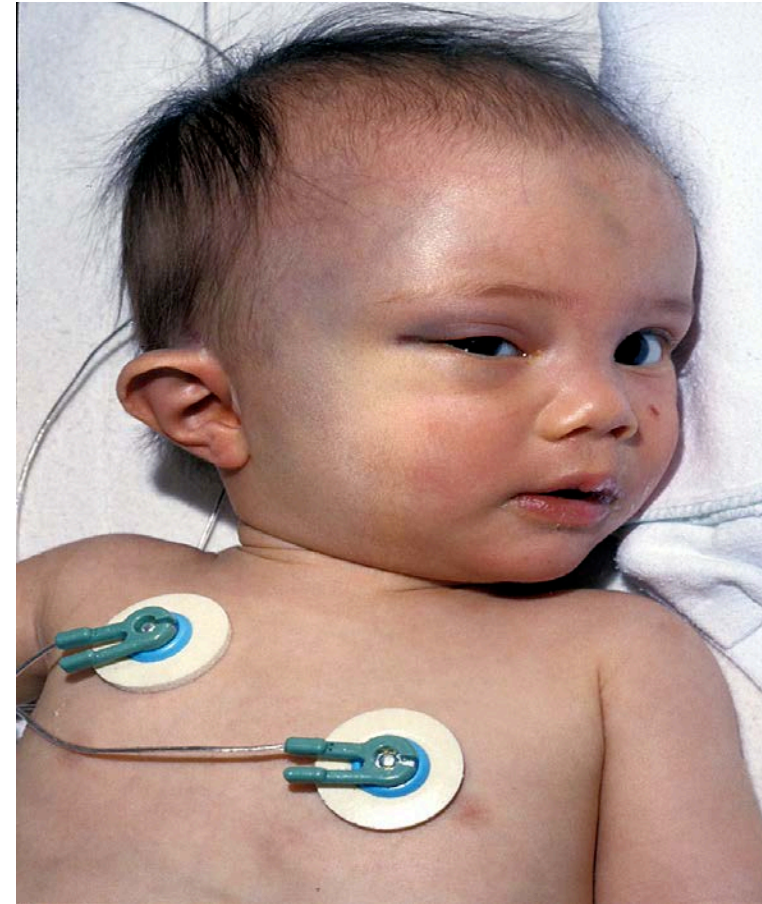
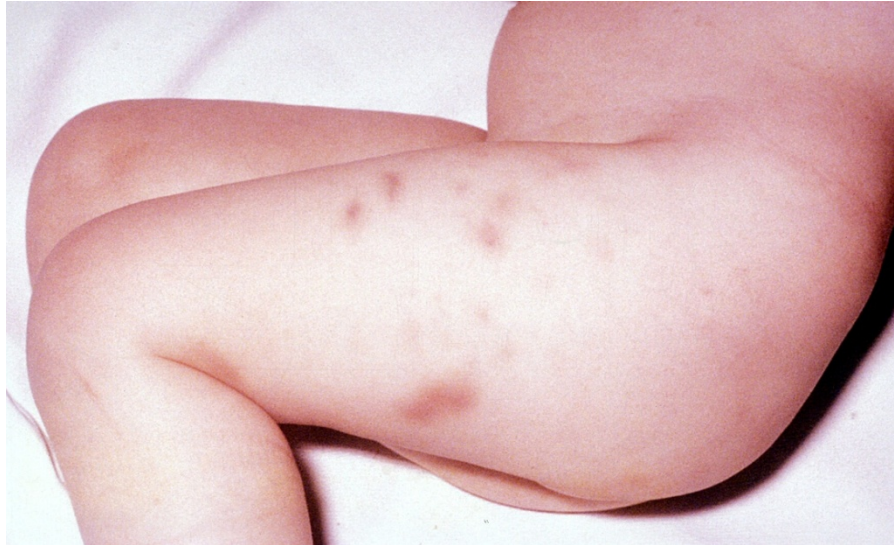
Retinal hemorrhages:

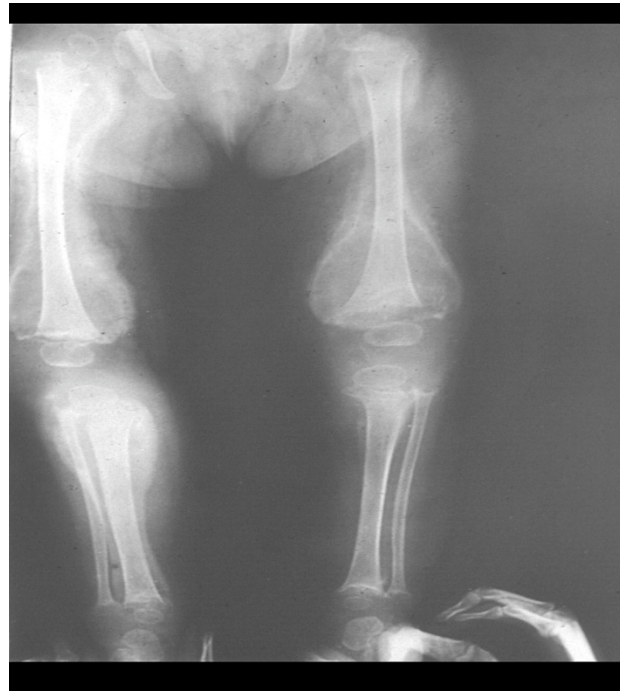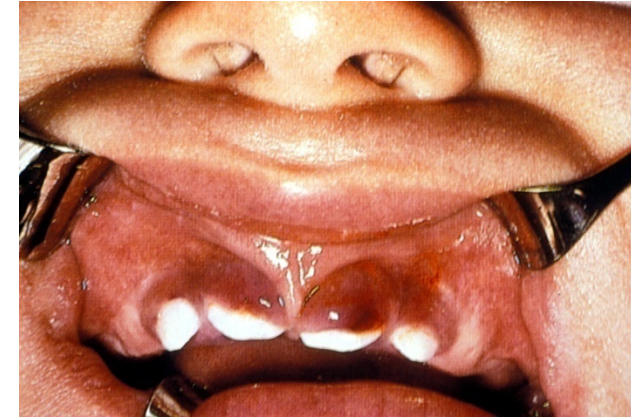
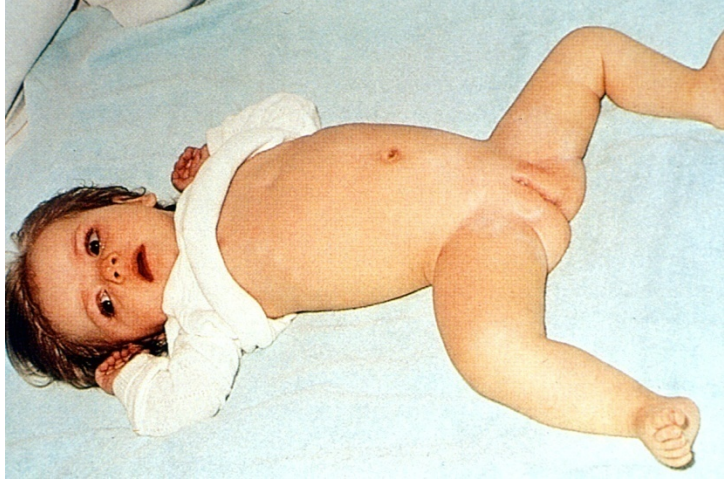- Extraordinary force
- Unilateral or bilateral hemorrhages are present in 75-95% of abusive head trauma
- Common with birth trauma but resolve within 4 weeks
- Other causes of retinal hemorrhages include: hematologic abnormalities, central nervous system vascular malformations, infections, high-altitude mountain climbing, during normal deliveries of newborns, and as a complication of general anesthesia
-



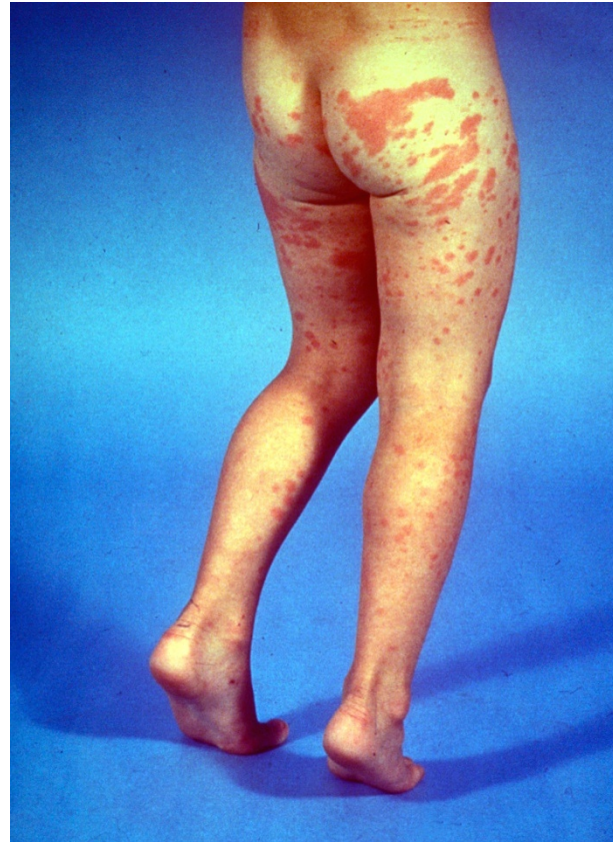Referred ?? bleeding disorder



Bleeding from gums, Pseudo paralysis

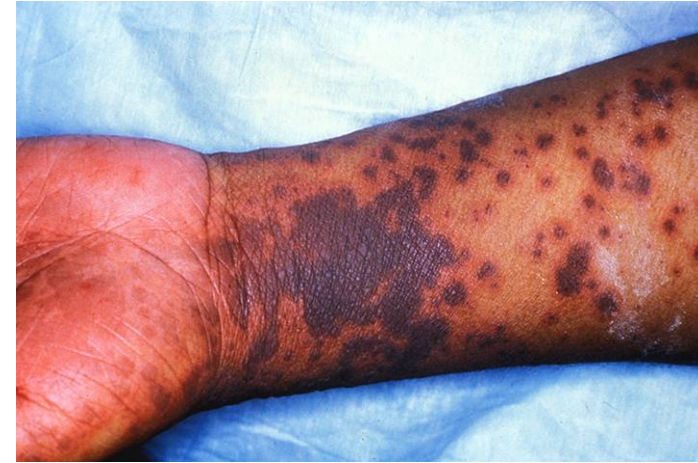

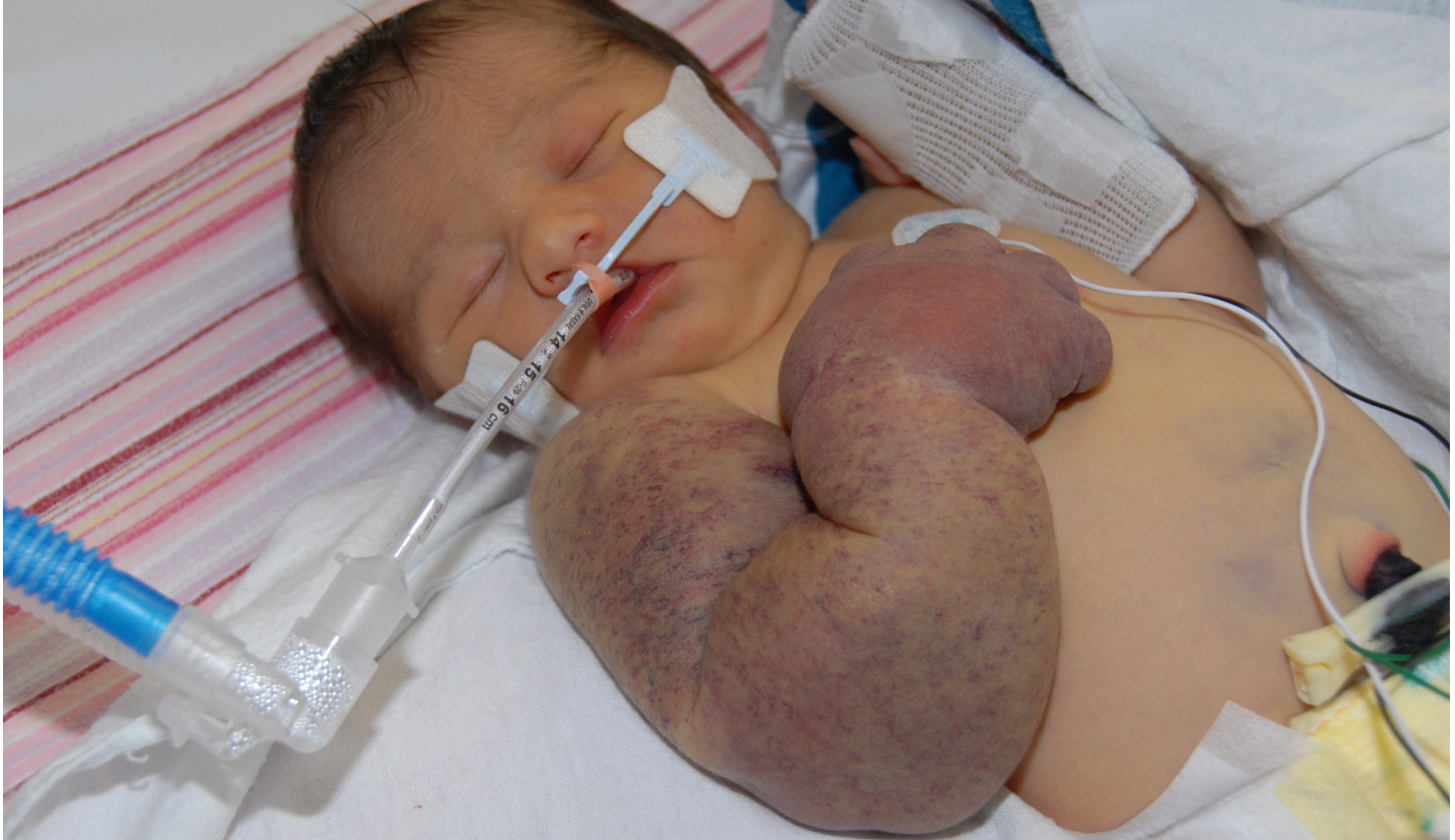Hematuria, arthropathy



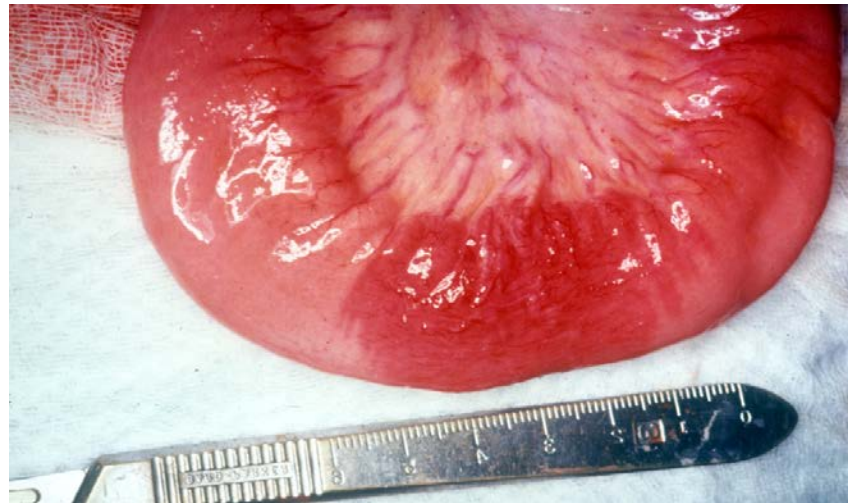
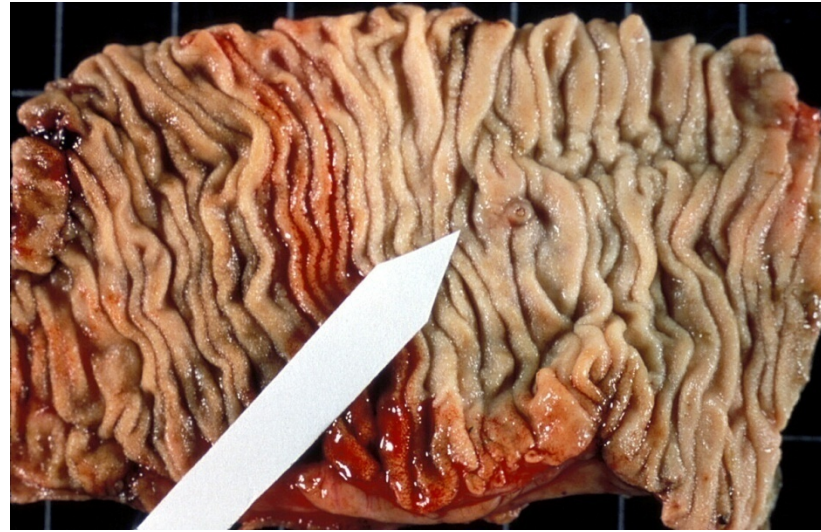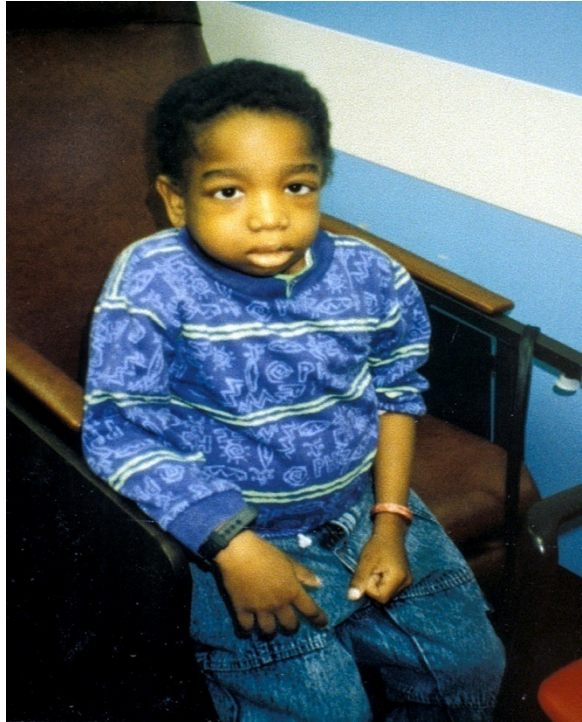Toxic child in ER

- 2yr old with h/o fever for 1 day
- Toxic, hypotensive
- Hb 5 gms, platelets 21000
- Review smear

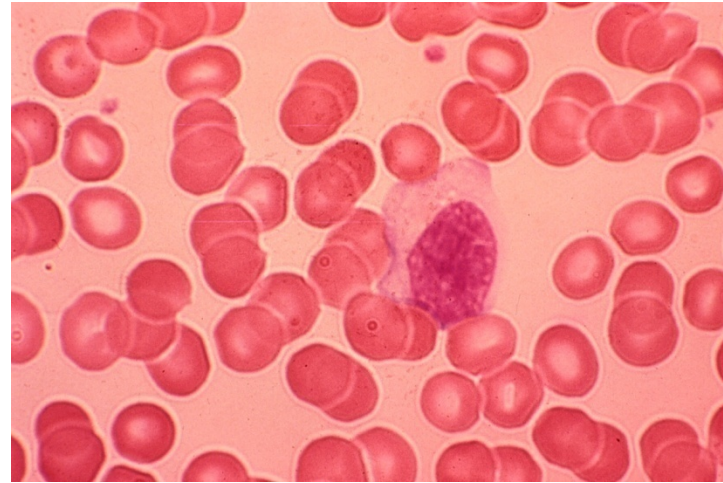
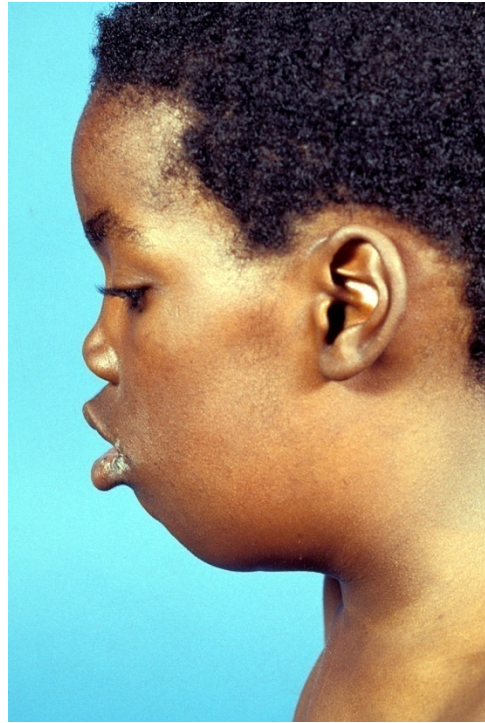




GI Bleed- less common

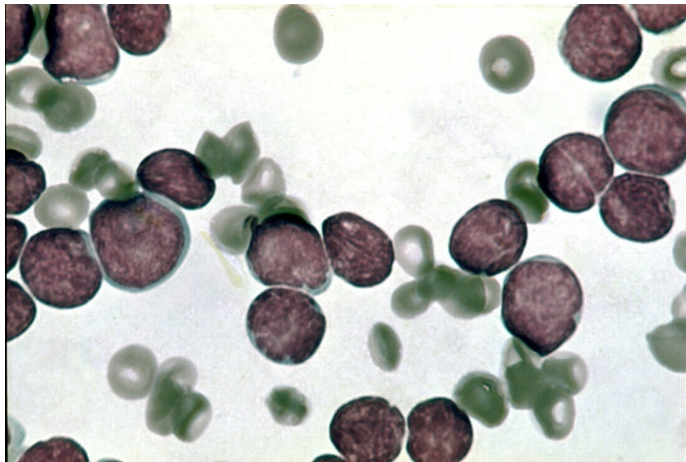


Fever, Lymphadenopathy,
Pharyngitis, abnormal smear!

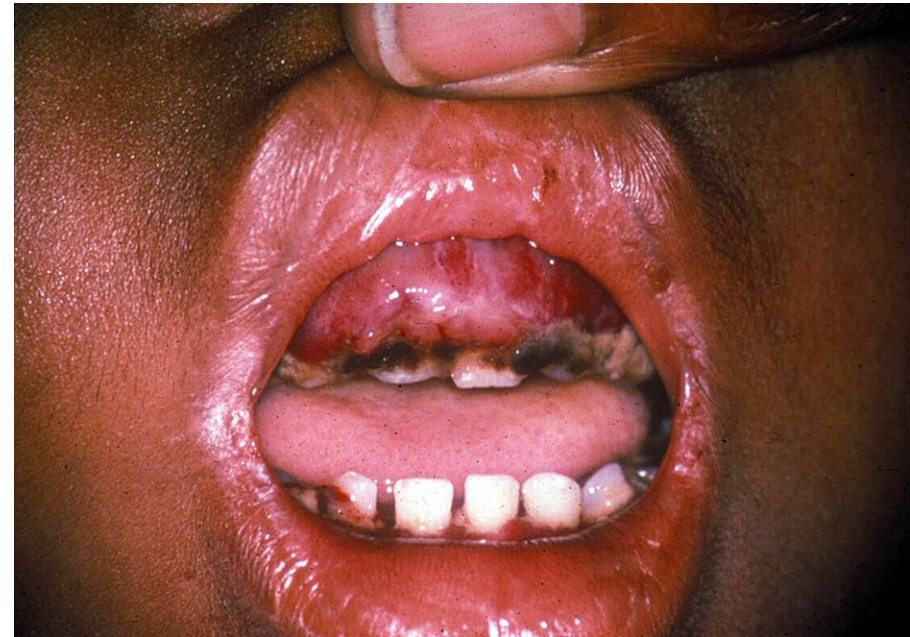
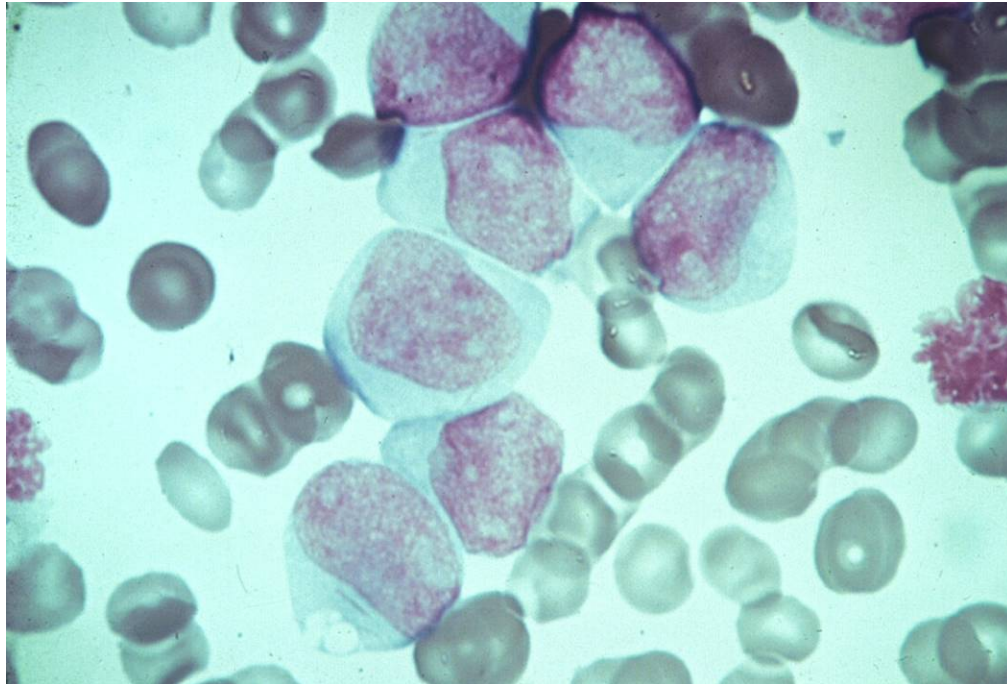
Beware of fever with bone pain!

- 8 yr old AA female
- Fever x 2weeks
- Joint pain
- Bleeding from gums
- Easy bruising



- Fever
 - Bone pain and joint pain
 - Weight loss
 - 14 yr old AA male
- # Bone pain again!

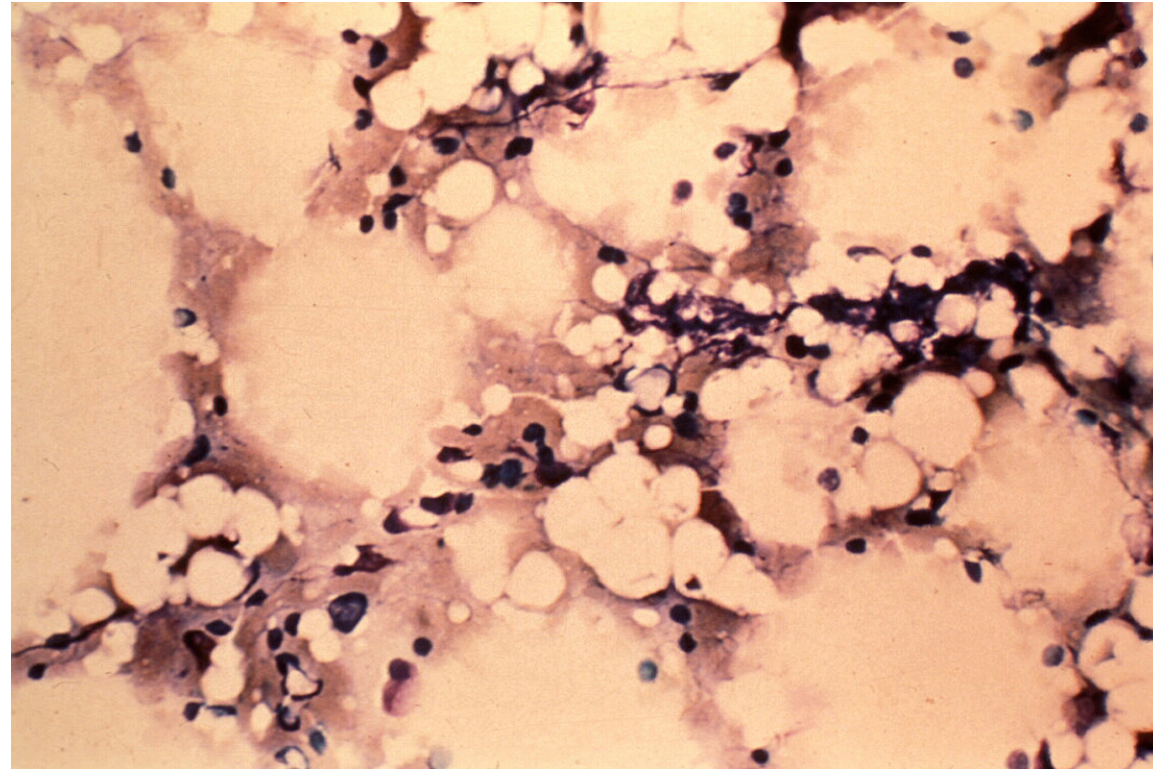


CASE 4

A 12 years old boy with progressive pallor, bruising ,no HSM

Parameter	Report
Hb	5.6 g%
TLC	2600
DLC	N34, L56, E5, M5
Platelet count	30,000 /cu.mm
MCV	114
MCH	28.4
MCHC	33.1
RBC count	1.7 million/cu.mm.
RDW-CV	21.5

Bone marrow- pt with pancytopenia



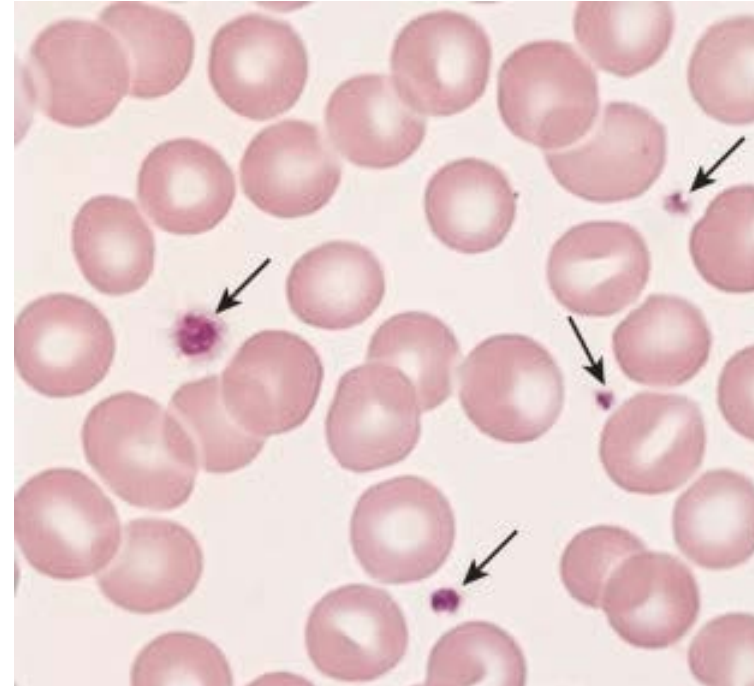
NEWER CBC PARAMETER

- Immature platelet fraction
- Immature granulocytes
- Immature reticulocyte fraction
- Red cell fragments/ Schistocytes
- Reticulocyte hemoglobin



Mean Platelet Volume (MPV)

- Normal MPV - 7 to 11 fL
- Platelets newly released - larger in size
- Platelets decrease in size with aging
- High MPV
 - Rapid turnover of platelets (ITP, TTP)
 - Bernard Soulier syndrome
 - MYH9- related thrombocytopenias [May-Hegglin anomaly, Sebastian platelet syndrome, Fechtner syndrome and Epstein syndrome]
- Low MPV
 - Wiskott Aldrich syndrome
 - X linked thrombocytopenia



Immature Platelet Fraction (IPF)

- Quantified by flow cytometry using any fluorescent dye that binds RNA
- Newly released, larger and more reactive
- Reflects the rate of thrombopoiesis
- Usual reference range: 1 – 7%

Immature Platelet Fraction (IPF)

Low IPF → Decreased Production

- Aplastic anemia
- Leukemia
- Marrow suppression
- Drugs

High IPF → Increased Destruction / Regeneration after suppression

- Immune Thrombocytopenia (ITP)
- Thrombotic Thrombocytopenic Purpura TTP
- Disseminated intravascular coagulation (DIC) – Drugs

CASE 5

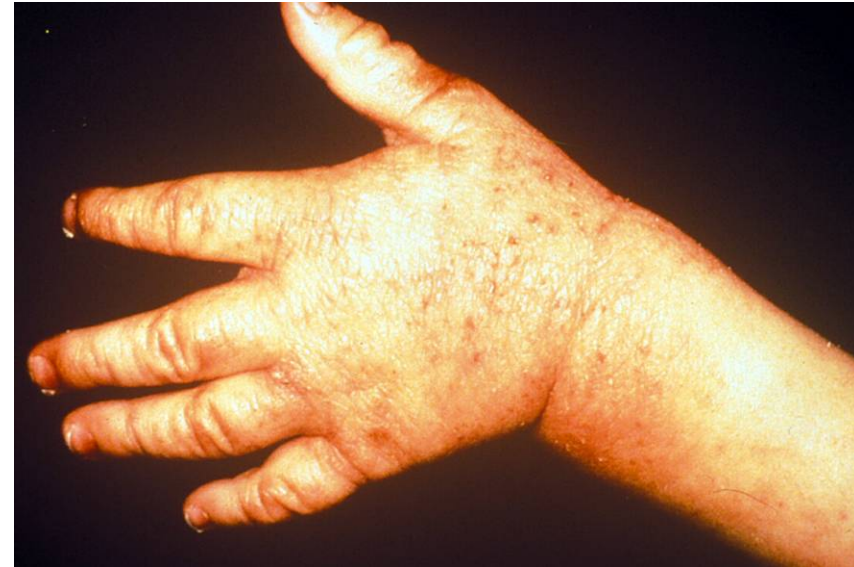A 3 years old boy presented with recurrent history of epistaxis, gum bleeds and petechial spots since past 1 year.

H/O recurrent respiratory tract infections, skin infections present.

Parameter	Report
Hb	10.6 g%
TLC	6600
DLC	N44, L46, E5, M5
Platelet count	10,000 /cu.mm
MCV	84
MCH	29.4
MCHC	33.1
RBC count	3.7 million/cu.mm.
RDW-CV	14.5
MPV	5.6 fL

Recurrent infections and cancer

- 2 yr WM, h/o recurrent pneumonia, persistent skin rash and lymphadenopathy. Platelets 40,000.
- Small platelet size MPV
- A male sibling died of septicemia 4 years ago. Skin tests for mumps, Candida and PPD are negative



CASE 6

A 7 years old boy admitted with Dengue Hemorrhagic fever

Afebrile, Hemodynamically stable

No bleeding complaints currently

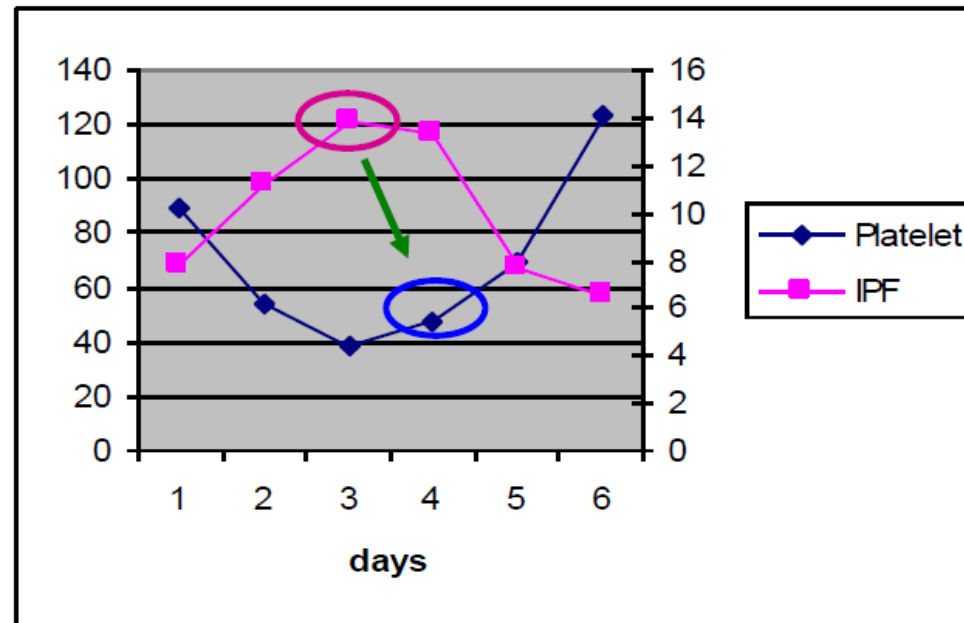
Parameter	Report
Hb	10.6 g%
TLC	4600
DLC	N34, L56, E5, M5
Platelet count	10,000 /cu.mm
IPF (Immature platelet fraction)	24% (Ref: 1 - 7)

Will you transfuse the child?

Immature Platelet Fraction (IPF)

- During regeneration phase, IPF rises 1–2 days prior to the platelet count rise.

DAYS	1	2	3	4	5	6
PLATELETS	89	54	39	47	70	123
IPF	7.8	11.2	13.9	13.3	7.7	6.5



Platelets

- Pseudothrombocytopenia
- Small platelets /low plts -
 - Hyoplastic and aplastic BM
 - Wiskott Aldrich Syndrome
 - X linked thrombocytopenia
 - THC 2 (ANK RD26)
 - Familial Plt disorder with predisposition to AML
 - (FPD/AML)

Platelets

- Large Platelets

ITP , Auto immune

BS , Grey plt syndrome

Type 2 B vWD

May Hegglin anomaly

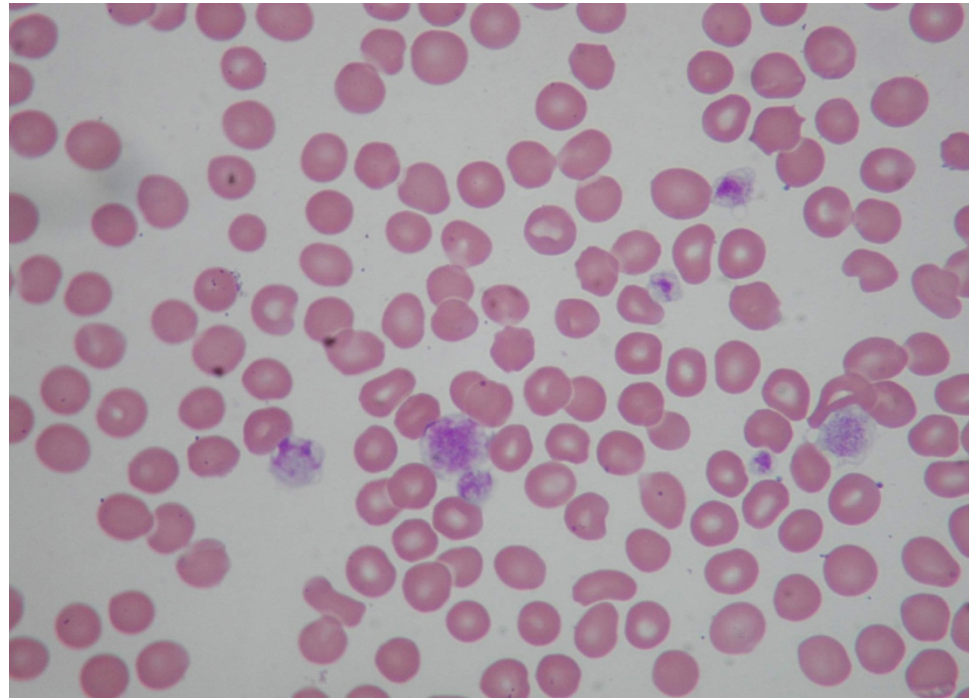
Di George syndrome , Epstein Syndrome

Sebastian Syndrome , Jacobsen Syndrome

Familial Mediterranean macrothrombocytopenia

H/O Nose bleeding, bleeding after extractions

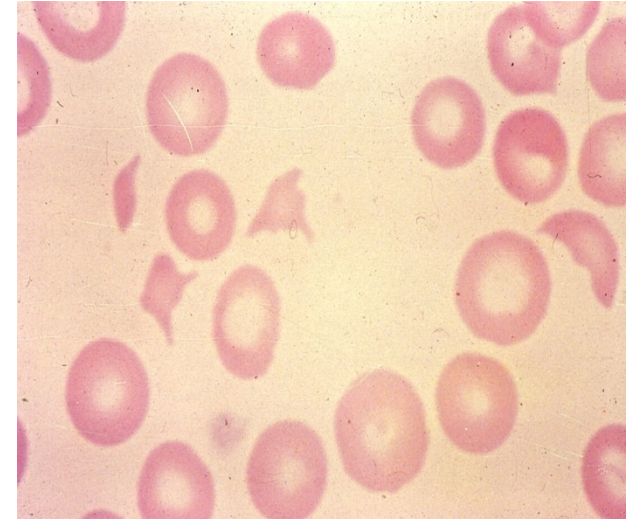
- Large Platelets, decreased numbers



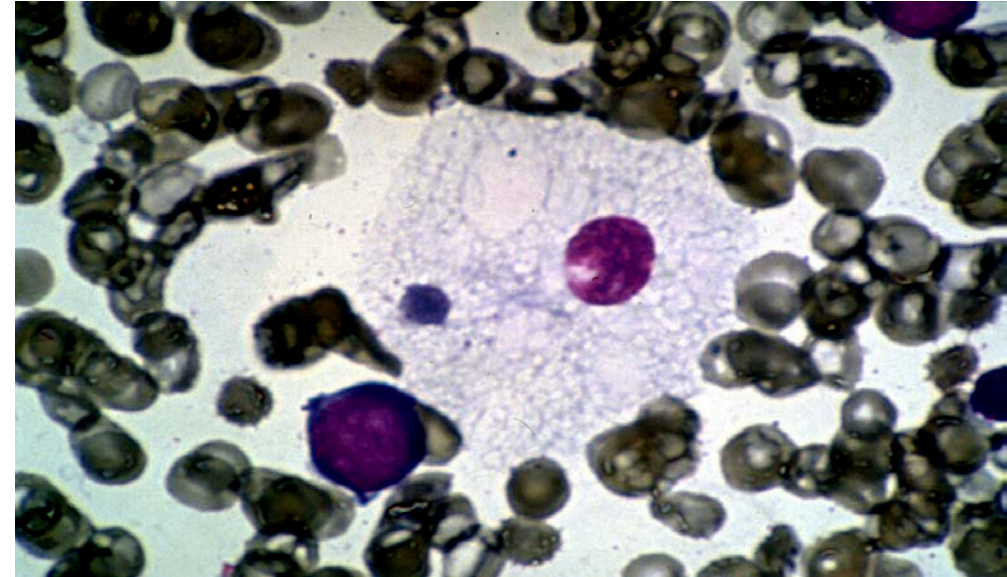
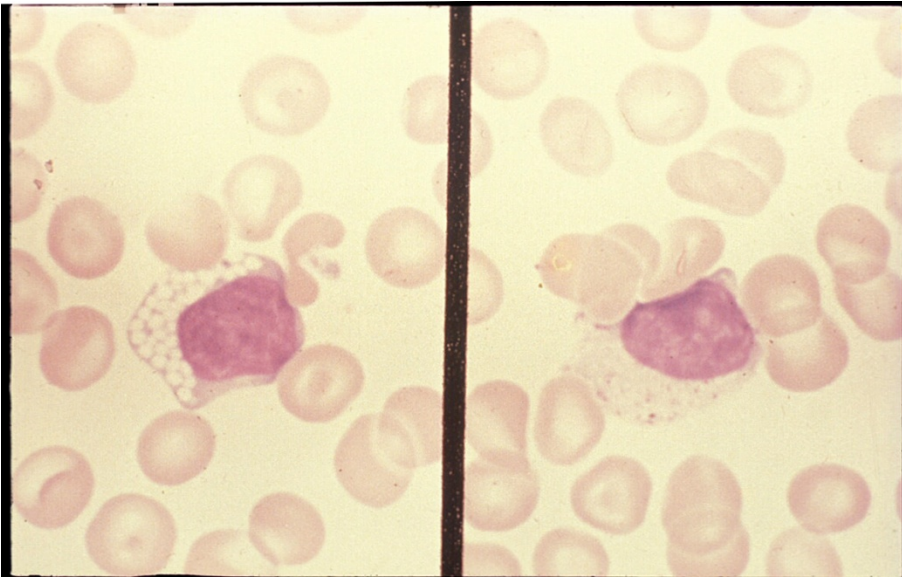
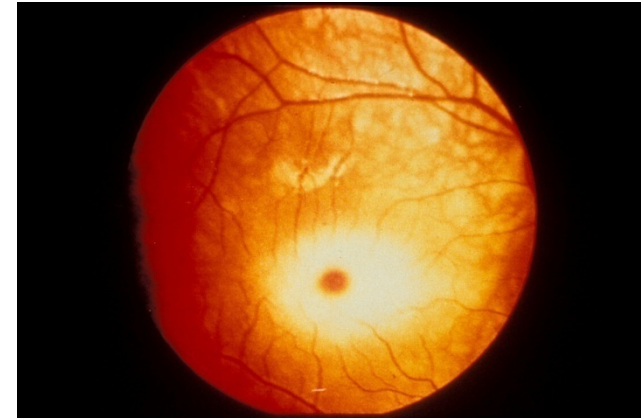
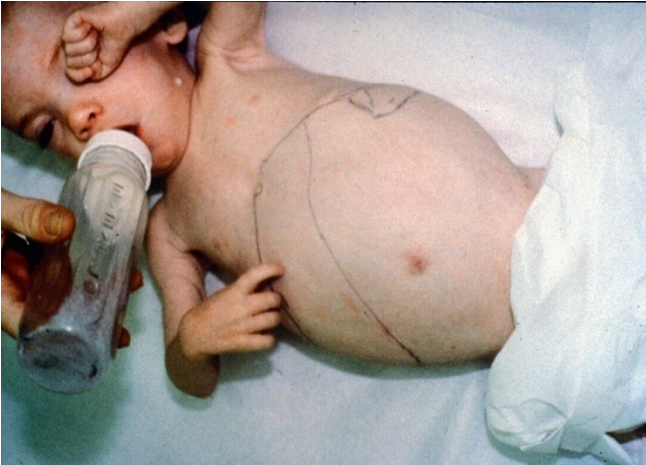Fragmented Red Cells (Schistocytes)

Seen in

- microangiopathies (eg, TTP,HUS ,DIC)
- cardiovascular disorders (eg, prosthetic valve and endocarditis)
- Serial counting in TTP may correlate with changes in serum LDH levels
- normal reference range for the schistocyte count is as 0.03–0.58%

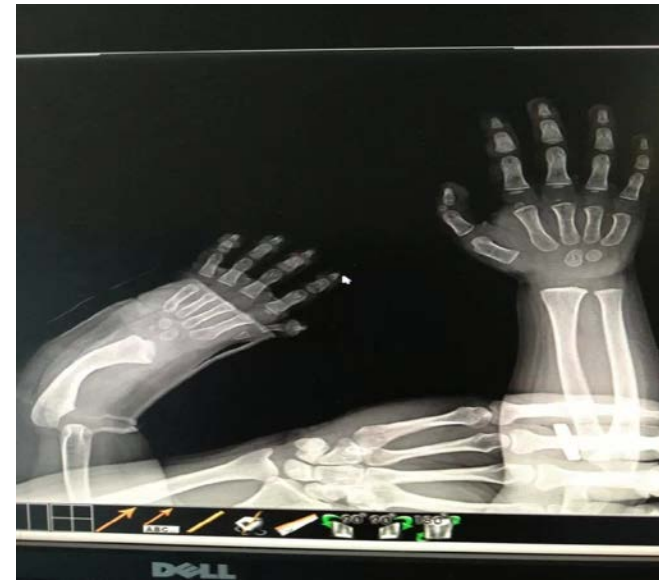
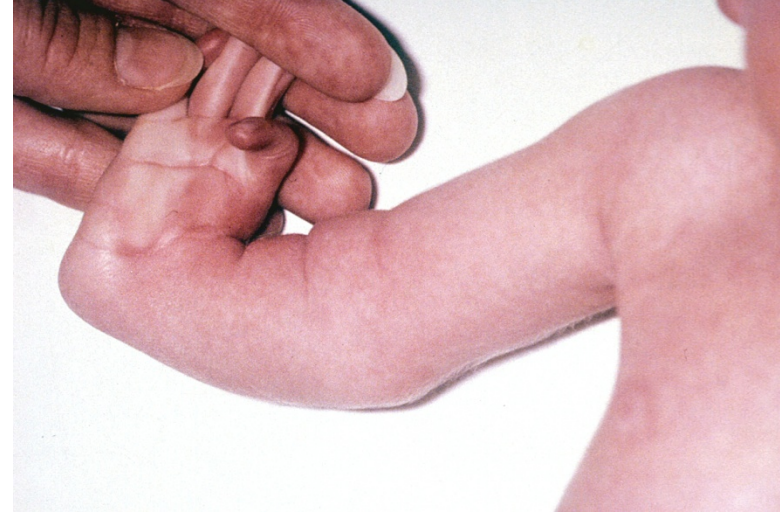
Regression, Hepatosplenomegaly and Pancytopenia



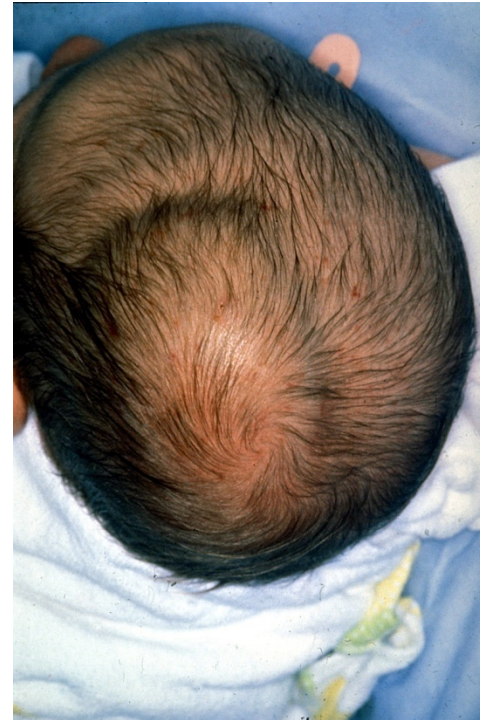Neonatal Thrombocytopenia

- Maternal ITP, Autoimmune disorders
- Alloimmune
- Sepsis, DIC
- IU Viral Infections, HIV
- Drugs
- TAR Syndrome
- Congenital leukemia



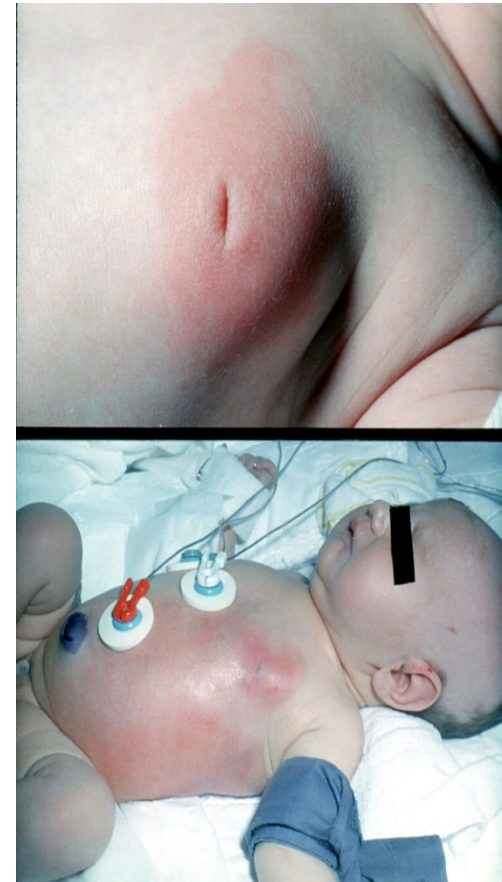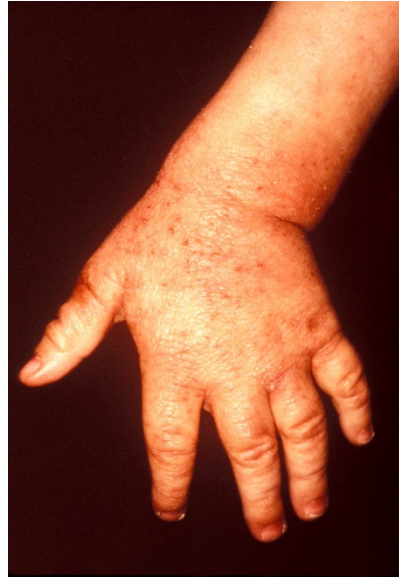Neonatal Alloimmune Thrombocytopenia

- Healthy mother and infant
- Normal CBC except for platelets
- Self limited
- Risk of IU IC hemorrhage
- Maternal platelets (PLA 1 Negative)
- IV Ig . ? Antenatal treatment



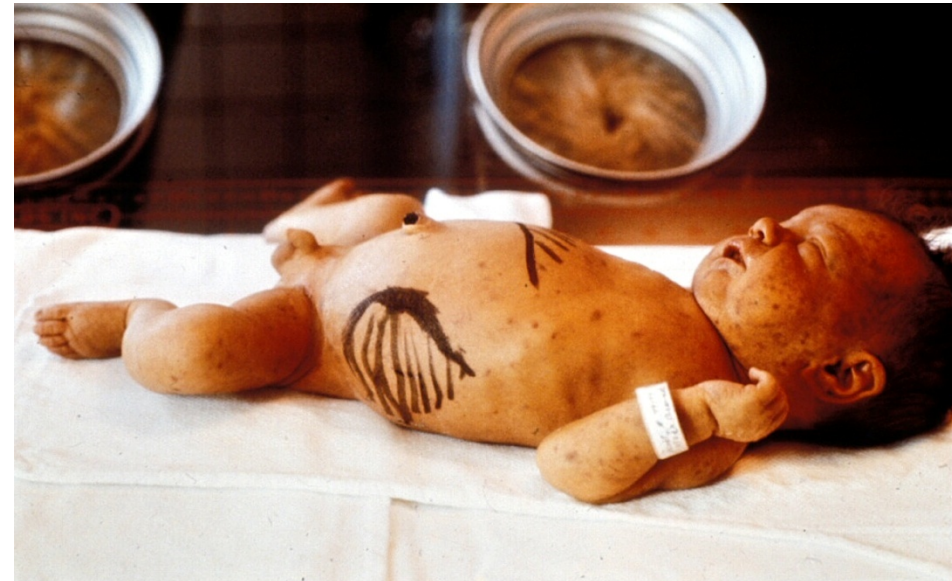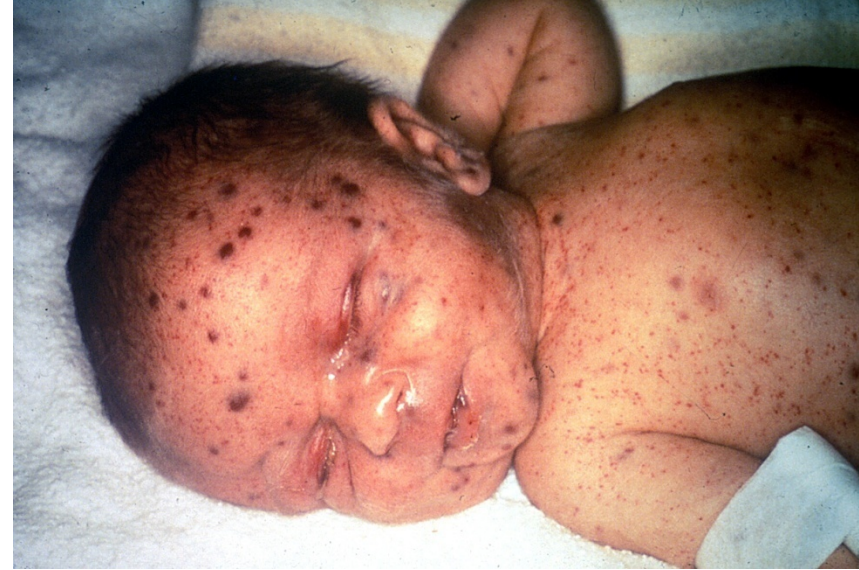Neonatal Thrombocytopenia

- TAR Syndrome
- Cavernous Hemangiomas – Kassabach Merritt Syndrome
- Wiskott Aldrich Syndrome
- Sepsis with DIC
- Maternal ITP, SLE, Drugs
- Alloimmune
- I.U.Infections,
- Placental infarcts

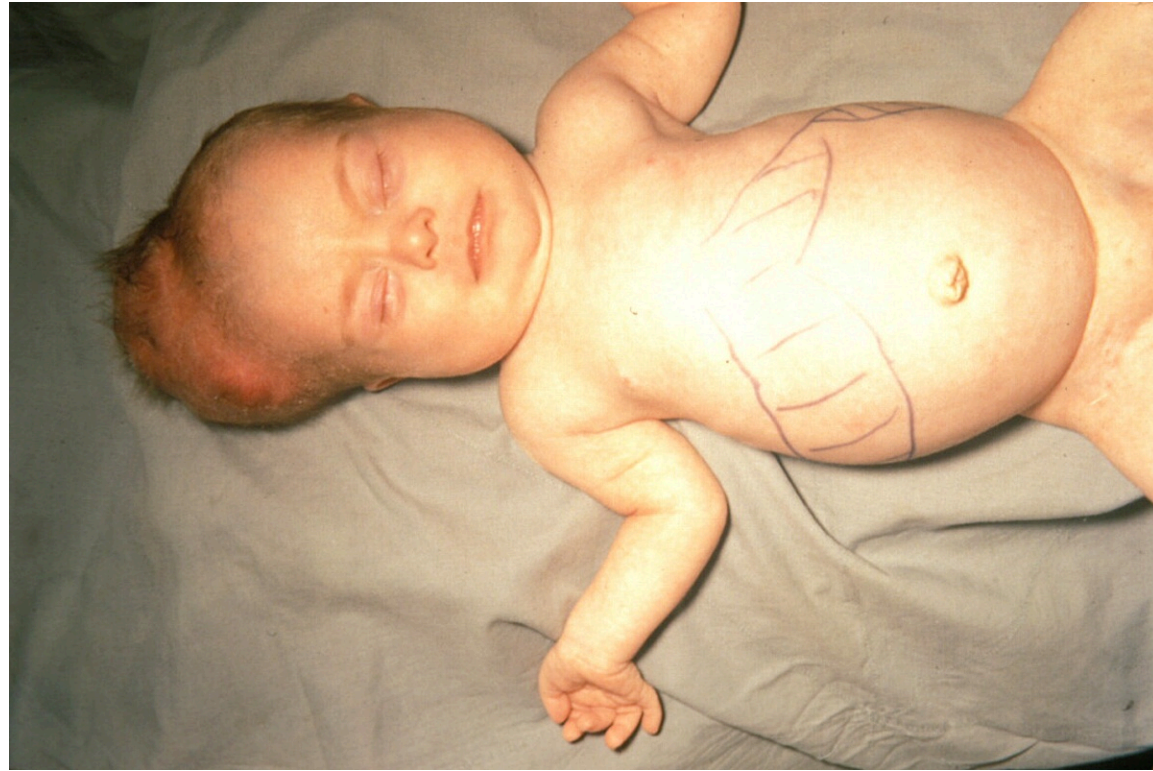

Clinical Case

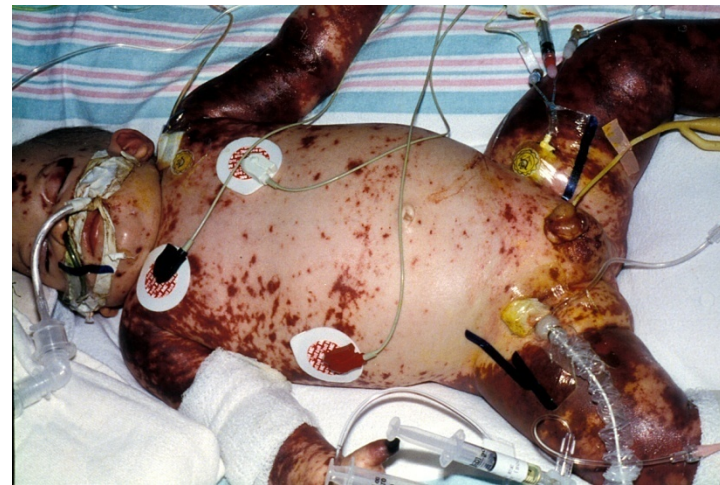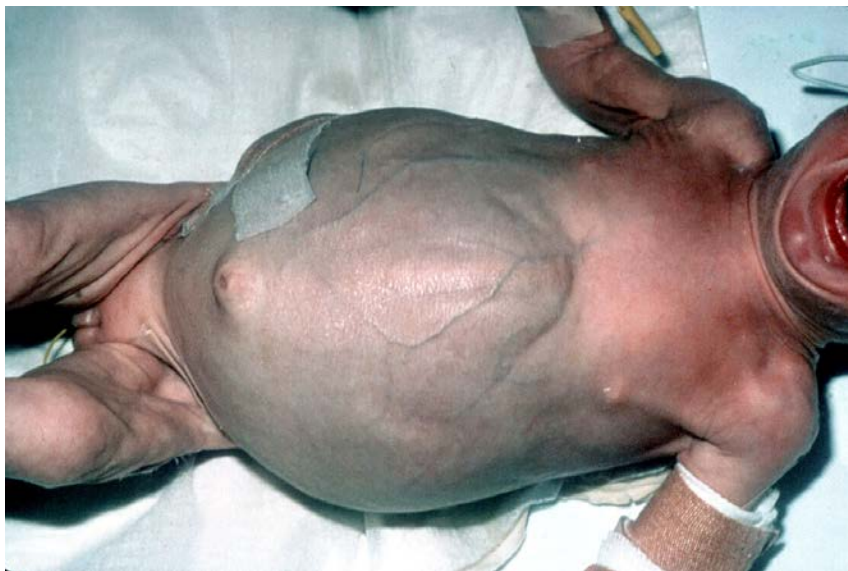- LBW, premie at 30 weeks, Looks ill
- Jaundice
- Anemia
- Purpura and Petichiae
- Hepatosplenomegaly
- Platelets – 40,000



Fever, Hepatosplenomegaly



Thrombocytopenia and bleeding in SICK neonates – 1 and 2

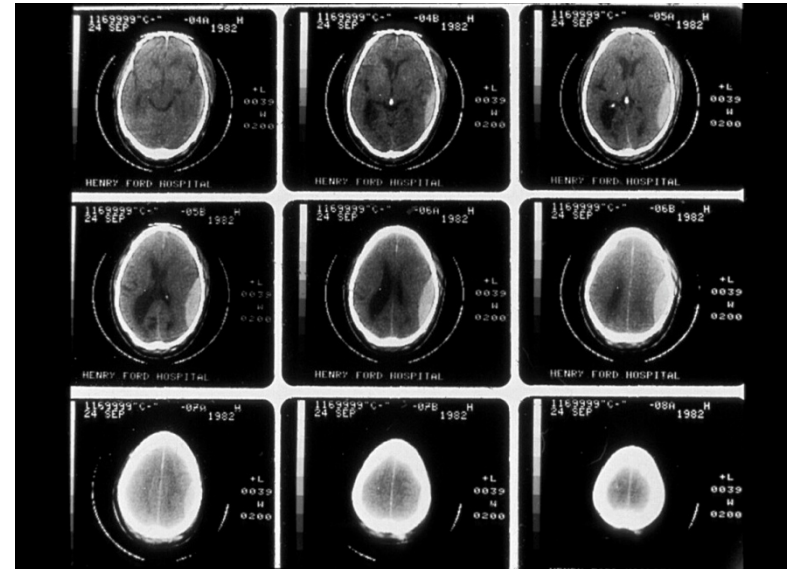


Case of a breast fed bleeding infant

- 7 day old infant born at 34 weeks
- Delivered at home in Bogalusa!!
- Baby Friendly mom- totally breast fed
- Generalized petichiae , Melena and GI bleed
- Transferred to you at 7 pm on a Friday afternoon!!

Hemorrhagic Disease Of New Born

- Classic
 - Primarily Breast fed infants
 - Bleeding 2-10 days of life
 - Generalized ecchymosis, GI Hge, Pulmonary Hge
 - I C Hge - Uncommon



Vit K Deficiency

- High risk in Premies and SGW
- Poor IU storage
- Poor Liver function and stores
- Gut flora – poor synthesis
- Decreased intake
- Breast Milk – poor source

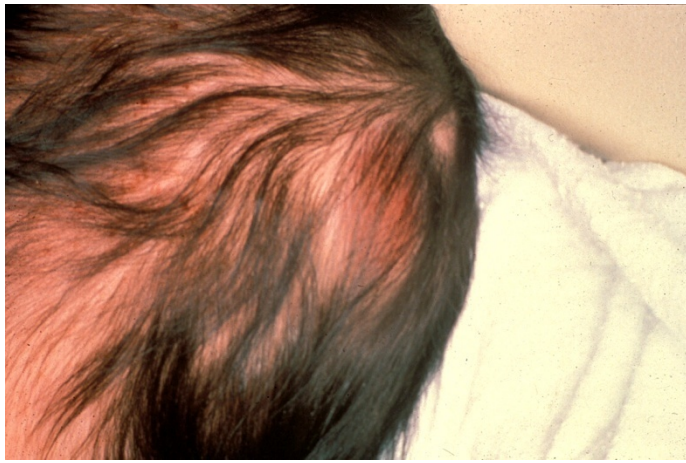D I C

- Sick Infant – Sepsis, Hypoxia, Hypotension
- NEC
- Death of a Twin in utero
- Kassabach Merritt
- Non immune Hydrops
- Neonatal Neoplasms

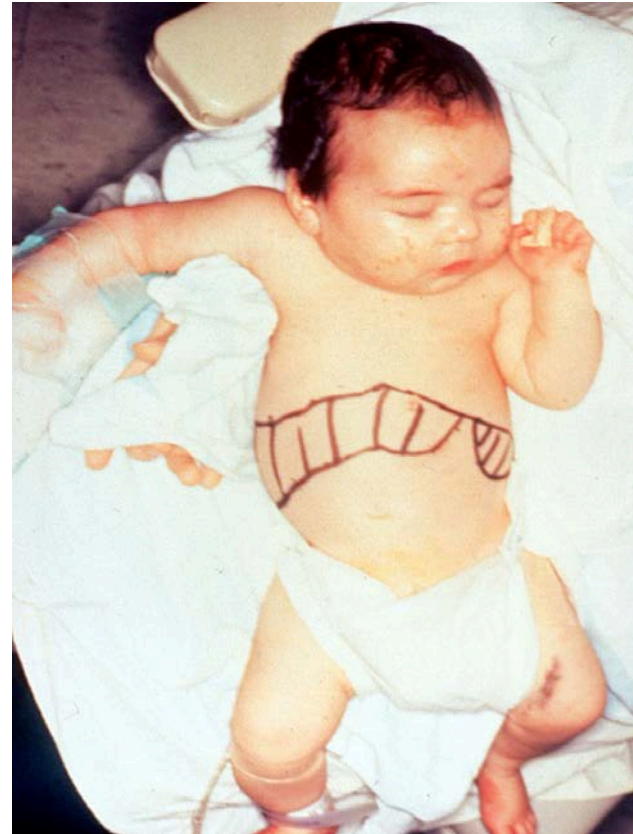- Diagnosis – CBC, D I C
Platelet, Smear , FSP, D-
dimers, Fibrinogen
PT,PTT,TT
- Treat Primary cause
- Supportive Care
- Transfusions as needed
- FFP, Platelets, PRBC

Congenital anomalies

- TAR Syndrome
- Trisomy 13
- Trisomy 18
- Trisomy 21
- Fanconi's anemia
- Ivy Mark Syndrome

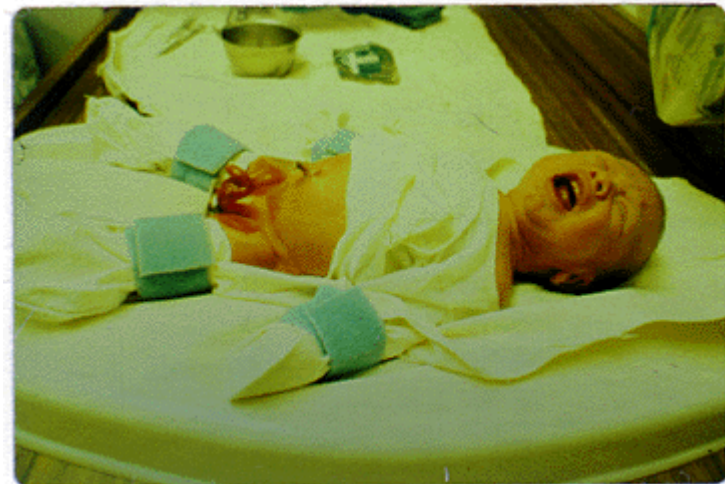

Cutaneous nodules,
hepatosplenomegaly – smear



Healthy Newborn male with bleeding after circumcision

- First born male, Routine circumcision
- Profuse delayed bleeding
- Family H/O of bleeding in maternal uncle
- Prolonged PTT, Normal PT



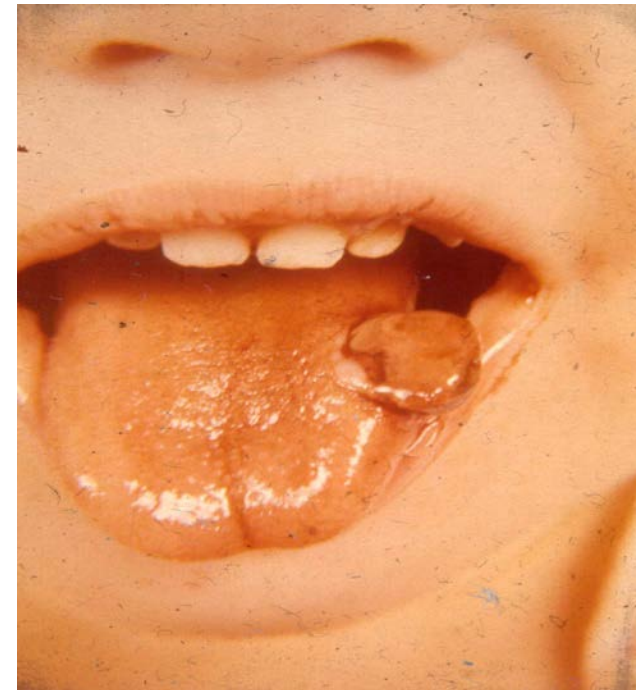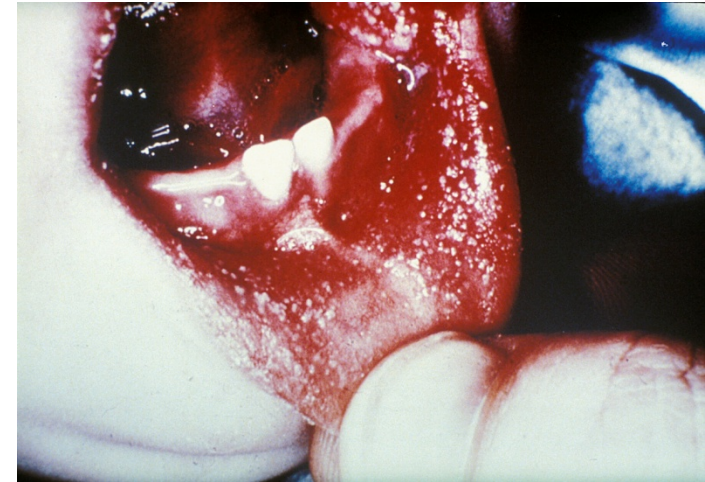
Hereditary Bleeding Disorders

- Hemophilia A or B
- Factor XIII Def – delayed bleeding from Umbilical stump
- Von Willebrand Disease- 1% of all Caucasians have VwD
- Report of Unusual cases – X, VII, XIII



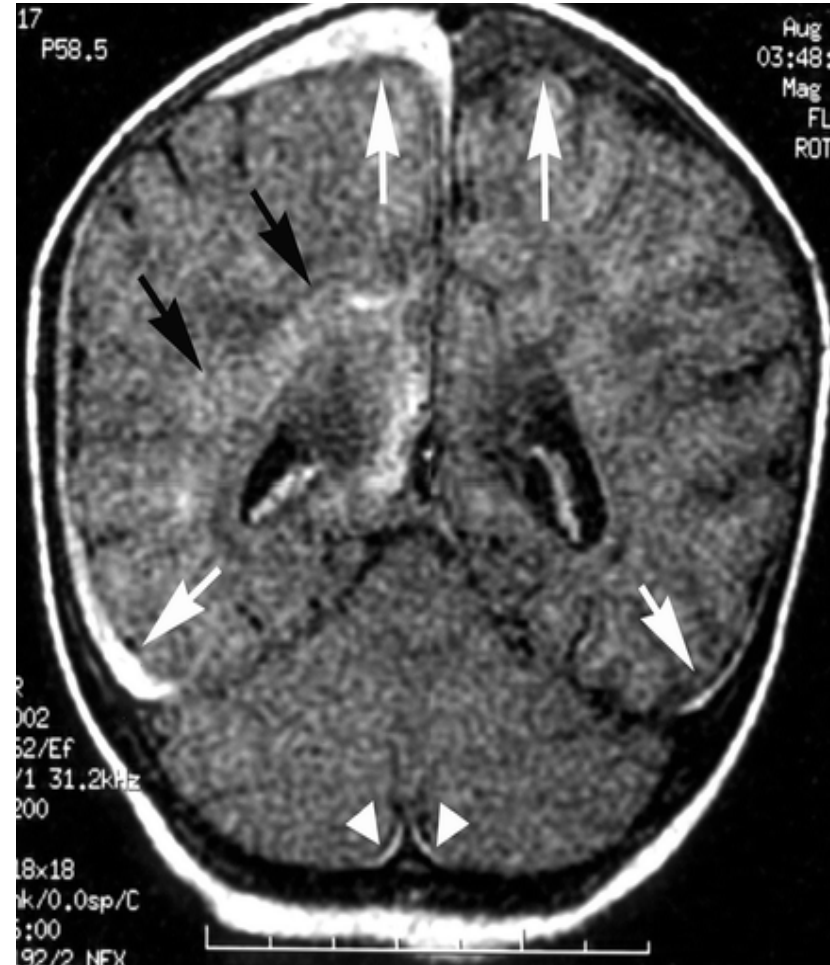
Tooth Extraction

- Treat before (50% or greater, depending on extent of procedure)
- Consider DDAVP for mild hemophiliac
- Epsilon amino caproic acid (Amicar) or tranexamic acid after



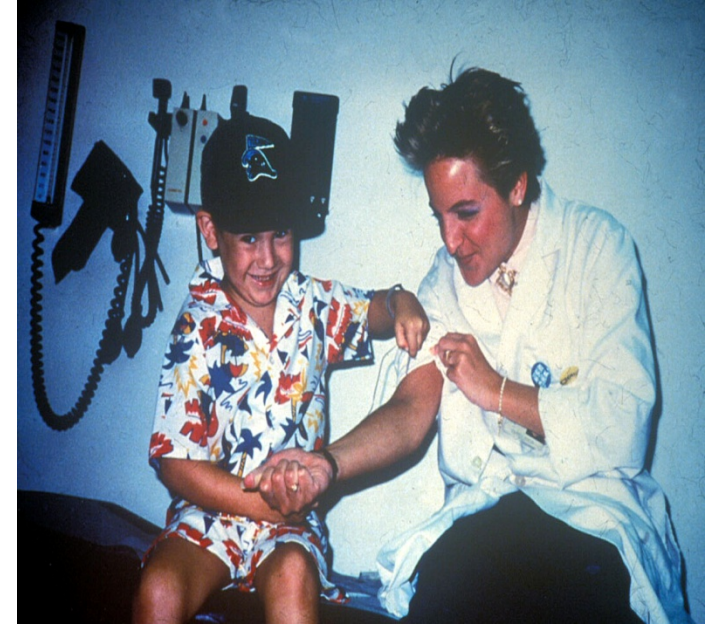■ CNS Bleeds (Head trauma)

- Most common cause of fatal bleeding
- May occur in delayed fashion
- Treat even minor head trauma in general
- 100% replacement, before diagnostic procedures
- CT or MRI may be helpful
- When in doubt, or if any sign of objective head trauma (abrasion or external hematoma), treat



Philosophy of Care

- Normalization of life style and prevention of disability
- Rx still “on-demand” in most cases, but prophylactic treatment should be considered
- Home therapy whenever possible



References /Reading material

- Text Book Of Peds Hematology – Nathan
- Text Book of Neonatology – Avery
- Neonatal Hematology – Christensen
- PCNA Oct 2010 ,57(5) 1085
- Arch Ped 2010 Sept 17,3:53
- Seminars in Hematology 2010 July ,47(3) 281
- Am J Of Perinatology 2010 July 15;55.145