



Endothelial Health After Biointerventional Scleral Allograft Reinforcement and Ab Interno Cyclodialysis in Eyes Undergoing Cataract Surgery: 24-Month Results

Arsham Sheybani, MD; James S Lewis, MD; Craig J Chaya, MD;
Nathan M Radcliffe, MD; Robert T Chang, MD; Robert N Weinreb, MD

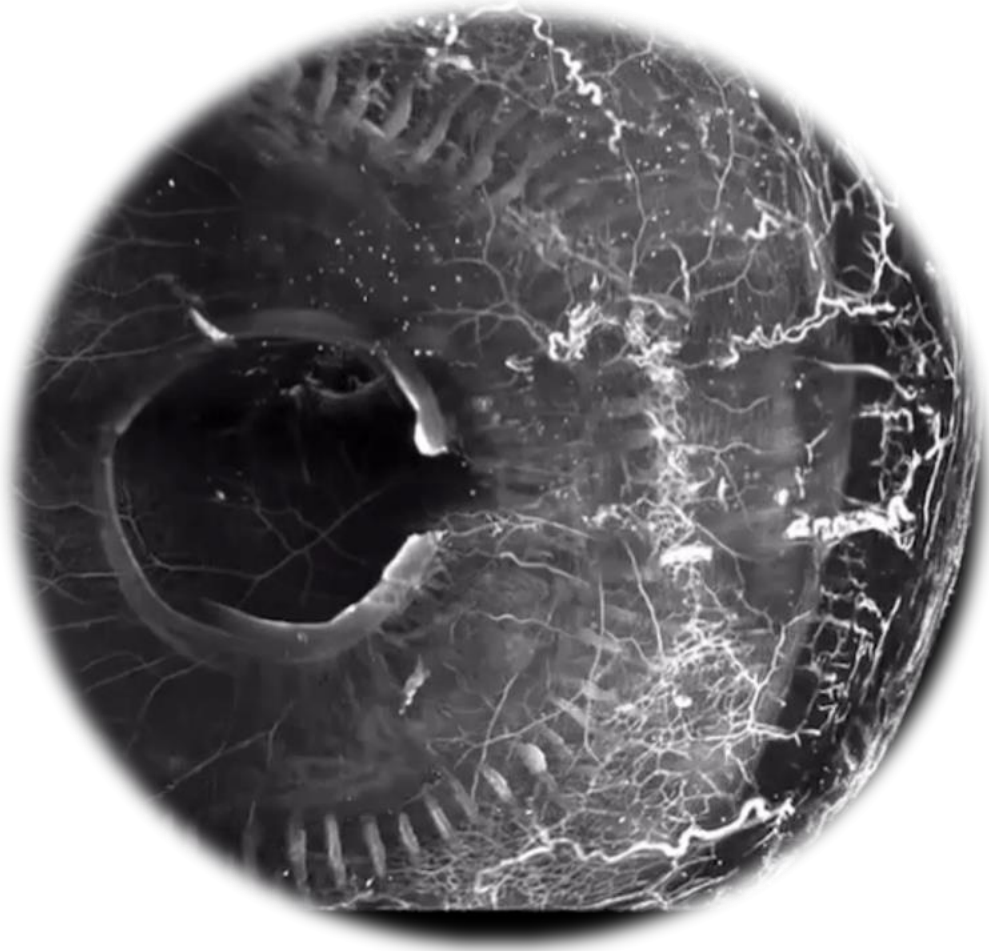
AAO 2025

PO354

Financial Disclosures

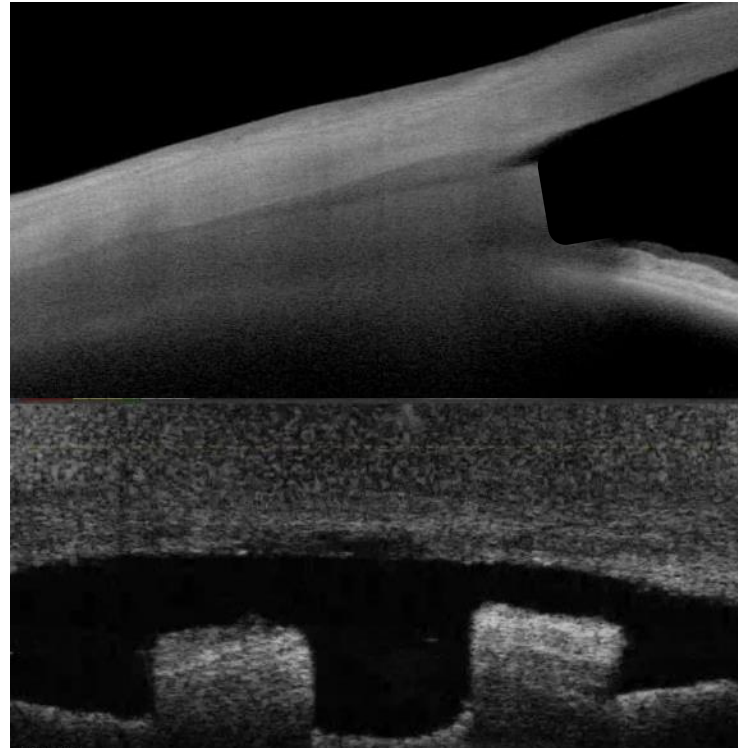
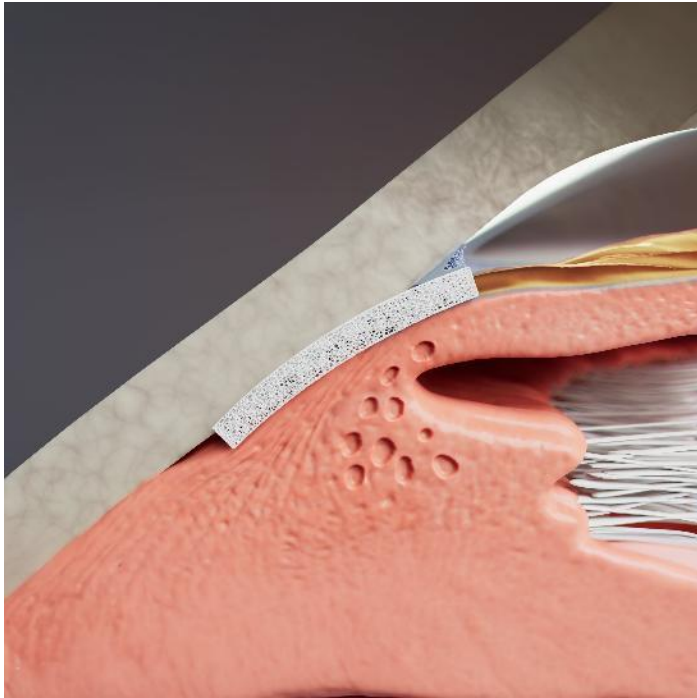
- Iantrek – Consultant
- Abbvie – Consultant
- Alcon – Consultant
- Glaukos – Consultant
- Myra – Consultant

Uveoscleral Outflow: A Validated Pathway



- Uveoscleral outflow is an established therapeutic target
- Demonstrated Rx efficacy with pharmacotherapy (PGAs)
- Larger aqueous drainage capacity than trabecular pathway
- Negative oncotic gradient drives aqueous outflow

Scleral Bio-Reinforcement of Cyclodialysis



Maintains Aqueous Pathway

A homologous bio-tissue for endoscleral reinforcement

Highly Permeable Bio-Tissue

Enhances uveoscleral aqueous outflow

Scleral Reinforcement

Scleral reinforcement without damage to the conjunctiva

Unlock the Other Half Of Natural Outflow

Work with your patient's natural physiology—while you stay in the angle

Hardware-free AC-clear Deployment

Internal cyclodialysis cleft reinforcement. Nothing projecting in AC

Advantages of scleral allograft material properties



Conforming Implant Material

Soft, scleral wall compliant bio-tissue; no vertical rigid tip



No Hardware

Bio-conforming soft tissue; no plastic, metal or rigid foreign body




No Rebound Movement

Enhanced post-deployment fixation - tissue expansion / rehydration in cleft





AC-Clear Deployment

Bio-spacer deployed within cyclodialysis cleft without any proximal segment in AC



Implant material biomechanical properties similar to surrounding tissue can drive reduced foreign body reaction

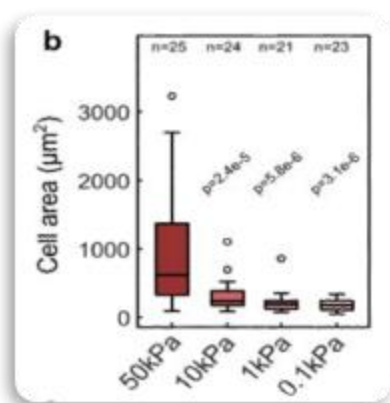
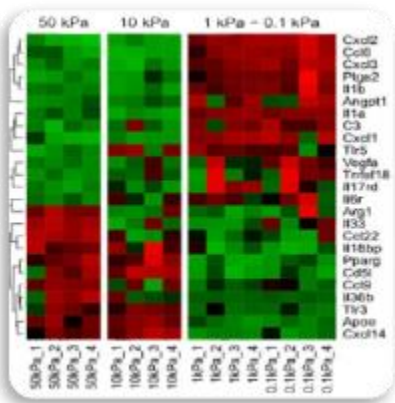


Homologous Allograft

Minimal foreign body reaction
Designed for corneal safety

Porous

For aqueous conductivity



Foreign body response: Reduced Macrophage activation with more homologous implant material biomechanics

	Tensile Strength MPa	SC Implant vs Tissue Mismatch
Scleral Allograft	1-2 ¹	0
Titanium	240 ³	239
Polyimide	80 ²	70

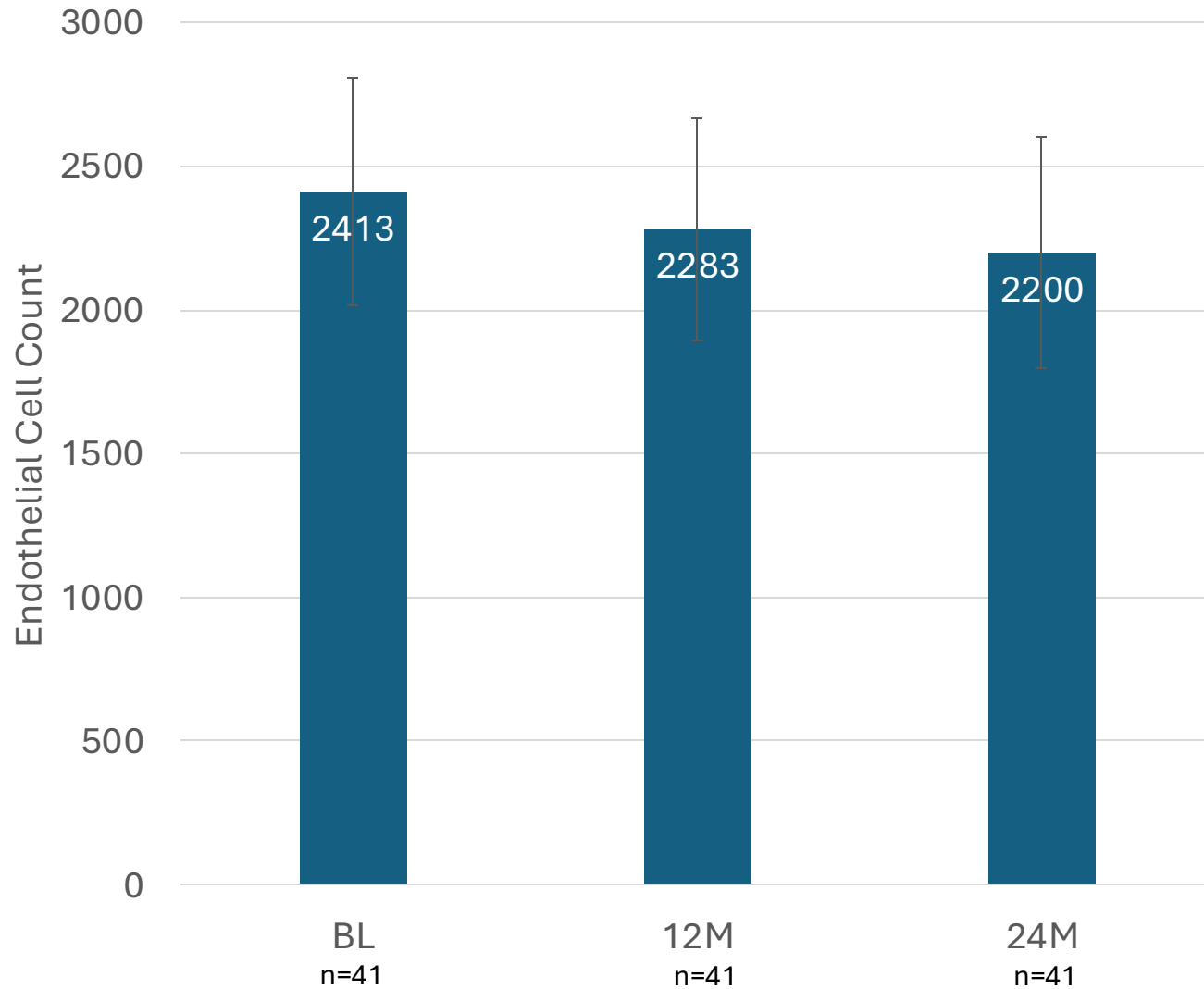
	Cornea Permeability (cm/s)	Sclera Permeability (cm/s)
BENZOLAMIDE	1.4 E-7	2.0E-5
INULIN	5.5 E-7	9.0 E-6
PROPRANOLOL	3.1 E-6	5.8 E-5
SUCROSE	4.4 E-6	2.2 E-5

Study Design and Baseline Characteristics

- CREST is a prospective, multicenter, observational, real world clinical study (n=400+)
- Medically uncontrolled cohort of glaucoma patients with a confirmed diagnosis of open-angle glaucoma. Prospectively followed for up to 24 months
- Subjects: Subjects were included following interventional ab-interno cyclodialysis with subsequent bio-tissue scleral reinforcement
- Endothelial cell count (ECC): Specular microscopy evaluation conducted at 12M and 24M based on discretion of individual investigators / sites and availability of specular microscope
- Analysis: Baseline, 12M, and 24M data was evaluated. Eyes with baseline ECC greater than 1600 were considered eligible for the analysis

Sample size, eyes, N	41
Age, mean \pm SD, years	70.0 \pm 7.5
Gender: female, %	38%
Race	
Black or African-American	7%
White	93%
Baseline BCVA (logMAR), mean +SD	1.17 \pm 2.51
Baseline IOP, mmHg, mean \pm SD	20.4 \pm 5.1
Number of IOP-lowering drugs, mean \pm SD	1.9 \pm 1.3

Results – Endothelial Cell Loss



Baseline, mean \pm SD	2413 \pm 394
12M, mean \pm SD	2283 \pm 388
24M, mean \pm SD	2200 \pm 401
% reduction, BL-12M, mean	5.4%
% reduction, BL-24M, mean	8.7%
24M > 20% loss, n (%)	2 (5%)
24M > 30% loss, n (%)	0 (0%)

Results – IOP and Medications

IOP Outcomes	
Preop IOP, mean (SD)	20.4 (5.1)
12M IOP, mean (SD)	14.0 (5.4)
24M IOP, mean (SD)	14.5 (7.2)

Medication Outcomes	
Preop Mean, (SD)	1.9 (1.3)
12M IOP, mean (SD)	0.6 (1.1)
24M IOP, mean (SD)	0.6 (0.7)

ECL reported across MIGS procedures

TABLE 1. COMPARISON OF ECL RATES ACROSS MIGS PROCEDURES

MIGS DEVICE	N	FOLLOW-UP TIME	MEAN % ECL	% WITH ECL >30%
Schlemm Canal				
iStent inject (Glaukos)	505	24 months	13.1% treatment 12.3% control	10.4% treatment 9.5% control
	20 ^a	12 months	13.2%	
Hydrus Microstent (Ivantis)	556	24 months	14.0% treatment 10.0% control	13.6% treatment 7.2% control
		36 months	15.0% treatment 11.0% control	14.0% treatment 10.2% control
Trabectome (NeoMedix)	80 ^b	12 months	No change	
Kahook Dual Blade (New World Medical)	Unknown			
Ab Interno Canaloplasty (Ellex)	Unknown			
Omni (Sight Sciences)	Unknown			
Supraciliary				
CyPass Micro-Stent (Alcon)	253	60 months	18.4% treatment 7.5% control	27.2% treatment 10.0% control
iStent Supra (Glaukos)	Unknown			

Conclusion

- Bio-interventional uveoscleral outflow enhancement using scleral allograft implants incorporates material similar to native tissue
- Spacer design allows for placement flush to scleral wall while maintaining patency of cyclodialysis cleft
- Endothelial cell loss is comparable to prior trabecular MIGS procedures; more data is needed to further validate these findings