

# Contrast Allergy Outpatient Prep



## Outpatient oral prep protocol (13 hour prep) for patients with a known allergic-like reaction to IV contrast:

From the 2021 ACR Manual on Contrast Media:

### Elective Premedication

Two frequently used regimens are:

1. Prednisone – 50 mg by mouth at 13 hours, 7 hours, and 1 hour before contrast media injection, plus Diphenhydramine (Benadryl®) – 50 mg intravenously, intramuscularly, or by mouth 1 hour before contrast medium.

Or

2. Methylprednisolone (Medrol®) – 32 mg by mouth 12 hours and 2 hours before contrast media injection. An anti-histamine (as in option 1) can also be added to this regimen.  
If the patient is unable to take oral medication, 200 mg of hydrocortisone intravenously may be substituted for oral prednisone in the Greenberger protocol.

## Patients with a known history of anaphylactic reaction:

Do not give contrast, proceed with a non-contrast exam, if at all possible.

Radiologist consultation may be considered if a contrast examination is thought to be necessary.

Reviewed by Dr. Keller 11/2021



# Contrast Allergy



## Accelerated IV premedication protocol for patients with a known allergic-like reaction to IV contrast:

From the 2021 ACR Manual on Contrast Media:

Inpatient or ED Setting (Emergency Premedication)  
(In Decreasing Order of Desirability)

1. Methylprednisolone sodium succinate (Solu-Medrol®) 40 mg or hydrocortisone sodium succinate (Solu-Cortef®) 200 mg intravenously every 4 hours (q4h) until contrast study required plus diphenhydramine 50 mg IV 1 hour prior to contrast injection.
2. Dexamethasone sodium sulfate (Decadron®) 7.5 mg or betamethasone 6.0 mg intravenously q4h until contrast study must be done in patient with known allergy to methylprednisolone, aspirin, or non-steroidal anti-inflammatory drugs, especially if asthmatic. Also, diphenhydramine 50 mg IV 1 hour prior to contrast injection.

Note: IV steroids have not been shown to be effective when administered less than 4 to 6 hours prior to contrast injection. THESE PATIENTS ARE TRUE EMERGENCIES AND MUST BE MONITORED BY THE ORDERING PHYSICIAN/SERVICE AS THEY ARE AT RISK FOR SERIOUS CONTRAST REACTION.

## Patients with a known history of anaphylactic reaction:

Do not give contrast, proceed with a non-contrast exam, except in EMERGENT situations.

Radiologist consultation may be considered if a contrast examination is thought to be necessary.

Reviewed by Dr. Keller 11/2021



# CT Oral Contrast Volumes

## Pediatric Guidelines



Any sugar free, non-carbonated, clear flavored drink is an acceptable diluting medium:

- Plain water
- Apple juice (no OJ)
- Crystal light, Kool-Aid, etc.
- Gatorade

### Volumes-

Age	Diluted contrast dose	
	ml	oz
0-1 year	100	3
2-5 years	200	7
5-10 years	350	12
10+ years <120lbs	480	16
Any pt > 120 lbs = Adult dose	960	32

**Ready To Drink (RTD) Omnipaque Oral Solution 12 mg/mL 500 mL jug (premixed contrast agent - no dilution necessary)**

Any sugar free, powder and/or single powder packets can be used to flavor the RTD jug (DO NOT DILUTE WITH ADDITIONAL LIQUID)

- Crystal Light powder/single powder packet
- Kool-Aid powder/single powder packet

Age	RTD Omnipaque 300/12mg
	ml
10+ years < 120lbs	500 = 1 jug
Any pt > 120lbs = Adult dose	1000 = 2 jugs

We understand that the listed volumes may not be tolerable at all times due to patient condition. The best possible test will be with the recommended amounts. We encourage patients to drink as much as possible.

**Scan Time-** Scan will take place 1-1 1/2 hours after the **beginning of the prep**, dependent on patient size, ability to complete volume requested and specific area of interest for exam.

**Inpatients-** We trust nursing's assessment of patient tolerance prior to starting contrast as well as throughout the prep period. Please contact us if the ordering physician decides to discontinue the oral prep so we can adjust the scan time and coordinate the schedule.

**Outpatients-** Radiology technologist will check on patient half way through your prep, but feel free to reach out to our front desk staff at any time during your preparation.

Reviewed by Dr. Steinberg 9/2023

\*Subject to change at the discretion of the radiologist due to clinical circumstances.\*



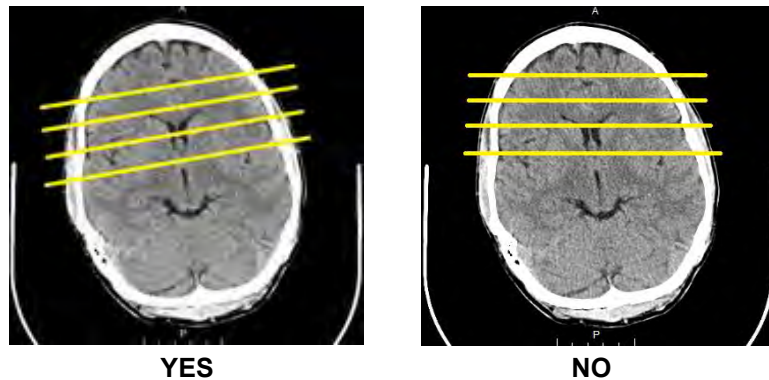
# CT General Comments



Diagnostic & Preventative Imaging Center

1. Make reconstructions relative to the patient, not the scanner. (See Fig. A)

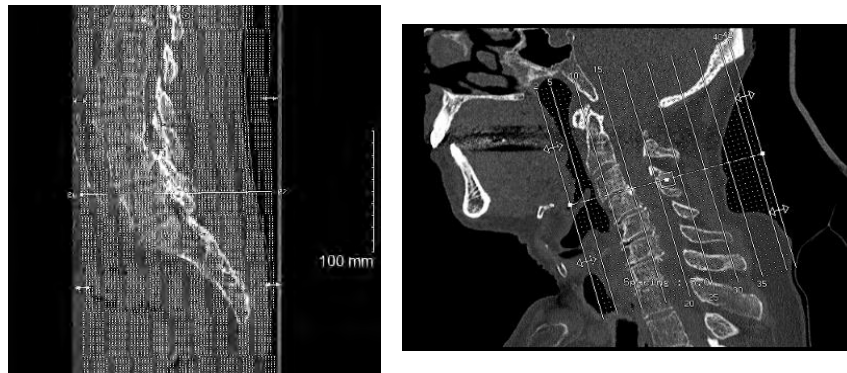
Fig. A



2. Position the patient to eliminate the need for a gantry tilt, when possible.

3. When creating sagittal and coronal reconstructions, do NOT send the additional image showing the plane of the reconstructions to PACS, if possible. If your scanner sends this image automatically, delete from PACS before marking the study as Reviewed. (See Fig. B)

Fig. B



4. All Bone Algorithm reconstructions should be created using a sharp bone algorithm, not smooth bone. This may be called Bone Plus, etc. depending on the machine.

5. Adult oral contrast for CT should be mixed at a ratio of 50 mL of water soluble contrast (Omnipaque 300 or equivalent water soluble contrast) per 1000 mL of liquid OR 1000mL Ready to Drink (RTD) Omnipaque Oral Solution 12mg/mL 500mL jugs (premixed contrast agent - no dilution necessary). CT Barium may be utilized, if indicated.

6. Pediatric oral contrast for CT - Please refer to CT Oral Contrast Volumes - Pediatric Guidelines posted online.

*Continued on next page*

Reviewed by Drs. Holdsworth, Steinberg, King 1/2025

\*Subject to change at the discretion of the radiologist due to clinical circumstances.\*



# CT General Comments Cont.

7. Protocols state Omnipaque for IV contrast. You may substitute other equivalent water soluble contrast brands such as those below.

GE Healthcare	Clinical Equivalent	Bracco
Omnipaque 300 mg/mL (Iohexal)	Clinical Equivalent	Isovue 300 mg/mL (Iopamidol)
Omnipaque 350 mg/mL (Iohexal)	Clinical Equivalent	Isovue 370 mg/mL (Iopamidol)

8. IV contrast for pediatric patients (17 years and younger) should be administered according to the following weight based guidelines: 1 mL/pound, up to a maximum dose of 80 mL

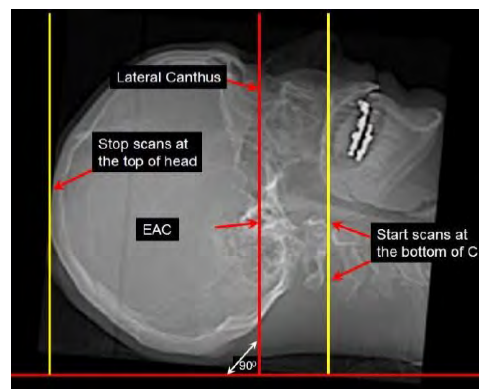


# CT Head



Diagnostic & Preventative Imaging Center

<b>Anatomical Reference:</b>	Orbitomeatal
<b>Patient Position:</b>	Supine; Tilt the patient's head so that the orbitomeatal line is perpendicular to the CT tabletop (see image).
<b>Patient Orientation:</b>	Head First
<b>Scan Range:</b>	C1 through vertex
<b>Scout:</b>	Lateral, AP if necessary
<b>Scan Type:</b>	Helical
<b>Rotation Time:</b>	0.9
<b>Thickness:</b>	5mm, Recon as thin as possible
<b>Interval:</b>	5mm, Recon as thin as possible
<b>Gantry Tilt:</b>	None
<b>SFOV:</b>	Head
<b>kVp:</b>	120
<b>mAs:</b>	Auto mA
<b>Scan Delay:</b>	60 seconds, if contrast used
<b>Respiration:</b>	None
<b>DFOV:</b>	25
<b>Recon Algorithm:</b>	See comments below
<b>Contrast:</b>	80 mL Omnipaque 300 mg/mL or equivalent water soluble contrast @ 1.5-3 mL/sec
<b>Comments:</b>	<ol style="list-style-type: none"><li>1. Send 5 mm Soft Tissue Algorithm Axial Images to PACS</li><li>2. Send 1 mm Soft Tissue Algorithm Axial Images to PACS</li><li>3. Send 2 mm Bone Algorithm Axial Images to PACS</li><li>4. Send 3mm Sagittal and Coronal Soft Tissue Algorithm Reconstructions to PACS</li><li>5. Send thin slices to 3D Workstation (Vitrea Bridge or TeraRecon)</li></ol>



\* Image courtesy of University of Wisconsin

## Indications

Without Contrast:	Trauma, Stroke Symptoms, Headache, Seizure, Altered Mental Status
With and Without Contrast:	Tumor, Infection AND unable to have MRI, Abnormal Non-Contrast CT

**\*\*Values will vary between machines. Use your own discretion when selecting these values.\*\***

Reviewed by Dr. Holdsworth 1/2025

\*Subject to change at the discretion of the radiologist due to clinical circumstances.\*



# CT Perfusion Single Slab

Performed at IMMC & \*ILH Only



Diagnostic & Preventative Imaging Center

Scanner:	IMMC Siemens Edge/Flash	ILH GE Discovery CT750 HD
Detector Width:	38.4	40
Detector Rows:	32 x 1.2 mm	64
Mode:	Helical	Axial
Acq Type:	VPCT	Shuttle
Scan Delay:	5 second	5 second
Tube Voltage (kVp)	70	80
Tube Current (mA)	350	500
Exposure Time:	570	400
Exposure (mAs):	200	200
Interval (mm):	96	40
Slice Thickness:	10	5
Slice Increment:	10	5
Beam Collimation:	38.4	40
Number of Cycles:	44	24
Recon FoV:	220 mm	22 cm
Recon Kernel:	H20f Smooth	Standard
Contrast:	IV: 40 mL Omnipaque 350 mg/mL or equivalent water soluble contrast at 5 mL/sec + 40 mL of Saline chase at 5 mL/sec	

## Wait 2 Minutes

CTA Head and Neck - Follow posted online protocol

**\*\*Values will vary between machines. Use your own discretion when selecting these values.\*\***

Reviewed by Dr. Holdsworth 1/2025

\*Subject to change at the discretion of the radiologist due to clinical circumstances.\*



# CT Perfusion Dual Slab



Diagnostic & Preventative Imaging Center

Performed at \*ILH & MWH Only

	ILH	MWH
<b>Scanner:</b>	<b>Siemens Edge</b>	<b>Siemens AS 64</b>
<b>Detector Width:</b>	38.4 - per slab	19.2 mm
<b>Detector Rows:</b>	32 x 1.2 mm	16 x 1.2 mm
<b>Mode:</b>	Helical	Axial
<b>Acq Type:</b>	VPCT	NeuroPCT
<b>Scan Delay:</b>	5 second	5 second
<b>Tube Voltage (kVp)</b>	80	80
<b>Tube Current (mA)</b>	350	85
<b>Exposure Time:</b>	570	1 second
<b>Exposure (mAs):</b>	110	85
<b>Interval (mm):</b>	0 mm	0 mm
<b>Slice Thickness:</b>	10	10
<b>Slice Increment:</b>	9.6	4.5
<b>Beam Collimation:</b>	38.4	19.2 mm
<b>Number of Cycles:</b>	44	65
<b>Recon FoV:</b>	220 mm	22 cm
<b>Recon Kernel:</b>	H20f Smooth	H20f Smooth
<b>Contrast:</b>	IV: <b>1st Perfusion Run:</b> 40 mL Omnipaque 350 mg/mL or equivalent water soluble contrast at 5 mL/sec + 40 mL of Saline chase at 5 mL/sec	
	<b>Wait 2 Minutes</b>	
	<b>2nd Perfusion Run:</b> 40 mL Omnipaque 350 mg/mL or equivalent water soluble contrast at 5 mL/sec + 40 mL of Saline chase at 5 mL/sec	
	<b>Wait 2 Minutes</b>	
	CTA Head and Neck - Follow posted online protocol	

**\*\*Values will vary between machines. Use your own discretion when selecting these values.\*\***

Reviewed by Dr. Holdsworth 1/2025

\*Subject to change at the discretion of the radiologist due to clinical circumstances.\*



# CT Head

Venogram



<b>Anatomical Reference:</b>	Orbitomeatal
<b>Patient Position:</b>	Supine; Tilt the patient's head so that the orbitomeatal line is perpendicular to the CT tabletop (see CT Head protocol).
<b>Patient Orientation:</b>	Head First
<b>Scan Range:</b>	C-1 through vertex
<b>Scout:</b>	Lateral, AP if necessary
<b>Scan Type:</b>	Helical
<b>Rotation Time:</b>	0.9
<b>Thickness:</b>	3 mm, Recon as thin as possible
<b>Interval:</b>	3 mm, Recon as thin as possible
<b>Gantry Tilt:</b>	None
<b>SFOV:</b>	Head
<b>kVp:</b>	120
<b>mAs:</b>	Auto mA
<b>Scan Delay:</b>	Smart Prep (ROI-Aorta) - Start scan 5 seconds after contrast arrival in aorta Scan a 2nd series immediately after completion of the first series.
<b>Respiration:</b>	Inspiration
<b>DFOV:</b>	25
<b>Recon Algorithm:</b>	Standard
<b>Contrast:</b>	80 mL Omnipaque 300 mg/mL or equivalent water soluble contrast @ 2-3 mL/sec
<b>Comments:</b>	1. Send 5 mm Soft Tissue Algorithm Axial Images to PACS 2. Send 1 mm Soft Tissue Algorithm Axial Images to PACS 3. Send 3mm Sagittal and Coronal Soft Tissue Algorithm Reconstructions to PACS 4. Send thin slices to 3D Workstation (Vitrea Bridge or TeraRecon)

## Indications

With Contrast: Venous Sinus Thrombosis, Headache

**\*\*Values will vary between machines. Use your own discretion when selecting these values.\*\***

Reviewed by Dr. Holdsworth 1/2025

\*Subject to change at the discretion of the radiologist due to clinical circumstances.\*




# CT Orbits



Diagnostic & Preventative Imaging Center

<b>Anatomical Reference:</b>	Orbitomeatal
<b>Patient Position:</b>	Supine; Tilt the patient's head so that the orbitomeatal line is perpendicular to the CT tabletop (see CT Head protocol).
<b>Patient Orientation:</b>	Head First
<b>Scan Range:</b>	Maxilla through Orbits
<b>Scout:</b>	Lateral
<b>Scan Type:</b>	Helical
<b>Rotation Time:</b>	0.9
<b>Thickness:</b>	3 mm, Recon as thin as possible
<b>Interval:</b>	3 mm, Recon as thin as possible
<b>Gantry Tilt:</b>	None
<b>SFOV:</b>	Head
<b>kVp:</b>	120
<b>mAs:</b>	Auto mA
<b>Scan Delay:</b>	60 seconds, if contrast used
<b>Respiration:</b>	None
<b>DFOV:</b>	15cm
<b>Recon Algorithm:</b>	See comments below
<b>Contrast:</b>	80 mL Omnipaque 300 mg/mL or equivalent water soluble contrast @ 2-3 mL/sec
<b>Comments:</b>	<ol style="list-style-type: none"><li>1. Send 1 mm Bone Algorithm Axial Images to PACS</li><li>2. Send 3 mm Soft Tissue Algorithm Axial Images to PACS</li><li>3. Send 2 mm Bone Algorithm Sagittal and Coronal Reconstructions to PACS</li><li>4. Send 2 mm Soft Tissue Algorithm Sagittal and Coronal Reconstructions to PACS</li><li>5. Send thin slices to 3D Workstation (Vitrea Bridge or TeraRecon)</li></ol>

\* Image courtesy of University of Wisconsin



## Indications

Without Contrast:	Injury, Fracture
With Contrast	Infection/Cellulitis; If patient cannot have MRI: Tumor/Mass, Proptosis, Grave's Disease
With and Without Contrast:	Rarely indicated - Consult radiologist

**\*\*Values will vary between machines. Use your own discretion when selecting these values.\*\***

Reviewed by Dr. Holdsworth 1/2025

\*Subject to change at the discretion of the radiologist due to clinical circumstances.\*



# CT Sinus



Diagnostic & Preventative Imaging Center

<b>Anatomical Reference:</b>	Orbitomeatal
<b>Patient Position:</b>	Supine; Tilt the patient's head so that the orbitomeatal line is perpendicular to the CT tabletop (see CT Head protocol).
<b>Patient Orientation:</b>	Head First
<b>Scan Range:</b>	Bottom of maxillary teeth through top of frontal sinuses
<b>Scout:</b>	Lateral
<b>Scan Type:</b>	Helical
<b>Rotation Time:</b>	0.9
<b>Thickness:</b>	3 mm, Recon as thin as possible
<b>Interval:</b>	3 mm, Recon as thin as possible
<b>Gantry Tilt:</b>	None
<b>SFOV:</b>	Head
<b>kVp:</b>	120
<b>mAs:</b>	Auto mA
<b>Scan Delay:</b>	None
<b>Respiration:</b>	None
<b>DFOV:</b>	Adjust to patient size
<b>Recon Algorithm:</b>	See comments below
<b>Contrast:</b>	None
<b>Comments:</b>	<ol style="list-style-type: none"><li>1. Send 1 mm Bone Algorithm Axial Images to PACS</li><li>2. Send 3 mm Soft Tissue Algorithm Axial Images to PACS</li><li>3. Send 2 mm Sagittal and Coronal Bone Algorithm Reconstructions to PACS</li><li>4. Send thin slices to 3D Workstation (Vitrea Bridge or TeraRecon)</li></ol>

## Indications

Without Contrast:	Sinusitis, Headache
With Contrast:	Rarely indicated - Consult radiologist
With and Without Contrast:	Rarely indicated - Consult radiologist

**\*\*Values will vary between machines. Use your own discretion when selecting these values.\*\***

Reviewed by Dr. Holdsworth 10/2019

\*Subject to change at the discretion of the radiologist due to clinical circumstances.\*



# CT Facial Bones



Diagnostic & Preventative Imaging Center

<b>Anatomical Reference:</b>	Orbitomeatal
<b>Patient Position:</b>	Supine; Tilt the patient's head so that the orbitomeatal line is perpendicular to the CT tabletop (see CT Head protocol).
<b>Patient Orientation:</b>	Head First
<b>Scan Range:</b>	Bottom of mandible through top of frontal sinuses
<b>Scout:</b>	Lateral
<b>Scan Type:</b>	Helical
<b>Rotation Time:</b>	0.9
<b>Thickness:</b>	3 mm, Recon as thin as possible
<b>Interval:</b>	3 mm, Recon as thin as possible
<b>Gantry Tilt:</b>	None
<b>SFOV:</b>	Head
<b>kVp:</b>	120
<b>mAs:</b>	Auto mA
<b>Scan Delay:</b>	60 seconds, if contrast used
<b>Respiration:</b>	None
<b>DFOV:</b>	Adjust to patient size
<b>Recon Algorithm:</b>	See comments below
<b>Contrast:</b>	80 mL Omnipaque 300 mg/mL or equivalent water soluble contrast @ 2-3 mL/sec
<b>Comments:</b>	<ol style="list-style-type: none"><li>1. Send 1 mm Bone Algorithm Axial Images to PACS</li><li>2. Send 3 mm Soft Tissue Algorithm Axial Images to PACS</li><li>3. Send 2 mm Sagittal and Coronal Bone Algorithm Reconstructions to PACS</li><li>4. Send thin slices to 3D Workstation (Vitrea Bridge or TeraRecon)</li></ol>

## Indications

Without Contrast:	Facial Trauma
With Contrast:	Infection
With and Without Contrast:	Rarely indicated - Consult radiologist

**\*\*Values will vary between machines. Use your own discretion when selecting these values.\*\***

Reviewed by Dr. Holdsworth 1/2025

\*Subject to change at the discretion of the radiologist due to clinical circumstances.\*



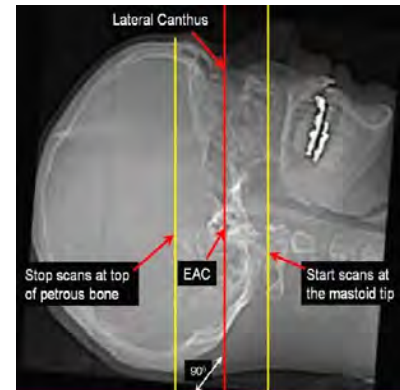
# CT Temporal Bones



Diagnostic & Preventative Imaging Center

**Anatomical Reference:** Orbitomeatal  
**Patient Position:** Supine; Tilt the patient's head so that the orbitomeatal line is perpendicular to the CT tabletop (see image).  
**Patient Orientation:** Head First  
**Scan Range:** Mastoid tip through top of petrous bone

**Scout:** Lateral  
**Scan Type:** Helical  
**Rotation Time:** 0.9  
**Thickness:** 1.25 mm, Recon as thin as possible  
**Interval:** .625 mm, Recon as thin as possible  
**Gantry Tilt:** None  
**SFOV:** Head  
**kVp:** 120  
**mAs:** Auto mA  
**Scan Delay:** 60 seconds, if contrast used  
**Respiration:** None  
**DFOV:** 15cm  
**Recon Algorithm:** See comments below




**Contrast:** 80 mL Omnipaque 300 mg/mL or equivalent water soluble contrast @ 2-3 mL/sec

**Comments:**

1. Send 3 mm Full FOV Soft Tissue Axial Images to PACS
2. Send thin (.625 mm, if possible) Bone Algorithm Axial Reconstructions of the Left Temporal Bone to PACS
3. Send thin (.625 mm, if possible) Bone Algorithm Axial Reconstructions of the Right Temporal Bone to PACS
4. Send thin (.625 mm, if possible) Bone Algorithm Coronal Reconstructions of the Left Temporal Bone to PACS
5. Send thin (.625 mm, if possible) Bone Algorithm Coronal Reconstructions of the Right Temporal Bone to PACS
6. Send thin Bone and Soft Tissue Algorithm slices to 3D workstation (Vitrea Bridge or TeraRecon)

\* Image courtesy of University of Wisconsin



Example axial field of view and coronal reconstruction plane

## Indications

Without Contrast: Hearing Loss, Cholesteatoma, Trauma/fracture, Mastoiditis

With Contrast: Jugular Bulb Anomalies; If patient cannot have MRI: Vestibulitis, Glomus

With and Without Contrast: Rarely indicated - Consult radiologist

**\*\*Values will vary between machines. Use your own discretion when selecting these values.\*\***

Reviewed by Dr. Holdsworth 1/2025

\*Subject to change at the discretion of the radiologist due to clinical circumstances.\*



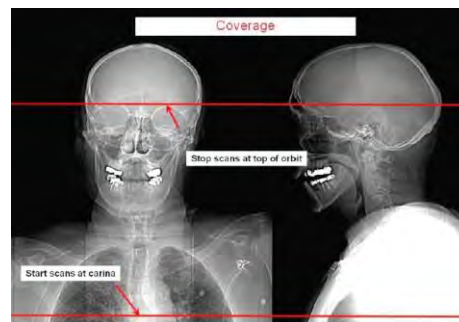
# CT Soft Tissue Neck



Diagnostic & Preventative Imaging Center

**Anatomical Reference:** Mid Neck  
**Patient Position:** Supine  
**Patient Orientation:** Head First  
**Scan Range:** Orbits to Carina

**Scout:** AP and Lateral  
**Scan Type:** Helical  
**Rotation Time:** 0.6  
**Thickness:** 3 mm, Recon as thin as possible  
**Interval:** 3 mm, Recon as thin as possible  
**Gantry Tilt:** None



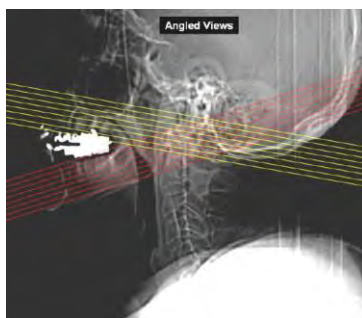
**\*\*If patient has significant dental hardware, scan additional angled axial views at 2 mm for 16 slices at two different angles - See Picture**

**SFOV:** Large  
**kVp:** 120  
**mAs:** Auto mA  
**Scan Delay:** 60 seconds, if contrast used  
**Respiration:** None  
**DFOV:** Adjust to patient size (Include nose in field)  
**Recon Algorithm:** Standard

**Contrast:** 80 mL Omnipaque 300 mg/mL or equivalent water soluble contrast @ 2-3 mL/sec

**Comments:**

1. Send 3 mm Soft Tissue Algorithm Axial Images to PACS
2. Send 2 mm Sagittal and Coronal Soft Tissue Algorithm Reconstructions to PACS
3. Send Angled Axial Images to PACS, if performed (Do not do recons on these series)
4. Send thin slices to 3D Workstation (Vitrea Bridge or TeraRecon)



Example of angled axial images, if necessary

\* Image courtesy of University of Wisconsin

## Indications

With Contrast: Infection, Mass, Adenopathy

Without Contrast: ONLY perform if patient unable to have contrast

With and Without Contrast: Rarely indicated - Consult radiologist

**\*\*Values will vary between machines. Use your own discretion when selecting these values.\*\***

Reviewed by Dr. Holdsworth 1/2025

\*Subject to change at the discretion of the radiologist due to clinical circumstances.\*



# CT C-Spine



Diagnostic & Preventative Imaging Center

<b>Anatomical Reference:</b>	Mid Neck
<b>Patient Position:</b>	Supine
<b>Patient Orientation:</b>	Head First
<b>Scan Range:</b>	C-1 thru C-7
<b>Scout:</b>	Lateral, AP if necessary
<b>Scan Type:</b>	Helical
<b>Rotation Time:</b>	1.0
<b>Thickness:</b>	3 mm, Recon as thin as possible
<b>Interval:</b>	3 mm, Recon as thin as possible
<b>Gantry Tilt:</b>	None
<b>SFOV:</b>	Small
<b>kVp:</b>	140
<b>mAs:</b>	Auto mA
<b>Scan Delay:</b>	None
<b>Respiration:</b>	None
<b>DFOV:</b>	Cone down to only include spine
<b>Recon Algorithm:</b>	See comments below
<b>Contrast:</b>	80 mL Omnipaque 300 mg/mL or equivalent water soluble contrast @ 2-3 mL/sec
<b>Comments:</b>	<ol style="list-style-type: none"><li>1. Send 2 mm Soft Tissue Axial Images to PACS</li><li>2. Send 2 mm Bone Algorithm Axial Images to PACS</li><li>3. Send 2 mm Bone Algorithm Sagittal and Coronal Reconstructions to PACS</li><li>4. Send 2 mm Soft Tissue Algorithm Sagittal Reconstructions to PACS</li><li>5. Send Soft Tissue Thin Slices to 3D Workstation (Vitrea Bridge or TeraRecon)</li></ol>

## Indications

Without Contrast:	Trauma, Fracture, Pain
With Contrast:	Infection or Tumor AND patient unable to have MRI
With and Without Contrast:	Rarely indicated - Consult radiologist

**\*\*Values will vary between machines. Use your own discretion when selecting these values.\*\***

Reviewed by Dr. Holdsworth 1/2025

\*Subject to change at the discretion of the radiologist due to clinical circumstances.\*



# CT T-Spine



Diagnostic & Preventative Imaging Center

<b>Anatomical Reference:</b>	Sternal Notch
<b>Patient Position:</b>	Supine
<b>Patient Orientation:</b>	Feet First
<b>Scan Range:</b>	T-1 thru T-12
<b>Scout:</b>	Lateral, AP if necessary
<b>Scan Type:</b>	Helical
<b>Rotation Time:</b>	1.0
<b>Thickness:</b>	3 mm, Recon as thin as possible
<b>Interval:</b>	3 mm, Recon as thin as possible
<b>Gantry Tilt:</b>	None
<b>SFOV:</b>	Large
<b>kVp:</b>	120
<b>mAs:</b>	Auto mA
<b>Scan Delay:</b>	None
<b>Respiration:</b>	None
<b>DFOV:</b>	Cone down to only include spine
<b>Recon Algorithm:</b>	See comments below
<b>Contrast:</b>	80 mL Omnipaque 300 mg/mL or equivalent water soluble contrast @ 2-3 mL/sec
<b>Comments:</b>	<ol style="list-style-type: none"><li>1. Send 2 mm Soft Tissue Axial Images to PACS</li><li>2. Send 2 mm Bone Algorithm Axial Images to PACS</li><li>3. Send 2 mm Bone Algorithm Sagittal and Coronal Reconstructions to PACS</li><li>4. Send 2 mm Soft Tissue Algorithm Sagittal Reconstructions to PACS</li><li>5. Send Soft Tissue Thin Slices to 3D Workstation (Vitrea Bridge or TeraRecon)</li></ol>

## Indications

Without Contrast:	Trauma, Fracture, Pain
With Contrast:	Infection or Tumor AND patient unable to have MRI
With and Without Contrast:	Rarely indicated - Consult radiologist

**\*\*Values will vary between machines. Use your own discretion when selecting these values.\*\***

Reviewed by Dr. Holdsworth 1/2025

\*Subject to change at the discretion of the radiologist due to clinical circumstances.\*



# CT L-Spine



Diagnostic & Preventative Imaging Center

<b>Anatomical Reference:</b>	Xyphoid
<b>Patient Position:</b>	Supine
<b>Patient Orientation:</b>	Feet First
<b>Scan Range:</b>	L-1 thru S-1
<b>Scout:</b>	Lateral, AP if necessary
<b>Scan Type:</b>	Helical
<b>Rotation Time:</b>	1.0
<b>Thickness:</b>	3 mm, Recon as thin as possible
<b>Interval:</b>	3 mm, Recon as thin as possible
<b>Gantry Tilt:</b>	None
<b>SFOV:</b>	Large
<b>kVp:</b>	120
<b>mAs:</b>	Auto mA
<b>Scan Delay:</b>	None
<b>Respiration:</b>	Inspiration
<b>DFOV:</b>	Cone down to only include spine
<b>Recon Algorithm:</b>	See comments below
<b>Contrast:</b>	80 mL Omnipaque 300 mg/mL or equivalent water soluble contrast @ 2-3 mL/sec
<b>Comments:</b>	<ol style="list-style-type: none"><li>1. Send 2 mm Soft Tissue Axial Images to PACS</li><li>2. Send 2 mm Bone Algorithm Axial Images to PACS</li><li>3. Send 2 mm Bone Algorithm Sagittal and Coronal Reconstructions to PACS</li><li>4. Send 2 mm Soft Tissue Algorithm Sagittal Reconstructions to PACS</li><li>5. Send Soft Tissue Thin Slices to 3D Workstation (Vitrea Bridge or TeraRecon)</li></ol>

## Indications

Without Contrast:	Trauma, Fracture, Pain
With Contrast:	Infection or Tumor AND patient unable to have MRI
With and Without Contrast:	Rarely indicated - Consult radiologist

**\*\*Values will vary between machines. Use your own discretion when selecting these values.\*\***

Reviewed by Dr. Holdsworth 1/2025

\*Subject to change at the discretion of the radiologist due to clinical circumstances.\*



# CT Chest Routine



Diagnostic & Preventative Imaging Center

<b>Anatomical Reference:</b>	Sternal Notch
<b>Patient Position:</b>	Supine
<b>Patient Orientation:</b>	Feet First
<b>Scan Range:</b>	Apices through Adrenal Glands
<b>Scout:</b>	AP, Lateral if necessary
<b>Scan Type:</b>	Helical
<b>Rotation Time:</b>	0.8
<b>Thickness:</b>	3 mm, Recon as thin as possible
<b>Interval:</b>	3 mm, Recon as thin as possible
<b>Gantry Tilt:</b>	None
<b>SFOV:</b>	Large
<b>kVp:</b>	120
<b>mAs:</b>	Auto mA (minimum 50-maximum 420)
<b>Scan Delay:</b>	Smart Prep (ROI-Aortic Arch, Scan Threshold-70 HU)
<b>Respiration:</b>	Inspiration
<b>DFOV:</b>	Adjust to patient size
<b>Recon Algorithm:</b>	Standard
<b>Contrast:</b>	Oral: None IV: 100 mL Omnipaque 300 mg/mL or equivalent water soluble contrast injected at 3 mL/sec
<b>Comments:</b>	1. Send 3 mm Soft Tissue Recon Algorithm Axial Images to PACS 2. Send 3 mm Lung Recon Algorithm Axial Images to PACS 3. Send 2 mm Sagittal and Coronal Reconstructions to PACS 4. Send thin slices to 3D Workstation (Vitrea Bridge or TeraRecon)

## Indications

Without Contrast:	Follow-Up Lung Nodule >8mm, Interstitial Lung Disease
With Contrast:	Cough, Smoker, Pneumonia, Emphysema, Follow-Up or Staging Lung Cancer, Follow-Up Lung Nodule

**\*\*Values will vary between machines. Use your own discretion when selecting these values.\*\***

Reviewed by Dr. King 1/2025

\*Subject to change at the discretion of the radiologist due to clinical circumstances.\*



# CT ION Chest

Performed at IMMC Only



Diagnostic & Preventative Imaging Center

**Anatomical Reference:** Sternal Notch  
**Patient Position:** Supine; Arms above head  
**Patient Orientation:** Feet First  
**Scan Range:** 2 cm above lung apexes through entire chest 2 cm below costophrenic angles

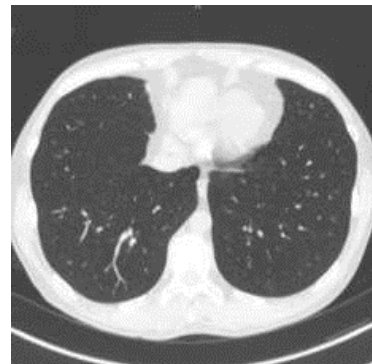
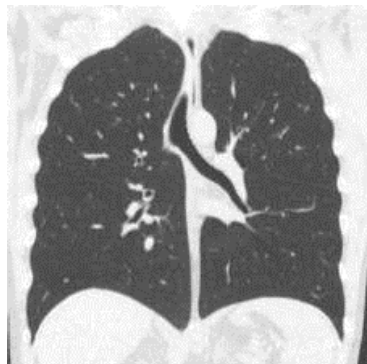
**Scout:** AP, Lateral  
**Scan Type:** Helical  
**Rotation Time:** Fastest to reduce motion  
**Thickness:** .5mm-1.0MM, Recon as thin as possible  
**Interval:** .5mm-.8mm, Recon as thin as possible  
**Gantry Tilt:** None  
**SFOV:** Large  
**kVp:** 110-140  
**mAs:** Auto mA (minimum 50-maximum 420)  
**Scan Delay:** None  
**Respiration:** Tech will give Full inspiration instructions  
**DFOV:** < 32cm  
**Recon Algorithm:** Standard

**Contrast:** Oral: None

**Comments:**

1. Send .7 mm FOV <32 Soft Tissue Recon Axial Images to Vitrea, Tera, ION
2. Send 3 mm Full FOV Soft Tissue Recon Algorithm Axial Images to PACS
3. Send 3 mm Full FOV Lung Recon Algorithm Axial Images to PACS
4. Send 2 mm Full FOV Sagittal and Coronal Reconstructions to PACS

Scan Patients in the same position that will be used during the procedure



**\*\*Values will vary between machines. Use your own discretion when selecting these values.\*\***

Reviewed by Dr. King 9/2023

\*Subject to change at the discretion of the radiologist due to clinical circumstances.\*



# CT Chest High Resolution

Over 18



Diagnostic & Preventative Imaging Center

<b>Anatomical Reference:</b>	Sternal Notch
<b>Patient Position:</b>	Supine
<b>Patient Orientation:</b>	Feet First
<b>Scan Range:</b>	Apices through Lung Base
<b>Scout:</b>	AP, Lateral if necessary
<b>Scan Type:</b>	Helical
<b>Rotation Time:</b>	0.8
<b>Thickness:</b>	1 mm
<b>Interval:</b>	1 mm
<b>Gantry Tilt:</b>	None
<b>SFOV:</b>	Large
<b>kVp:</b>	120
<b>mAs:</b>	Auto mA (minimum 50-maximum 420)
<b>Scan Delay:</b>	None
<b>Respiration:</b>	Series 1 - Inspiration Series 2 - Expiration
<b>DFOV:</b>	Adjust to patient size
<b>Recon Algorithm:</b>	Series 1 - Bone Plus (Detailed Lung) Series 2 - Bone Plus (Detailed Lung)

<b>Contrast:</b>	Oral: None
	IV: None

<b>Comments:</b>	History of Cystic Fibrosis - Call Radiologist
	1. Series 1 - Inspiration - Scan using High Res technique
	- Send 1 mm Inspiration High Res Lung Images to PACS.
	- Send 3 mm Mediastinum Images to PACS.
	- Send 3 mm Sagittal and Coronal Mediastinum Reconstructions to PACS.
	- Send Thin Inspiration Lung Windows to 3D Workstation (Vitrea Bridge or TeraRecon)
	2. Series 2 - Expiration - Scan using High Res technique
	- Send 1 mm Expiration High Res Lung Images to PACS.

## Indications

Without Contrast:	Interstitial Lung Disease, Bronchiectasis
-------------------	---

**\*\*Values will vary between machines. Use your own discretion when selecting these values.\*\***

Reviewed by Dr. Keller 6/2021

\*Subject to change at the discretion of the radiologist due to clinical circumstances.\*



# CT Chest High Resolution

Under 18



Diagnostic & Preventative Imaging Center

<b>Anatomical Reference:</b>	Sternal Notch
<b>Patient Position:</b>	Prone
<b>Patient Orientation:</b>	Feet First
<b>Scan Range:</b>	Apices through Lung Base
<b>Scout:</b>	AP, Lateral if necessary
<b>Scan Type:</b>	Axial
<b>Rotation Time:</b>	0.8
<b>Thickness:</b>	2 mm, Recon as thin as possible
<b>Interval:</b>	2 mm, Recon as thin as possible
<b>Gantry Tilt:</b>	None
<b>SFOV:</b>	Large
<b>kVp:</b>	120
<b>mAs:</b>	Auto mA (minimum 50-maximum 420)
<b>Scan Delay:</b>	None
<b>Respiration:</b>	Inspiration
<b>DFOV:</b>	Adjust to patient size
<b>Recon Algorithm:</b>	Standard
<b>Contrast:</b>	Oral:       None IV:         None
<b>Comments:</b>	1. Send 2 mm Axial Mediastinum Windows to PACS 2. Send 2 mm Axial High Res Lung Windows to PACS 3. Send 3 mm Sagittal and Coronal Mediastinum Reconstructions to PACS 3. Send thin slices to 3D Workstation (Vitrea Bridge or TeraRecon)

## Indications

Without Contrast:                   Interstitial Lung Disease, Bronchiectasis

**\*\*Values will vary between machines. Use your own discretion when selecting these values.\*\***

Reviewed by Dr. Steinberg 4/2019

\*Subject to change at the discretion of the radiologist due to clinical circumstances.\*



# CT Low Dose Lung Screen



Diagnostic & Preventative Imaging Center

**Anatomical Reference:** Sternal Notch  
**Patient Position:** Supine  
**Patient Orientation:** Feet First  
**Scan Range:** Apices through Lung Base

**Scout:** AP, Lateral if necessary  
**Scan Type:** Helical  
**Rotation Time:** 0.5  
**Thickness:** 1 mm  
**Interval:** 1 mm  
**Gantry Tilt:** None  
**SFOV:** Large  
**kVp:** 120  
**mAs:** Use low dose technique  
**Scan Delay:** None  
**Respiration:** Inspiration  
**DFOV:** Adjust to patient size  
**Recon Algorithm:** Standard

**Contrast:** Oral: None  
IV: None

**Comments:**

1. Send 3 mm Mediastinum Algorithm Axial Images to PACS
2. Send 1.5 mm Mediastinum Algorithm Axial Images to PACS
3. Send 3 mm Mediastinum Algorithm Sagittal and Coronal Reconstructions to PACS
4. Send thin (recon to 0.6mm) Abdomen Algorithm Images to 3D Workstation (Vitrea Bridge or TeraRecon)

**Notes:**

\*\*\*\* For patients having a lung screening exam which requires a 3 or 6 month follow up, the follow up exam should be scanned using the low dose protocol but billed as a CT Chest WO Contrast

\*\*\*\* On follow up exams, be sure to add a comment for the radiologist that the scan is a lung screen F/U so the correct dictation template is used.

## Indications

Without Contrast: Screening

**\*\*Values will vary between machines. Use your own discretion when selecting these values.\*\***

Reviewed by Dr. Smith 1/2023

\*Subject to change at the discretion of the radiologist due to clinical circumstances.\*



# CT Cardiac Calcium Score



Diagnostic & Preventative Imaging Center

<b>Anatomical Reference:</b>	Top of the Shoulders
<b>Patient Position:</b>	Supine
<b>Patient Orientation:</b>	Feet First
<b>Scan Range:</b>	Carina thru Base of Heart
<b>Scout:</b>	AP
<b>Scan Type:</b>	Axial
<b>Thickness:</b>	3 mm
<b>Interval:</b>	3 mm
<b>Gantry Tilt:</b>	None
<b>SFOV:</b>	Large
<b>kVp:</b>	120
<b>mAs:</b>	Auto mA
<b>Scan Delay:</b>	None
<b>Respiration:</b>	Inspiration
<b>DFOV:</b>	Varied
<b>Recon Algorithm:</b>	Mediastinum
<b>Contrast:</b>	None
<b>Comments:</b>	<ol style="list-style-type: none"><li>1. Send Mediastinum windows to PACS</li><li>2. Send Mediastinum windows to 3D Workstation (TeraRecon)</li><li>3. Use 4 lead EKG for gating</li><li>4. Female patients must remove bra prior to scan</li></ol>

## Indications

Without Contrast: Screening, Elevated Cholesterol, Hypertension, Diabetes, Atypical Chest Pain

**\*\*Values will vary between machines. Use your own discretion when selecting these values.\*\***

Reviewed by Dr. Walker 6/2017

\*Subject to change at the discretion of the radiologist due to clinical circumstances.\*



# CT Esophagram

## Esophageal Leak Study



Diagnostic & Preventative Imaging Center

<b>Anatomical Reference:</b>	Mid neck
<b>Patient Position:</b>	Supine
<b>Patient Orientation:</b>	Feet First
<b>Scan Range:</b>	Mid Neck (C4/C5) thru Stomach (L2/L3)
<b>Scout:</b>	AP, Lateral if necessary
<b>Scan Type:</b>	Helical
<b>Rotation Time:</b>	0.8
<b>Thickness:</b>	3 mm, Recon as thin as possible
<b>Interval:</b>	3 mm, Recon as thin as possible
<b>Gantry Tilt:</b>	None
<b>SFOV:</b>	Large
<b>kVp:</b>	120
<b>mAs:</b>	Auto mA (minimum 50-maximum 420)
<b>Scan Delay:</b>	None
<b>Respiration:</b>	Inspiration
<b>DFOV:</b>	Adjust to patient size
<b>Recon Algorithm:</b>	Standard
<b>Contrast:</b>	Oral: Dilute 15 mL Omnipaque 350 or equivalent water soluble contrast in 10 oz bottled or sterile water IV: None
<b>Comments:</b>	<p><b>**Patient needs to be NPO for 2 hours prior to exam</b></p> <ol style="list-style-type: none"><li>1. Series 1 - Non contrast</li><li>2. Series 2 - Oral Contrast - The patient drinks all of the contrast - Scan immediately</li></ol> <p><b>The shorter the time period between swallowing oral contrast and imaging acquisition, the better the diagnostic value</b></p> <ol style="list-style-type: none"><li>1. Send 3 mm Axial Images to PACS</li><li>2. Send 2 mm Sagittal and Coronal Reconstructions to PACS</li><li>3. Send thin slices to 3D Workstation (Vitrea Bridge or TeraRecon)</li></ol>

## Indications

Without Contrast: Esophageal leak or rupture

**\*\*Values will vary between machines. Use your own discretion when selecting these values.\*\***

Reviewed by Dr. Becker 1/2025

\*Subject to change at the discretion of the radiologist due to clinical circumstances.\*



# CT Trauma

## Chest/Abd/Pelvis



Diagnostic & Preventative Imaging Center

<b>Anatomical Reference:</b>	Sternal Notch
<b>Patient Position:</b>	Supine
<b>Patient Orientation:</b>	Head First
<b>Scan Range:</b>	Apices through Ischial Tuberosities
<b>Scout:</b>	AP, Lateral if necessary
<b>Scan Type:</b>	Helical
<b>Rotation Time:</b>	0.8
<b>Thickness:</b>	3 mm, Recon as thin as possible
<b>Interval:</b>	3 mm, Recon as thin as possible
<b>Gantry Tilt:</b>	None
<b>SFOV:</b>	Large
<b>kVp:</b>	120
<b>mAs:</b>	Auto mA (minimum 50-maximum 420)
<b>Scan Delay:</b>	60 seconds
<b>Respiration:</b>	Inspiration
<b>DFOV:</b>	Adjust to patient size
<b>Recon Algorithm:</b>	Standard
<b>Contrast:</b>	Oral: None IV: 100 mL Omnipaque 300 mg/mL or equivalent water soluble contrast injected at 2-3 mL/sec, preferred
<b>Comments:</b>	<ol style="list-style-type: none"><li>1. Send 3 mm Soft Tissue Recon Algorithm Axial Images to PACS</li><li>2. Send 3 mm Lung Recon Algorithm Axial Images of entire Chest/Adomen/Pelvis to PACS</li><li>3. Send 2 mm Soft Tissue Sagittal and Coronal Reconstructions to PACS</li><li>4. Send 2 mm Bone Recon Algorithm Sagittal and Coronal Reconstructions to PACS</li><li>5. Send thin slices to 3D Workstation (Vitrea Bridge or TeraRecon)</li><li>6. Delay images only if requested by ER or trauma physician</li></ol>

## Indications

With Contrast: Trauma

**\*\*Values will vary between machines. Use your own discretion when selecting these values.\*\***

Reviewed by Dr. King 1/2025

\*Subject to change at the discretion of the radiologist due to clinical circumstances.\*



# CT Abd/Pelvis

Routine



<b>Anatomical Reference:</b>	Xyphoid				
<b>Patient Position:</b>	Supine				
<b>Patient Orientation:</b>	Feet First				
<b>Scan Range:</b>	Dome of Diaphragm through Ischial Tuberosities				
<b>Scout:</b>	AP, Lateral if necessary				
<b>Scan Type:</b>	Helical				
<b>Rotation Time:</b>	0.8				
<b>Thickness:</b>	3 mm, Recon as thin as possible				
<b>Interval:</b>	3 mm, Recon as thin as possible				
<b>Gantry Tilt:</b>	None				
<b>SFOV:</b>	Large				
<b>kVp:</b>	120				
<b>mAs:</b>	Auto mA (minimum 50-maximum 420)				
<b>Scan Delay:</b>	60 seconds				
<b>Respiration:</b>	Inspiration				
<b>DFOV:</b>	Adjust to patient size				
<b>Recon Algorithm:</b>	Standard				
<b>Contrast:</b>	<table><tr><td>Oral:</td><td><b>See notes below</b> - 1000 mL diluted contrast 1-2 hours prior to CT OR 1000 mL Ready to Drink (RTD) Omnipaque Oral Solution 1-2 hours prior to CT</td></tr><tr><td>IV:</td><td>100 mL Omnipaque 300 mg/mL or equivalent water soluble contrast injected at 2-3 mL/sec</td></tr></table>	Oral:	<b>See notes below</b> - 1000 mL diluted contrast 1-2 hours prior to CT OR 1000 mL Ready to Drink (RTD) Omnipaque Oral Solution 1-2 hours prior to CT	IV:	100 mL Omnipaque 300 mg/mL or equivalent water soluble contrast injected at 2-3 mL/sec
Oral:	<b>See notes below</b> - 1000 mL diluted contrast 1-2 hours prior to CT OR 1000 mL Ready to Drink (RTD) Omnipaque Oral Solution 1-2 hours prior to CT				
IV:	100 mL Omnipaque 300 mg/mL or equivalent water soluble contrast injected at 2-3 mL/sec				
<b>Comments:</b>	<ol style="list-style-type: none"><li>1. Send 3 mm Axial Images to PACS</li><li>2. Send 2 mm Sagittal and Coronal Reconstructions to PACS</li><li>3. Send thin slices to 3D Workstation (Vitrea Bridge or TeraRecon)</li><li>4. Renal/bladder delays not routinely indicated. Contact the on site radiologist if there are questions.</li></ol>				
<b>Oral Contrast Notes:</b>	<ol style="list-style-type: none"><li>1. Oral contrast not needed for most exams.</li><li>2. Give oral contrast for:<ol style="list-style-type: none"><li>a. Any history of pelvic radiation therapy</li><li>b. PARTIAL small bowel obstruction (SBO) (Complete or High grade SBO = NO oral contrast)</li><li>c. Recently treated SBO (e.g. floor patients with an NG tube for a couple days)</li></ol></li></ol>				

*Continued on next page*

Reviewed by Dr. King 1/2025

\*Subject to change at the discretion of the radiologist due to clinical circumstances.\*



# CT Abdomen/Pelvis - Routine Cont.

## Oral Contrast Notes:

- d. Abscess
- e. Symptoms of appendicitis for 3 days or more
- f. Low BMI (24 or less)
- g. Postop from any major bowel surgery including bariatrics
- h. Any Gynecologic Oncology patient of Dr. Elg
- i. Ovarian pathology / Tubo-ovarian abscess
- j. GI fistula
- k. Duplication cyst
- l. Follow up of gastrointestinal or mesenteric trauma
- m. Crohn's Disease

## Indications

With Contrast:                      Routine, Follow-Up, Pain

**\*\*Values will vary between machines. Use your own discretion when selecting these values.\*\***

Reviewed by Dr. King 1/2025

\*Subject to change at the discretion of the radiologist due to clinical circumstances.\*



# CT Abd/Pelvis

Adult ER Belly Pain



Diagnostic & Preventative Imaging Center

<b>Anatomical Reference:</b>	Xyphoid
<b>Patient Position:</b>	Supine
<b>Patient Orientation:</b>	Feet First
<b>Scan Range:</b>	Dome of Diaphragm through Ischial Tuberosities
<b>Scout:</b>	AP, Lateral if necessary
<b>Scan Type:</b>	Helical
<b>Rotation Time:</b>	0.8
<b>Thickness:</b>	3 mm, Recon as thin as possible
<b>Interval:</b>	3 mm, Recon as thin as possible
<b>Gantry Tilt:</b>	None
<b>SFOV:</b>	Large
<b>kVp:</b>	120
<b>mAs:</b>	Auto mA (minimum 50-maximum 420)
<b>Scan Delay:</b>	60 seconds
<b>Respiration:</b>	Inspiration
<b>DFOV:</b>	Adjust to patient size
<b>Recon Algorithm:</b>	Standard
<b>Contrast:</b>	<p>Oral: <b>See notes below</b> - 1000 mL diluted contrast 1-2 hours prior to CT OR 1000 mL Ready to Drink (RTD) Omnipaque Oral Solution 1-2 hours prior to CT</p> <p>IV: 100 mL Omnipaque 300 mg/mL or equivalent water soluble contrast injected at 2-3 mL/sec</p>
<b>Comments:</b>	<ol style="list-style-type: none"><li>1. Send 3 mm Axial Images to PACS</li><li>2. Send 2 mm Sagittal and Coronal Reconstructions to PACS</li><li>3. Send thin slices to 3D Workstation (Vitrea Bridge or TeraRecon)</li><li>4. Renal/bladder delays not routinely indicated. Contact the on site radiologist if there are questions.</li></ol>
<b>Oral Contrast Notes:</b>	<p>1. <b>Give oral contrast for:</b></p> <ol style="list-style-type: none"><li>a. Recent (<math>\leq 2</math> months) hx of abdominal surgery</li><li>b. BMI <math>\leq 24</math></li><li>c. Any hx of inflammatory bowel disease (i.e. Crohns or ulcerative</li><li>d. Any hx major complex oncologic abdominal/pelvic cancer surgery (i.e. gyn-onc, whipple surgery)</li><li>e. Lower abdominal pain <math>&gt; 3</math> days with concern for abscess</li><li>f. Concern for partial SBO (no vomiting, passing gas/stool) should receive oral contrast, regardless of BMI</li></ol>

*Continued on next page*

Reviewed by Dr. King 1/2025

\*Subject to change at the discretion of the radiologist due to clinical circumstances.\*



# CT Abdomen/Pelvis - ER Cont.

## Oral Contrast Notes:

g. Crohns disease

### 2. Plain film first:

- a. Surgical abdomen (i.e. rigid abd, generalized peritonitis, concern for perforation/free air)
- b. High grade SBO (i.e. vomiting, obstipation, distension, hx prior abdominal surgeries)

*Pending results of Plain Film - Should consult surgery prior to ordering CT*

### 3. Without oral contrast for:

- a. Uncomplicated appendicitis, uncomplicated diverticulitis, uncomplicated colitis or pyelonephritis
- b. Recent trauma

## Indications

With Contrast: Adult patients presenting to ER with belly pain

**\*\*Values will vary between machines. Use your own discretion when selecting these values.\*\***

Reviewed by Dr. King 1/2025

\*Subject to change at the discretion of the radiologist due to clinical circumstances.\*



# CT Abd/Pelvis

## Appy Protocol



Diagnostic & Preventative Imaging Center

<b>Anatomical Reference:</b>	Xyphoid				
<b>Patient Position:</b>	Supine				
<b>Patient Orientation:</b>	Feet First				
<b>Scan Range:</b>	Dome of Diaphragm through Ischial Tuberosities				
<b>Scout:</b>	AP, Lateral if necessary				
<b>Scan Type:</b>	Helical				
<b>Rotation Time:</b>	0.8				
<b>Thickness:</b>	3 mm, Recon as thin as possible				
<b>Interval:</b>	3 mm, Recon as thin as possible				
<b>Gantry Tilt:</b>	None				
<b>SFOV:</b>	Large				
<b>kVp:</b>	120				
<b>mAs:</b>	Auto mA (minimum 50-maximum 420)				
<b>Scan Delay:</b>	60 seconds				
<b>Respiration:</b>	Inspiration				
<b>DFOV:</b>	Adjust to patient size				
<b>Recon Algorithm:</b>	Standard				
<b>Contrast:</b>	<table><tr><td>Oral:</td><td>None, except for symptoms of appendicitis for 3 days or more, then give: 1000 mL diluted contrast 1-2 hours prior to CT OR 1000 mL Ready to Drink (RTD) Omnipaque Oral Solution 1-2 hours prior to CT</td></tr><tr><td>IV:</td><td>100 mL Omnipaque 300 mg/mL or equivalent water soluble contrast injected at 2-3 mL/sec</td></tr></table>	Oral:	None, except for symptoms of appendicitis for 3 days or more, then give: 1000 mL diluted contrast 1-2 hours prior to CT OR 1000 mL Ready to Drink (RTD) Omnipaque Oral Solution 1-2 hours prior to CT	IV:	100 mL Omnipaque 300 mg/mL or equivalent water soluble contrast injected at 2-3 mL/sec
Oral:	None, except for symptoms of appendicitis for 3 days or more, then give: 1000 mL diluted contrast 1-2 hours prior to CT OR 1000 mL Ready to Drink (RTD) Omnipaque Oral Solution 1-2 hours prior to CT				
IV:	100 mL Omnipaque 300 mg/mL or equivalent water soluble contrast injected at 2-3 mL/sec				
<b>Comments:</b>	<ol style="list-style-type: none"><li>1. No preliminary non-contrast scans necessary.</li><li>2. For all abdominal CT's in which there is a concern for or history of recent abscess, oral contrast is needed in addition to IV.</li><li>3. Send 3 mm Axial Images to PACS</li><li>4. Send 2 mm Sagittal and Coronal Reconstructions to PACS</li><li>5. Send thin slices to 3D Workstation (Vitrea Bridge or TeraRecon)</li><li>6. Renal/bladder delays not routinely indicated. Contact the on site radiologist if there are questions.</li><li>7. For symptoms of appendicitis for 3 days or more, give oral and IV contrast.</li></ol>				

## Indications

With Contrast: RLQ Pain, Elevated WBC, Fever

**\*\*Values will vary between machines. Use your own discretion when selecting these values.\*\***

Reviewed by Dr. King 1/2025

\*Subject to change at the discretion of the radiologist due to clinical circumstances.\*



# CT Abd/Pelvis

## Renal Stone Protocol



Diagnostic & Preventative Imaging Center

**Anatomical Reference:** Xyphoid  
**Patient Position:** Supine  
**Patient Orientation:** Feet First  
**Scan Range:** Dome of Diaphragm through Ischial Tuberosities

**Scout:** AP, Lateral if necessary  
**Scan Type:** Helical  
**Rotation Time:** 0.8  
**Thickness:** 3 mm, Recon as thin as possible  
**Interval:** 3 mm, Recon as thin as possible  
**Gantry Tilt:** None  
**SFOV:** Large  
**kVp:** 120  
**mAs:** Auto mA (minimum 50-maximum 420)  
**Scan Delay:** None  
**Respiration:** Inspiration  
**DFOV:** Adjust to patient size  
**Recon Algorithm:** Standard

**Contrast:**  
Oral: None  
IV: None

**Comments:**

1. Send 3 mm Axial Images to PACS
2. Send 2 mm Sagittal and Coronal Reconstructions to PACS
3. Send thin slices to 3D Workstation (Vitrea Bridge or TeraRecon)
4. Check scans with radiologist before patient leaves to make sure contrast is not necessary.

## Indications

Without Contrast: Hematuria, Flank Pain, Hx Stones

**\*\*Values will vary between machines. Use your own discretion when selecting these values.\*\***

Reviewed by Dr. King 1/2019 / Dr. Keller 1/2019

\*Subject to change at the discretion of the radiologist due to clinical circumstances.\*



# CT Abd/Pelvis

Venogram



**\* Call radiologist before the exam. Radiologist needs to review 100 second acquisition immediately.\***

<b>Anatomical Reference:</b>	Xyphoid
<b>Patient Position:</b>	Supine
<b>Patient Orientation:</b>	Feet First
<b>Scan Range:</b>	Dome of Diaphragm through Ischial Tuberosities
<b>Scout:</b>	AP, Lateral if necessary
<b>Scan Type:</b>	Helical
<b>Rotation Time:</b>	0.8
<b>Thickness:</b>	3 mm, Recon as thin as possible
<b>Interval:</b>	3 mm, Recon as thin as possible
<b>Gantry Tilt:</b>	None
<b>SFOV:</b>	Large
<b>kVp:</b>	120
<b>mAs:</b>	Auto mA (minimum 50-maximum 420)
<b>Scan Delay:</b>	Series 1 - 100 seconds; Series 2 - 4 minutes
<b>Respiration:</b>	Inspiration
<b>DFOV:</b>	Adjust to patient size
<b>Recon Algorithm:</b>	Standard
<b>Contrast:</b>	Oral: None IV: 150 mL Omnipaque 300 mg/mL or Omnipaque 350 mg/mL or equivalent water soluble contrast injected at 2-3 mL/sec
<b>Comments:</b>	1. Series 1 - 100 second delay - Dome of diaphragm through pubic symphysis <b>*Radiologist Review*</b> 2. Series 2 - 4 minute delays - Dome of diaphragm through pubic symphysis 3. Send 3 mm Axial Images to PACS 4. Send 2 mm Sagittal and Coronal Reconstructions to PACS 5. Send thin slices to 3D Workstation (Vitrea Bridge or TeraRecon)

## Indications

With Contrast: Blood Clot in IVC

**\*\*Values will vary between machines. Use your own discretion when selecting these values.\*\***

Reviewed by Dr. King 1/2025

\*Subject to change at the discretion of the radiologist due to clinical circumstances.\*



# CT Liver

## 3 Phase



Diagnostic & Preventative Imaging Center

<b>Anatomical Reference:</b>	Xyphoid
<b>Patient Position:</b>	Supine
<b>Patient Orientation:</b>	Feet First
<b>Scan Range:</b>	Dome of Diaphragm to Iliac Crest
<b>Scout:</b>	AP, Lateral if necessary
<b>Scan Type:</b>	Helical
<b>Rotation Time:</b>	0.8
<b>Thickness:</b>	3 mm, Recon as thin as possible
<b>Interval:</b>	3 mm, Recon as thin as possible
<b>Gantry Tilt:</b>	None
<b>SFOV:</b>	Large
<b>kVp:</b>	120
<b>mAs:</b>	Auto mA (minimum 50-maximum 420)
<b>Scan Delay:</b>	Arterial - 30-35 sec; Venous - 70sec; Series 4 - 5 min
<b>Respiration:</b>	Inspiration
<b>DFOV:</b>	Adjust to patient size
<b>Recon Algorithm:</b>	Standard
<b>Contrast:</b>	Oral: None IV: 120 mL Omnipaque 300 mg/mL or equivalent water soluble contrast injected at 5 mL/sec
<b>Comments:</b>	<ol style="list-style-type: none"><li>1. Series 1 - Without Contrast</li><li>2. Series 2 - Arterial Phase</li><li>3. Series 3 - Venous Phase</li><li>4. Series 4 - 5 minute delay</li><li>5. OPTIONAL - If performed specifically for hemangioma, add: Series 5 - 10 minute delay</li><li>6. Send 3 mm Axial Images (Series 1-4) to PACS</li><li>7. Send 2 mm Sagittal and Coronal Reconstructions (Series 1-3) to PACS</li><li>8. Send thin images (Series 1-4) to 3D Workstation (Vitrea Bridge or TeraRecon)</li><li>9. A proper hepatic arterial phase is when the hepatic artery is heavily contrasted and there is a trace amount of contrast in the portal vein.</li></ol>

## Indications

With & Without Contrast:	Known Liver Mass/Hepatoma, S/P Radiofrequency Ablation (RFA), S/P Chemotherapy, Embolization, Follow Up Known Hemangioma
--------------------------	--

**\*\*Values will vary between machines. Use your own discretion when selecting these values.\*\***

Reviewed by Dr. King 1/2025

\*Subject to change at the discretion of the radiologist due to clinical circumstances.\*



# CT Adrenals



Diagnostic & Preventative Imaging Center

<b>Anatomical Reference:</b>	Xyphoid
<b>Patient Position:</b>	Supine
<b>Patient Orientation:</b>	Feet First
<b>Scan Range:</b>	Dome of Diaphragm to Iliac Crest
<b>Scout:</b>	AP, Lateral if necessary
<b>Scan Type:</b>	Helical
<b>Rotation Time:</b>	0.8
<b>Thickness:</b>	3 mm, Recon as thin as possible
<b>Interval:</b>	3 mm, Recon as thin as possible
<b>Gantry Tilt:</b>	None
<b>SFOV:</b>	Large
<b>kVp:</b>	120
<b>mAs:</b>	Auto mA (minimum 50-maximum 420)
<b>Scan Delay:</b>	Venous - 70 sec, Series 3 - 15 minutes
<b>Respiration:</b>	Inspiration
<b>DFOV:</b>	Adjust to patient size
<b>Recon Algorithm:</b>	Standard
<b>Contrast:</b>	Oral: None IV: 130 mL Omnipaque 300 mg/mL or equivalent water soluble contrast injected at 2 mL/sec
<b>Comments:</b>	<ol style="list-style-type: none"><li>1. Series 1 - Without Contrast to Localize Adrenals</li><li>2. Series 2 - Venous Phase - Dome of Diaphragm to the Iliac Crest, <b>or through Pubic Symphysis if Pelvis ordered</b></li><li>3. Series 3 - 15 minute delay from Dome of Diaphragm to Iliac Crest, <b>or from Dome of Diaphragm through Pubic Symphysis if Pelvis ordered</b></li><li>4. Send 3 mm Axial Images (Series 1-3) to PACS</li><li>5. Send 2 mm Sagittal and Coronal Reconstructions (Series 1 &amp; 2) to PACS</li><li>6. Send thin images (Series 1-3) to 3D Workstation (Vitrea Bridge or TeraRecon)</li></ol>

## Indications

With & Without Contrast: Adrenal Mass, Adrenal F/U, Pheochromocytoma

**\*\*Values will vary between machines. Use your own discretion when selecting these values.\*\***

Reviewed by Dr. King 1/2025

\*Subject to change at the discretion of the radiologist due to clinical circumstances.\*



# CT Pancreas



Diagnostic & Preventative Imaging Center

**Anatomical Reference:** Xyphoid  
**Patient Position:** Supine  
**Patient Orientation:** Feet First  
**Scan Range:** Dome of Diaphragm to Iliac Crest

**Scout:** AP, Lateral if necessary  
**Scan Type:** Helical  
**Rotation Time:** 0.8  
**Thickness:** 3 mm, Recon as thin as possible  
**Interval:** 3 mm, Recon as thin as possible  
**Gantry Tilt:** None  
**SFOV:** Large  
**kVp:** 120  
**mAs:** Auto mA (minimum 50-maximum 420)  
**Scan Delay:** Arterial - 25 sec, Venous - 60 sec, Series 4 - 5 min  
**Respiration:** Inspiration  
**DFOV:** Adjust to patient size  
**Recon Algorithm:** Standard

**Contrast:**

Oral: 200 mL diluted contrast 15-20 minutes prior to scanning  
**EXCEPTION**, if recent post-op, following recent abscess in upper abdomen or gastric outlet, or duodenal obstruction, then give:  
1000 mL diluted contrast 1-2 hour prior to CT plus 200 mL diluted contrast just prior to scanning OR  
1000 mL Ready to Drink (RTD) Omnipaque Oral Solution 1-2 hours prior to CT plus 200 mL diluted contrast just prior to scanning

IV: 120 mL Omnipaque 300 mg/mL or equivalent water soluble contrast injected at 4 mL/sec

**Comments:** **All series must include entire pancreas - Scan from top of liver through bottom of duodenal sweep or iliac crest, whichever is lower.**

1. Series 1 - Without Contrast
2. Series 2 - Arterial Phase
3. Series 3 - Venous Phase
4. Series 4 - 5 minute delay
5. Send 3 mm Axial Images (Series 1-4) to PACS
6. Send 2 mm Sagittal and Coronal Reconstructions (Series 1-3) to PACS
7. Send thin images (Series 1-4) to 3D Workstation (Vitrea Bridge or TeraRecon)

## Indications

With & Without Contrast: Epigastric Pain, Elevated Amylase-Lipase, Pancreatitis

**\*\*Values will vary between machines. Use your own discretion when selecting these values.\*\***

Reviewed by Dr. King 1/2025

\*Subject to change at the discretion of the radiologist due to clinical circumstances.\*



# CT Kidneys /Mass



Diagnostic & Preventative Imaging Center

**\*If ordered as CT Abdomen & Pelvis, see notes below.\***

<b>Anatomical Reference:</b>	Xyphoid
<b>Patient Position:</b>	Supine
<b>Patient Orientation:</b>	Feet First
<b>Scan Range:</b>	Dome of Diaphragm to Iliac Crest
<b>Scout:</b>	AP, Lateral if necessary
<b>Scan Type:</b>	Helical
<b>Rotation Time:</b>	0.8
<b>Thickness:</b>	3 mm, Recon as thin as possible
<b>Interval:</b>	3 mm, Recon as thin as possible
<b>Gantry Tilt:</b>	None
<b>SFOV:</b>	Large
<b>kVp:</b>	120
<b>mAs:</b>	Auto mA (minimum 50-maximum 420)
<b>Scan Delay:</b>	Arterial - 30 sec; Nephrographic - 60 sec; Delays - 10 mins
<b>Respiration:</b>	Inspiration
<b>DFOV:</b>	Adjust to patient size
<b>Recon Algorithm:</b>	Standard
<b>Contrast:</b>	Oral: None IV: 120 mL Omnipaque 300 mg/mL or equivalent water soluble contrast injected at 4 mL/sec
<b>Comments:</b>	<ol style="list-style-type: none"><li>1. Series 1 - Without Contrast - Dome of Diaphragm to the Iliac Crest</li><li>2. Series 2 - Arterial Phase - Dome of Diaphragm to the Iliac Crest</li><li>3. Series 3 - Nephrographic Phase - Dome of Diaphragm to the Iliac Crest</li><li>4. Series 4 - Delayed Kidneys - 10 minute delay</li><li>5. Send 3 mm Axial Images (Series 1-4) to PACS</li><li>6. Send 2 mm Sagittal and Coronal Reconstructions (Series 1-4) to PACS</li><li>7. Send thin images (Series 1-4) to 3D Workstation (Vitrea Bridge or TeraRecon)</li><li>8. <i>When a pelvis is also ordered, contact Dr. King or the on site radiologist for pelvis protocol. Default protocol for pelvis portion is a single run in the portal venous phase.</i></li></ol>

## Indications

With & Without Contrast:	F/U suspected mass on other study, Known renal mass, Follow up abscess, renal trauma, infarction, laceration, etc.
--------------------------	--

**\*\*Values will vary between machines. Use your own discretion when selecting these values.\*\***

Reviewed by Dr. King 1/2025

\*Subject to change at the discretion of the radiologist due to clinical circumstances.\*



# CT Urogram

Split Bolus Protocol



Diagnostic & Preventative Imaging Center

**\*If a CT Urogram is ordered for renal mass, scan according to CT Kidney/Mass protocol (to include pelvis)**

**Anatomical Reference:** Xyphoid  
**Patient Position:** Supine  
**Patient Orientation:** Feet First  
**Scan Range:** Dome of Diaphragm to Ischial Tuberosities

**Scout:** AP, Lateral if necessary  
**Scan Type:** Helical  
**Thickness:** Variable, See comments  
**Interval:** Variable, See comments  
**Gantry Tilt:** None  
**SFOV:** Large  
**kVp:** 120  
**mAs:** Auto mA (minimum 50-maximum 420)  
**Scan Delay:** See below  
**Respiration:** Inspiration  
**DFOV:** Adjust to patient size  
**Recon Algorithm:** Standard

**Contrast:**  
Oral: 200 mL water on the CT scan table  
IV: 50 mL Omnipaque 300 or Isovue 300 mg/mL + 50 mL Saline flush injected at 1.5 mL/sec **Wait 10 minutes**  
100 mL Omnipaque 300 or Isovue 300 mg/mL + 50 mL Saline flush injected at 3 mL/sec

**Comments:**

1. Patient needs to arrive with a full bladder. Have patient void before bringing to the scanner.
2. Series 1 - Without Contrast - Dome of Diaphragm to Pubic Symphysis (3 mm slice thickness) - Call radiologist if obvious ureter stone, otherwise proceed.
3. INJECTION - Inject 50 mL of contrast + 50 mL saline flush @ 1.5 mL/second. Wait 10 minutes, THEN proceed with the next series.
4. Series 2 - Parenchymal Phase - Inject 100 mL of contrast + 50 mL saline flush @ 3mL/second. Start the scan after a 115 second delay (build delay into scan protocol if possible) - Scan Dome of Diaphragm to Pubic Symphysis
5. Send Axial Images (Series 1 & 2) to PACS
6. Send 2 mm Sagittal & Coronal Reconstructions (Series 1 & 2) to PACS
7. Send thin slices (all series) to 3D Workstation (Vitrea Bridge or TeraRecon)
8. Correct Order: CT Abdomen / Pelvis W/WO contrast

## Indications

With & Without Contrast: Nonspecific hematuria, Ureter injury

**\*\*Values will vary between machines. Use your own discretion when selecting these values.\*\***

Reviewed by Drs. King & Thornton 3/2021

\*Subject to change at the discretion of the radiologist due to clinical circumstances.\*



# CT Cystogram



Diagnostic & Preventative Imaging Center

**Anatomical Reference:** Iliac Crest  
**Patient Position:** Supine  
**Patient Orientation:** Feet First  
**Scan Range:** Iliac Crest through Ischial Tuberosities

**Scout:** AP, Lateral if necessary  
**Scan Type:** Helical  
**Rotation Time:** 0.8  
**Thickness:** 3 mm, Recon as thin as possible  
**Interval:** 3 mm, Recon as thin as possible  
**Gantry Tilt:** None  
**SFOV:** Large  
**kVp:** 120  
**mAs:** Auto mA (minimum 50-maximum 420)  
**Scan Delay:** None  
**Respiration:** Inspiration  
**DFOV:** Adjust to patient size  
**Recon Algorithm:** Standard

**Contrast:** Oral: None  
Retrograde: 30 mL Omnipaque 300 mg/mL or equivalent water soluble contrast diluted in 500 mL Saline  
Using sterile technique, connect the tubing to the patient's foley catheter and allow the bladder to fill retrograde. If the patient is oriented, have the pt tell you when they are getting uncomfortably full. If they are unable to tell you, run in about 300 mL.

**Comments:**

1. Series 1 - Without Contrast
2. Series 2 - Fill bladder and scan
3. Have onsite radiologist check images to determine if additional imaging is needed.
4. Send 3 mm Axial Images (All series) to PACS
5. Send 2 mm Sagittal and Coronal Reconstructions (All series) to PACS  
*\*If performed for trauma, include soft tissue and bone algorithm recons on without series. If not for trauma, only include soft tissue algorithm recons on w/o series.*
6. Send thin images (All series) to 3D Workstation (Vitrea Bridge or TeraRecon)

## Indications

With & Without Contrast: Trauma, Post Op Bladder/Pelvic Surgery

**\*\*Values will vary between machines. Use your own discretion when selecting these values.\*\***

Reviewed by Dr. King 1/2025

\*Subject to change at the discretion of the radiologist due to clinical circumstances.\*



# CT Enterography

Routine



Diagnostic & Preventative Imaging Center

**Anatomical Reference:** Xyphoid  
**Patient Position:** Supine  
**Patient Orientation:** Feet First  
**Scan Range:** Dome of Diaphragm to Ischial Tuberosities

**Scout:** AP, Lateral if necessary  
**Scan Type:** Helical  
**Rotation Time:** 0.8  
**Thickness:** 3 mm, Recon as thin as possible  
**Interval:** 3 mm, Recon as thin as possible  
**Gantry Tilt:** None  
**SFOV:** Large  
**kVp:** 100  
**mAs:** Auto mA  
**Scan Delay:** 50-60 seconds  
**Respiration:** Inspiration  
**DFOV:** Adjust to patient size  
**Recon Algorithm:** Standard

**Contrast:**  
Oral: 1350 mL's Volumen @ 60, 45 and 30 minutes prior to scanning.  
Full cup of water immediately before scanning.  
IV: 120 mL Omnipaque 300 mg/mL or equivalent water soluble contrast  
injected at 4 mL/sec

**Comments:**  
1. Radiologist to approve prior to scheduling (if ordered for Crohn's, then proceed)  
2. KUB before patient starts drinking contrast.  
3. Send 3 mm Axial Images to PACS  
4. Send 2 mm Sagittal and Coronal Reconstructions to PACS  
5. Send thin images to 3D Workstation (Vitrea Bridge or TeraRecon)

## Indications

With Contrast: Crohn's Disease, Stricture, Nonspecific GI Indications, specifically small bowel

### GI BLEED WORKUP - USE MULTIPHASE PROTOCOL

**\*\*Values will vary between machines. Use your own discretion when selecting these values.\*\***

Reviewed by Dr. King 1/2025

\*Subject to change at the discretion of the radiologist due to clinical circumstances.\*



# CT Enterography

Multiphase



Diagnostic & Preventative Imaging Center

<b>Anatomical Reference:</b>	Xyphoid
<b>Patient Position:</b>	Supine
<b>Patient Orientation:</b>	Feet First
<b>Scan Range:</b>	Dome of Diaphragm to Ischial Tuberosities
<b>Scout:</b>	AP, Lateral if necessary
<b>Scan Type:</b>	Helical
<b>Rotation Time:</b>	0.8
<b>Thickness:</b>	3 mm, Recon as thin as possible
<b>Interval:</b>	3 mm, Recon as thin as possible
<b>Gantry Tilt:</b>	None
<b>SFOV:</b>	Large
<b>kVp:</b>	100
<b>mAs:</b>	Auto mA
<b>Scan Delay:</b>	Arterial: As Below; Enteric: 20-25 secs; Delayed: 70-75 secs
<b>Respiration:</b>	Inspiration
<b>DFOV:</b>	Adjust to patient size
<b>Recon Algorithm:</b>	Standard
<b>Contrast:</b>	Oral: 1350 mL's Volumen @ 60, 45 and 30 minutes prior to scanning. Full cup of water immediately before scanning. IV: 120 mL Omnipaque 300 mg/mL or equivalent water soluble contrast injected at 4 mL/sec
<b>Comments:</b>	1. Radiologist to approve prior to scheduling (if ordered for occult GI bleeding, then proceed). 2. KUB before patient starts drinking contrast. 3. Series 1 - Without contrast 4. Series 2 - Arterial Phase - Bolus triggered w/ ROI on mid aorta. Trigger with 200 HU. 5. Series 3 - Enteric Phase - 20-25 secs after arterial phase 6. Series 4 - Delayed Phase - 70-75 secs after arterial phase 7. Send 3 mm Axial Images (Series 1-4) to PACS 8. Send 2 mm Sagittal and Coronal Reconstructions (Series 1-4) to PACS 9. Send thin images (Series 1-4) to 3D Workstation (Vitrea Bridge or TeraRecon)

## Indications

With Contrast: Occult GI Bleed Workup; For Acute GI Bleed-See CTA Protocol

**\*\*Values will vary between machines. Use your own discretion when selecting these values.\*\***

Reviewed by Dr. King 1/2025

\*Subject to change at the discretion of the radiologist due to clinical circumstances.\*



# CT Virtual Colonoscopy



Diagnostic & Preventative Imaging Center

<b>Anatomical Reference:</b>	Xyphoid
<b>Patient Position:</b>	Series 1 - Supine Series 2 - Prone
<b>Patient Orientation:</b>	Feet First
<b>Scan Range:</b>	Dome of Diaphragm to Pubic Symphysis
<b>Scout:</b>	AP, PA, Lateral if necessary
<b>Scan Type:</b>	Helical
<b>Rotation Time:</b>	0.8
<b>Thickness:</b>	1.25 mm
<b>Interval:</b>	1.25 mm
<b>Gantry Tilt:</b>	None
<b>SFOV:</b>	Large
<b>kVp:</b>	120
<b>mAs:</b>	Auto mA
<b>Scan Delay:</b>	None
<b>Respiration:</b>	Inspiration
<b>DFOV:</b>	Adjust to patient size
<b>Recon Algorithm:</b>	Standard
<b>Contrast:</b>	Distend colon with CO2
<b>Comments:</b>	<ol style="list-style-type: none"><li>1. Make sure patient has done the bowel prep.</li><li>2. Do not scan until colon is completely distended.</li><li>3. Series 1 - Patient is supine.</li><li>4. Series 2 - Patient is prone.</li><li>5. Send 2 mm Sagittal and Coronal Reconstructions (on Series 1 OR 2, whichever has best coverage) to PACS</li><li>6. Send all images to McKesson PACS.</li></ol>

## Indications

Without Contrast: Screening

**\*\*Values will vary between machines. Use your own discretion when selecting these values.\*\***

Reviewed by Dr. Keller 2/2018 / Dr. King 2/2018

\*Subject to change at the discretion of the radiologist due to clinical circumstances.\*



# CT Pelvis



Diagnostic & Preventative Imaging Center

**Anatomical Reference:** Iliac Crest  
**Patient Position:** Supine  
**Patient Orientation:** Feet First  
**Scan Range:** Iliac Crest thru Ischial Tuberosities

**Scout:** AP, Lateral if necessary  
**Scan Type:** Helical  
**Rotation Time:** 0.8  
**Thickness:** 3 mm, Recon as thin as possible  
**Interval:** 3 mm, Recon as thin as possible  
**Gantry Tilt:** None  
**SFOV:** Large  
**kVp:** 120  
**mAs:** Auto mA  
**Scan Delay:** 75 seconds  
**Respiration:** Inspiration  
**DFOV:** Adjust to patient size  
**Recon Algorithm:** Standard

**Contrast:**

Oral: **See notes below** - 1000 mL diluted contrast 1-2 hours prior to CT OR 1000 mL Ready to Drink (RTD) Omnipaque Oral Solution 1-2 hours prior to CT

IV: 100 mL Omnipaque 300 mg/mL or equivalent water soluble contrast injected at 2-3 mL/sec

**Comments:**

1. No preliminary non-contrast scans necessary.
2. Send 3 mm Axial Images to PACS
3. Send 2 mm Sagittal and Coronal Reconstructions to PACS
4. Send thin slices to 3D Workstation (Vitrea Bridge or TeraRecon)
5. Do delayed bladder on all patients with:
  - a. Pelvic abscess
  - b. Recent pelvic surgery
  - c. Any bladder, prostate or gynecologic surgery

**Oral Contrast Notes:**

1. Oral contrast not needed for most exams.
2. Give oral contrast for:
  - a. Any history of pelvic radiation therapy
  - b. PARTIAL small bowel obstruction (SBO) (Complete or High grade SBO = NO oral contrast)

*Continued on next page*

Reviewed by Dr. King 1/2025



# CT Pelvis Cont.

## Oral Contrast Notes:

- c. Recently treated SBO (e.g. floor patients with an NG tube for a couple days)
- d. Abscess
- e. Symptoms of appendicitis for 3 days or more
- f. Low BMI (24 or less)
- g. Postop from any major bowel surgery including bariatrics
- h. Any Gynecologic Oncology patient of Dr. Elg
- i. Ovarian pathology / Tubo-ovarian abscess
- j. GI fistula
- k. Duplication cyst
- l. Follow up of gastrointestinal or mesenteric trauma

## Indications

Without Contrast: Pain, Follow Up

**\*\*Values will vary between machines. Use your own discretion when selecting these values.\*\***

Reviewed by Dr. King 1/2025

\*Subject to change at the discretion of the radiologist due to clinical circumstances.\*



# CT Bony Pelvis



Diagnostic & Preventative Imaging Center

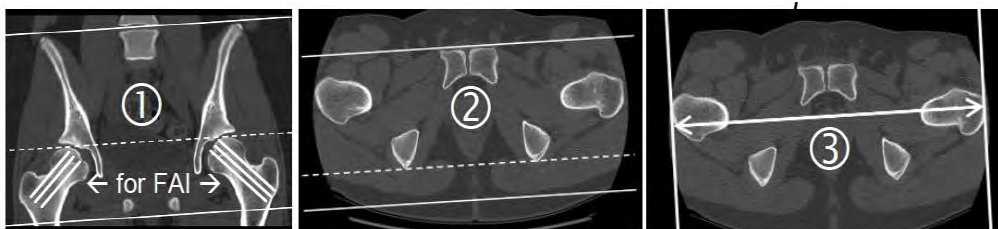
**Anatomical Reference:** Iliac Crest  
**Patient Position:** Supine  
**Patient Orientation:** Feet First  
**Scan Range:** 2 cm above Iliac Crest thru Proximal Femoral Shaft

**Scout:** AP, Lateral if necessary  
**Scan Type:** Helical  
**Rotation Time:** 0.8  
**Thickness:** 1.25 mm, Recon as thin as possible  
**Interval:** 0.6 mm, Recon as thin as possible  
**Gantry Tilt:** None  
**SFOV:** Large  
**kVp:** 120  
**mAs:** Auto mA  
**Scan Delay:** None  
**Respiration:** None  
**DFOV:** Adjust to patient size  
**Recon Algorithm:** Standard

**Contrast:** None

**Comments:**

1. Send 3 mm Soft Tissue Axial Images to PACS
2. Send 3 mm Bone Window Axial Images to PACS
3. Send 3 mm thick / 3 mm interval Bone Window Sagittal and Coronal Reconstructions to PACS
4. Send Soft Tissue Thin (0.6 mm) Slices to 3D Workstation (Vitrea Bridge or TeraRecon)



\* Images used with permission: Ken L. Schreibman PhD/MD (schreibman@alum.mit.edu)

## Indications

Without Contrast: Pain, Injury, Fracture

**\*\*Values will vary between machines. Use your own discretion when selecting these values.\*\***

Reviewed by Dr. Choi 1/2019

\*Subject to change at the discretion of the radiologist due to clinical circumstances.\*



# CT Hip/Pelvis



Diagnostic & Preventative Imaging Center

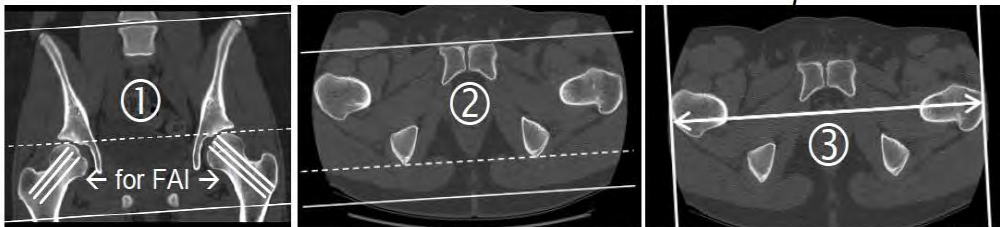
**Anatomical Reference:** Iliac Crest  
**Patient Position:** Supine  
**Patient Orientation:** Feet First  
**Scan Range:** 2 cm above Iliac Crest thru Proximal Femoral Shaft

**Scout:** AP, Lateral if necessary  
**Scan Type:** Helical  
**Rotation Time:** 0.8  
**Thickness:** 1.25 mm, Recon as thin as possible  
**Interval:** 0.6 mm, Recon as thin as possible  
**Gantry Tilt:** None  
**SFOV:** Large  
**kVp:** 120  
**mAs:** Auto mA  
**Scan Delay:** None  
**Respiration:** None  
**DFOV:** Adjust to patient size  
**Recon Algorithm:** Standard

**Contrast:** None

**Comments:**

1. Send 3 mm Soft Tissue Axial Images (Pelvis & Affected Hip) to PACS
2. Send 3 mm Bone Window Axial Images (Pelvis & Affected Hip) to PACS
3. Send 3 mm thick / 3 mm interval Bone Window Sagittal and Coronal Reconstructions to PACS
4. Send Soft Tissue Thin (0.6 mm) Slices to 3D Workstation (Vitrea Bridge or TeraRecon)



\* Images used with permission: Ken L. Schreibman PhD/MD (schreibman@alum.mit.edu)

## Indications

Without Contrast: Pain, Injury, Fracture

**\*\*Values will vary between machines. Use your own discretion when selecting these values.\*\***

Reviewed by Dr. Choi 1/2019

\*Subject to change at the discretion of the radiologist due to clinical circumstances.\*



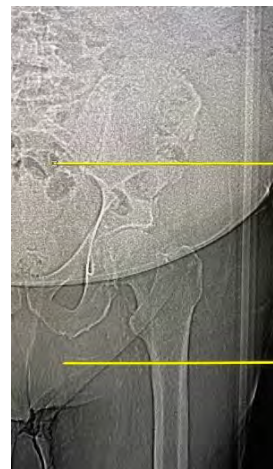# CT Hip Arthrogram



Diagnostic & Preventative Imaging Center

**Anatomical Reference:** Iliac Crest  
**Patient Position:** Supine  
**Patient Orientation:** Feet First  
**Scan Range:** Mid Iliac Crest to Subtrochanter (See picture)

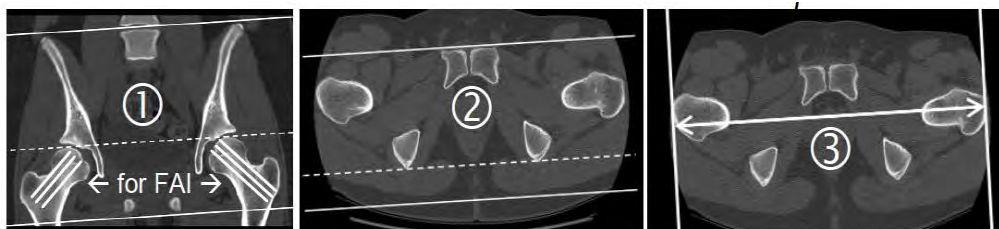
**Scout:** AP, Lateral if necessary  
**Scan Type:** Helical  
**Rotation Time:** 0.8  
**Thickness:** 1.25 mm, Recon as thin as possible  
**Interval:** 0.6 mm, Recon as thin as possible  
**Gantry Tilt:** None  
**SFOV:** Small  
**kVp:** 120  
**mAs:** Auto mA  
**Scan Delay:** None  
**Respiration:** None  
**DFOV:** Adjust to patient size  
**Recon Algorithm:** Standard



**Contrast:** None

**Comments:**

1. Send 3 mm Soft Tissue Axial Images (Pelvis & Affected Hip) to PACS
2. Send 3 mm Bone Window Axial Images (Pelvis & Affected Hip) to PACS
3. Send 3 mm thick / 3 mm interval Bone Window Sagittal and Coronal Reconstructions to PACS
4. Send Soft Tissue Thin (0.6 mm) Slices to 3D Workstation (Vitrea Bridge or TeraRecon)



\* Images used with permission: Ken L. Schreibman PhD/MD (schreibman@alum.mit.edu)

## Indications

With Contrast: Pain, Injury, Fracture

**\*\*Values will vary between machines. Use your own discretion when selecting these values.\*\***

Reviewed by Dr. Choi 6/2021

\*Subject to change at the discretion of the radiologist due to clinical circumstances.\*



# CT SI Joint / Tailbone



Diagnostic & Preventative Imaging Center

**Anatomical Reference:** Iliac Crest  
**Patient Position:** Supine  
**Patient Orientation:** Feet First  
**Scan Range:** 2 cm above Iliac Crest thru Coccyx

**Scout:** AP, Lateral if necessary  
**Scan Type:** Helical  
**Rotation Time:** 0.8  
**Thickness:** 1.25 mm, Recon as thin as possible  
**Interval:** 0.6 mm, Recon as thin as possible  
**Gantry Tilt:** None  
**SFOV:** Large  
**kVp:** 120  
**mAs:** Auto mA  
**Scan Delay:** None  
**Respiration:** None  
**DFOV:** Adjust to patient size  
**Recon Algorithm:** Standard

**Contrast:** None

**Comments:**

1. Send 3 mm Soft Tissue Axial Images to PACS
2. Send 3 mm Bone Window Axial Images to PACS
3. Send 3 mm thick / 3 mm interval Bone Window Sagittal and Coronal Reconstructions to PACS
4. Send Soft Tissue Thin (0.6 mm) Slices to 3D Workstation (Vitrea Bridge or TeraRecon)

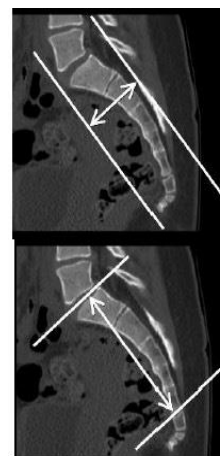
## \*\*SI Joint Reconstruction:

Align reconstruction plan from the mid sagittal sacral image

Oblique Coronal: Angle plane parallel to the long axis of the sacrum

Oblique Axial: Angle plane parallel to the OBLIQUE CORONAL reconstructed image

\* Images used with permission: Ken L. Schreibman PhD/MD (schreibman@alum.mit.edu)



## Indications

Without Contrast: Pain, Injury, Fracture

**\*\*Values will vary between machines. Use your own discretion when selecting these values.\*\***

Reviewed by Dr. Choi 1/2019

\*Subject to change at the discretion of the radiologist due to clinical circumstances.\*



# CT Knee



Diagnostic & Preventative Imaging Center

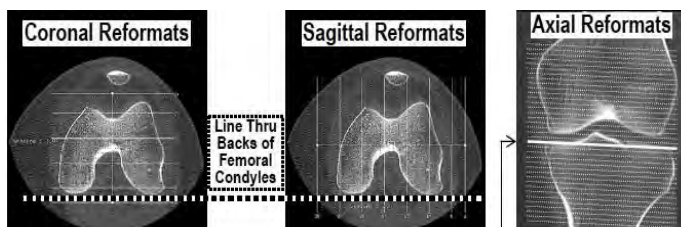
**Anatomical Reference:** Mid Knee  
**Patient Position:** Supine; TAPE FEET TOGETHER  
**Patient Orientation:** Feet First  
**Scan Range:** Entire Knee

**Scout:** AP, Lateral if necessary  
**Scan Type:** Helical  
**Rotation Time:** 0.8  
**Thickness:** 1.25 mm, Recon as thin as possible  
**Interval:** 0.6 mm, Recon as thin as possible  
**Gantry Tilt:** None  
**SFOV:** Large  
**kVp:** 120  
**mAs:** Auto mA  
**Scan Delay:** None  
**Respiration:** None  
**DFOV:** Adjust to Knee  
**Recon Algorithm:** Standard

**Contrast:** None

**Comments:**

1. Send 3 mm Soft Tissue Axial Images to PACS
2. Send 3 mm Bone Window Axial Images to PACS
3. Send 3 mm thick / 3 mm interval Bone Window Sagittal and Coronal Reconstructions to PACS
4. Send Soft Tissue Thin (0.6 mm) Slices to 3D Workstation (Vitrea Bridge or TeraRecon)



\* Images used with permission: Ken L. Schreibman PhD/MD (schreibman@alum.mit.edu)

## Indications

Without Contrast: Pain, Injury, Fracture

**\*\*Values will vary between machines. Use your own discretion when selecting these values.\*\***

Reviewed by Dr. Choi 4/2016

\*Subject to change at the discretion of the radiologist due to clinical circumstances.\*



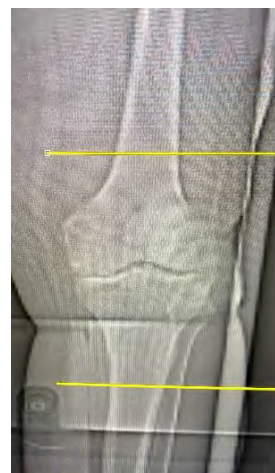# CT Knee Arthrogram



Diagnostic & Preventative Imaging Center

**Anatomical Reference:** Mid Knee  
**Patient Position:** Supine; TAPE FEET TOGETHER  
**Patient Orientation:** Feet First  
**Scan Range:** Entire Knee (See picture)

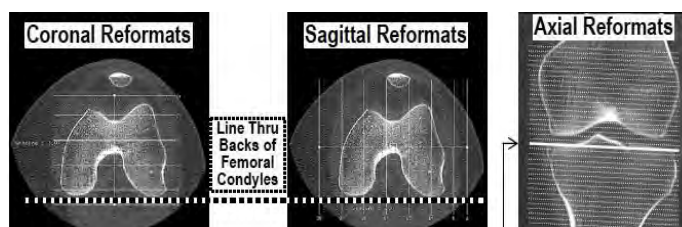
**Scout:** AP, Lateral if necessary  
**Scan Type:** Helical  
**Rotation Time:** 0.8  
**Thickness:** 1.25 mm, Recon as thin as possible  
**Interval:** 0.6 mm, Recon as thin as possible  
**Gantry Tilt:** None  
**SFOV:** Large  
**kVp:** 120  
**mAs:** Auto mA  
**Scan Delay:** None  
**Respiration:** None  
**DFOV:** Adjust to Knee  
**Recon Algorithm:** Standard



**Contrast:** None

**Comments:**

1. Send 3 mm Soft Tissue Axial Images to PACS
2. Send 3 mm Bone Window Axial Images to PACS
3. Send 3 mm thick / 3 mm interval Bone Window Sagittal and Coronal Reconstructions to PACS
4. Send Soft Tissue Thin (0.6 mm) Slices to 3D Workstation (Vitrea Bridge or TeraRecon)



\* Images used with permission: Ken L. Schreibman PhD/MD (schreibman@alum.mit.edu)

## Indications

With Contrast: Pain, Injury, Fracture

**\*\*Values will vary between machines. Use your own discretion when selecting these values.\*\***

Reviewed by Dr. Choi 6/2021

\*Subject to change at the discretion of the radiologist due to clinical circumstances.\*



# CT Ankle



Diagnostic & Preventative Imaging Center


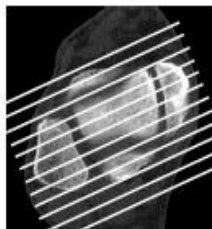
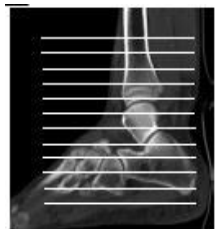
**Anatomical Reference:** Mid Ankle  
**Patient Position:** Supine; TAPE FEET TOGETHER (if possible)  
**Patient Orientation:** Feet First  
**Scan Range:** Entire Ankle

**Scout:** AP, Lateral if necessary  
**Scan Type:** Helical  
**Rotation Time:** 0.8  
**Thickness:** 1.25 mm, Recon as thin as possible  
**Interval:** 0.6 mm, Recon as thin as possible  
**Gantry Tilt:** None  
**SFOV:** Small  
**kVp:** 120  
**mAs:** Auto mA  
**Scan Delay:** None  
**Respiration:** None  
**DFOV:** Adjust to Ankle  
**Recon Algorithm:** Standard

**Contrast:** None

**Comments:**

1. Send 3 mm Soft Tissue Window Axial Images to PACS
2. Send 3 mm Bone Window Axial Images to PACS
3. Send 3 mm thick / 3 mm interval Bone Window Sagittal and Coronal Reconstructions to PACS
4. Send Soft Tissue Thin (0.6 mm) Slices to 3D Workstation (Vitrea Bridge or TeraRecon)



\* Images used with permission: Ken L. Schreibman PhD/MD (schreibman@alum.mit.edu)

## Indications

Without Contrast: Pain, Injury, Fracture

**\*\*Values will vary between machines. Use your own discretion when selecting these values.\*\***

Reviewed by Dr. Choi 4/2016

\*Subject to change at the discretion of the radiologist due to clinical circumstances.\*



# CT Subtalar



Diagnostic & Preventative Imaging Center

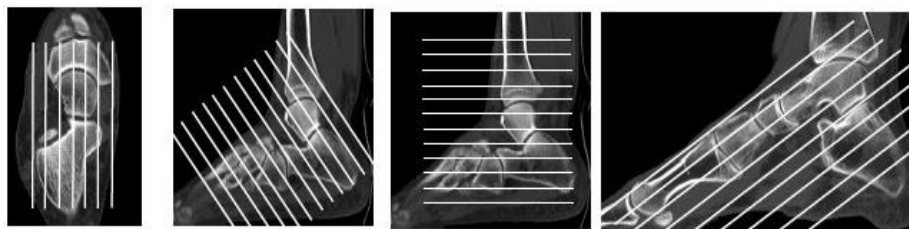
**Anatomical Reference:** Mid Foot  
**Patient Position:** Supine; TAPE FEET TOGETHER (if possible)  
**Patient Orientation:** Feet First  
**Scan Range:** Entire Ankle

**Scout:** AP, Lateral if necessary  
**Scan Type:** Helical  
**Rotation Time:** 0.8  
**Thickness:** 1.25 mm, Recon as thin as possible  
**Interval:** 0.6 mm, Recon as thin as possible  
**Gantry Tilt:** None  
**SFOV:** Small  
**kVp:** 120  
**mAs:** Auto mA  
**Scan Delay:** None  
**Respiration:** None  
**DFOV:** Adjust to Foot  
**Recon Algorithm:** Standard

**Contrast:** None

**Comments:**

1. Send 3 mm Soft Tissue Axial Images to PACS
2. Send 3 mm Bone Window Axial Images to PACS
3. Send 2 mm thick / 2 mm interval Bone Window Sagittal and Coronal Reconstructions to PACS
4. Send Soft Tissue Thin (0.6 mm) Slices to 3D Workstation (Vitrea Bridge or TeraRecon)



\* Images used with permission: Ken L. Schreibman PhD/MD (schreibman@alum.mit.edu)

## Indications

Without Contrast: Pain, Injury, Fracture

**\*\*Values will vary between machines. Use your own discretion when selecting these values.\*\***

Reviewed by Dr. Choi 4/2016

\*Subject to change at the discretion of the radiologist due to clinical circumstances.\*



# CT Lisfranc



Diagnostic & Preventative Imaging Center

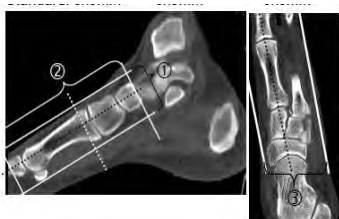
**Anatomical Reference:** Mid Ankle  
**Patient Position:** Supine; TAPE FEET TOGETHER (if possible)  
**Patient Orientation:** Feet First  
**Scan Range:** Entire Ankle

**Scout:** AP, Lateral if necessary  
**Scan Type:** Helical  
**Rotation Time:** 0.8  
**Thickness:** 1.25 mm, Recon as thin as possible  
**Interval:** 0.6 mm, Recon as thin as possible  
**Gantry Tilt:** None  
**SFOV:** Small  
**kVp:** 120  
**mAs:** Auto mA  
**Scan Delay:** None  
**Respiration:** None  
**DFOV:** Adjust to Foot  
**Recon Algorithm:** Standard

**Contrast:** None

**Comments:**

1. Send 3 mm Soft Tissue Axial Images to PACS
2. Send 3 mm Bone Window Axial Images to PACS
3. Send 2 mm thick / 2 mm interval Bone Window Sagittal and Coronal Reconstructions to PACS
4. Send Soft Tissue Thin (0.6 mm) Slices to 3D Workstation (Vitrea Bridge or TeraRecon)



**\*\*Align reconstruction on the 1st TMT Joint.**

\* Images used with permission: Ken L. Schreibman PhD/MD (schreibman@alum.mit.edu)

## Indications

Without Contrast: Pain, Injury, Fracture

**\*\*Values will vary between machines. Use your own discretion when selecting these values.\*\***

Reviewed by Dr. Choi 4/2016

\*Subject to change at the discretion of the radiologist due to clinical circumstances.\*



# CT Foot



Diagnostic & Preventative Imaging Center

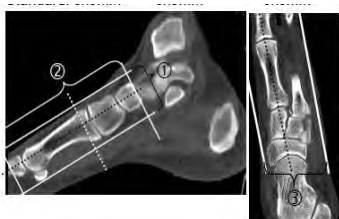
**Anatomical Reference:** Mid Foot  
**Patient Position:** Supine; TAPE FEET TOGETHER (if possible)  
**Patient Orientation:** Feet First  
**Scan Range:** Entire Foot

**Scout:** AP, Lateral if necessary  
**Scan Type:** Helical  
**Rotation Time:** 0.8  
**Thickness:** 1.25 mm, Recon as thin as possible  
**Interval:** 0.6 mm, Recon as thin as possible  
**Gantry Tilt:** None  
**SFOV:** Small  
**kVp:** 120  
**mAs:** Auto mA  
**Scan Delay:** None  
**Respiration:** None  
**DFOV:** Adjust to Foot  
**Recon Algorithm:** Standard

**Contrast:** None

**Comments:**

1. Send 3 mm Soft Tissue Axial Images to PACS
2. Send 3 mm Bone Window Axial Images to PACS
3. Send 2 mm thick / 2 mm interval Bone Window Sagittal and Coronal Reconstructions to PACS
4. Send Soft Tissue Thin (0.6 mm) Slices to 3D Workstation (Vitrea Bridge or TeraRecon)



**\*\*Align reconstruction on the metatarsals (MTP joint).**

\* Images used with permission: Ken L. Schreibman PhD/MD (schreibman@alum.mit.edu)

## Indications

Without Contrast: Pain, Injury, Fracture

**\*\*Values will vary between machines. Use your own discretion when selecting these values.\*\***

Reviewed by Dr. Choi 4/2016

\*Subject to change at the discretion of the radiologist due to clinical circumstances.\*



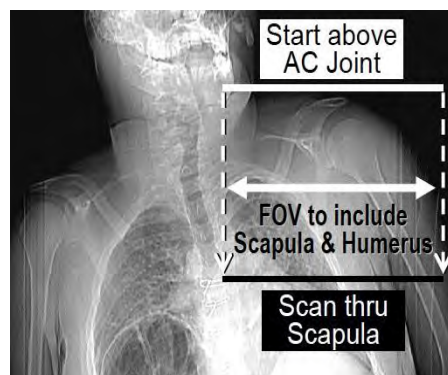
# CT Shoulder



Diagnostic & Preventative Imaging Center

**Anatomical Reference:** Sternal Notch  
**Patient Position:** Supine (off center pt so affected shoulder is completely on table)  
**Patient Orientation:** Head First  
**Scan Range:** Entire Shoulder

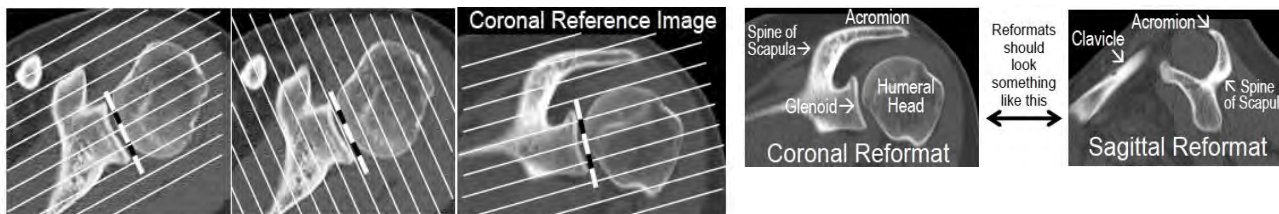
**Scout:** AP, Lateral if necessary  
**Scan Type:** Helical  
**Rotation Time:** 0.8  
**Thickness:** 1.25 mm, Recon as thin as possible  
**Interval:** 0.6 mm, Recon as thin as possible  
**Gantry Tilt:** None  
**SFOV:** Large  
**kVp:** 120  
**mAs:** Auto mA  
**Scan Delay:** None  
**Respiration:** Inspiration  
**DFOV:** Adjust to Shoulder  
**Recon Algorithm:** Standard



**Contrast:** None

**Comments:**

1. Send 3 mm Soft Tissue Axial Images to PACS
2. Send 3 mm Bone Window Axial Images to PACS
3. Send 3 mm thick / 3 mm interval Bone Window Sagittal and Coronal Reconstructions to PACS
4. Send Soft Tissue Thin (0.6 mm) Slices to 3D Workstation (Vitrea Bridge or TeraRecon)



\* Images used with permission: Ken L. Schreibman PhD/MD (schreibman@alum.mit.edu)

## Indications

Without Contrast: Pain, Injury, F/U Fracture, Post Arthrogram

**\*\*Values will vary between machines. Use your own discretion when selecting these values.\*\***

Reviewed by Dr. Choi 4/2016

\*Subject to change at the discretion of the radiologist due to clinical circumstances.\*



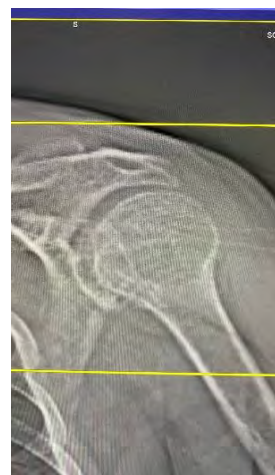# CT Shoulder Arthrogram



Diagnostic & Preventative Imaging Center

**Anatomical Reference:** Sternal Notch  
**Patient Position:** Supine (off center pt so affected shoulder is completely on table)  
**Patient Orientation:** Head First  
**Scan Range:** Proximal 1/3 Shaft (See picture)

**Scout:** AP, Lateral if necessary  
**Scan Type:** Helical  
**Rotation Time:** 0.8  
**Thickness:** 1.25 mm, Recon as thin as possible  
**Interval:** 0.6 mm, Recon as thin as possible  
**Gantry Tilt:** None  
**SFOV:** Large  
**kVp:** 120  
**mAs:** Auto mA  
**Scan Delay:** None  
**Respiration:** Inspiration  
**DFOV:** Adjust to Shoulder  
**Recon Algorithm:** Standard



**Contrast:** None

**Comments:**

1. Series 1 - Scan as a Routine CT Shoulder
2. Series 2 - ABER (Abduction External Rotation), if tolerated - Affected arm up with the patient's hand resting behind their head - Scan through shoulder
3. Send 3 mm Soft Tissue Axial Images (Series 1-2) to PACS
4. Send 3 mm Bone Window Axial Images (Series 1-2) to PACS
5. Send 3 mm thick / 3 mm interval Bone Window Sagittal and Coronal Reconstructions (Series 1-2) to PACS
4. Send Soft Tissue Thin (0.6 mm) Slices (Series 1-2) to 3D Workstation (Vitrea Bridge or TeraRecon)

## Indications

With Contrast: Pain, Injury, F/U Fracture, Post Arthrogram

**\*\*Values will vary between machines. Use your own discretion when selecting these values.\*\***

Reviewed by Dr. Choi 6/2021

\*Subject to change at the discretion of the radiologist due to clinical circumstances.\*



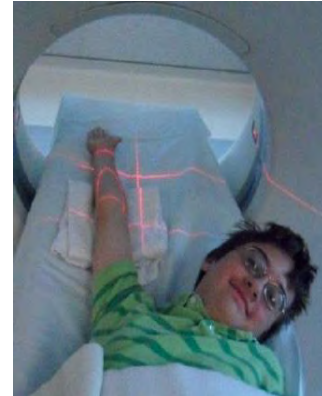
# CT Elbow



Diagnostic & Preventative Imaging Center

**Anatomical Reference:** Mid Elbow  
**Patient Position:** Supine; Arm extended above head  
**Patient Orientation:** Head First  
**Scan Range:** Entire Elbow

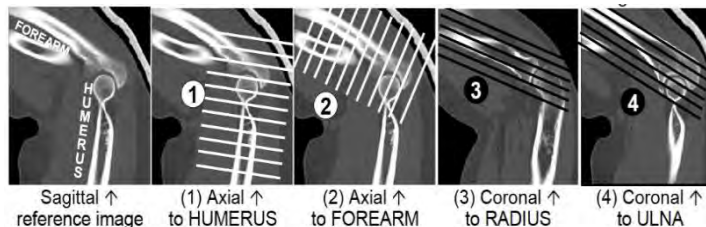
**Scout:** AP, Lateral if necessary  
**Scan Type:** Helical  
**Rotation Time:** 0.8  
**Thickness:** 1.25 mm, Recon as thin as possible  
**Interval:** 0.6 mm, Recon as thin as possible  
**Gantry Tilt:** None  
**SFOV:** Small  
**kVp:** 120  
**mAs:** Auto mA  
**Scan Delay:** None  
**Respiration:** None  
**DFOV:** Adjust to Elbow  
**Recon Algorithm:** Standard



**Contrast:** None

**Comments:**

1. Send 3 mm Soft Tissue Axial Images to PACS
2. Send 3 mm Bone Window Axial Images to PACS
3. Send 3 mm thick / 3 mm interval Bone Window Sagittal and Coronal Reconstructions to PACS
4. Send Soft Tissue Thin (0.6 mm) Slices to 3D Workstation (Vitrea Bridge or TeraRecon)



\* Images used with permission: Ken L. Schreibman PhD/MD (schreibman@alum.mit.edu)

## Indications

Without Contrast: Pain, Injury, Fracture

**\*\*Values will vary between machines. Use your own discretion when selecting these values.\*\***

Reviewed by Dr. Choi 4/2016

\*Subject to change at the discretion of the radiologist due to clinical circumstances.\*



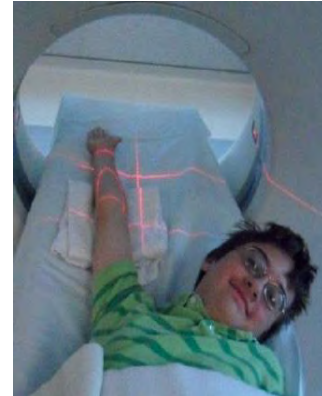
# CT Elbow Arthrogram



Diagnostic & Preventative Imaging Center

**Anatomical Reference:** Mid Elbow  
**Patient Position:** Supine; Arm extended above head  
**Patient Orientation:** Head First  
**Scan Range:** Entire Elbow

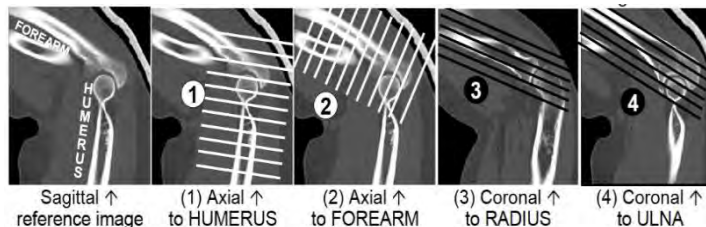
**Scout:** AP, Lateral if necessary  
**Scan Type:** Helical  
**Rotation Time:** 0.8  
**Thickness:** 1.25 mm, Recon as thin as possible  
**Interval:** 0.6 mm, Recon as thin as possible  
**Gantry Tilt:** None  
**SFOV:** Small  
**kVp:** 120  
**mAs:** Auto mA  
**Scan Delay:** None  
**Respiration:** None  
**DFOV:** Adjust to Elbow  
**Recon Algorithm:** Standard



**Contrast:** None

**Comments:**

1. Send 3 mm Soft Tissue Axial Images to PACS
2. Send 3 mm Bone Window Axial Images to PACS
3. Send 3 mm thick / 3 mm interval Bone Window Sagittal and Coronal Reconstructions to PACS
4. Send Soft Tissue Thin (0.6 mm) Slices to 3D Workstation (Vitrea Bridge or TeraRecon)



\* Images used with permission: Ken L. Schreibman PhD/MD (schreibman@alum.mit.edu)

## Indications

With Contrast: Pain, Injury, Fracture

**\*\*Values will vary between machines. Use your own discretion when selecting these values.\*\***

Reviewed by Dr. Choi 6/2017

\*Subject to change at the discretion of the radiologist due to clinical circumstances.\*



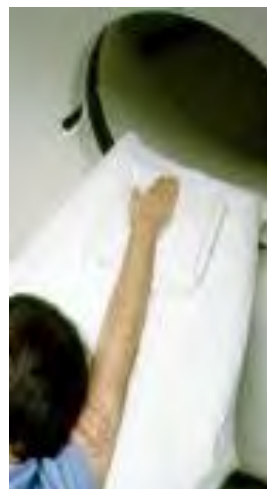# CT Wrist



Diagnostic & Preventative Imaging Center

**Anatomical Reference:** Mid Wrist  
**Patient Position:** Prone, Arm Extended  
**Patient Orientation:** Head First  
**Scan Range:** Entire Wrist

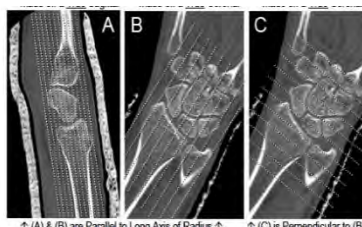
**Scout:** AP, Lateral if necessary  
**Scan Type:** Helical  
**Rotation Time:** 0.8  
**Thickness:** 1.25 mm, Recon as thin as possible  
**Interval:** 0.6 mm, Recon as thin as possible  
**Gantry Tilt:** None  
**SFOV:** Small  
**kVp:** 120  
**mAs:** Auto mA  
**Scan Delay:** None  
**Respiration:** None  
**DFOV:** Adjust to Wrist  
**Recon Algorithm:** Standard



**Contrast:** None

**Comments:**

1. Send 2 mm Soft Tissue Axial Images to PACS
2. Send 2 mm Bone Window Axial Images to PACS
3. Send 2 mm thick / 2 mm interval Bone Window Sagittal and Coronal Reconstructions to PACS
4. Send Soft Tissue Thin (0.6 mm) Slices to 3D Workstation (Vitrea Bridge or TeraRecon)



\* Images used with permission: Ken L. Schreibman PhD/MD (schreibman@alum.mit.edu)

## Indications

Without Contrast: Pain, Injury, Fracture

**\*\*Values will vary between machines. Use your own discretion when selecting these values.\*\***

Reviewed by Dr. Choi 4/2016

\*Subject to change at the discretion of the radiologist due to clinical circumstances.\*



# CT Scaphoid / Wrist



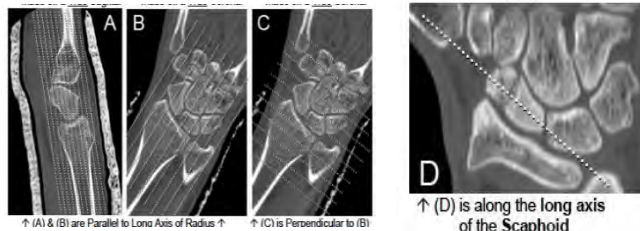
Diagnostic & Preventative Imaging Center

<b>Anatomical Reference:</b>	Mid Wrist
<b>Patient Position:</b>	Prone, Arm Extended
<b>Patient Orientation:</b>	Head First
<b>Scan Range:</b>	Entire Wrist
<b>Scout:</b>	AP, Lateral if necessary
<b>Scan Type:</b>	Helical
<b>Rotation Time:</b>	0.8
<b>Thickness:</b>	1.25 mm, Recon as thin as possible
<b>Interval:</b>	0.6 mm, Recon as thin as possible
<b>Gantry Tilt:</b>	None
<b>SFOV:</b>	Small
<b>kVp:</b>	120
<b>mAs:</b>	Auto mA
<b>Scan Delay:</b>	None
<b>Respiration:</b>	None
<b>DFOV:</b>	Adjust to Wrist
<b>Recon Algorithm:</b>	Standard

**Contrast:** None

**Comments:**

1. Send 2 mm Soft Tissue Axial Images to PACS
2. Send 2 mm Bone Window Axial Images to PACS
3. Send 2 mm thick / 2 mm interval Bone Window Sagittal and Coronal Reconstructions to PACS
4. Send Soft Tissue Thin (0.6 mm) Slices to 3D Workstation (Vitrea Bridge or TeraRecon)



\* Images used with permission: Ken L. Schreibman PhD/MD (schreibman@alum.mit.edu)

## Indications

Without Contrast: Pain, Injury, Fracture

**\*\*Values will vary between machines. Use your own discretion when selecting these values.\*\***

Reviewed by Dr. Choi 4/2016

\*Subject to change at the discretion of the radiologist due to clinical circumstances.\*



# CT Hand



Diagnostic & Preventative Imaging Center

<b>Anatomical Reference:</b>	Mid Hand
<b>Patient Position:</b>	Prone, Arm Extended
<b>Patient Orientation:</b>	Head First
<b>Scan Range:</b>	Entire Hand
<b>Scout:</b>	AP, Lateral if necessary
<b>Scan Type:</b>	Helical
<b>Rotation Time:</b>	0.8
<b>Thickness:</b>	1.25 mm, Recon as thin as possible
<b>Interval:</b>	0.6 mm, Recon as thin as possible
<b>Gantry Tilt:</b>	None
<b>SFOV:</b>	Small
<b>kVp:</b>	120
<b>mAs:</b>	Auto mA
<b>Scan Delay:</b>	None
<b>Respiration:</b>	None
<b>DFOV:</b>	Adjust to Hand
<b>Recon Algorithm:</b>	Standard



**Contrast:** None

**Comments:**

1. Send 2 mm Soft Tissue Axial Images to PACS
2. Send 2 mm Bone Window Axial Images to PACS
3. Send 2 mm thick / 2 mm interval Bone Window Sagittal and Coronal Reconstructions to PACS
4. Send Soft Tissue Thin (0.6 mm) Slices to 3D Workstation (Vitrea Bridge or TeraRecon)

\* Images used with permission: Ken L. Schreibman PhD/MD (schreibman@alum.mit.edu)

## Indications

Without Contrast: Pain, Injury, Fracture

**\*\*Values will vary between machines. Use your own discretion when selecting these values.\*\***

Reviewed by Dr. Choi 4/2016

\*Subject to change at the discretion of the radiologist due to clinical circumstances.\*



# CTA Head & Neck



Diagnostic & Preventative Imaging Center

**Anatomical Reference:** Mid Neck  
**Patient Position:** Supine  
**Patient Orientation:** Head First  
**Scan Range:** Inferior Border of Aortic Arch through Vertex

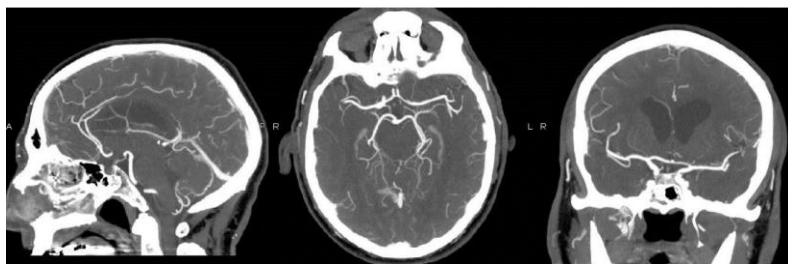**Scout:** AP and Lateral  
**Scan Type:** Helical  
**Rotation Time:** 0.6  
**Thickness:** 3 mm, Recon as thin as possible  
**Interval:** 3 mm, Recon as thin as possible  
**Gantry Tilt:** None  
**SFOV:** Large  
**kVp:** 120  
**mAs:** Auto mA  
**Scan Delay:** Smart Prep (ROI-Aorta)  
**Respiration:** None  
**DFOV:** Adjust to include all of head  
**Recon Algorithm:** Standard

**Contrast:** 80 mL Omnipaque 350 mg/mL or equivalent water soluble contrast @ 3 mL/sec

**Comments:**

1. Send thin Soft Tissue Axial images to PACS
2. Send Axial, Coronal and Sagittal Head MIP reformats to PACS, see below
3. Send Coronal and Sagittal Neck MIP reformats to PACS, see below
4. Send thin slices to 3D Workstation (Vitrea Bridge or TeraRecon)
- 5. If only a CTA Head or CTA Neck is ordered, contact a radiologist**

**MIPs:** Head - 10 mm slice thickness; 2.5 mm slice overlap; Window width = 600; Window level = 200  
Neck - 10 mm slice thickness; 5 mm slice overlap; Window width = 600; Window level = 200

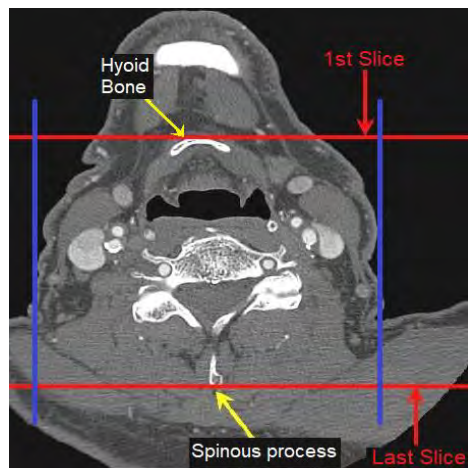


\* Image courtesy of University of Wisconsin

## Indications

With Contrast: Headache, Vertigo, Syncope, Aneurysm, Stenosis, Stroke, TIA

**\*\*Values will vary between machines. Use your own discretion when selecting these values.\*\***



Reviewed by Dr. Holdsworth 1/2025

\*Subject to change at the discretion of the radiologist due to clinical circumstances.\*



# CTA Chest

## PE Protocol



Diagnostic & Preventative Imaging Center

<b>Anatomical Reference:</b>	Sternal Notch
<b>Patient Position:</b>	Supine
<b>Patient Orientation:</b>	Feet First
<b>Scan Range:</b>	Apices through Lung Bases
<b>Scout:</b>	AP, Lateral if necessary
<b>Scan Type:</b>	Helical
<b>Rotation Time:</b>	0.5
<b>Thickness:</b>	3mm, Recon as thin as possible
<b>Interval:</b>	3mm, Recon as thin as possible
<b>Gantry Tilt:</b>	None
<b>SFOV:</b>	Large
<b>kVp:</b>	100, adjust accordingly for very large patients
<b>mAs:</b>	Auto mA (minimum 50-maximum 420)
<b>Scan Delay:</b>	Smart Prep (ROI-Pulmonary Artery, Scan Threshold-120 HU)
<b>Respiration:</b>	Inspiration
<b>DFOV:</b>	Adjust to patient size
<b>Recon Algorithm:</b>	Standard
<b>Contrast:</b>	Oral: None IV: 100 mL Omnipaque 350 or Isovue 370 mg/mL injected at 5 mL/sec *May need to adjust scan parameters to use all 100 mL IV contrast
<b>Comments:</b>	1. Start IV in right arm, if possible. 2. Send 3 mm Axial Images to PACS 3. Send 2 mm Sagittal and Coronal Reconstructions to PACS 4. Send 3D Reformatted Images to PACS 5. Send thin slices to PACS 6. Send thin slices to 3D Workstation (Vitrea Bridge or TeraRecon)

## Indications

With Contrast: Evaluate for Pulmonary Emboli, Positive DVT, Acute SOB

**\*\*Values will vary between machines. Use your own discretion when selecting these values.\*\***

Reviewed by Dr. Wolford 4/2025

\*Subject to change at the discretion of the radiologist due to clinical circumstances.\*



# CTA Chest



Diagnostic & Preventative Imaging Center

<b>Anatomical Reference:</b>	Sternal Notch
<b>Patient Position:</b>	Supine
<b>Patient Orientation:</b>	Feet First
<b>Scan Range:</b>	Aortic Arch through Diaphragm
<b>Scout:</b>	AP, Lateral if necessary
<b>Scan Type:</b>	Helical
<b>Thickness:</b>	3 mm, Recon as thin as possible
<b>Interval:</b>	3 mm, Recon as thin as possible
<b>Gantry Tilt:</b>	None
<b>SFOV:</b>	Large
<b>kVp:</b>	120
<b>mAs:</b>	Auto mA (minimum 50-maximum 420)
<b>Scan Delay:</b>	Smart Prep (ROI-descending aorta just below aortic arch)
<b>Respiration:</b>	Inspiration
<b>DFOV:</b>	Adjust to patient size
<b>Recon Algorithm:</b>	Standard
<b>Contrast:</b>	Oral: None IV: 130 mL Omnipaque 350 or Isovue 370 mg/mL injected at 5 mL/sec
<b>Comments:</b>	<ol style="list-style-type: none"><li>1. Series 1 - Without Contrast</li><li>2. Series 2 - Arterial Phase</li><li>3. If scanning for aneurysm or dissection, need to scan through iliacs.</li><li>4. Send 3 mm Axial Images to PACS</li><li>5. Send 2 mm Sagittal and Coronal Reconstructions to PACS</li><li>6. Send 3D Reformatted Images to PACS</li><li>7. Send thin slices to PACS</li><li>8. Send thin slices to 3D Workstation (Vitrea Bridge or TeraRecon)</li></ol>

**Use gating for CTA Chest, if available.**

## Indications

With & Without Contrast: Aneurysm, Dissection, Coarctation

**\*\*Values will vary between machines. Use your own discretion when selecting these values.\*\***

Reviewed by Dr. Keller 6/2021

\*Subject to change at the discretion of the radiologist due to clinical circumstances.\*



# CTA

## Chest/Abd/Pelvis



<b>Anatomical Reference:</b>	Xyphoid
<b>Patient Position:</b>	Supine
<b>Patient Orientation:</b>	Feet First
<b>Scan Range:</b>	Thoracic Inlet to Ischial Tuberosities
<b>Scout:</b>	AP, Lateral if necessary
<b>Scan Type:</b>	Helical
<b>Thickness:</b>	3 mm, Recon as thin as possible
<b>Interval:</b>	3 mm, Recon as thin as possible
<b>Gantry Tilt:</b>	None
<b>SFOV:</b>	Large
<b>kVp:</b>	120
<b>mAs:</b>	Auto mA (minimum 50-maximum 420)
<b>Scan Delay:</b>	Smart Prep (ROI-Descending Aorta just below Arch)
<b>Respiration:</b>	Inspiration
<b>DFOV:</b>	Adjust to patient size
<b>Recon Algorithm:</b>	Standard
<b>Contrast:</b>	Oral: None IV: 130 mL Omnipaque 350 or Isovue 370 mg/mL injected at 5 mL/sec
<b>Comments:</b>	<ol style="list-style-type: none"><li>1. Series 1 - Without Contrast</li><li>2. Series 2 - Arterial Phase</li><li>3. Send 3 mm Axial Images to PACS</li><li>4. Send 2 mm Sagittal and Coronal Reconstructions to PACS</li><li>5. Send 3D Reformatted Images to PACS</li><li>6. Send thin slices to PACS</li><li>7. Send thin slices to 3D Workstation (Vitrea Bridge or TeraRecon)</li></ol> <p><b>Use gating for CTA Chest, if available and scanner allows for diagnostic imaging.</b></p>

## Indications

With & Without Contrast: Dissection

**\*\*Values will vary between machines. Use your own discretion when selecting these values.\*\***

Reviewed by Dr. King 10/2023

\*Subject to change at the discretion of the radiologist due to clinical circumstances.\*



# CTA Abd/Pelvis



Diagnostic & Preventative Imaging Center

<b>Anatomical Reference:</b>	Xyphoid
<b>Patient Position:</b>	Supine
<b>Patient Orientation:</b>	Feet First
<b>Scan Range:</b>	Dome of Diaphragm to Ischial Tuberosities
<b>Scout:</b>	AP, Lateral if necessary
<b>Scan Type:</b>	Helical
<b>Thickness:</b>	3 mm, Recon as thin as possible
<b>Interval:</b>	3 mm, Recon as thin as possible
<b>Gantry Tilt:</b>	None
<b>SFOV:</b>	Large
<b>kVp:</b>	120
<b>mAs:</b>	Auto mA (minimum 50-maximum 420)
<b>Scan Delay:</b>	Smart Prep (ROI-Descending Aorta just below Arch)
<b>Respiration:</b>	Inspiration
<b>DFOV:</b>	Adjust to patient size
<b>Recon Algorithm:</b>	Standard
<b>Contrast:</b>	Oral: None IV: 130 mL Omnipaque 350 or Isovue 370 mg/mL injected at 5 mL/sec
<b>Comments:</b>	<ol style="list-style-type: none"><li>1. Series 1 - Without Contrast</li><li>2. Series 2 - Arterial Phase</li><li>3. Series 3 (perform regional delay if concern for active bleed seen on arterial phase acquisition) - 2 Min Delayed Phase</li><li>3. Send 3 mm Axial Images to PACS</li><li>4. Send 2 mm Sagittal and Coronal Reconstructions to PACS</li><li>5. Send 3D Reformatted Images to PACS</li><li>6. Send thin slices to PACS</li><li>7. Send thin slices to 3D Workstation (Vitrea Bridge or TeraRecon)</li></ol>

## Indications

With & Without Contrast: AAA

**\*\*Values will vary between machines. Use your own discretion when selecting these values.\*\***

Reviewed by Dr. Becker 6/2024

\*Subject to change at the discretion of the radiologist due to clinical circumstances.\*



# CTA Abd/Pelvis

## Mesenteric Protocol



<b>Anatomical Reference:</b>	Xyphoid
<b>Patient Position:</b>	Supine
<b>Patient Orientation:</b>	Feet First
<b>Scan Range:</b>	Dome of Diaphragm to Ischial Tuberosities
<b>Scout:</b>	AP, Lateral if necessary
<b>Scan Type:</b>	Helical
<b>Thickness:</b>	3 mm, Recon as thin as possible
<b>Interval:</b>	3 mm, Recon as thin as possible
<b>Gantry Tilt:</b>	None
<b>SFOV:</b>	Large
<b>kVp:</b>	120
<b>mAs:</b>	Auto mA (minimum 50-maximum 420)
<b>Scan Delay:</b>	Smart Prep (ROI-Descending Aorta just below Arch)
<b>Respiration:</b>	Inspiration
<b>DFOV:</b>	Adjust to patient size
<b>Recon Algorithm:</b>	Standard
<b>Contrast:</b>	Oral: None IV: 130 mL Omnipaque 350 or Isovue 370 mg/mL injected at 5 mL/sec
<b>Comments:</b>	<ol style="list-style-type: none"><li>1. Series 1 - Without Contrast</li><li>2. Series 2 - Arterial Phase</li><li>3. Series 3 - Venous Phase - 70 second delay</li><li>4. Send 3 mm Axial Images to PACS</li><li>5. Send 2 mm Sagittal and Coronal Reconstructions to PACS</li><li>6. Send 3D Reformatted Images to PACS</li><li>7. Send thin slices to PACS</li><li>8. Send thin slices to 3D Workstation (Vitrea Bridge or TeraRecon)</li></ol>

## Indications

With & Without Contrast: Mesenteric Ischemic Bowel

**\*\*Values will vary between machines. Use your own discretion when selecting these values.\*\***

Reviewed by Drs. King/Becker 10/2023

\*Subject to change at the discretion of the radiologist due to clinical circumstances.\*



# CTA Abd/Pelvis

GI Bleed



Diagnostic & Preventative Imaging Center

<b>Anatomical Reference:</b>	Xyphoid
<b>Patient Position:</b>	Supine
<b>Patient Orientation:</b>	Feet First
<b>Scan Range:</b>	Dome of Diaphragm to Ischial Tuberosities
<b>Scout:</b>	AP, Lateral if necessary
<b>Scan Type:</b>	Helical
<b>Thickness:</b>	3 mm, Recon as thin as possible
<b>Interval:</b>	3 mm, Recon as thin as possible
<b>Gantry Tilt:</b>	None
<b>SFOV:</b>	Large
<b>kVp:</b>	120
<b>mAs:</b>	Auto mA (minimum 50-maximum 420)
<b>Scan Delay:</b>	See below.
<b>Respiration:</b>	Inspiration
<b>DFOV:</b>	Adjust to patient size
<b>Recon Algorithm:</b>	Standard
<b>Contrast:</b>	Oral: None IV: 130 mL Omnipaque 350 or Isovue 370 mg/mL injected at 5 mL/sec
<b>Comments:</b>	<ol style="list-style-type: none"><li>1. Series 1 - Without Contrast</li><li>2. Series 2 - Enteric Phase - Place ROI on aorta at level of diaphragm. Scan 25 seconds after ROI trigger of 150 HU.</li><li>3. Series 3 - 2 minute delays</li><li>4. Send 3 mm Axial Images (Series 1-3) to PACS</li><li>5. Send 3 mm Sagittal and Coronal Reconstructions (Series 2) to PACS</li><li>6. Send 3D Reformatted Images to PACS</li><li>7. Send thin images (Series 2) to PACS</li><li>8. Send thin images (Series 1-3) to 3D Workstation (Vitrea Bridge or TeraRecon)</li></ol>

## Indications

With & Without Contrast:	Clinical/laboratory presentation consistent with rapid GI bleed (estimated bleed rate of $\geq$ to 0.35 mL/min) which would be detectable with CTA
--------------------------	--

**\*\*Values will vary between machines. Use your own discretion when selecting these values.\*\***

Reviewed by Drs. Becker & Stradling 4/2025

\*Subject to change at the discretion of the radiologist due to clinical circumstances.\*



# CTA Abd/Pelvis

For Kidney Donors



**\*To be performed at IMMC only\***

<b>Anatomical Reference:</b>	Xyphoid
<b>Patient Position:</b>	Supine
<b>Patient Orientation:</b>	Feet First
<b>Scan Range:</b>	Dome of Diaphragm to Ischial Tuberosities
<b>Scout:</b>	AP, Lateral if necessary
<b>Scan Type:</b>	Helical
<b>Thickness:</b>	Variable, See comments
<b>Interval:</b>	Variable, See comments
<b>Gantry Tilt:</b>	None
<b>SFOV:</b>	Large
<b>kVp:</b>	140
<b>mAs:</b>	Auto mA (minimum 50-maximum 420)
<b>Scan Delay:</b>	Arterial - 25 sec; Venous - 65 sec; Series 4 - 10 min
<b>Respiration:</b>	Inspiration
<b>DFOV:</b>	Adjust to patient size
<b>Recon Algorithm:</b>	Standard
<b>Contrast:</b>	Oral: None IV: 130mL Omnipaque 350 or Isovue 370 mg/ml injected at 5cc/second
<b>Comments:</b>	<ol style="list-style-type: none"><li>1. Series 1 - Without Contrast (5mm slice thickness)</li><li>2. Series 2 - Arterial Phase - Dome of Diaphragm to Iliac Crest (3 mm slice thickness)</li><li>3. Series 3 - Venous Phase - Dome of Diaphragm to Iliac Crest (3 mm slice thickness)</li><li>4. Series 4 - 10 minute Delay - Top of Kidneys through Bladder (3 mm slice thickness)</li><li>5. Send Axial Images to PACS</li><li>6. Send 2 mm Sagittal and Coronal Reconstructions (Series 1-3) to PACS</li><li>7. Send thin slices to 3D Workstation (Vitrea Bridge or TeraRecon)</li><li>8. Correct Order: CT CTA Abdomen / Pelvis W/WO contrast</li></ol>

## Indications

With & Without Contrast: Examination of Potential Living Donor

**\*\*Values will vary between machines. Use your own discretion when selecting these values.\*\***

Reviewed by Drs. King & Smith 10/2024

\*Subject to change at the discretion of the radiologist due to clinical circumstances.\*



# CTA Abd/Pelvis

For Kidney Transplant Recipients



Diagnostic & Preventative Imaging Center

**\* Kidney Transplant Recipient Protocol - For patients already on dialysis and ordered by Drs. Chaudhry and Malik - To be performed at IMMC only\***

<b>Anatomical Reference:</b>	Xyphoid
<b>Patient Position:</b>	Supine
<b>Patient Orientation:</b>	Feet First
<b>Scan Range:</b>	Dome of Diaphragm to Ischial Tuberosities
<b>Scout:</b>	AP, Lateral if necessary
<b>Scan Type:</b>	Helical
<b>Thickness:</b>	3 mm, Recon as thin as possible
<b>Interval:</b>	3 mm, Recon as thin as possible
<b>Gantry Tilt:</b>	None
<b>SFOV:</b>	Large
<b>kVp:</b>	120
<b>mAs:</b>	Auto mA (minimum 50-maximum 420)
<b>Scan Delay:</b>	Smart Prep (ROI-Descending Aorta just below Arch)
<b>Respiration:</b>	Inspiration
<b>DFOV:</b>	Adjust to patient size
<b>Recon Algorithm:</b>	Standard
<b>Contrast:</b>	Oral: None IV: 130 mL Omnipaque 350 or Isovue 370 mg/mL injected at 5 mL/sec
<b>Comments:</b>	1. Series 1 - Without Contrast 2. Series 2 - Arterial Phase 3. Series 3 - Portal Venous Phase at approximately 1 minute 4. Send 3 mm Axial Images to PACS 5. Send 2 mm Sagittal and Coronal Reconstructions to PACS 6. Send thin slices to 3D Workstation (Vitrea Bridge or TeraRecon)

## Indications

With & Without Contrast: Kidney Transplant Recipient - Only used for patients already on dialysis  
**\*\* For patients not on dialysis - Perform a CT Abd/Pelvis without contrast only\*\***

**\*\*Values will vary between machines. Use your own discretion when selecting these values.\*\***

Reviewed by Dr. King 7/2020

\*Subject to change at the discretion of the radiologist due to clinical circumstances.\*



# CTA Renal Arteries



<b>Anatomical Reference:</b>	Xyphoid
<b>Patient Position:</b>	Supine
<b>Patient Orientation:</b>	Feet First
<b>Scan Range:</b>	Dome of Diaphragm to Iliac Crest
<b>Scout:</b>	AP, Lateral if necessary
<b>Scan Type:</b>	Helical
<b>Thickness:</b>	3 mm, Recon as thin as possible
<b>Interval:</b>	3 mm, Recon as thin as possible
<b>Gantry Tilt:</b>	None
<b>SFOV:</b>	Large
<b>kVp:</b>	120 (100 for small patients)
<b>mAs:</b>	Auto mA (minimum 50-maximum 420)
<b>Scan Delay:</b>	Smart Prep (ROI-Descending Aorta just below Arch)
<b>Respiration:</b>	Inspiration
<b>DFOV:</b>	Adjust to patient size
<b>Recon Algorithm:</b>	Standard
<b>Contrast:</b>	Oral: None IV: 130 mL Omnipaque 350 or Isovue 370 mg/mL injected at 5 mL/sec
<b>Comments:</b>	1. Series 1 - Without Contrast 2. Series 2 - Arterial Phase 3. Send 3 mm Axial Images to PACS 4. Send 2 mm Sagittal and Coronal Reconstructions to PACS 5. Send 3D Reformatted Images to PACS 6. Send thin slices to PACS 7. Send thin slices to 3D Workstation (Vitrea Bridge or TeraRecon)

## Indications

With & Without Contrast: Hypertension, Stenosis

**\*\*Values will vary between machines. Use your own discretion when selecting these values.\*\***

Reviewed by Dr. King 10/2023

\*Subject to change at the discretion of the radiologist due to clinical circumstances.\*



# CTA Runoff



<b>Anatomical Reference:</b>	Xyphoid
<b>Patient Position:</b>	Supine; TAPE FEET TOGETHER (if possible) to prevent motion
<b>Patient Orientation:</b>	Feet First
<b>Scan Range:</b>	Dome of Diaphragm to Toes
<b>Scout:</b>	AP, Lateral if necessary
<b>Scan Type:</b>	Helical
<b>Thickness:</b>	3 mm, Recon as thin as possible
<b>Interval:</b>	3 mm, Recon as thin as possible
<b>Gantry Tilt:</b>	None
<b>SFOV:</b>	Large
<b>kVp:</b>	140
<b>mAs:</b>	Auto mA (minimum 50-maximum 420)
<b>Scan Delay:</b>	Smart Prep (ROI-Descending Aorta just below Arch)
<b>Respiration:</b>	Inspiration
<b>DFOV:</b>	Adjust to patient size
<b>Recon Algorithm:</b>	Standard
<b>Contrast:</b>	Oral: None IV: 150 mL Omnipaque 350 or Isovue 370 mg/mL injected at 5 mL/sec
<b>Comments:</b>	<ol style="list-style-type: none"><li>1. Series 1 - Without Contrast - Dome of diaphragm to toes</li><li>2. Series 2 - Arterial Phase - Dome of diaphragm to toes</li><li>3. Series 3 - Knees to toes - *ONLY if you see you lost the contrast bolus* - Set up prior to series 2 scan just in case you need it</li><li>4. Send 3 mm Axial Images to PACS</li><li>5. Send 2 mm Sagittal and Coronal Reconstructions (Series 2) to PACS</li><li>6. Send 3D Reformatted Images of Aorta and Lower Extremity Arteries to PACS</li><li>7. Send thin slices (Series 2 Only) to PACS</li><li>8. Send thin slices to 3D Workstation (Vitrea Bridge or TeraRecon)</li></ol>

## Indications

With & Without Contrast: Peripheral Arterial Disease, Gangrenous Extremities, Non-existent Distal Pulses

**\*\*Values will vary between machines. Use your own discretion when selecting these values.\*\***

Reviewed by Dr. Stradling 10/2023

\*Subject to change at the discretion of the radiologist due to clinical circumstances.\*



# Coronary CTA



Diagnostic & Preventative Imaging Center

**\*\*To be performed at IMMC and Iowa Radiology-Clive only\*\***

<b>Anatomical Reference:</b>	Top of shoulders	
<b>Patient Position:</b>	Supine	
<b>Patient Orientation:</b>	Feet First	
<b>Scan Range:</b>	Entire coronary circulation and heart	
<b>Scout:</b>	AP	
<b>Scan Type:</b>	Helical	
<b>Rotation Time:</b>	0.33 sec	
<b>Acquisition Slice Thickness:</b>	Cardiac score=30x0.6	Coronary CTA=64x0.6mm
<b>Pitch:</b>	Varied	
<b>Recon Interval (mm):</b>	Cardiac score=3x3	Coronary CTA=0.6mm x 0.3mm
<b>Gantry Tilt:</b>	None	
<b>SFOV:</b>	500 mm	
<b>kVp:</b>	120	
<b>mAs:</b>	Varied on patient body habitus	
<b>Scan Delay:</b>	Smart Prep (ROI-Ascending aorta above LCA, Scan Threshold-100 HU)	
<b>Respiration:</b>	Inspiration	
<b>DFOV:</b>	Varied	
<b>Recon Algorithm:</b>	B35f heartview medium ca score, mediastinum for cardiac score, I36f heartview medium ASA, CT angio for coronary CTA (SAFIRE-3)	
<b>Contrast:</b>	Oral:	None
	IV:	60 mL Omnipaque 350 mg/mL or equivalent water soluble contrast injected at 5 mL/sec followed immediately by a mixed bolus of 30mL Omnipaque 350 mg/mL or equivalent water soluble contrast and 30mL saline injected at 5 mL/sec. May need to increase contrast amount with larger body habitus. Injection of 40 mL saline at 5 mL/sec to flush.
<b>Scans:</b>	<ol style="list-style-type: none"><li>1. AP Scout</li><li>2. Non contrast of entire heart and vessels (calcium score)</li><li>3. Monitoring on the ascending aorta just above LCA (Trigger at 100 HU)</li><li>4. Gated scan to include entire coronary circulation and heart</li></ol>	
<b>Comments:</b>	<ol style="list-style-type: none"><li>1. All helical scans are gated.</li><li>2. Calcium score prior unless indicated otherwise by ordering doctor (PACS) Qr36/Mediastinum</li><li>3. 65% phase (PACS and 3D workstation) 0.6mm x 3mm Bv41/CT Angio</li><li>4. 75% phase (PACS and 3D workstation) 0.6mm x 3mm Bv41/CT Angio</li><li>5. 80% phase (PACS and 3D workstation) 0.6mm x 3mm Bv41/CT Angio</li></ol>	

*Continued on next page*

Reviewed by Dr. Wolford 1/2025

\*Subject to change at the discretion of the radiologist due to clinical circumstances.\*



# Coronary CTA - Routine Cont.

## Comments:

6. 0-90% phase (3D workstation) 1mm x 1mm Bv41/CT Angio
7. Full FOV to include lungs (3D workstation and PACS) 5 mm x 5 mm Bf39/Mediastinum
8. 40% trigger (PACS and 3D workstation) 0.6mm x 0.3mm Bv41/CT Angio

\*\*\*Manually push ECG gating image to PACS

9. If the ordering office feels the patient's heart rate will run higher than 65 BPM the day of the exam, they can prescribe 50-150 mg of oral Metoprolol for the patient to take 1.5 hours prior to the exam and the evening before the exam. A 0.4 mg Nitroglycerin tablet will be given sublingual 4 minutes prior to imaging.

## Indications

With & Without Contrast: Chest Pain, Abnormal Stress Echo, Suspected Congenital Anomalies, Irregular Heart Rate

**\*\*Values will vary between machines. Use your own discretion when selecting these values.\*\***

Reviewed by Dr. Wolford 1/2025

\*Subject to change at the discretion of the radiologist due to clinical circumstances.\*



# DEXA



## Standard Examination

AP scan of the Lumbar Spine

AP scan of the Left Hip

## Alternate Scan Sites

In instances where the patient has had left hip surgery, scan the right hip instead.

Add a scan of the nondominant wrist if the L-Spine has hardware, the patient has severe scoliosis where the spine is out of the field of view or the patient has had both hips replaced.

If in doubt at all, add a scan of the nondominant wrist.

## Contraindications

The following may limit the value or require modification of the technique or rescheduling of the examination in some situations, including:

1. Recently administered gastrointestinal contrast or radionuclides or calcium supplement tablet within the field of view. Calcium should be held 24 hours prior to the DEXA scan.
2. Pregnancy.
3. Severe degenerative changes or fracture deformity in the measurement area.

Reviewed by Dr. Walker 6/2017



# Pediatric DEXA



\*Note – Dr. Steinberg will read all Pediatric DEXA exams\*

## 16-18 y/o

Call Dr. Steinberg for protocol, if he is available.

Depending on diagnosis, may only need to do lumbar and hip.

If Dr. Steinberg is on vacation/unavailable, scan whole body, lumbar and hip.

## 5-15 y/o

Scan whole body, lumbar and left hip.

If there is any hardware in the body, do NOT scan the whole body, only scan lumbar and hip.

## 4 y/o and younger

Do not perform. Software is not compatible.

## Indications

Treatment for Acute Lymphoblastic Lymphoma (ALL)

Multiple Fractures without Injury

Reviewed by Dr. Steinberg 6/2017



# Dr. Hilpipre



## Esophagram

2 packets crystals mixed with ½ ounce water, thick barium in left hand while standing, LPO. He will use thin barium also and a straw. Will use barium tablet and water for most adult patients and any patient with sensation of food getting “stuck”.

Overhead films:      None.

## UGI

Overhead films:      AP Scout to include LUQ of abdomen.

2 packets crystals mixed with ½ ounce water, thick barium in left hand while standing, LPO. He will lay the table down, then thin barium through a straw. May use a barium tablet if suspecting stenosis.

## Small Bowel

Scout. Drink 2 cups of thin barium.

Immediate AP film, be sure to include the entire abdomen.

Do PA every 30 minutes for 1 hour, then check films. Additional film intervals per radiologist discretion.

When barium gets to the ileocecal valve, he will come in and spot under fluoro with glove.

--If for fistula or Crohns Disease, Dr. Hilpipre will fluoro at regular intervals.

**\*\*If UGI and SBFT are ordered together, do scout before starting UGI.\*\***

## BE

Scout. He will come in and spot with fluoro.

Overhead films:      AP  
                             Sigmoid  
                             PA  
                             Bilat Decubs  
                             Bilat Obliques  
                             Lateral Rectum (with balloon inflated)  
                             - Check films with radiologist.  
                             - Deflate balloon, remove catheter, then:  
                             Lateral Rectum  
                             Post Evac  
                             - Do not need to check last 2 views with radiologist. Patient may leave.

Reviewed by Dr. Hilpipre 6/2024



# Dr. Holdsworth



## Esophagram

2 packets crystals mixed with ½ ounce water, thick barium in left hand while standing, LPO. He will lay the table down, then thin barium through a straw. May use a barium tablet if suspecting stenosis.

Overhead films: Dr. will let you know when finished with fluoro.

## UGI

2 packets crystals mixed with ½ ounce water, thick barium in left hand while standing, LPO. He will lay the table down, then thin barium through a straw. May use a barium tablet if suspecting stenosis.

Overhead films: Dr. will let you know when finished with fluoro.

## Small Bowel

Scout. Drink 2 cups of thin barium.

Immediate PA film, be sure to include the entire abdomen.

Do PA every 15 minutes for 1 hour, then every 30 minutes for 1 hour.

When barium gets to the ileocecal valve, he will come in and spot under fluoro with glove.

--If for fistula or Crohns Disease, Dr. Holdsworth will fluoro at regular intervals.

**\*\*If UGI and SBFT are ordered together, do scout before starting UGI.\*\***

## BE

Scout. He will come in and spot with fluoro.

Overhead films: AP  
Sigmoid  
Lateral Rectum  
PA  
Bilat Decubs  
Post Evac.

Reviewed by Dr. Holdsworth 1/2018



# Dr. Hurlbut



## Esophagram

2 packets crystals mixed with ½ ounce water, thick barium in left hand while standing, LPO. He will use thin barium also and a straw. Will use barium tablet for anyone over 18 years of age.

Overhead films: Dr. will let you know when finished with fluoro.

## UGI

2 packets crystals mixed with ½ ounce water, thick barium in left hand while standing, LPO. He will lay the table down, then thin barium through a straw. May use a barium tablet if suspecting stenosis.

Overhead films: Dr. will let you know when finished with fluoro.

## Small Bowel

Scout. Drink 2 cups of thin barium.

Immediate PA film, be sure to include the entire abdomen.

Do PA every 15 minutes for 1 hour, then every 30 minutes for 1 hour.

When barium gets to the ileocecal valve, he will come in and spot under fluoro with glove.

--If for fistula or Crohns Disease, Dr. Hurlbut will fluoro at regular intervals.

**\*\*If UGI and SBFT are ordered together, do scout before starting UGI.\*\***

## BE

Scout. He will come in and spot with fluoro.

Overhead films: AP  
Sigmoid  
Lateral Rectum  
PA  
Bilat Decubs  
Post Evac.

Reviewed by Dr. Hurlbut 8/2016



# Dr. Jabour



## Esophagram

2 packets crystals mixed with ½ ounce water, thick barium in left hand while standing, LPO. He will use thin barium also and a straw. Will use barium tablet for anyone over 18 years of age.

Overhead films: Dr. will let you know when finished with fluoro.

## UGI

2 packets crystals mixed with ½ ounce water, thick barium in left hand while standing, LPO. He will lay the table down, then thin barium through a straw. May use a barium tablet if suspecting stenosis.

Overhead films: Dr. will let you know when finished with fluoro.

## Small Bowel

Scout. Drink 2 cups of thin barium.

Immediate PA film, be sure to include the entire abdomen.

Do PA every 15 minutes for 1 hour, then every 30 minutes for 1 hour.

When barium gets to the ileocecal valve, he will come in and spot under fluoro with glove.

--If for fistula or Crohns Disease, Dr. Jabour will fluoro at regular intervals.

**\*\*If UGI and SBFT are ordered together, do scout before starting UGI.\*\***

## BE

Scout. He will come in and spot with fluoro.

Overhead films: AP  
Sigmoid  
Lateral Rectum  
PA  
Bilat Decubs  
Post Evac.

Reviewed by Dr. Jabour 9/2017



# Dr. Julian



## Esophagram

Thin barium PA then LPO. 2 packets crystals then do PA and LPO with thick. He may get lateral of larynx with thick or thin if pt reports aspiration. He may or may not use barium pill depending on symptoms reported. Table flat, patient in RPO and have them sip thin through straw and valsalva watching for reflux.

## UGI

2 packets crystals. PA and LPO of esophagus with thick. Table flat and get PA and oblique views of stomach and duodenum. Try to get good images of GE junction and duodenal bulb.

## Small Bowel

Pre film. 2 cups Gastroview. Immediate post. Get half hour film and then either every half hour or hour depending how much it's moved.

## BE

Scout. He will come in and spot with fluoro.

Overhead films:      AP  
                             Sigmoid  
                             Lateral Rectum  
                             PA  
                             Bilat Decubs  
                             Post Evac.

Reviewed by Dr. Julian 6/2024



# Dr. Karibo



## Esophagram

2 packets crystals mixed with ½ ounce water, thick barium in left hand while standing, LPO. He will use thin barium also and a straw. Will use barium tablet for anyone over 18 years of age.

Overhead films: Dr. will let you know when finished with fluoro.

## UGI

2 packets crystals mixed with ½ ounce water, thick barium in left hand while standing, LPO. He will lay the table down, then thin barium through a straw. May use a barium tablet if suspecting stenosis.

Overhead films: Dr. will let you know when finished with fluoro.

## Small Bowel

Scout. Drink 2 cups of thin barium.

Immediate PA film, be sure to include the entire abdomen.

Do PA every 15 minutes for 1 hour, then every 30 minutes for 1 hour.

When barium gets to the ileocecal valve, he will come in and spot under fluoro with glove.

--If for fistula or Crohns Disease, Dr. Karibo will fluoro at regular intervals.

**\*\*If UGI and SBFT are ordered together, do scout before starting UGI.\*\***

## BE

Scout. He will come in and spot with fluoro.

Overhead films: AP  
Sigmoid  
Lateral Rectum  
PA  
Bilat Decubs  
Post Evac.

Reviewed by Dr. Karibo 5/2016



# Dr. King



## Esophagram

2 packets crystals mixed with ½ ounce water, thick barium in left hand while standing, LPO. He will use thin barium also and a straw. Will use barium tablet and water for most adult patients and any patient with sensation of food getting “stuck”.

Overhead films: Dr. will let you know when finished with fluoro.

## UGI

2 packets crystals mixed with ½ ounce water, thick barium in left hand while standing, LPO. He will lay the table down, then thin barium through a straw. May use a barium tablet if suspecting stenosis.

Overhead films: Dr. will let you know when finished with fluoro.

## Small Bowel

Scout. Drink 2 cups of thin barium.

Immediate PA film, be sure to include the entire abdomen.

Do PA every 15 minutes for 1 hour, then every 30 minutes for 1 hour.

When barium gets to the ileocecal valve, he will come in and spot under fluoro with glove.

--If for fistula or Crohns Disease, Dr. King will fluoro at regular intervals.

**\*\*If UGI and SBFT are ordered together, do scout before starting UGI.\*\***

## BE

Scout. He will come in and spot with fluoro.

Overhead films: AP  
Sigmoid  
Lateral Rectum  
PA  
Bilat Decubs  
Post Evac.

Reviewed by Dr. King 4/2016



# Dr. Kliewer



## Esophagram

Crystals mixed with water, thick barium in left hand while standing, LPO. He will lay the table down, then thin barium through a straw while RAO. Will use barium tablet for most adult patients. Any patient with sensation of food getting "stuck", check with doctor prior to exam.

Overhead films:      None

## UGI

Crystals mixed with water, thick barium in left hand while standing, LPO. He will lay the table down, then thin barium through a straw while RAO.

Overhead films:      None

## Small Bowel

Scout. Drink 2 cups of thin barium.  
Immediate AP film, be sure to include the stomach, then 15 minute, then check.  
When barium gets to the ileocecal valve, he will come in and spot with fluoro.

**\*\*If UGI and SBFT are ordered together, do scout before starting UGI.\*\***

## BE

Scout. He will come in and spot with fluoro.

Overhead films:      AP  
                             Sigmoid  
                             Lateral Rectum  
                             PA  
                             Bilat Decubs  
                             Post Evac.

Reviewed by Dr. Kliewer 6/2024



# Dr. Liudahl



## Esophagram

2 packets crystals mixed with ½ ounce water, thick barium in left hand while standing, LPO. He will use thin barium also and a straw. Will use barium tablet and water for most adult patients and any patient with sensation of food getting “stuck”.

Overhead films: Dr. will let you know when finished with fluoro.

## UGI

2 packets crystals mixed with ½ ounce water, thick barium in left hand while standing, LPO. He will lay the table down, then thin barium through a straw. May use a barium tablet if suspecting stenosis.

Overhead films: Dr. will let you know when finished with fluoro.

## Small Bowel

Scout. Drink 2 cups of thin barium.

Immediate PA film, be sure to include the entire abdomen.

Do PA every 15 minutes for 1 hour, then every 30 minutes for 1 hour.

When barium gets to the ileocecal valve, he will come in and spot under fluoro with glove.

--If for fistula or Crohns Disease, Dr. Liudahl will fluoro at regular intervals.

\*\*If UGI and SBFT are ordered together, do scout before starting UGI.\*\*

## BE

Scout. He will come in and spot with fluoro.

Overhead films: AP  
Sigmoid  
Lateral Rectum  
PA  
Bilat Decubs  
Post Evac.

Reviewed by Dr. Liudahl 10/2018



# Dr. Myneni



## Esophagram

Crystals mixed with water, thick barium in left hand while standing, LPO. She will lay the table down, then thin barium through a straw.

Overhead films: Dr. will let you know when finished with fluoro.

## UGI

Crystals mixed with water, thick barium in left hand while standing, LPO. She will lay the table down, then thin barium through a straw.

Overhead films: Dr. will let you know when finished with fluoro.

## Small Bowel

Scout. Drink 2 cups of thin barium.

Immediate AP film, be sure to include the stomach.

Do PA every 15 minutes for the first hour.

When barium gets to the ileocecal valve, she will come in and spot with fluoro.

**\*\*If UGI and SBFT are ordered together, do scout before starting UGI.\*\***

## BE

Scout. She will come in and spot with fluoro.

Overhead films: AP  
Sigmoid  
Lateral Rectum  
PA  
Bilat Decubs  
Post Evac.

Reviewed by Dr. Myneni 4/2016



# Dr. Peters



## Esophagram

2 packets crystals mixed with ½ ounce water, thick barium in left hand while standing, LPO. He will use thin barium also and a straw. Will use barium tablet and water for most adult patients and any patient with sensation of food getting “stuck”.

Overhead films: Dr. will let you know when finished with fluoro.

## UGI

2 packets crystals mixed with ½ ounce water, thick barium in left hand while standing, LPO. He will lay the table down, then thin barium through a straw. May use a barium tablet if suspecting stenosis.

Overhead films: Dr. will let you know when finished with fluoro.

## Small Bowel

Scout. Drink 2 cups of thin barium.

Immediate PA film, be sure to include the entire abdomen.

Do PA every 15 minutes for 1 hour, then every 30 minutes for 1 hour.

When barium gets to the ileocecal valve, he will come in and spot under fluoro with glove.

--If for fistula or Crohns Disease, Dr. Peters will fluoro at regular intervals.

**\*\*If UGI and SBFT are ordered together, do scout before starting UGI.\*\***

## BE

Scout. He will come in and spot with fluoro.

Overhead films: AP  
Sigmoid  
Lateral Rectum  
PA  
Bilat Decubs  
Post Evac.

Reviewed by Dr. Peters 6/2024



# Dr. Riebe



## Esophagram

Thick barium in left hand while standing.

Will use barium tablet and water for most adult patients and any patient with sensation of food getting "stuck".

He will lay the table flat.

He will use thin barium and a straw while flat.

## UGI

Will start with 1 packet of crystals, then thick barium in left hand while standing.

He will lay the table down, then thin barium through a straw. May use a barium tablet if suspecting stenosis.

## Small Bowel

Scout. Drink 2 cups of thin barium.

Immediate PA film, be sure to include the entire abdomen.

Do PA every 15 minutes for 1 hour, then every 30 minutes for 1 hour.

When barium gets to the ileocecal valve, will be done.

**\*\*If UGI and SBFT are ordered together, do scout before starting UGI.\*\***

## BE

Scout. He will come in and spot with fluoro.

Overhead films:

- AP
- Sigmoid
- Lateral Rectum
- PA
- Bilat Decubs
- Post Evac.

Reviewed by Dr. Riebe 6/2024



# Dr. Smith



## Esophagram

2 packets crystals mixed with ½ ounce water, thick barium in left hand while standing, LPO. He will use thin barium also and a straw. Will use barium tablet and water for most adult patients and any patient with sensation of food getting “stuck”.

Overhead films: Dr. will let you know when finished with fluoro.

## UGI

2 packets crystals mixed with ½ ounce water, thick barium in left hand while standing, LPO. He will lay the table down, then thin barium through a straw. May use a barium tablet if suspecting stenosis.

Overhead films: Dr. will let you know when finished with fluoro.

## Small Bowel

Scout. Drink 2 cups of thin barium.

Immediate PA film, be sure to include the entire abdomen.

Do PA every 15 minutes for 1 hour, then every 30 minutes for 1 hour.

When barium gets to the ileocecal valve, he will come in and spot under fluoro with glove.

--If for fistula or Crohns Disease, Dr. Smith will fluoro at regular intervals.

**\*\*If UGI and SBFT are ordered together, do scout before starting UGI.\*\***

## BE

Scout. He will come in and spot with fluoro.

Overhead films: AP  
Sigmoid  
Lateral Rectum  
PA  
Bilat Decubs  
Post Evac.

Reviewed by Dr. Smith 6/2024



# Dr. Soe



## Esophagram

Frame rate = 4 F/s

Discuss case with Dr. Soe before mixing crystals with water. Thick barium while standing.

Overhead films: Dr. will let you know when finished with fluoro.

## UGI

Start patient sitting on the table, mix crystals with water. Thick barium with the patient in the RAO position.

Overhead films: None

## Small Bowel

Scout KUB. Show scout to Dr. Soe.

Drink 2 cups of thin barium mixed with gastrografin if needed (usually needed).

Immediate KUB of abdomen.

30 minutes following immediate film, take another KUB of abdomen and check with Dr. Soe. He will then decide on the time intervals for any additional films. \*Be sure to mark the delay time on all films.\*

When Dr. Soe determines it is time for the spot films, he will come in and spot with fluoro and inflated paddle.

## UGI/SBFT

Scout KUB. Show scout to Dr. Soe.

Start with patient sitting on table. Crystals mixed with water. Thick barium with patient in the RAO position.

Overhead films: None

Show Dr. Soe the overhead films.

Have the patient drink a second cup of thick barium.

Take an immediate KUB of the abdomen when patient done drinking.

30 minutes following immediate film, take another KUB of abdomen and check with Dr. Soe. He will then decide on the time intervals for any additional films. \*Be sure to mark the delay time on all films.\*

When Dr. Soe determines it is time for the spot films, he will come in and spot with fluoro and inflated paddle.

Reviewed by Dr. Soe 3/2016



# Dr. Soe



## BE – Double Contrast

Scout. Show Dr. Soe. Insert tip. He will come in and spot with fluoro.

Overhead films:      PA  
                             Right Lateral Rectum  
                             RPO – 20 degrees  
                             LPO – 45 degrees  
                             Chassard – 15 degree RAO with 35 degree caudal angle  
                             Chassard – 15 degree LPO with 35 degree cephalic angle  
                             Bilat Decubitus – include rectal area  
                             Check images with Dr. Soe  
                             Post Evac. – include entire colon

## BE – Single Contrast

Scout. Show Dr. Soe. Insert tip. He will come in and spot with fluoro.

Overhead films:      AP  
                             Chassard – 15 degree LPO with 35 degree cephalic angle  
                             RPO – 45 degrees  
                             LPO – 45 degrees  
                             Left Lateral Rectosigmoid View  
                             Check images with Dr. Soe  
                             Post Evac. – include entire colon

## IVP

Scout KUB. Show Dr. Soe

Start IV.  
Inject 100 mL Isovue.

Patient under 40 – After injection, do immediate of kidneys and 3 tomos of kidneys  
Patient over 40 – After injection, do 3 tomos of kidneys

5 minute – KUB  
10 minute – KUB  
15 minute – KUB

All films need checked with Dr. Soe. He will advise if other images are needed.

Upright Post Void film

Reviewed by Dr. Soe 3/2016



# Dr. Waddell



## Esophagram

Crystals mixed with water, thick barium in left hand while standing, LPO. He will lay the table down, then thin barium through a straw while RAO.

Overhead films:      None

## UGI

Crystals mixed with water, thick barium in left hand while standing, LPO. He will lay the table down, then thin barium through a straw while RAO.

Overhead films:      None

## Small Bowel

Scout. Drink 2 cups of thin barium.

Immediate AP film, be sure to include the stomach, then 15 minute, then check.

When barium gets to the ileocecal valve, he will come in and spot with fluoro.

**\*\*If UGI and SBFT are ordered together, do scout before starting UGI.\*\***

## BE

Scout. He will come in and spot with fluoro.

Overhead films:      AP  
                             Sigmoid  
                             Lateral Rectum  
                             PA  
                             Bilat Decubs  
                             Post Evac.

Reviewed by Dr. Waddell 3/2016



# Dr. Wolford



## Esophagram

Crystals mixed with water, thick barium in left hand while standing, LPO. He will lay the table down, then thin barium through a straw while RAO. Will use barium tablet for most adult patients. Any patient with sensation of food getting "stuck", check with doctor prior to exam.

Overhead films:      None

## UGI

Crystals mixed with water, thick barium in left hand while standing, LPO. He will lay the table down, then thin barium through a straw while RAO.

Overhead films:      None

## Small Bowel

Scout. Drink 2 cups of thin barium.

Immediate AP film, be sure to include the stomach, then 15 minute, then check.

When barium gets to the ileocecal valve, he will come in and spot with fluoro.

**\*\*If UGI and SBFT are ordered together, do scout before starting UGI.\*\***

## BE

Scout. He will come in and spot with fluoro.

Overhead films:      AP  
                             Sigmoid  
                             Lateral Rectum  
                             PA  
                             Bilat Decubs  
                             Post Evac.

Reviewed by Dr. Wolford 10/2017



# General X-Ray



## Comments

ALL lateral views of the chest and spine should be oriented with the anterior aspect of the patient on the left of the image in PACS (See Fig. A and Fig. B)

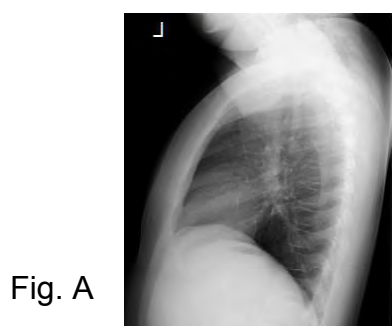
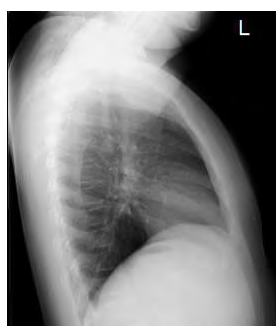

Fig. A

YES



NO

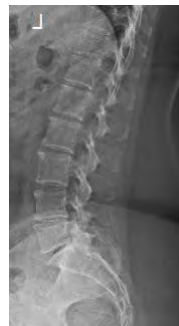
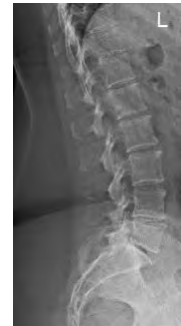
Fig. B

YES



NO

## Abdomen

Abdomen	Upright/KUB
KUB	AP KUB
Foreign Body	AP Mouth to Pubic Symphysis

## Chest

Chest	PA/Lateral
Ribs	PA (or AP, depending on location of pain)/Oblique (BB marker on focal pain) *Document detailed history for all rib exams*
Sternum	RAO/Lateral
SC Joints	PA/Oblique to side of interest

## Extremities

Shoulder	Neutral/Grashey/Y-View
AC Joints	AP with Weights/AP without Weights
Humerus	AP/Lateral
Scapula	AP/Y-View

**\*\*These are routine adult protocols. If order requests specific views, perform the exam as ordered.\*\***

**\*\*\*Adapt protocols accordingly per patient.\*\*\***

Reviewed by Dr. Steinberg 10/2018



# General X-Ray



## Extremities-cont.

Clavicle	AP/AP Axial
Forearm	AP/Lateral
Elbow	AP/External Oblique/Lateral
Wrist-Routine	PA/Oblique/Lateral
Wrist-4 View	PA/Oblique/Lateral/Scaphoid View, preferably in the PA position with 15-30° ulnar deviation *For patients ≥ 11 y/o with wrist trauma or non-traumatic pain in the scaphoid or radial styloid area*
Hand	PA/Oblique/Fan Lateral
Finger	PA/Oblique/Lateral
Pelvis	AP *For all patients ≥ 16 y/o*
Pediatric Pelvis	AP Pelvis and Bilat Frog Leg Pelvis *Include bilat hips on both views for all patients ≤ 15 y/o*
Hip	AP/Frog Leg Lateral *For all patients ≥ 16 y/o*
Pediatric Hip	AP Pelvis and Bilat Frog Leg Pelvis *Include bilat hips on both views for all patients ≤ 15 y/o*
Femur	AP/Lateral
Knee	AP/Lateral/Rosenberg/Sunrise (first 3 views performed standing)
Tib/Fib	AP/Lateral
Ankle	AP/Oblique/Lateral
Foot	AP/Oblique/Lateral
Toe	AP/Oblique/Lateral
Calcaneus	Tangential/Lateral

## Head Work

Skull	PA/Townes/Both Laterals
Sinuses	Caldwell/Waters/Lateral
Nasal Bones	Waters/Both Laterals
Facial Bones	Waters/Caldwell/Lateral
Mandible	Townes/PA/Both Lateral Obliques

**\*\*These are routine adult protocols. If order requests specific views, perform the exam as ordered.\*\***

**\*\*\*Adapt protocols accordingly per patient.\*\*\***

Reviewed by Dr. Steinberg 9/2023



# General X-Ray



## Head Work-cont.

TMJ	Townes/AP/Bilat Laterals (Open and Closed Mouth)
Foreign Body	Caldwell/Waters/Lateral
Orbits	PA/Waters/Bilat Rhese
Shunt	PA Skull/Lateral Skull/AP Chest/AP Abdomen

## Spine

Cervical Spine	AP/Odontoid/Lateral, Swimmers if needed
Thoracic Spine	AP/Lateral/Swimmers
Lumber Spine	AP/Lateral/L5-S1 Spot
Sacrum/Coccyx	AP Sacrum/AP Coccyx/Lateral
SI Joints	AP Axial/Bilat Obliques
Scoliosis	Spine from C4 through Pelvis (PA for Females and AP for Males)/ Lateral Spine from C4 through Pelvis Need entire pelvis, do not cone If not able to image in 1 exposure, images need to be stitched together

## Bone Survey

Chest	PA
Skull	AP/Lateral
C-Spine	AP/Lateral
T-Spine	AP/Lateral
L-Spine	AP/Lateral
Pelvis	AP
Humerus	Bilateral AP
Forearm	Bilateral AP
Femur	Bilateral AP
Tib/Fib	Bilateral AP

## Bone Age

Left Hand/Wrist	PA (Annotate Gender and DOB on image)
-----------------	---------------------------------------

**\*\*These are routine adult protocols. If order requests specific views, perform the exam as ordered.\*\***

**\*\*\*Adapt protocols accordingly per patient.\*\*\***

Reviewed by Dr. Steinberg 12/2020



# General X-Ray



## IVP

Scout

Show radiologist.

Inject 100cc IV contrast.

Immediate AP

5 minute Bilateral Obliques

10 minute AP

Show radiologist.

Post Void AP

**\*\*Ask radiologist before exam.\*\***

## Pediatric Bone Survey (Abuse and/or Trauma)

Chest	AP
Ribs	Bilateral Oblique
Skull	AP/Lateral
C-Spine	Lateral
T-Spine	AP/Lateral
L-Spine	AP/Lateral
Upper Extremities	Bilateral AP
Pelvis	AP
Elbows	Bilateral AP
Wrists	Bilateral PA
Hands	Bilateral PA
Lower Extremities	Bilateral AP
Knees	Bilateral AP
Ankles	Bilateral AP/Lateral
Feet	Bilateral AP

**\*\*These are routine protocols. If order requests specific views, perform the exam as ordered.\*\***

Reviewed by Dr. Steinberg 6/2017

\*Subject to change at the discretion of the radiologist due to clinical circumstances.\*



# General X-Ray



## Pediatric Bone Survey (Other than Abuse/Trauma)

Chest	AP
Skull	AP/Lateral
C-Spine	Lateral
T-Spine	Lateral
L-Spine	Lateral
Pelvis	AP
Humerus	Bilateral AP
Forearm	Bilateral AP
Hand	Bilateral PA
Femur	Bilateral AP
Tib/Fib	Bilateral AP
Feet	Bilateral AP

## G-Tube Contrast Check

Correct Imaging Order – XR Abdomen 1 View (IMG154)  
Contrast – Omnipaque 300 mg/mL or equivalent water-soluble contrast

### Adult Patient

- AP Supine KUB Scout
- Inject 30 mL Omnipaque 300 mg/mL or equivalent water-soluble contrast
- Immediate AP
- 10-minute AP & Lateral

### Pediatric Patient

- AP Supine KUB Scout
- Inject 15 mL Omnipaque 300 mg/mL or equivalent water-soluble contrast
- Immediate AP
- 10-minute AP & Lateral

Annotate all images (i.e. Scout, Immediate, 10-minute)

Tech notes must include patient's room number, time contrast administered, and the amount of contrast administered

**\*\*These are routine protocols. If order requests specific views, perform the exam as ordered.\*\***

Reviewed by Drs. King/Becker/Steinberg 1/2025

\*Subject to change at the discretion of the radiologist due to clinical circumstances.\*



# Insulin Pumps & CGM Devices



## Contraindications for Insulin Pumps

All insulin pump companies recommend that insulin pumps are disconnected where there is a risk of exposure to x-rays, radiation or MRI. This is indicated for general x-rays, mammograms, DEXA, fluoroscopy, CT Scan and MRI. The insulin pump must be left outside the exam room where the test is performed.

If the insulin pump is disconnected for longer than one hour, the patient will need to contact the referring physician prior to the exam for instructions.

## Contraindications for Continuous Glucose Monitoring (CGM) Devices

All continuous glucose monitoring device should not be exposed to x-rays or MRIs. The patient will remove the sensor/transmitter prior to any general x-ray, mammogram, DEXA, fluoroscopy, CT scan or MRI. All the components of the CGM could be damaged when exposed to any radiation and/or strong electromagnetic field.

## Because of the Contraindications involving insulin pumps and Continuous Glucose Monitoring (CGM) device:

All Iowa Diagnostic Imaging and Procedure Center patients will be asked prior to any x-rays, mammogram, DEXA, Fluoroscopy, CT Scan or MRI if they are using an insulin pump or Continuous Glucose Monitoring (CGM) Device. If the patient has:

**Insulin Pump:** Have the patient disconnect and remove the pump and leave the pump outside the exam room. If the patient will be disconnected longer than one hour the patient will need to contact the referring physician for instructions prior to the exam.

**Continuous Glucose Monitoring (CGM) Device:** The patient will remove the sensor and transmitter prior to the x-ray exam or MRI and leave the device outside the exam room.

Reviewed by Dr. Keller 1/2019



# Interventional Radiology



## Heparinized Saline on Sterile Scrub Table in Interventional Radiology

- Heparinized Saline Solution – 2u/mL-500mL Heparin
- Heparinized Saline is used in all Interventional procedures if and when arterial or venous access is being achieved. The heparinized saline is used on the sterile scrub table in bowls and syringes to flush catheters and wires.

## Arterial Line Set-Up & Usage for Angiography Cases in Interventional Radiology

- Heparinized Saline Solution – 2u/mL-500mL bag of Heparin will be used in a pressure bag set-up during all angiographic cases in Interventional Radiology.
- If the arterial line is continued once the patient leaves the Radiology Department, the pressure bag will be converted to Normal Saline to support the Hospital Protocol.



# Interventional Radiology



## Abdominal abscess drain/Cholecystostomy drains

- On all abdominal abscess and cholecystostomy drains, obtain the following on the fluid:
  - Aerobic culture
  - Anaerobic culture

## Thoracentesis

- Always send a fluid sample to the lab

## Paracentesis

- Always obtain a cell count on fluid for all patient with the diagnosis: Cirrhosis

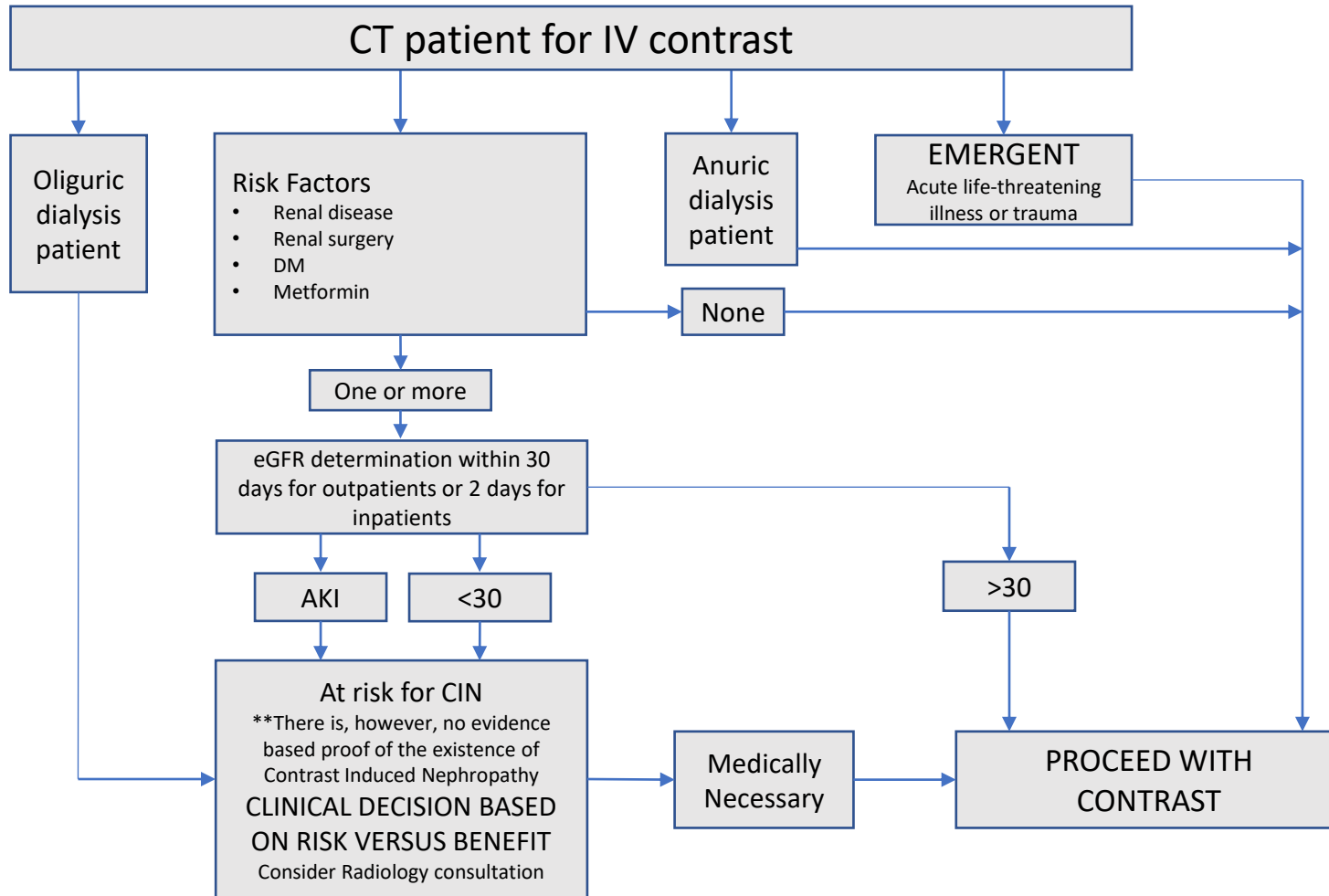
## Things to remember

- Clearly label all specimens with patient name, the area the specimen is from, and differentiate location if there are multiple sites.
- Check for orders in the chart to ensure the ordering physician hasn't ordered labs.

Reviewed by Casey Burch PA-C & Rebecca Miller PA-C 8/2018



# IV Contrast Flowchart



The 2021 ACR Manual on Contrast Media states that it is not necessary to wait 24 hours between doses of IV contrast (gadolinium or iodinated).



# MRI Contrast



Diagnostic & Preventative Imaging Center

Excerpts taken from the ACR Manual on Contrast Media 2024:

**TABLE 1. ACR Manual Classification of Gadolinium-Based Agents Relative to Nephrogenic Systemic Fibrosis**

<b>Group I: Agents associated with the greatest number of NSF cases:</b>
▪ Gadodiamide (Omniscan® – GE Healthcare)
▪ Gadopentetate dimeglumine (Magnevist® – Bayer HealthCare Pharmaceuticals)
▪ Gadoversetamide (OptiMARK® – Guerbet)
<b>Group II: Agents associated with few, if any, unconfounded cases of NSF:</b>
▪ Gadobenate dimeglumine (MultiHance® – Bracco Diagnostics)
▪ Gadobutrol (Gadavist® – Bayer HealthCare Pharmaceuticals; Gadovist in many countries)
▪ Gadoteric acid (Dotarem® – Guerbet, Clariscan – GE Healthcare)
▪ Gadoteridol (ProHance® – Bracco Diagnostics)
▪ Gadopichlenol* (Elucirem® – Guerbet, Vueway® – Bracco Diagnostics)
▪ Gadoxetate disodium (Eovist – Bayer HealthCare Pharmaceuticals; Primovist in many countries)
<b>Group III: Agents for which data remains limited regarding NSF risk, but for which few, if any unconfounded cases of NSF have been reported:</b>
▪ No agents currently in this category (as of April 2024)

Based on the most recent scientific and clinical evidence the ACR Committee on Drugs and Contrast considers the risk of NSF among patients exposed to standard or lower than standard doses of group II gadolinium-based contrast agents is sufficiently lower or possibly nonexistent such that assessment of renal function with a questionnaire or laboratory testing is **OPTIONAL** prior to intravenous administration.

As in all instances, group II GBCAs should only be administered if they are deemed necessary by the supervising radiologist, and the lowest dose needed for diagnosis should be used as deemed necessary by the supervising radiologist.

The ACR Committee on Drugs and Contrast Media recognizes that the U.S. Food and Drug Administration guidelines and drug labeling for GBCA have the same recommendations for each GBCA with respect to assessing renal function prior to GBCA administration. Nevertheless, the committee authoring the ACR Manual on Contrast Media 2024 has reviewed the evidence and believes that the prevailing weight of clinical evidence on this matter allows less stringent yet safe patient management which should reduce patient cost and inconvenience.

Given the very low, if any, risk of NSF development with group II agents, regardless of renal function or dialysis status, informed consent is **NOT** recommended prior to GBCA group II injection.

The ACR Committee on Drugs and Contrast Media and National Kidney Foundation recommend that elective GBCA-enhanced MRI examinations be performed as closely before a regularly scheduled hemodialysis as is possible, as dialysis can improve GBCM clearance. However, dialysis should not be initiated or altered.



# GBCA Workflow



MRI Contrast Patients



Group II Contrast Agents

(In use at all UPHC and Iowa Radiology facilities)



Proceed with Contrast



# Mammography

## Diagnostic Views



### Calcs Call Back

- Full Field ML + tomo
- Mag CC
- Mag ML (Mag MLO may be performed if calcs are outside field-of view on Mag ML)

### Other Call Backs

- Spot CC + tomo and/or Spot MLO + tomo – depending if seen on one or both views on the screening mammo
  - Spot XCCL + tomo may be performed instead of Spot CC, if needed
- Full Field ML + tomo
- Ultrasound if indicated

### Calcs 6-month F/U (Unilat) 1 & 2-year F/U (Bilat)

- Full Field CC + tomo
- Full Field MLO + tomo
- Mag CC
- Mag ML (Mag MLO may be performed if calcs are outside field-of view on Mag ML)

#### Pregnant Patients

- Okay to perform diagnostic

#### Lactating Patients

- Nurse or pump prior to exam

### Non-calcs 6-month F/U (Unilat) 1 & 2-year F/U (Bilat)

#### > 30 years old

- Full Field CC + tomo
- Full Field MLO + tomo
- Ultrasound if indicated

#### < 30 years old

- Ultrasound first
- Mammogram per radiologist discretion

*Continued on next page*

Reviewed by Drs. Hilpipre, Westercamp, Wolford 11/2023

\*Subject to change at the discretion of the radiologist due to clinical circumstances.\*



# Mammography – Diagnostic Views Cont.

## Pregnant Patients

- Ultrasound first
- If no definitive answer or suspicious findings on ultrasound, proceed with mammogram

## Lactating Patients

- Nurse or pump prior to exam then proceed according to age above

## Lumps/Pain

- Mark site(s)
- > 30 years old
  - Full Field CC + tomo
  - Full Field MLO + tomo
  - Lump or focal pain - Ultrasound to follow mammogram
  - Diffuse pain - Ultrasound to follow per radiologist discretion

## < 30 years old

- Ultrasound first
- Mammogram per radiologist discretion

## Pregnant Patients

- Ultrasound first
- If no definitive answer or suspicious findings on ultrasound, proceed with mammogram

## Lactating Patients

- Nurse or pump prior to exam then proceed according to age above

## Post-Biopsy

- Full Field CC + tomo
- Full Field ML + tomo (Full Field MLO + tomo may be performed if clip is outside field-of view on ML)



# Mammography Post Lumpectomy



## 1<sup>st</sup> F/U Lumpectomy:

- One diagnostic (uni or bilateral depending on timing) at 6-12 month post treatment with mag of scar --- Recommend **return to screen** if no finding.

## Going forward:

- After first diagnostic, **techs do not need to check**. If patient wants exam checked, can ask a radiologist, if not busy, or put on "Stat" list. Then watch for report and call the patient with results as a courtesy.

Note: If the current recommendation is a screening mammogram with mags, you do not need to do the mags anymore. Just do the screening images and let the patient go. If seeing the surgeon to follow, mark it Stat and put it out as review/stat. This goes to the top of the screening list to be picked up.

\*\*Patients going directly to surgeon after mammogram (Screening / F/U breast CA beyond first diagnostic exam): Put on list as "stat" and let patient go.

- Stat mammograms should be read first by screening mammo readers. Do not need to show these if screening. (All offices)



# Metformin Management



## From the ACR Manual on Contrast Media:

The management of patients taking metformin should be guided by the following:

1. Patients taking metformin are not at higher risk than other patients for post-contrast acute kidney injury.
2. Iodinated contrast is a potential concern for furthering renal damage in patients with acute kidney injury, and in patients with severe chronic kidney disease (stage IV or stage V).
3. There have been no reports of lactic acidosis following intravenous iodinated contrast medium administration in patients properly selected for metformin administration.

The Committee recommends that patients taking metformin be classified into one of two categories based on the patient's renal function (as measured by eGFR).

### Category I

In patients with no evidence of AKI and with  $\text{eGFR} \geq 30 \text{ mL} / \text{min}/1.73\text{m}^2$ , there is no need to discontinue metformin either prior to or following the intravenous administration of iodinated contrast media, nor is there an obligatory need to reassess the patient's renal function following the test or procedure.

### Category II

In patients taking metformin who are known to have acute kidney injury or severe chronic kidney disease (stage IV or stage V; i.e.,  $\text{eGFR} < 30$ ), or are undergoing arterial catheter studies that might result in emboli (atheromatous or other) to the renal arteries, metformin should be temporarily discontinued at the time of or prior to the procedure, and withheld for 48 hours subsequent to the procedure and reinstituted only after renal function has been re-evaluated and found to be normal.

### Metformin and Gadolinium

It is not necessary to discontinue metformin prior to contrast medium administration when the amount of gadolinium-based contrast material administered is in the usual dose range of 0.1 to 0.3 mmol per kg of body weight.



# MRI Brain



Diagnostic & Preventative Imaging Center

## *Without Contrast:*

1. Localizer
2. Sagittal T1 - 5 mm slice thickness; Cover whole brain ear to ear
3. Axial DWI - 5 mm slice thickness; Parallel to corpus callosum; Cover vertex to foramen magnum
4. Axial T2 - 5 mm slice thickness; Same coverage and orientation as #3
5. Axial T2\* - 5 mm slice thickness; Same coverage and orientation as #3
6. Coronal T2 - 5 mm slice thickness; Cover globes through occipital lobes
7. Sagittal 3D FLAIR - Send thin sagittal images to PACS as well as 5 mm Axial slices in same plane as #3
8. Axial 3D T1 - NO OBLIQUE; Send thin axial images to PACS

## *Without and With Contrast:*

1. Localizer
2. Sagittal T1 - 5 mm slice thickness; Cover whole brain ear to ear
3. Axial DWI - 5 mm slice thickness; Parallel to corpus callosum; Cover vertex to foramen magnum
4. Axial T2 - 5 mm slice thickness; Same coverage and orientation as #3
5. Axial T2\* - 5 mm slice thickness; Same coverage and orientation as #3
6. Coronal T2 - 5 mm slice thickness; Cover globes through occipital lobes
7. Axial T1 Fat Sat - 5 mm slice thickness; Same coverage and orientation as #3

## ***\*\*Inject contrast\*\****

8. +C Sagittal 3D FLAIR - Send thin sagittal images to PACS as well as 5 mm Axial slices in same plane as #3
9. +C Axial T1 Fat Sat - 5 mm slice thickness; Same coverage and orientation as #3
10. +C Axial 3D T1 - NO OBLIQUE; Send thin axial images to PACS

## **Notes:**

- If seizure is a listed indication, replace the Coronal T2 with 2 mm Oblique Coronal T2 through the temporal lobes.
- If exam is follow-up of a primary brain tumor (astrocytoma, oligodendroglioma, glioblastoma multiforme [GBM]), add MR Perfusion. These patients should predominantly be scheduled at sites where perfusion is available.

## Indications

Without Contrast:  
(70551)

Headaches, TIA or Stroke Symptoms, Tremors, Seizure (chronic),  
Demyelinating Disease/Multiple Sclerosis (asymptomatic follow-up)

With & Without Contrast:  
(70553)

Tumor, Infection, Seizure (new onset), Demyelinating Disease/Multiple  
Sclerosis (new evaluation or symptoms)

**\*\*Values will vary between machines. Use your own discretion when selecting values.\*\***

Reviewed by Dr. Holdsworth 10/2020



# MRI Brain Cranial Nerves



Diagnostic & Preventative Imaging Center

1. Localizer
  2. Sagittal T1 - 5 mm slice thickness; Cover whole brain ear to ear
  3. Axial DWI - 5 mm slice thickness; Parallel to corpus callosum; Cover vertex to foramen magnum
  4. Axial T2 - 5 mm slice thickness; Same coverage and orientation as #3
  5. Axial T2\* - 5 mm slice thickness; Same coverage and orientation as #3
  6. Axial T2 High Res - Cranial Nerve - See coverage below
  7. Axial T1 Thin - Cranial Nerve - 2 mm slice thickness; See coverage below
- \*\*Inject contrast\*\****
8. +C Sagittal 3D FLAIR - Send thin sagittal images to PACS as well as 5 mm Axial slices in same plane as #3
  9. +C Axial T1 Fat Sat Thin - Cranial Nerve - 2 mm slice thickness; See coverage below
  10. +C Coronal T1 Fat Sat Thin - Cranial Nerve - 2 mm slice thickness; See coverage below
  11. +C Axial 3D T1 - NO OBLIQUE; Send thin axial images to PACS

## Notes:

***\*\*Field of view for cranial nerve sequences:***

- For Hearing Loss, Tinnitus, or Dizziness/Vertigo, center coverage on the Internal Auditory Canals (IACs)
- For all other listed indications, coverage as follows:

Axial: Orbits through skull base/base of the pons

Coronal: Mid orbits through 4th ventricle/back of the brainstem

## Indications

With & Without Contrast:  
(70553)

Hearing Loss, Tinnitus, Dizziness/Vertigo, CP Angle Tumor, Facial Pain and/or Numbness, Cranial Nerve Palsy, Facial Paralysis, Bell's Palsy

***\*\*Values will vary between machines. Use your own discretion when selecting values.\*\****

Reviewed by Dr. Holdsworth 10/2020

*\*Subject to change at the discretion of the radiologist due to clinical circumstances.\**



# MRI Brain Shunt Protocol



1. Localizer
2. Axial Single Shot Fast T2 - 5 mm slice thickness
3. Coronal Single Shot Fast T2 - 5 mm slice thickness
4. Sagittal Single Shot Fast T2 - 5 mm slice thickness

**Note:**

- This exam is ONLY to evaluate for changes in ventricular size, typically in the ER or inpatient setting

## Indications

Without Contrast: Shunt Malfunction, Assess Ventricular Size  
(70551 - Reduced charge)

**\*\*Values will vary between machines. Use your own discretion when selecting values.\*\***

Reviewed by Dr. Holdsworth 10/2020

\*Subject to change at the discretion of the radiologist due to clinical circumstances.\*



# MRI Pituitary



Diagnostic & Preventative Imaging Center

1. Localizer
  2. Axial DWI - Parallel to corpus callosum; Cover vertex to foramen magnum
  3. Sagittal 3D FLAIR - Send thin sagittal images to PACS as well as 5 mm Axial slices in same plane as #2
  4. Sagittal T1 Thin - Pituitary - 2 mm slice thickness; Cover entire pituitary/sella
  5. Coronal T2 Thin - Pituitary - 2 mm slice thickness; Cover entire pituitary/sella
  6. Coronal T1 Thin - Pituitary - 2 mm slice thickness; Cover entire pituitary/sella
- \*\*Inject contrast\*\****
7. +C Coronal T1 Dynamic - Pituitary - 2 mm slice thickness; Cover entire pituitary/sella
  8. +C Sagittal T1 Thin - Pituitary - 2 mm slice thickness; Cover entire pituitary/sella

**Note:**

- If indication for exam includes additional symptoms beyond the listed indications below (i.e. headaches, altered mental status, etc.), additional whole brain sequences may be required. Check with Radiologist.
- If obvious mass or tumor is noted, include +C Axial 3D T1 whole brain.

## Indications

With & Without Contrast:  
(70553)

Pituitary Tumor, Growth Hormone Deficiency, Short Stature, Precocious Puberty, Hyperprolactinemia, Craniopharyngioma, Increased Prolactin, Galactorrhea, Amenorrhea, Micro/Macro Adenoma, Diabetes Insipidus

**\*\*Values will vary between machines. Use your own discretion when selecting values.\*\***

Reviewed by Dr. Holdsworth 10/2020

\*Subject to change at the discretion of the radiologist due to clinical circumstances.\*

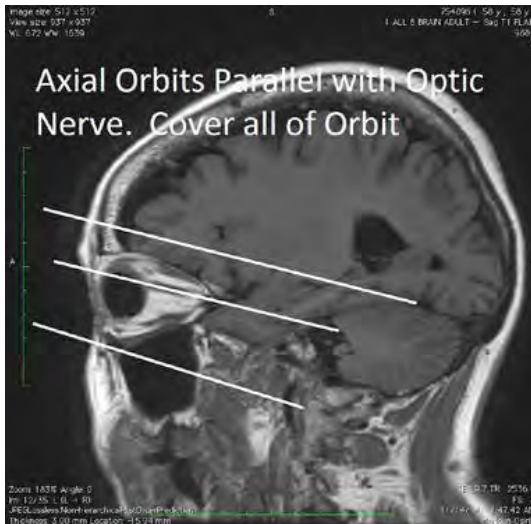

# MRI Brain and Orbits



Diagnostic & Preventative Imaging Center

1. Localizer
  2. Sagittal T1 - 5 mm slice thickness; Cover whole brain ear to ear
  3. Axial DWI - 5 mm slice thickness; Parallel to corpus callosum; Cover vertex to foramen magnum
  4. Axial T2 - 5 mm slice thickness; Same coverage and orientation as #3
  5. Axial T2\* - 5 mm slice thickness; Same coverage and orientation as #3
  6. Coronal T2 Fat Sat Thin - Orbit - 3 mm slice thickness; Cover front of globes through base of clivus
  7. Axial T2 High Res - Orbit - Cover entire orbit parallel to optic nerve (see example below)
  8. Axial T1 Fat Sat Thin - Orbit - 3 mm slice thickness; Same coverage as #7
- \*\*Inject contrast\*\****
9. +C Sagittal 3D FLAIR - Send thin sagittal images to PACS as well as 5 mm Axial slices in same plane as #3
  10. +C Axial T1 Fat Sat Thin - Orbit - 3 mm slice thickness; Same coverage as #7
  11. +C Coronal T1 Fat Sat Thin - Orbit - 3 mm slice thickness; Same coverage as #6
  12. +C Axial 3D T1 - NO OBLIQUE; Send thin axial images to PACS



\*Image courtesy University of Wisconsin

## Indications

With & Without Contrast: Vision Changes, Optic Neuritis  
(70553 & 70543)

***\*\*Values will vary between machines. Use your own discretion when selecting values.\*\****

Reviewed by Dr. Holdsworth 10/2020

\*Subject to change at the discretion of the radiologist due to clinical circumstances.\*

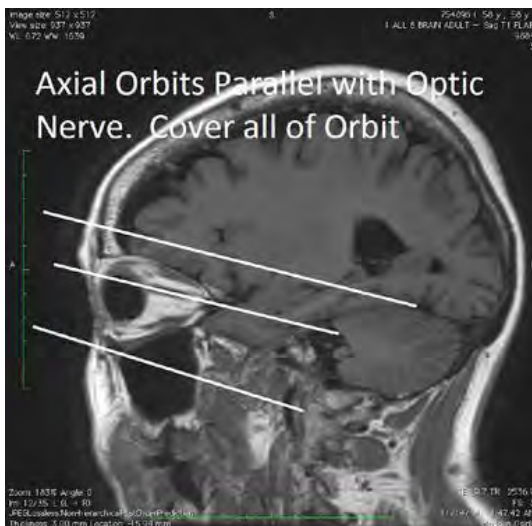


# MRI Orbits



Diagnostic & Preventative Imaging Center

1. Localizer
  2. Sagittal T1 - 3 mm slice thickness; Cover both orbits, left to right
  3. Coronal T2 Fat Sat Thin - Orbit - 3 mm slice thickness; Cover front of globes through base of clivus
  4. Axial T2 High Res - Orbit - Cover entire orbit parallel to optic nerve (see example below)
  5. Axial T1 Fat Sat Thin - Orbit - 3 mm slice thickness; Same coverage as #4
- \*\*Inject contrast\*\***
6. +C Coronal T1 Fat Sat Thin - Orbit - 3 mm slice thickness; Same coverage as #3
  7. +C Axial Fat Sat Thin - Orbit - 3 mm slice thickness; Same coverage as #4



\*Image courtesy University of Wisconsin

## Indications

With & Without Contrast: Orbital Mass/Tumor, Proptosis, Infection/Cellulitis, Grave's Disease (70543)

**\*\*Values will vary between machines. Use your own discretion when selecting values.\*\***

Reviewed by Dr. Holdsworth 10/2020

\*Subject to change at the discretion of the radiologist due to clinical circumstances.\*



# MRI TMJ

## (Temporomandibular Joint)



*Without Contrast:*

1. 3 Plane Localizer
2. Axial T1 Quick Localizer

### CLOSED JAW

- **Coronal: PARALLEL to condyles**

- |           |                    |       |          |
|-----------|--------------------|-------|----------|
| 3. LEFT:  | Coronal T1 Oblique | 3/0.2 | 9 slices |
| 4. RIGHT: | Coronal T1 Oblique | 3/0.2 | 9 slices |

- **Sagittal: MEDIAL Oblique 20° - 30° off Sagittal Plane**

- |                  |                             |       |          |
|------------------|-----------------------------|-------|----------|
| 5. LEFT & RIGHT: | Sagittal PD Oblique         | 3/0.2 | 9 slices |
| 6. LEFT & RIGHT: | Sagittal T2 Fat Sat Oblique | 3/0.2 | 9 slices |

### OPEN JAW

- |                  |                     |       |          |
|------------------|---------------------|-------|----------|
| 7. LEFT & RIGHT: | Sagittal PD Oblique | 3/0.2 | 9 slices |
|------------------|---------------------|-------|----------|

*Without and With Contrast:*

1. 3 Plane Localizer
2. Axial T1 Quick Localizer

### CLOSED JAW

- **Coronal: PARALLEL to condyles**

- |           |                    |       |          |
|-----------|--------------------|-------|----------|
| 3. LEFT:  | Coronal T1 Oblique | 3/0.2 | 9 slices |
| 4. RIGHT: | Coronal T1 Oblique | 3/0.2 | 9 slices |

- **Sagittal: MEDIAL Oblique 20° - 30° off Sagittal Plane**

- |                  |                             |       |          |
|------------------|-----------------------------|-------|----------|
| 5. LEFT & RIGHT: | Sagittal PD Oblique         | 3/0.2 | 9 slices |
| 6. LEFT & RIGHT: | Sagittal T2 Fat Sat Oblique | 3/0.2 | 9 slices |
| 7. LEFT & RIGHT: | Sagittal T1 Fat Sat Oblique | 3/0.2 | 9 slices |

### OPEN JAW

- |                  |                     |       |          |
|------------------|---------------------|-------|----------|
| 8. LEFT & RIGHT: | Sagittal PD Oblique | 3/0.2 | 9 slices |
|------------------|---------------------|-------|----------|

**\*\*Inject contrast\*\***

### CLOSED JAW

- **Coronal: PARALLEL to condyles**

- |             |                    |       |          |
|-------------|--------------------|-------|----------|
| 9. +C LEFT: | Coronal T1 Fat Sat | 3/0.2 | 9 slices |
|-------------|--------------------|-------|----------|

*Continued on next page*

Reviewed by Drs. Holdsworth, Hurlbut & Riebe 10/2023

\*Subject to change at the discretion of the radiologist due to clinical circumstances.\*



# MRI TMJ Cont.

10. +C RIGHT: Coronal T1 Fat Sat 3/0.2 9 slices

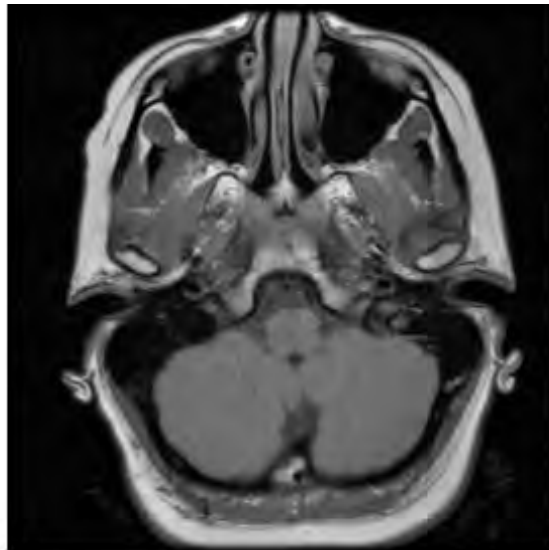
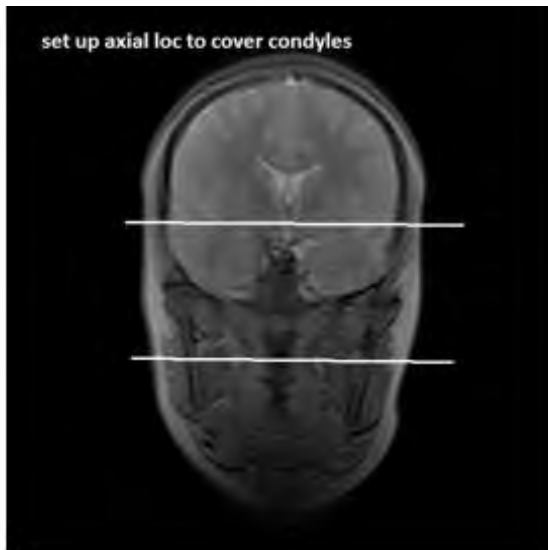• **Sagittal: MEDIAL Oblique 20° - 30° off Sagittal Plane**

11. +C LEFT & RIGHT: Sagittal T1 Fat Sat Oblique 3/0.2 9 slices

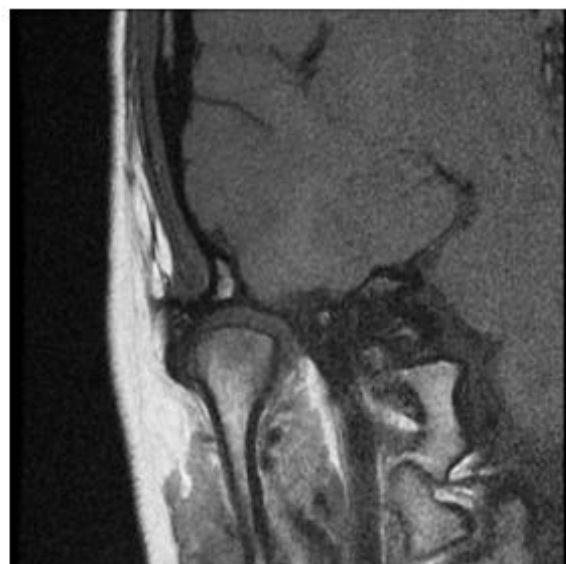
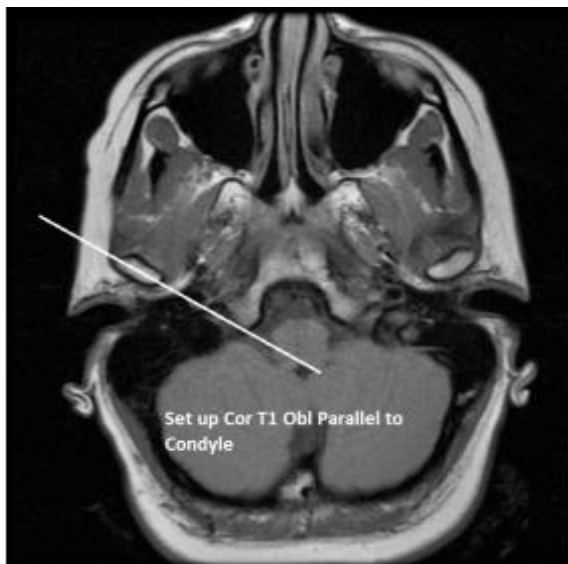
## Note:

◦The Open and Closed Oblique PDs are often the most helpful for diagnosis, so making sure those look optimal is appreciated.

**TMJ Set Up:** Set up axial loc to cover condyles



**TMJ Coronal:** Set up Cor T1 Obl Parallel to Condyle



*Continued on next page*

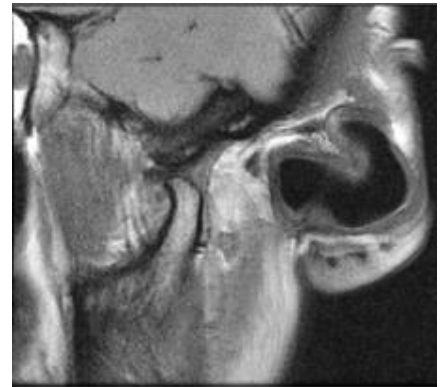
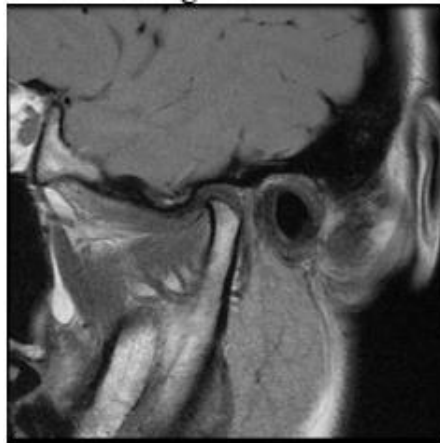
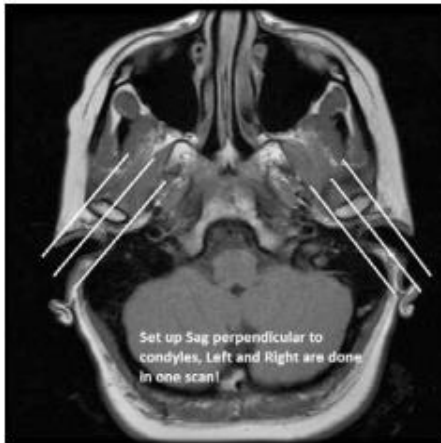
Reviewed by Drs. Holdsworth, Hurlbut & Riebe 10/2023

\*Subject to change at the discretion of the radiologist due to clinical circumstances.\*



# MRI TMJ Cont.

**TMJ Sagittal:** Set up Sag perpendicular to condyles, Left and Right are done in one scan



## Indications

Without Contrast:  
(70336)

TMJ Dysfunction or Pain, Inflammatory- or Osteo-Arthritis of TMJ, Prior TMJ Dislocation, Prior TMJ Surgery

Without & With Contrast:  
(70336)

Inflammatory Arthritis, Synovitis, Mass

**\*\*Values will vary between machines. Use your own discretion when selecting values.\*\***

Reviewed by Drs. Holdsworth, Hurlbut & Riebe 10/2023

\*Subject to change at the discretion of the radiologist due to clinical circumstances.\*



# MRI Mandible



Diagnostic & Preventative Imaging Center

1. Localizer
2. Axial T1 - 3 mm slice thickness; Cover from above temporomandibular joint through entire mandible
3. Axial T2 Fat Sat - 3 mm slice thickness; Same coverage as #2
4. Coronal T1 - 3 mm slice thickness; Include entire mandible from symphysis through temporomandibular joints
5. Coronal T1 Fat Sat - 3 mm slice thickness; Same coverage as #4
6. Coronal T2 Fat Sat - 3 mm slice thickness; Same coverage as #4
7. Sagittal T1 Oblique - 3 mm slice thickness; Angle with affected mandible
8. Sagittal T2 FS Oblique - 3 mm slice thickness; Angle with affected mandible
- \*\*Inject contrast\*\**
9. +C Axial T1 Fat Sat - 3 mm slice thickness; Same coverage as #2
10. +C Coronal T1 Fat Sat - 3 mm slice thickness; Same coverage as #4
11. +C Sagittal T1 Fat Sat Oblique - 3 mm slice thickness; Angle with affected mandible

## Indications

With & Without Contrast:                      Osteomyelitis, Mass/Tumor  
(70543)

**\*\*Values will vary between machines. Use your own discretion when selecting values.\*\***

Reviewed by Dr. Holdsworth 10/2020

\*Subject to change at the discretion of the radiologist due to clinical circumstances.\*



# MRI Soft Tissue Neck



Diagnostic & Preventative Imaging Center

1. Localizer
2. Sagittal T1 - 5 mm slice thickness; Cover skin to skin
3. Axial T1 - 5 mm slice thickness; Cover from above sella to the sternal notch
4. Axial T2 Fat Sat - 5 mm slice thickness; Same coverage as #3
5. Axial DWI - 5 mm slice thickness; Same coverage as #3
6. Coronal T2 Fat Sat - 5 mm slice thickness; Cover from lips to posterior aspect of the neck
7. Coronal T1 - 5 mm slice thickness; Same coverage as #6
8. Coronal T1 Fat Sat - 5 mm slice thickness - Same coverage as #6

***\*\*Inject contrast\*\****

9. +C Axial T1 Fat Sat - 5 mm slice thickness - Same coverage as #3
10. +C Coronal T1 Fat Sat - 5 mm slice thickness; Same coverage as #6

## **Note:**

◦Listed coverage is for most indications. Certain tumors of the nasal cavity, sinuses, or pharynx may require changes in coverage and/or additional sequences. Check with Radiologist if any questions.

## Indications

With & Without Contrast:                      Tumor/Mass, Adenopathy, Infection/Cellulitis, Salivary Gland Abnormality  
(70543)

**\*\*Values will vary between machines. Use your own discretion when selecting values.\*\***

Reviewed by Dr. Holdsworth 10/2020

\*Subject to change at the discretion of the radiologist due to clinical circumstances.\*



# MRI Brachial Plexus

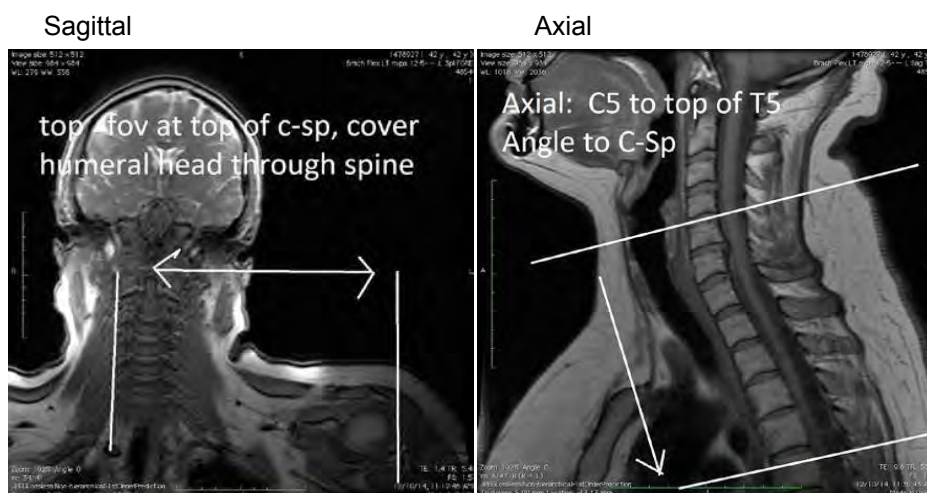


Diagnostic & Preventative Imaging Center

1. Localizer
2. Coronal T1 - 4 mm slice thickness; Cover spine through axilla from clavicle through posterior spine (see below)
3. Coronal T1 Fat Sat - 4 mm slice thickness; Same coverage as #2
4. Coronal T2 Fat Sat or Coronal STIR - 4 mm slice thickness; Same coverage as #2
5. Sagittal T1 - 4 mm slice thickness; Cover spine through humeral head (see below)
6. Axial T1 - 4 mm slice thickness; Angle with spine; Cover from above C5 to below T5 (see below)
7. Axial T2 Fat Sat - 4 mm slice thickness - Same coverage as #6

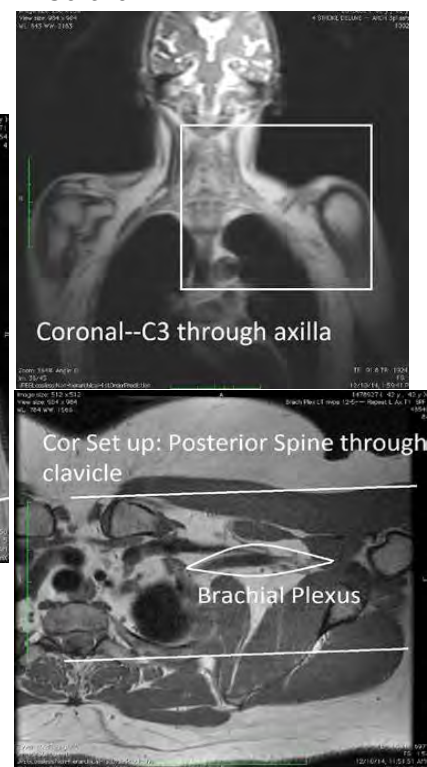**\*\*Inject contrast\*\***

8. +C Coronal T1 Fat Sat - 4 mm slice thickness; Same coverage as #2
9. +C Axial T1 Fat Sat - 4 mm slice thickness; Same coverage as #6
10. +C Sagittal T1 Fat Sat - 4 mm slice thickness; Same coverage as #5



\*Images courtesy University of Wisconsin

**Coronal**



## Indications

With & Without Contrast:  
(73220)

Brachial Plexopathy, Upper Extremity Pain or Weakness, Tumor/Mass

**\*\*Values will vary between machines. Use your own discretion when selecting values.\*\***

Reviewed by Dr. Holdsworth 10/2020

\*Subject to change at the discretion of the radiologist due to clinical circumstances.\*



# MRI C-Spine



Diagnostic & Preventative Imaging Center

1. Localizer
2. Sagittal T2 - 4 mm slice thickness; Cover spine side to side; Field of view: Skull base to T2
3. Sagittal STIR - 4 mm slice thickness; Same coverage as #2
4. Sagittal T1 - 4 mm slice thickness; Same coverage as #2
5. Axial T2 - 4 mm slice thickness; Cover C1 through T1
6. Axial T2\* - 4 mm slice thickness; Same coverage as #5
7. Axial T1 - 4 mm slice thickness; Same coverage as #5

**\*\*Inject contrast - if contrast ordered\*\***

8. +C Sagittal T1 Fat Sat - 4 mm slice thickness; Same coverage as #2
9. +C Axial T1 - 4 mm slice thickness; Same coverage as #5

## Notes:

- If Discitis/Osteomyelitis is a listed indication, include Sagittal DWI sequence.
- If Stroke/Infarction is a listed indication, include both Sagittal and Axial DWI sequences.
- If Scoliosis is present, include Coronal T2.
- If the exam is for Acute Trauma, include a non-contrast Sagittal T2 gradient.

## Indications

**\*\*A history of cervical or thoracic spine surgery DO NOT require contrast\*\***

Without Contrast: (72141)	Neck Pain, Radiculopathy, Upper Extremity Numbness, Tingling or Pain, Demyelinating Disease/Multiple Sclerosis (asymptomatic follow-up)
------------------------------	--

With & Without Contrast: (72156)	Infection, Discitis/Osteomyelitis, Tumor/Mass, Metastatic Disease, Demyelinating Disease/Multiple Sclerosis (new evaluation or symptoms)
-------------------------------------	---

**\*\*Values will vary between machines. Use your own discretion when selecting values.\*\***

Reviewed by Dr. Holdsworth 10/2020

\*Subject to change at the discretion of the radiologist due to clinical circumstances.\*



# MRI T-Spine



Diagnostic & Preventative Imaging Center

1. Localizer
2. Sagittal T2 - 4 mm slice thickness; Cover spine side to side; Field of view: C7 through L1
3. Sagittal STIR - 4 mm slice thickness; Same coverage as #2
4. Sagittal T1 - 4 mm slice thickness; Same coverage as #2
5. Axial T2 - 4 mm slice thickness; Cover T1 through L1
6. Axial T1 - 4 mm slice thickness; Same coverage as #5

***\*\*Inject contrast - if contrast ordered\*\****

8. +C Sagittal T1 Fat Sat - 4 mm slice thickness; Same coverage as #2
9. +C Axial T1 - 4 mm slice thickness; Same coverage as #5

## **Notes:**

- If Discitis/Osteomyelitis is a listed indication, include a sagittal DWI sequence.
- If Stroke/Infarction is a listed indication, include both Sagittal and Axial DWI sequences.
- If Scoliosis is present, include a non-contrast Coronal T2.
- If the exam is for Acute Trauma, include a non-contrast Sagittal T2 gradient.
- One stack of Axial images is preferred, if possible. If angled axial series is needed, only perform 2 sets of Axial T1 and T2 images.

## Indications

***\*\*A history of cervical or thoracic spine surgery DO NOT require contrast\*\****

Without Contrast: (72146)	Mid-Back Pain, Numbness or Tingling, Pain in the Upper or Lower Extremities, Demyelinating Disease/Multiple Sclerosis (routine follow up)
------------------------------	--

With & Without Contrast: (72157)	Infection, Discitis/Osteomyelitis, Tumor/Mass, Metastatic Disease, Demyelinating Disease/Multiple Sclerosis (new evaluation or symptoms)
-------------------------------------	---

***\*\*Values will vary between machines. Use your own discretion when selecting values.\*\****

Reviewed by Dr. Holdsworth 10/2020

\*Subject to change at the discretion of the radiologist due to clinical circumstances.\*



# MRI L-Spine



1. Localizer
2. Sagittal T2 - 4 mm slice thickness; Cover spine side to side; Field of view: T11 through S2/Mid-sacrum
3. Sagittal STIR - 4 mm slice thickness; Same coverage as #2
4. Sagittal T1 - 4 mm slice thickness; Same coverage as #2
5. Axial T2 - 4 mm slice thickness; Cover T12 through S1
6. Axial T1 - 4 mm slice thickness; Same coverage as #5
- \*\*Inject contrast - if contrast ordered\*\**
7. +C Sagittal T1 Fat Sat - 4 mm slice thickness; Same coverage as #2
8. +C Axial T1 - 4 mm slice thickness; Same coverage as #5

## Notes:

- If Discitis/Osteomyelitis is a listed indication, include Sagittal DWI sequence.
- If Scoliosis is present, include a non-contrast Coronal T2.
- One stack of Axial images is preferred, if possible. If angled axial series is needed, only perform 2 sets of Axial T1 and T2 images.

## Indications

Without Contrast:  
(72148)

Low back Pain, Radiculopathy, Degenerative Disc Disease, Pain Radiating to the Hips or Legs, Numbness in the Legs

With & Without Contrast:  
(72158)

History of Lumbar Surgery within 7 years (contrast not needed if patient has had another contrast enhanced MR since surgery), Infection/Discitis/Osteomyelitis, Tumor/Mass, Metastatic Disease, Guillain-Barre, Arachnoiditis

**\*\*Values will vary between machines. Use your own discretion when selecting values.\*\***

Reviewed by Dr. Holdsworth 10/2020

\*Subject to change at the discretion of the radiologist due to clinical circumstances.\*



# Neuro MRI Sequence Reference



Diagnostic & Preventative Imaging Center

## **Standard Whole Brain Sequences:**

- Axial DWI: 5mm slices. B Value = 1000. Send B0, B1000 and ADC to PACS.
- Sagittal T1: T1 weighted FSE/TSE or T1 FLAIR. 5 mm slice thickness. Send all images to PACS.
- Axial T2: T2 weighted FSE/TSE. 5 mm slice thickness. Send all images to PACS.
- Axial T2\*: T2 weighted Gradient Echo (GRE/T2\*). 5 mm slice thickness. Send all images to PACS.
- Coronal T2: T2 weighted FSE/TSE. 5 mm slice thickness. Send all images to PACS.
- Axial T1: T1 weighted FSE/TSE. 5 mm slice thickness. May be with or without Fat Saturation (will be indicated in protocol). Send all images to PACS.
- Sagittal 3D FLAIR: Volumetric 3D FLAIR FSE/TSE (SPACE[Siemens], CUBE[GE], VISTA[Philips], MVOX[Canon]). ~1 mm isotropic or near-isotropic voxels. TR ~8000. Use Fat Suppression. Straight Sagittal - NO OBLIQUES. Send thin sagittal and 5 mm Axial (in the same plane as 2D sequence) to PACS.
  - \*If MRI scanner is unable to perform 3D sequence or if significant patient motion, substitute Axial 2D FLAIR: 5 mm slices.
- Axial 3D T1: T1 weighted ultrafast GRE (MPRAGE[Siemens], BRAVO[GE], 3D TFE[Philips], FFE[Canon]). Straight Axial - NO OBLIQUES. Send thin Axial images to PACS.
  - \*If MRI scanner is unable to perform 3D sequence, substitute 5 mm slice thickness Axial, Sagittal and Coronal 2D T1 for post contrast sequences.

## **Additional Whole Brain Sequences:**

- Oblique Coronal T2: Oblique coronal T2 weighted sequence orthogonal to the temporal lobes. 2 mm slice thickness.
- Fast T2: Single Shot Fast Spin Echo/Turbo Spin Echo (HASTE[Siemens], SSFSE[GE], Single Shot TSE[Philips], FASE[Canon]). 5 mm slice thickness. For use in limited shunt eval or moving patient.
- Axial Perfusion (select sites only)

*Continued on next page*

Reviewed by Dr. Holdsworth 10/2020

\*Subject to change at the discretion of the radiologist due to clinical circumstances.\*



# Neuro MRI Sequence Reference Cont.

## Cranial Nerve Sequences:

- Axial T2 High Res: T2 weighted high spatial resolution, small field of view 3D volumetric Balanced Steady State Free Precession (CISS[Siemens], FIESTA[GE], Balanced FFE[Philips], True SSFP[Canon]) **OR** FSE/TSE (SPACE[Siemens], CUBE[GE], VISTA[Philips], MVOX[Canon]). Check protocol for field of view. Send thin images to PACS.
- Axial T1: T1 weighted FSE/TSE sequence through the cranial nerves. 2 mm slice thickness. May be with or without Fat Saturation (will be indicated in protocol). Check protocol for field of view. Send all images to PACS.
- Coronal T1: T1 weighted FSE/TSE sequence through the cranial nerves. 2 mm slice thickness. May be with or without Fat Saturation (will be indicated in protocol). Check protocol for field of view. Send all images to PACS.

## Pituitary Sequences:

- Sagittal T1 thin: Sagittal T1 weighted small field of view FSE/TSE sequence through the pituitary. 2 mm slice thickness. Send all images to PACS.
- Coronal T2 thin: Coronal T2 weighted small field of view FSE/TSE sequence through the pituitary. 2 mm slice thickness. Send all images to PACS.
- Coronal T1 thin: Coronal T1 weighted small field of view FSE/TSE sequence through the pituitary. 2 mm slice thickness. Send all images to PACS.
- Coronal T1 dynamic: Multiphase T1 weighted coronal imaging through the pituitary during and after contrast injection. 2 mm slice thickness. ~12 phases. Send all images to PACS as 1 series.

## Orbit Sequences:

- Coronal T2: T2 weighted FSE/TSE sequence through the orbits. 3 mm slice thickness. Fat suppressed. Send all images to PACS.
- Axial T2 High Res: T2 weighted high spatial resolution, small field of view 3D volumetric Balanced Steady State Free Precession (CISS[Siemens], FIESTA[GE], Balanced FFE[Philips], True SSFP[Canon]) **OR** FSE/TSE (SPACE[Siemens], CUBE[GE], VISTA[Philips], MVOX[Canon]). Send thin images to PACS.
- Axial T1: T1 weighted FSE/TSE sequence through the orbits. 3 mm slice thickness. Fat suppressed. Send all images to PACS.
- Coronal T1: T1 weighted FSE/TSE sequence through the orbits. 3 mm slice thickness. Fat suppressed. Send all images to PACS.



# MRA Head



Diagnostic & Preventative Imaging Center

1. Localizer
2. Axial 3D Time of Flight (TOF) MRA - Send raw data and multiplanar MIPS to PACS
- \*\*Inject contrast - if contrast ordered\*\**
3. Axial 3D Time of Flight (TOF) MRA

**Notes:**

- Almost always without contrast. Include contrast if history of prior intracranial arterial stent placement

## Indications

Without Contrast:                      Stroke/TIA, Stenosis, Aneurysm  
(70544)

**\*\*Values will vary between machines. Use your own discretion when selecting values.\*\***

Reviewed by Dr. Holdsworth 10/2020

\*Subject to change at the discretion of the radiologist due to clinical circumstances.\*







# MRV Head



Diagnostic & Preventative Imaging Center

1. Localizer
2. 3D Phase Contrast (PC) MRV  
*\*\*Inject contrast - if contrast ordered\*\**
3. +C 3D Phase Contrast (PC) MRV

**Notes:**

- Without contrast most common.
- May substitute Time of Flight (TOF) MRV if scanner not able to perform 3D phase contrast.

## Indications

Without Contrast: Headache, Venous Sinus Thrombosis, Idiopathic Intracranial Hypertension  
(70554)

**\*\*Values will vary between machines. Use your own discretion when selecting values.\*\***

Reviewed by Dr. Holdsworth 10/2020

\*Subject to change at the discretion of the radiologist due to clinical circumstances.\*



# MRI Shoulder



Sequence	Plane	FOV	Thickness	Gap	NSA	F/S	PE x RO Matrix	TI	TR	TE	Comments
Axial LOC	Ax	50 x 50	6.0	1.5	1	-	128 X 256	-	190	9	
3 Plane LOC	-	25 x 25	5.0	0.5	1	-	128 x 256	-	119	9	
Shim	-	18 x 18	5.0	3.0	1	-	64 x 64	-	200	4-8	
PD FS Axial	Ax	15 x 15	3.0	0.3	1	Light	224 x 288	-	2300	36	No Speeder Coil
TS FS Coronal	Cor	14 x 14	3.0	0.3	1	Light	224 x 320	-	3400	60	No Speeder Coil
T1 Sagittal	Sag	15 x 15	3.0	0.3	1	-	224 x 256	-	475	12	Speeder 1.3
T2 FS Sagittal	Sag	15 x 15	3.0	0.3	2	Light	192 x 288	-	3450	60	Speeder 1.3
T2 FS Oblique/Sagittal	Obl	15 x 15	3.0	0.3	2	Light	224 x 288	-	3400	60	Speeder 1.3

## Indications

Without Contrast: Pain, Injury, Instability and Limited Range of Motion, Arthritis

With & Without Contrast: Bone and Soft Tissue Masses, Infection of the Bone and Soft Tissue

**\*\*Matrix/TR/TE values will vary between machines. Use your own discretion when selecting these values\*\***

Reviewed by Dr. Choi 4/2016

\*Subject to change at the discretion of the radiologist due to clinical circumstances.\*



# MRI Shoulder Arthrogram



Diagnostic & Preventative Imaging Center

Sequence	Plane	FOV	Thickness	Gap	NSA	F/S	PE x RO Matrix	TI	TR	TE	Comments
3 Plane LOC	-	45 x 45	5.0	0.5	1	-	128 x 256	-	119	9	Large FOV
3 Plane LOC	-	25 x 25	5.0	0.5	1	-	128 x 256	-	119	9	
Shim	-	18 x 18	5.0	3.0	1	-	64 x 64	-	200	4.8	
T1 FS Axial	Ax	15 x 15	3.0	0.3	2	Light	224 x 288	-	590	12	Speeder 1.5
T2 FS Coronal	Cor	15 x 15	3.0	0.3	1	Light	224 x 320	-	3400	60	No Speeder Coil
T1 FS Coronal	Cor	15 x 15	3.0	0.3	1	Light	224 x 288	-	560	12	Speeder 1.5
T1 FS Sagittal	Sag	15 x 15	3.0	0.3	1	Light	224 x 256	-	560	12	Speeder 1.3
<i>Optional (Ask Rad)</i>											Full-thickness Cuff Tear
T2 Sagittal	Sag	15 x 15	3.0	0.3	2		192 x 288	-	3450	60	Speeder 1.3
3 Plane LOC	-	32 x 32	5.0	0.5	1.5	-	192 x 256	-	360	9	Large FOV
Aber LOC	Obl	25 x 25	5.0	0.5	1	-	192 x 256	-	427	60	
Shim	-	18 x 18	5.0	5.0	1	-	64 x 64	-	200	4.8	
T1 FS Aber	Obl	18 x 18	3.0	0.5	2	Light	192 x 256	-	510	10	No Speeder Coil
<i>Optional</i>											
Sagittal T2	Sag	15 x 15	3.0	0.3	2	-	192 x 288	-	3450	60	For RTC Surgery
Axial T1	Ax	15 x 15	3.0	0.3	1	-	224 x 288	-	415	12	For Labral Surgery

## Indications

With Contrast:

Shoulder Pain, Labral Tear, Popping, Clicking, Decreased Range of Motion, Pain

**\*\*Matrix/TR/TE values will vary between machines. Use your own discretion when selecting these values\*\***

Reviewed by Dr. Choi 11/2016

\*Subject to change at the discretion of the radiologist due to clinical circumstances.\*



# MRI

## Humerus



Diagnostic & Preventative Imaging Center

Sequence	Plane	FOV	Thickness	Gap	NSA	F/S	PE x RO Matrix	TI	TR	TE	Comments
3 Axis Lg LOC	-	42 x 42	5.0	0.5	1	-	128 x 256	-	119	9	
3 Plane LOC	-	19 x 30	5.0	1.0	1	-	144 x 256	-	360	9	
Map	-	23 x 23	6.0	10.0	1	-	64 x 64	-	184	4	
T1 Axial	Ax	16 x 15	6.0	1.5	2	-	224 x 320	-	540	10	
T2 FS Axial	Ax	16 x 15	6.0	1.5	3	Light	192 x 256	-	6300	60	
Shim	-	17 x 17	5.0	16.0	2	-	32 x 32	-	200	4.8/9	
T2 FS Coronal	Cor	26 x 15	3.0	1.0	1	Light	192 x 288	-	4550	60	
T1 Coronal	Cor	26 x 15	3.0	1.0	1	-	192 x 288	-	595	10	
PD FS Sagittal	Sag	14 x 27	3.0	1.0	1	Light	192 x 256	-	3000	30	May need to be T2 FS Cor
T1 Sagittal	Sag	14 x 27	3.0	1.0	2	-	192 x 288	-	490	10	
<i>Optional</i>											
STIR Coronal	Cor	26 x 15	3.0	1.0	1	-	192 x 256	145	4400	60	

## Indications

Without Contrast: Pain, Injury, Instability and Limited Range of Motion, Arthritis

With Contrast: Bone and Soft Tissue Masses, Infection of the Bone and Soft Tissue

**\*\*Matrix/TR/TE values will vary between machines. Use your own discretion when selecting these values\*\***

Reviewed by Dr. Choi 4/2016

\*Subject to change at the discretion of the radiologist due to clinical circumstances.\*



# MRI Elbow



Sequence	Plane	FOV	Thickness	Gap	NSA	F/S	PE x RO Matrix	TI	TR	TE	Comments
Axial LOC	Ax	50 x 50	6.0	1.0	1	-	128 x 256	-	290	9	
3 Plane LOC	-	18 x 18	5.0	0.5	1	-	144 x 256	-	360	9	
Map	-	23 x 23	6.0	4.0	1	-	64 x 64	-	184	4	
T1 Axial	Ax	14 x 14	3.0	0.5	3	-	224 x 320	-	595	10	
Shim	-	12 x 12	5.0	2.0	2	-	32 x 32	-	200	4.8	
T2 FS Axial	Ax	14 x 14	3.0	0.5	4	Light	192 x 256	-	3650	60	
T1 Coronal	Cor	14 x 14	3.0	0.5	2	-	224 x 288	-	485	10	
T2 FS Coronal	Cor	14 x 14	3.0	0.5	2	Light	224 x 320	-	3000	60	
PD FS Sagittal	Sag	14 x 14	3.0	0.5	2	Light	192 x 256	-	2600	30	
T1 Sagittal	Sag	14 x 14	3.0	0.5	2	-	224 x 288	-	650	10	

## Indications

Without Contrast: Pain, Injury, Instability and Limited Range of Motion, Arthritis

With & Without Contrast: Bone and Soft Tissue Masses, Infection of the Bone and Soft Tissue

**\*\*Matrix/TR/TE values will vary between machines. Use your own discretion when selecting these values\*\***

Reviewed by Dr. Choi 4/2016

\*Subject to change at the discretion of the radiologist due to clinical circumstances.\*



# MRI Elbow Arthrogram



Sequence	Plane	FOV	Thickness	Gap	NSA	F/S	PE x RO Matrix	TI	TR	TE	Comments
Axial LOC	Ax	50 x 50	6.0	1.0	1	-	128 x 256	-	290	9	
3 Plane LOC	-	18 x 18	5.0	1.0	1	-	144 x 256	-	360	9	
Map	-	14 x 14	6.0	0.0	1	-	32 x 64	-	184	4	
Shim	-	14 x 14	5	2	2	-	32 x 32	-	200	4.8	
T1 FS Axial	Ax	14 x 14	3.0	0.5	3	Light	224 x 320	-	570	10	
T1 FS Coronal	Cor	14 x 14	3.0	0.5	2	Light	224 x 288	-	555	10	
T1 FS Sagittal	Sag	14 x 14	3.0	0.5	3	Light	224 x 288	-	430	10	
T2 FS Axial	Ax	14 x 14	3.0	0.5	4	Light	192 x 256	-	5300	108	
PD FS Coronal	Cor	14 x 14	3.0	0.5	2	Light	192 x 256	-	3333	30	
<i>Optional</i>											
T1 Sagittal	Sag	14 x 14	3.0	0.5	3	-	224 x 288	-	540	10	
T1 Coronal	Cor	14 x 14	3.0	0.5	2	-	224 x 288	-	600	10	

## Indications

With Contrast:

Ligament Tears

**\*\*Matrix/TR/TE values will vary between machines. Use your own discretion when selecting these values\*\***

Reviewed by Dr. Choi 11/2016

\*Subject to change at the discretion of the radiologist due to clinical circumstances.\*



# MRI Wrist



Diagnostic & Preventative Imaging Center

Sequence	Plane	FOV	Thickness	Gap	NSA	F/S	PE x RO Matrix	TI	TR	TE	Comments
Axial LOC	Ax	50 x 50	6.0	1.0	1	-	128 x 256	-	360	9	
3 Plane LOC	-	18 x 18	5.0	1.0	1	-	128 x 256	-	360	9	
Map	-	13 x 13	6.0	1.0	1	-	64 x 64	-	185	4	
Shim	-	28 x 28	5.0	5.0	1	-	64 x 64	-	200	4.8	
PD FS Axial	Ax	11 x 11	3.0	0.5	1	Light	224 x 256	-	3200	24	
T1 Axial	Ax	11 x 11	3.0	0.5	3	-	224 x 320	-	575	12	
PD FS Coronal	Cor	11 x 11	3.0	0.5	3	Light	224 x 324	-	3000	30	
T1 Coronal	Cor	11 x 11	3.0	0.5	3	-	224 x 320	-	580	12	
T2 FS Sagittal	Sag	11 x 11	3.0	0.5	2	Light	224 x 320	-	3150	60	
T1 Sagittal	Sag	11 x 11	3	0.5	1	-	256 x 352	-	440	12	
3D FE Coronal	Cor	12 x 12	1.0	0.0	1	-	256 x 256	-	45	15	Cartilage Series
<i>Optional</i>											
T1 FS Axial Post	Ax	12 x 12	3.0	0.5	2	Light	192 x 256	-	720	12	
T1 FS Coronal Post	Cor	12 x 12.5	3.0	0.5	2	Light	192 x 320	-	680	12	
T1 FS Sagittal Post	Sag	12 x 12	3.0	0.5	2	Light	192 x 320	-	680	12	

## Indications

Without Contrast: Pain, Injury, Instability and Limited Range of Motion, Arthritis

With & Without Contrast: Bone and Soft Tissue Masses, Infection of the Bone and Soft Tissue

**\*\*Matrix/TR/TE values will vary between machines. Use your own discretion when selecting these values\*\***

Reviewed by Dr. Choi 11/2016

\*Subject to change at the discretion of the radiologist due to clinical circumstances.\*



# MRI Wrist Arthrogram



Sequence	Plane	FOV	Thickness	Gap	NSA	F/S	PE x RO Matrix	TI	TR	TE	Comments
Axial LOC	Ax	50 x 50	6.0	1.0	1	-	128 x 256	-	360	9	
3 Plane LOC	-	18 x 18	5.0	1.0	1	-	128 x 256	-	360	9	
Map	-	13 x 13	6.0	1.0	1	-	64 x 64	-	185	4	
Shim	-	11 x 11	5.0	3.0	2	-	32 x 32	-	200	4.8	
T2 FS Axial	Ax	12 x 12	3.0	0.5	3	Light	192 x 256	-	3000	60	
T1 FS Axial	Ax	12 x 12	3.0	0.5	2	Light	192 x 256	-	645	10	
T1 FS Coronal	Cor	12 x 12	2.5	0.5	2	Light	192 x 256	-	745	12	
PD FS Coronal	Cor	12 x 12	2.5	0.5	3	Light	192 x 256	-	3000	30	
T1 FS Sagittal	Sag	12 x 12	2.5	0.5	2	Light	192 x 256	-	735	12	
3D FE Coronal	Cor	12 x 12	1.0	0.0	1	-	256 x 256	-	45	15	Cartilage Series

## Indications

With Contrast: TFCC Tear, Ligament Tears

**\*\*Matrix/TR/TE values will vary between machines. Use your own discretion when selecting these values\*\***

Reviewed by Dr. Choi 11/2016

\*Subject to change at the discretion of the radiologist due to clinical circumstances.\*



# MRI Hand



Diagnostic & Preventative Imaging Center

Sequence	Plane	FOV	Thickness	Gap	NSA	F/S	PE x RO Matrix	TI	TR	TE	Comments
Axial LOC	Ax	50 x 50	6.0	1.0	1	-	128 x 256	-	360	9	
3 Plane LOC	-	24 x 24	5.0	1.0	1	-	128 x 256	-	360	9	
Map	-	18 x 21	6.0	5.0	1	-	64 x 64	-	185	4	
Shim	-	14 x 14	5.0	8.0	2	-	32 x 32	-	200	4.8	
T2 FS Axial	Ax	12 x 12	3.0	0.5	4	Light	192 x 256	-	4953	60	
T1 Axial	Ax	12 x 12	3.0	0.5	3	-	256 x 288	-	515	12	
T1 Coronal	Cor	14 x 14	2.5	0.5	2	-	192 x 256	-	580	12	
STIR Coronal	Cor	14 x 14	2.5	0.5	1	-	192 x 256	130	4101	48	
T2 FS Sagittal	Sag	13 x 13	2.5	0.5	4	Light	192 x 256	-	4953	60	
T1 Sagittal	Sag	13 x 13	2.5	0.5	2	-	192 x 256	-	520	12	
<i>Optional</i>											
3D FE Coronal	Cor	14 x 14	1.0	0.0	1	-	256 x 256	-	45	15	Cartilage Series
PD FS Sagittal	Sag	13 x 13	2.5	0.5	2	Light	192 x 256	-	2350	30	

## Indications

Without Contrast: Pain, Injury, Instability and Limited Range of Motion, Arthritis

With & Without Contrast: Bone and Soft Tissue Masses, Infection of the Bone and Soft Tissue

**\*\*Matrix/TR/TE values will vary between machines. Use your own discretion when selecting these values\*\***

Reviewed by Dr. Choi 4/2016

\*Subject to change at the discretion of the radiologist due to clinical circumstances.\*



# MRI Sacrum /SI Joints



Diagnostic & Preventative Imaging Center

Sequence	Plane	FOV	Thickness	Gap	NSA	F/S	PE x RO Matrix	TI	TR	TE	Comments
Sagittal LOC	Sag	50 x 50	5.0	1.0	1	-	128 x 256	-	265	9	
Coronal LOC	Cor	45 x 45	5.0	1.0	1	-	128 x 256	-	285	9	
Map	-	40 x 60	6.0	10.0	1	-	64 x 64	-	235	4	
T1 Coronal	Cor	28 x 28	5.0	1.0	2	-	256 x 352	-	495	10	
STIR Coronal	Cor	28 x 28	5.0	1.0	2	-	224 x 256	150	5526	84	
T1 Axial	Ax	30 x 15	5.0	1.0	1	-	224 x 512	-	615	15	
T2 FS Axial	Ax	30 x 15	5.0	1.0	2	Light	256 x 352	-	4850	90	
T2 FS Sagittal	Sag	26 x 24	5.0	1.0	2	Light	192 x 304	-	4621	90	

## Indications

Without Contrast: Pain, Injury

**\*\*Matrix/TR/TE values will vary between machines. Use your own discretion when selecting these values\*\***

Reviewed by Dr. Choi 4/2016

\*Subject to change at the discretion of the radiologist due to clinical circumstances.\*



# MRI Bony Pelvis / Hip

(Over 65 y/o)



Sequence	Plane	FOV	Thickness	Gap	NSA	F/S	PE x RO Matrix	TI	TR	TE	Comments
3 Plane LOC	-	45 x 45	7.0	0.0	1	-	128 x 256	-	45	5	
Map	-	50 x 55	6.0	14.0	1	-	32 x 64	-	185	4	
STIR Coronal (Bilat)	Cor	37 x 32	5.0	1.0	2	-	192 x 256	135	6023	48	Entire Pelvis
T1 Coronal (Bilat)	Cor	37 x 32	5.0	1.0	1	-	256 x 320	-	777	10	Entire Pelvis
Shim	-	28 x 28	5.0	5.0	1	-	64 x 64	-	200	4.8	
T2 FS Axial	Ax	35 x 35	5.0	1.0	1	Light	192 x 256	-	4700	60	Entire Pelvis
T1 Axial	Ax	35 x 35	5.0	1.0	1	-	192 x 256	-	650	10	Entire Pelvis
PD FS Sagittal	Sag	20 x 20	4.0	0.5	1	Light	224 x 288	-	2555	36	Cover Joint
<i>Optional</i>											
T1 Sagittal	Sag	20 x 20	4.0	0.5	1	-	192 x 256	-	480	12	Cover Joint
T1 Axial	Ax	24 x 24	4.0	0.5	2	-	256 x 320	-	777	10	Cover Joint
T1 Coronal	Cor	20 x 20	4.0	0.5	2	-	256 x 256	-	410	10	Cover Joint
<i>Optional Contrast</i>											
T1 FS Coronal Post	Cor	35 x 35	5.0	1.0	2	Light	192 x 256	-	625	10	Entire Pelvis
T1 FS Axial Post	Ax	35 x 35	5.0	1.0	2	Light	192 x 256	-	560	10	Entire Pelvis
T1 FS Sagittal Post	Sag	35 x 35	5.0	1.0	2	Light	192 x 256	-	560	10	Entire Pelvis

## Indications

Without Contrast: Evaluate for Fracture, Pain, Injury, Instability and Limited Range of Motion, Arthritis

With & Without Contrast: Bone and Soft Tissue Masses, Infection of the Bone and Soft Tissue

**\*\*Matrix/TR/TE values will vary between machines. Use your own discretion when selecting these values\*\***

Reviewed by Dr. Choi 11/2017



# MRI Bony Pelvis / Hip

(65 y/o & Younger)



Sequence	Plane	FOV	Thickness	Gap	NSA	F/S	PE x RO Matrix	TI	TR	TE	Comments
3 Plane LOC	-	45 x 45	7.0	0.0	1	-	128 x 256	-	45	5	
Map	-	50 x 55	6.0	14.0	1	-	32 x 64	-	185	4	
STIR Coronal (Bilat)	Cor	37 x 32	5.0	1.0	2	-	192 x 256	135	6023	48	Entire Pelvis
T1 Coronal (Bilat)	Cor	37 x 32	5.0	1.0	1	-	256 x 320	-	777	10	Entire Pelvis
Shim	-	28 x 28	5.0	5.0	1	-	64 x 64	-	200	4.8	
T2 FS Axial	Ax	24 x 24	4.0	0.5	3	Light	192 x 256	-	4656	60	ASIS thru Symphysis
T2 FS Coronal	Cor	20 x 20	4.0	0.5	2	Light	224 x 288	-	5796	60	
PD FS Sagittal	Sag	20 x 20	4.0	0.5	1	Light	224 x 288	-	2555	36	\ Include
T1 Sagittal	Sag	20 x 20	4.0	0.5	1	-	192 x 256	-	480	12	/ Symphysis
T1 Axial	Ax	24 x 24	4.0	0.5	2	-	256 x 320	-	777	10	ASIS thru Symphysis
T1 Coronal	Cor	20 x 20	4.0	0.5	2	-	256 x 256	-	410	10	
<i>Optional Contrast</i>											
T1 FS Coronal Post	Cor	20 x 20	4.0	0.5	2	Light	192 x 256	-	625	10	
T1 FS Axial Post	Ax	24 x 24	4.0	0.5	2	Light	192 x 256	-	560	10	ASIS thru Symphysis

## Indications

Without Contrast: Pain, Injury, Instability and Limited Range of Motion, Arthritis

With & Without Contrast: Bone and Soft Tissue Masses, Infection of the Bone and Soft Tissue

**\*\*Matrix/TR/TE values will vary between machines. Use your own discretion when selecting these values\*\***

Reviewed by Dr. Choi 11/2017



# MRI Hip Arthrogram



Diagnostic & Preventative Imaging Center

Sequence	Plane	FOV	Thickness	Gap	NSA	F/S	PE x RO Matrix	TI	TR	TE	Comments
3 Plane LOC	-	45 x 45	7.0	0.0	1	-	128 x 256	-	45	5	
Map	-	50 x 65	6.0	14.0	1	-	32 x 64	-	185	4	
T1 Axial	Ax	20 x 20	4.0	0.4	2	-	256 x 384	-	475	10	
Shim	-	22 x 22	5.0	5.0	1	-	64 x 64	-	200	4.8	
T1 FS Coronal	Cor	20 x 20	4.0	0.4	2	Light	192 x 256	-	615	10	
T2 FS Coronal	Cor	20 x 20	4.0	0.4	3	Light	192 x 256	-	4000	60	
T1 FS Sagittal	Sag	20 x 20	4.0	0.4	2	Light	192 x 256	-	460	10	
T1 FS Parallel	Obl	20 x 20	4.0	0.4	2	Light	224 x 256	-	510	10	Parallel to Neck
<i>Optional</i>											
T1 FS Perpendicular	Obl	20 x 20	4.0	0.4	2	Light	192 x 256	-	460	10	Perpendicular To Neck

## Indications

With Contrast:

Pain, Decreased Range of Motion, Tears, Groin Pain, Catching, Evaluate for labral tear

**\*\*Matrix/TR/TE values will vary between machines. Use your own discretion when selecting these values\*\***

Reviewed by Dr. Choi 11/2022

\*Subject to change at the discretion of the radiologist due to clinical circumstances.\*



# MRI Femur



Diagnostic & Preventative Imaging Center

Sequence	Plane	FOV	Thickness	Gap	NSA	F/S	PE x RO Matrix	TI	TR	TE	Comments
Coronal LOC	Cor	28 x 50	6.0	2.0	1	-	128 x 256	-	2000	15	
3 Plane LOC	-	28 x 50	6.0	2.0	1	-	128 x 256	-	190	9	
Map	-	50 x 55	6.0	16.0	1	-	32 x 64	-	185	4	
T1 Sagittal	Sag	17 x 47	5.0	1.0	1	-	224 x 320	-	400	12	
Shim	-	21 x 21	5.0	23.0	1	-	64 x 64	-	200	4.8	
STIR Coronal	Cor	47 x 21	5.0	1.0	1	-	192 x 256	-	3250	60	
T2 FS Sagittal	Sag	17 x 47	5.0	1.0	1	Light	192 x 256	-	3250	60	
T2 FS Axial	Ax	16 x 18	6.0	2.0	2	Light	224 x 256	-	7100	60	
T1 Axial	Ax	16 x 18	6.0	2.0	1	-	256 x 336	-	580	12	
T1 Coronal	Cor	47 x 21	5.0	1.0	1	-	192 x 256	-	630	10	
<i>Optional</i>											
STIR Sagittal	Sag	17 x 47	5.0	1.0	1	-	192 x 256	140	6409	60	
<i>Optional Contrast</i>											
T1 FS Coronal Post	Cor	47 x 21	5.0	1.0	1	Light	192 x 256	-	620	10	
T1 FS Sagittal Post	Sag	17 x 47	5.0	1.0	1	Light	192 x 256	-	700	10	
T1 FS Axial Post	Ax	16 x 18	6.0	2.0	1	Light	192 x 256	-	560	10	

## Indications

Without Contrast: Pain, Injury, Instability and Limited Range of Motion, Arthritis

With & Without Contrast: Bone and Soft Tissue Masses, Infection of the Bone and Soft Tissue

**\*\*Matrix/TR/TE values will vary between machines. Use your own discretion when selecting these values\*\***

Reviewed by Dr. Choi 11/2016

\*Subject to change at the discretion of the radiologist due to clinical circumstances.\*



# MRI Knee



Sequence	Plane	FOV	Thickness	Gap	NSA	F/S	PE x RO Matrix	TI	TR	TE	Comments
Coronal LOC	Cor	50 x 50	5.0	1.0	1	-	128 x 256	-	356	9	
3 Plane LOC	-	50 x 50	5.0	1.0	1	-	128 x 256	-	356	9	
Shim	-	20 x 20	5.0	5.0	1	-	64 x 64	-	200	4.8	
PD FS Axial	Ax	15 x 16	3.5	0.5	1	Light	224 x 256	-	2900	30	
PD Sagittal	Sag	15 x 15	3.5	0.3	1	-	256 x 320	-	1728	24	
T2 FS Sagittal	Sag	15 x 15	3.5	0.3	1	Light	256 x 320	-	3850	60	
PD FS Coronal	Cor	15 x 15	3.5	0.5	1	Light	224 x 256	-	3000	24	
T1 Coronal	Cor	15 x 15	3.5	0.5	1	-	256 x 320	-	485	10	
Sagittal Oblique ACL	Obl	16 x 16	3.0	0.5	1	Light	224 x 256	-	3400	60	

## Indications

Without Contrast: Pain, Injury, Instability and Limited Range of Motion, Arthritis

With & Without Contrast: Bone and Soft Tissue Masses, Infection of the Bone and Soft Tissue

**\*\*Matrix/TR/TE values will vary between machines. Use your own discretion when selecting these values\*\***

Reviewed by Dr. Choi 4/2016

\*Subject to change at the discretion of the radiologist due to clinical circumstances.\*



# MRI Knee Arthrogram



Diagnostic & Preventative Imaging Center

Sequence	Plane	FOV	Thickness	Gap	NSA	F/S	PE x RO Matrix	TI	TR	TE	Comments
LOCS											
T2 FS Axial	Ax	17 x 17	3.5	0.5	2	-	192 x 288	-	4800	60	
PD Sagittal	Sag	16 x 16	3.0	0.3	1	-	256 x 320	-	2514	30	
T1 FS Coronal	Cor	16 x 16	3.0	0.5	1	-	224 x 256	-	500	10	
T2 FS Sagittal	Sag	16 x 16	3.0	0.3	1	-	256 x 288	-	3304	48	
T1 FS Sagittal	Sag	16 x 16	3.0	0.3	1	-	256 x 320	-	450	10	

## Indications

With Contrast:

Ligament Tears

**\*\*Matrix/TR/TE values will vary between machines. Use your own discretion when selecting these values\*\***

Reviewed by Dr. Choi 11/2016

\*Subject to change at the discretion of the radiologist due to clinical circumstances.\*



# MRI Tib/Fib



Sequence	Plane	FOV	Thickness	Gap	NSA	F/S	PE x RO Matrix	TI	TR	TE	Comments
Coronal LOC	Cor	28 x 50	6.0	2.0	1	-	128 x 256	-	2000	15	
3 Plane LOC	-	28 x 50	6.0	2.0	1	-	128 x 256	-	190	9	
Map	-	50 x 55	6.0	16.0	1	-	32 x 64	-	185	4	
T1 Sagittal	Sag	14 x 40	5.0	1.0	1	-	224 x 320	-	400	12	
T2 FS Sagittal	Sag	14 x 40	5.0	1.0	1	Light	192 x 256	140	6409	60	
Shim	-	21 x 21	5.0	23.0	1	-	64 x 64	-	200	4.8	
T1 Coronal	Cor	40 x 14	5.0	1.0	1	-	192 x 256	-	630	10	
STIR Coronal	Cor	40 x 14	5.0	1.0	1	-	192 x 256	140	6409	60	
T2 FS Axial	Ax	15 x 15	6.0	2.0	2	Light	224 x 256	-	7100	60	
T1 Axial	Ax	15 x 15	6.0	2.0	1	-	256 x 336	-	580	12	
<i>Optional Contrast</i>											
T1 FS Coronal Post	Cor	40 x 14	5.0	1.0	1	Light	192 x 256	-	620	10	
T1 FS Sagittal Post	Sag	14 x 40	5.0	1.0	1	Light	192 x 256	-	700	10	
T1 FS Axial Post	Ax	15 x 15	6.0	2.0	1	Light	192 x 256	-	560	10	

## Indications

Without Contrast: Pain, Injury, Instability and Limited Range of Motion, Arthritis, Evaluate for Stress Fracture, Running Injury

With & Without Contrast: Bone and Soft Tissue Masses, Infection of the Bone and Soft Tissue

**\*\*Matrix/TR/TE values will vary between machines. Use your own discretion when selecting these values\*\***

Reviewed by Dr. Choi 11/2016

\*Subject to change at the discretion of the radiologist due to clinical circumstances.\*



# MRI

## Ankle/Hindfoot



Sequence	Plane	FOV	Thickness	Gap	NSA	F/S	PE x RO Matrix	TI	TR	TE	Comments
Coronal LOC	Cor	28 x 28	5.0	1.0	1	-	128 x 256	-	2000	15	
3 Plane LOC	-	25 x 25	6.0	2.0	1	-	128 x 256	-	213	9	
Shim	-	28 x 28	5.0	5.0	1	-	64 x 64	-	200	4.8	
T2 FS Axial	Ax	14 x 14	3.5	0.5	1	Light	224 x 256	-	4800	60	Long Axis
T1 Axial	Ax	14 x 14	3.5	0.5	1	-	256 x 320	-	595	10	Long Axis
T1 Sagittal	Sag	14 x 14	3.0	0.3	1	-	256 x 320	-	595	10	
STIR Sagittal	Sag	14 x 14	3.0	0.3	2	-	192 x 288	130	4500	100	
T1 Coronal	Cor	14 x 14	3.0	0.3	1	-	256 x 320	-	655	10	Short Axis
T2 FS Coronal	Cor	14 x 14	3.0	0.3	1	Light	192 x 256	-	3900	48	Short Axis
PD Coronal Tendon	Obl	14 x 14	3.0	0.3	1	-	192 x 256	-	3000	30	Peroneal Tendon
<i>Optional Contrast</i>											
T1 FS Axial Post	Ax	14 x 14	3.5	0.5	1	Light	256 x 320	-	595	10	
T1 FS Coronal Post	Cor	14 x 14	3.0	0.3	1	Light	256 x 320	-	655	10	
T1 FS Sagittal Post	Sag	14 x 14	3.5	0.3	1	Light	192 x 256	-	570	10	

### Indications

Without Contrast: Pain, Injury, Instability and Limited Range of Motion, Arthritis

With & Without Contrast: Bone and Soft Tissue Masses, Infection of the Bone and Soft Tissue

**\*\*Matrix/TR/TE values will vary between machines. Use your own discretion when selecting these values\*\***

Reviewed by Dr. Choi 11/2016

\*Subject to change at the discretion of the radiologist due to clinical circumstances.\*



# MRI Ankle Arthrogram



Sequence	Plane	FOV	Thickness	Gap	NSA	F/S	PE x RO Matrix	TI	TR	TE	Comments
LOCS											
T1 FS Axial	Ax	14 x 14	3.0	1.0	1	-	224 x 256	-	600	12	
T1 FS Sagittal	Sag	14 x 14	3.0	0.5	1	-	224 x 256	-	600	12	
STIR Sagittal	Sag	14 x 14	3.0	0.5	2	-	192 x 288	130	4750	100	
T1 FS Coronal	Cor	14 x 14	3.0	0.5	1	-	224 x 256	-	705	12	
PD FS Coronal	Cor	14 x 14	3.0	0.5	2	-	224 x 240	-	3665	40	
3D FE Coronal	Cor	14 x 14	1.5	0.0	1	-	224 x 224	-	41.9	15	

## Indications

With Contrast:

Ligament Tears

**\*\*Matrix/TR/TE values will vary between machines. Use your own discretion when selecting these values\*\***

Reviewed by Dr. Choi 11/2016

\*Subject to change at the discretion of the radiologist due to clinical circumstances.\*



# MRI

## Lisfranc



Diagnostic & Preventative Imaging Center

Sequence	Plane	FOV	Thickness	Gap	NSA	F/S	PE x RO Matrix	TI	TR	TE	Comments
Coronal LOC	Cor	28 x 28	5.0	1.0	1	-	128 x 256	-	2000	15	
3 Plane LOC	-	25 x 25	6.0	0.0	1	-	128 x 256	-	119	9	
Shim	-	28 x 28	5.0	5.0	1	-	64 x 64	-	200	4.8	
PD FS Axial	Ax	14 x 14	3.5	0.3	1	Light	224 x 256	-	3500	30	Short Axis: 1st TMT
T1 Axial	Ax	14 x 14	3.5	0.3	1	-	256 x 336	-	375	12	Short Axis: 1st TMT
T1 Sagittal	Sag	14 x 14	3.0	0.3	1	-	256 x 320	-	603	12	
STIR Sagittal	Sag	14 x 14	3.0	0.3	1	-	192 x 256	145	7073	60	
T1 Coronal	Cor	14 x 14	3.0	0.3	1	-	224 x 256	-	575	10	Long Axis: 1st TMT
PD FS Coronal	Cor	14 x 14	3.0	0.3	1	Light	224 x 256	-	3500	30	Long Axis: 1st TMT

## Indications

Without Contrast: Pain midfoot, Evaluate for Lisfranc ligament injury

With & Without Contrast: Bone and Soft Tissue Masses, Infection of the Bone and Soft Tissue

**\*\*Matrix/TR/TE values will vary between machines. Use your own discretion when selecting these values\*\***

Reviewed by Dr. Choi 11/2016

\*Subject to change at the discretion of the radiologist due to clinical circumstances.\*



# MRI

## Mid/Forefoot



Diagnostic & Preventative Imaging Center

Sequence	Plane	FOV	Thickness	Gap	NSA	F/S	PE x RO Matrix	TI	TR	TE	Comments
Coronal LOC	Cor	28 x 28	5.0	1.0	1	-	128 x 256	-	2000	15	
3 Plane LOC	-	25 x 25	6.0	0.0	1	-	128 x 256	-	119	9	
Shim	-	28 x 28	5.0	5.0	1	-	64 x 64	-	200	4.8	
T2 FS Axial	Ax	14 x 14	3.5	0.3	1	Light	224 x 256	-	4550	60	Short Axis
T1 Axial	Ax	14 x 14	3.5	0.3	1	-	256 x 336	-	375	12	Short Axis
T1 Sagittal	Sag	14 x 14	3.0	0.3	1	-	256 x 320	-	603	12	
STIR Sagittal	Sag	14 x 14	3.0	0.3	1	-	192 x 256	145	7073	60	
T1 Coronal	Cor	14 x 14	3.0	0.3	1	-	224 x 256	-	575	10	Long Axis
T2 FS Coronal	Cor	14 x 14	3.0	0.3	1	Light	224 x 256	-	4656	60	Long Axis
<i>Optional Contrast</i>											
T1 FS Axial Post	Ax	14 x 14	3.5	0.5	2	Light	192 x 256	-	650	10	
T1 FS Sagittal Post	Sag	14 x 14	3.0	0.3	3	Light	192 x 256	-	570	10	
T1 FS Coronal Post	Cor	14 x 14	3.0	0.3	1	Light	192 x 256	-	650	10	

## Indications

Without Contrast: Pain, Injury, Instability and Limited Range of Motion, Arthritis

With & Without Contrast: Bone and Soft Tissue Masses, Infection of the Bone and Soft Tissue

**\*\*Matrix/TR/TE values will vary between machines. Use your own discretion when selecting these values\*\***

Reviewed by Dr. Choi 11/2016

\*Subject to change at the discretion of the radiologist due to clinical circumstances.\*



# MRI Midfoot Stress Fracture



Diagnostic & Preventative Imaging Center

Sequence	Plane	FOV	Thickness	Gap	NSA	F/S	PE x RO Matrix	TI	TR	TE	Comments
Coronal LOC	Cor	28 x 28	5.0	1.0	1	-	128 x 256	-	2000	15	
3 Plane LOC	-	25 x 25	6.0	0.0	1	-	128 x 256	-	119	9	
Shim	-	28 x 28	5.0	5.0	1	-	64 x 64	-	200	4.8	
T2 FS Axial	Ax	14 x 14	3.5	0.3	1	Light	224 x 256	-	4550	60	Short Axis to Metatarsal
T1 Axial	Ax	14 x 14	3.5	0.3	1	-	256 x 336	-	375	12	Short Axis to Metatarsal
T1 Sagittal	Sag	14 x 14	3.0	0.3	1	-	256 x 320	-	603	12	Sagittal to Metatarsal
STIR Sagittal	Sag	14 x 14	3.0	0.3	1	-	192 x 256	145	7073	60	Sagittal to Metatarsal
T1 Coronal	Cor	14 x 14	3.0	0.3	1	-	224 x 256	-	575	10	Long Axis to Metatarsal
T2 FS Coronal	Cor	14 x 14	3.0	0.3	1	Light	224 x 256	-	4656	60	Long Axis to Metatarsal
<i>Optional Contrast</i>											
T1 FS Axial Post	Ax	14 x 14	3.5	0.5	2	Light	192 x 256	-	650	10	
T1 FS Sagittal Post	Sag	14 x 14	3.0	0.3	3	Light	192 x 256	-	570	10	
T1 FS Coronal Post	Cor	14 x 14	3.0	0.3	1	Light	192 x 256	-	650	10	

## Indications

Without Contrast: Midfoot stress fracture, Running injury, Runner

With & Without Contrast: Bone and Soft Tissue Masses, Infection of the Bone and Soft Tissue

**\*\*Matrix/TR/TE values will vary between machines. Use your own discretion when selecting these values\*\***

Reviewed by Dr. Choi 11/2016

\*Subject to change at the discretion of the radiologist due to clinical circumstances.\*



# MRI Plantar Plate/Turf Toe



Diagnostic & Preventative Imaging Center

Sequence	Plane	FOV	Thickness	Gap	NSA	F/S	PE x RO Matrix	TI	TR	TE	Comments
Coronal LOC	Cor	28 x 28	5.0	1.0	1	-	128 x 256	-	2000	15	
3 Plane LOC	-	25 x 25	6.0	0.0	1	-	128 x 256	-	119	9	
Shim	-	28 x 28	5.0	5.0	1	-	64 x 64	-	200	4.8	
PD FS Axial	Ax	14 x 14	3.5	0.3	1	Light	224 x 256	-	3500	30	Short Axis: 1st MTP
T1 Axial	Ax	14 x 14	3.5	0.3	1	-	256 x 336	-	375	12	Short Axis: 1st MTP
T1 Sagittal	Sag	14 x 14	3.0	0.3	1	-	256 x 320	-	603	12	Sagittal: 1st MTP
PD FS Sagittal	Sag	14 x 14	3.0	0.3	1	Light	192 x 256	-	3500	30	Sagittal: 1st MTP
T1 Coronal	Cor	14 x 14	3.0	0.3	1	-	224 x 256	-	575	10	Long Axis: 1st MTP
PD FS Coronal	Cor	14 x 14	3.0	0.3	1	Light	224 x 256	-	3500	30	Long Axis: 1st MTP

## Indications

Without Contrast: 1st MTP Pain, Evaluate plantar plate

With & Without Contrast: Bone and Soft Tissue Masses, Infection of the Bone and Soft Tissue

**\*\*Matrix/TR/TE values will vary between machines. Use your own discretion when selecting these values\*\***

Reviewed by Dr. Choi 11/2016

\*Subject to change at the discretion of the radiologist due to clinical circumstances.\*



# Body MRI General Comments



1. All body imaging should be performed on a 1.5 T magnet unless body habitus necessitates the larger bore of the 3 T.
2. DWI is now considered standard protocol for all solid organ or mass workup with MRI.
3. Blade or propeller techniques for T2WI should be performed whenever possible in the setting of a poor breath-holder or other movement. These techniques should not be used otherwise.
4. If not using Eovist for liver MRI, omit only the delayed hepatocyte phase.
5. Continue to contact a radiologist for female pelvis MRI protocol = "Nish Pelvis" vs. "King Pelvis". Please note that all female pelvis MRI should have a straight sagittal T2 (not FS) and a T1 FS Pre GAD.
6. Contrast dose is weight based, per manufacturer guidelines, except when using Eovist. Patients who receive Eovist should always be given 10 mL of contrast.



# MRI Chest

## Pectus Excavatum



1. 3 Plane LOC
2. Sagittal HASTE - Free breathing
3. Axial HASTE - Respiratory Navigator/(BH) - Coverage: Entire chest to include region of pectus deformity as seen on sagittal sequence (Series 2)

**Comments:** (BH) = Breath Hold

### Indications

Without Contrast: Evaluate pectus deformity; Haller index

**\*\*Values will vary between machines. Use your own discretion when selecting values.\*\***

Reviewed by Dr. Becker 11/2023

\*Subject to change at the discretion of the radiologist due to clinical circumstances.\*



# MRI Liver



## 1.5 T Magnet

Eovist 10 mL for all patients except young peds; Call radiologist for large patients to consider dose doubling.

No Eovist if Bilirubin at or above 3 mg/dL

If not using Eovist, omit #9

If ordered with MRCP, must do before administration of Eovist

1. 3 Plane LOC, Non-Breath Hold

2. Coronal HASTE Localizer - (BH) - Must include superior dome of diaphragm

3. Axial In/Out - (BH) - Top of diaphragm through duodenal c-loop; Use (BH) Localizer

4. ADC, DWI B50, B400 and B800

5. Axial FLASH FS, Pre GAD - Same as Series 3; Run immediately before GAD dose.

ST = 4mm, no gap

Post GAD FLASH (FS): Inject 1 mL/sec and 20 mL NS chaser at 2 mL/sec; Run 4 acquisitions - 1st = 20 sec delay, may need 30 sec delay if CHF/over 70 y/o; 2nd = Allow a breath then run again; 3rd = ~70 sec after injection; 4th = ~4 min after injection

**\*\*Do not bolus track with Eovist.**

**\*\*Optimal hepatic arterial phase is when the hepatic artery is heavily contrasted and there is a trace amount of contrast in the portal vein.\*\***

6. Axial T2 FS with TE 90 - Same coverage as Series 3; Respiratory gated; Use non-breath hold Loc; User propeller technique if possible on breathing pts, but ONLY when T2's are poor due to breathing or other motion

7. Axial T2 FS, long TE (TE 180) - Match Series 6

8. T1 FS Axial and Coronal - Long delays after these T2WI Sequences; Must be 20 minutes after injection; Use FA 40 degrees for these delayed images only, 1.8mm

## Indications

With and Without Contrast:      Mass/Lesion seen on other imaging, Increased Liver Enzymes

**\*\*Values will vary between machines. Use your own discretion when selecting values.\*\***

Reviewed by Dr. King 12/2018

\*Subject to change at the discretion of the radiologist due to clinical circumstances.\*



# MRCP



1 cup of water (~8 oz) right before exam.

Call radiologist if known ascites

**\*\*Call radiologist if clinical statement is for infection or tumor. This may warrant contrast.\*\***

1. 3 Plane LOC, Non-Breath Hold
2. Coronal HASTE Localizer - Navigator, center slices on liver, ensure dome is covered
3. Axial T2 HASTE FS with Nav - Cover bile ducts
4. Coronal T2 HASTE FS with Nav - Cover bile ducts
5. Coronal 3D TSE with Navigator - Cover bile ducts

**Comments:** Send dataset to 3D Workstation (Vitrea Bridge or TeraRecon)  
Call radiologist for Secretin Stimulation MRCP, if needed. This is done at IMMC.

## Indications

Without Contrast: Common Bile Duct Dilation, Pancreatic Duct Dilation

**\*\*Values will vary between machines. Use your own discretion when selecting values.\*\***

Reviewed by Dr. King 4/2016

\*Subject to change at the discretion of the radiologist due to clinical circumstances.\*



# MRI Renal



Water Prep and IV

1. 3 Plane LOC, Non-Breath Hold
2. Coronal HASTE Localizer - (BH)
3. Axial In/Out - (BH) - Use (BH) Loc (Do not alter transmit gain)
4. Axial T2 FS with TE ~ 140. Resp Gated, use Non-Breath Hold Loc to determine superior starting location, same end as in-phase axials
5. ADC, DWI B50, B400 and B800
6. Axial FLASH FS, Pre GAD
- 7.-9. Axial FLASH, Post GAD Dynamics - 2 mL gad/sec and 20 mL saline flush at 2 mL/sec. Run 3 dynamic acquisitions T1 Axial FS - 25 seconds after injection, then at 100 seconds, then at 10 minutes
10. Coronal Post at 10 minutes

**Comments:** (BH) = Breath Hold

Do subtractions for all post-contrast acquisitions if renal mass is T1 bright.

## Indications

With and Without Contrast: Mass/Cyst seen on other imaging, Decreased Kidney Function

**\*\*Values will vary between machines. Use your own discretion when selecting values.\*\***

Reviewed by Dr. King 4/2016



# MRI Adrenal



Diagnostic & Preventative Imaging Center

## Body Array

1. 3 Plane Localizer, Non-BH
2. Coronal HASTE T2 Localizer - (BH) - Cover adrenal glands +/- mass
3. Axial HASTE T2 - (BH) - Cover both adrenal glands; Use (BH) localizer to determine coverage
4. Axial HASTE T2 FS - (BH) - Same location as Series 3
5. Axial T1 In/Out Phase - (BH) - Same location as Series 3
6. Axial DWI 50-400-800  
*\*\*Please send only b800 and ADC map*
7. Axial T1 FS - (BH) - Same location as Series 3

## CONTRAST

8. Axial T1 FS Arterial - (BH) - Same location as Series 3
9. Axial T1 FS - Immediately after Arterial phase (Series 8), allowing time for patient to exhale and perform second set of breathing instructions - (BH) - Same location as Series 3
10. Axial T1 FS - Run scan at 150 seconds after contrast injection - (BH) - Same location as Series 3

**Comments:** (BH) = Breath Hold

## Indications

Without Contrast: Mass seen on other imaging

**\*\*Values will vary between machines. Use your own discretion when selecting values.\*\***

Reviewed by Dr. Becker 4/2025

\*Subject to change at the discretion of the radiologist due to clinical circumstances.\*



# MRI Pancreas



Diagnostic & Preventative Imaging Center

**\*If following pancreatic cancer, or after whipple procedure for any reason, use Eovist and cover entire liver.**

**Include 20 minute delayed FatSat through entire liver. Use timing for post-contrast series as per Liver protocol.**

IV and water

1. 3 Plane LOC, Non-Breath Hold
2. Coronal HASTE Localizer - (BH) - Do as many slices as possible in the breath hold.
3. Axial In/Out - Cover top of diaphragm though c-loop of duodenum or bottom of the liver (whichever is lowest), use (BH) LOC
4. ADC, DWI B50, B400, B800
5. Axial T2 RT FS, RG
6. 3D MRCP, include rotating MIPS
7. Axial FLASH FS Pre-GAD THIN ST/SG 3.0/0 (no gaps), just cover pancreas
- 8.-11. Axial FLASH Post-GAD, like #5, first 25 seconds after injection, then breath and run second phase, then another phase at 70 seconds. Fourth phase at 4 minutes.

**Comments:** (BH) = Breath Hold

If bolus tracking, run first scan 8 seconds after blush in abdominal aorta.

If working up pancreas cancer for metastatic disease, call radiologist. Might need liver instead.

**\*\*Values will vary between machines. Use your own discretion when selecting values.\*\***

Reviewed by Dr. King 6/2021

\*Subject to change at the discretion of the radiologist due to clinical circumstances.\*



# MRI Enterography



1.5 T Magnet  
Coil: Body Array

Setup:

1. NPO x 6 hours
2. 3 total bottles of Breeza at 15 minute increments over the course of 1 hour prior to scan
3. 1mg IM glucagon - IF patient is NOT insulin dependent diabetic  
To be given 2 minutes before start of study/first localizer  
*Onset of action is 8-10 minutes, duration is 12-27 minutes*

Series:

Series 1: Localizer  
Series 2: Localizer BH  
Series 3: Cor T2 HASTE LOC  
Series 4: Cor T2 cine TruFISP Free Breath

Series 5: Cor T2 HASTE  
Series 6 Ax T2 HASTE  
Series 7: Ax T2 HASTE FS Composed  
Series 8: Cor T2 TruFISP FS

Series 9: Ax T1 FS pre, breath hold  
Series 10: Coronal T1 FS pre, breath hold

Setup: Contrast - Gadavist 0.15 mL/kg, 3cc/second

Series 11: Cor T1 FS 3D VIBE POST (40 seconds)  
Series 12: Cor T1 FS 3D VIBE POST (2 minutes)  
Series 13: Ax T1 FS VIBE POST

Series 14: FB DW 50-800 composed  
*\*\*Please send only b800 and ADC map*

**Comments:** (BH) = Breath Hold

**\*\*Values will vary between machines. Use your own discretion when selecting values.\*\***

Reviewed by Drs. Becker, King and Smith 1/2023

\*Subject to change at the discretion of the radiologist due to clinical circumstances.\*



# MRI of Right Sided Abdominal Pain in Pregnancy



1.5 T Phased Array Surface Coil  
Non Contrast Technique

1. Axial, Coronal, Sagittal T2 SSFSE (4 skip 1) - Limit FOV to right abdomen unless patient is small then may need to expand coverage.
2. Axial dual echo T1 in/out phase AND T1 Fat Sat Axial.
3. Repeat Axial SSFSE T2 with above parameters with Fat Sat.
4. **\*\*Call radiologist to review.\*\*** May need multiplanar T2 FS's, may need additional imaging such as below or may be done.
5. T2 thick slab (slice thickness between 20-60 mm) SSFSE for patients with suspected choledocholithiasis or ureterolithiasis. This is optional.
6. Axial T2\* = TR 30 msec, 45 degree flip, 3-skip-1, 256 x 128, 35 cm FOV.
7. DWI Coronal B-400 and B-800.

## Indications

Without Contrast: Right-sided abdominal pain in pregnancy

**\*\*Values will vary between machines. Use your own discretion when selecting values.\*\***

Reviewed by Dr. King 4/2016



# MRI Female Pelvis

## Generic



Diagnostic & Preventative Imaging Center

Bowel Prep - Avoid bulky, high fiber and spicy foods, and carbonated beverages the day prior to and the day of the examination.

Foods to avoid - Nuts, food with seeds, bulky high-fiber foods, juices with pulp, spicy foods, carbonated beverages.

Acceptable foods - Soup, Jell-O, pudding, yogurt, white bread, rolls without seeds, white rice, plain white pasta noodles

NPO for 4 hours prior to exam. Medications may be taken with sips of water only.

For diagnoses involving the cervix and uterus, including endometriosis, administer 20 mL ultrasound gel to the vagina. Patient may administer themselves. Do not administer gel to any patient with an unbroken hymen. Contact radiologist with questions.

1. 3 Plane LOC
2. Coronal HASTE - Sacrum through pelvic cavity
3. Axial T1 - Aortic bifurcation through 1 slice below vaginal canal; 24-26 FOV, use smallest possible; R→L phase encode
4. Axial T2 - Same as Series 3
5. Axial STIR - Top of iliac crests through lesser trochanter; FOV to include bony pelvis, do not need to include all of the muscles or subcutaneous fat
6. Axial DWI 50-400-800  
*\*\*Please send only b800 and ADC map*
7. Sagittal T2 - Include all of female anatomy, femoral head to femoral head; 24-26 FOV, use smallest possible; S→I phase encode
8. Coronal T2 - Sacrum through pelvic cavity; 24-26 FOV, use smallest possible
9. Axial T1 FS Pre - (BH) - Cover at least from the top of uterus through the vaginal canal, possibly as high as the aortic bifurcation; 32-36 FOV, phase AP, adjust FOV so that 3/4 of FOV just covers skin to skin

### **Post GAD - Inject and wait 10-12 seconds, 3 mL/sec**

10. Axial T1 FS Post - (BH) - Arterial
11. Axial T1 FS Post - (BH) - At 60 seconds
12. Sagittal T1 FS Post - (BH)

**Comments:** 1. (BH) = Breath Hold

## Indications

With and Without Contrast: Pelvic Pain, Mass seen on other imaging, Abnormal Bleeding, Amenorrhea, Fibroids

**\*\*Values will vary between machines. Use your own discretion when selecting values.\*\***

Reviewed by Dr. Becker 6/2024

\*Subject to change at the discretion of the radiologist due to clinical circumstances.\*



# MRI Female Pelvis

## Uterine/Mullerian Formation Anomaly



Diagnostic & Preventative Imaging Center

Bowel Prep - Avoid bulky, high fiber and spicy foods, and carbonated beverages the day prior to and the day of the examination.

Foods to avoid - Nuts, food with seeds, bulky high-fiber foods, juices with pulp, spicy foods, carbonated beverages.

Acceptable foods - Soup, Jell-O, pudding, yogurt, white bread, rolls without seeds, white rice, plain white pasta noodles

NPO for 4 hours prior to exam. Medications may be taken with sips of water only.

1. 3 Plane LOC

2. Coronal HASTE - Sacrum through pelvic cavity

3. Axial T1 - Aortic bifurcation through 1 slice below vaginal canal; 24-26 FOV, use smallest possible; R→L phase encode

4. Axial T2 - Same as Series 3

5. Axial T2 SPAIR SPACE

6. Axial STIR

7. Axial DWI 50-400-800

*\*\*Please send only b800 and ADC map*

8. Sagittal T2 - Include all of female anatomy, femoral head to femoral head; 24-26 FOV, use smallest possible; S→I phase encode

9. Coronal T2 - Sacrum through pelvic cavity; 24-26 FOV, use smallest possible

10. #1 Oblique Axial T2 - PERPENDICULAR to the endometrial canal; 5mm skip 1mm

11. #2 Oblique Axial T2 - PARALLEL to the endometrial canal; 5mm skip 1 mm

12. Axial T1 FS Pre - (BH) - Cover at least from the top of uterus through the vaginal canal, possibly as high as the aortic bifurcation; 32-36 FOV, phase AP, adjust FOV so that 3/4 of FOV just covers skin to skin

\*\*\*These studies can be completed without intravenous contrast; if the ordering provider specifically requests contrast, continue with acquisitions as below.

**Post GAD - Inject and wait 10-12 seconds, 3 mL/sec**

13. Axial T1 FS Post - (BH) - Arterial

14. Axial T1 FS Post - (BH) - At 60 seconds

15. Sagittal T1 FS Post - (BH)

**Comments:** 1. (BH) = Breath Hold

## Indications

Without Contrast: Workup for Uterine/Mullerian Formation Anomaly; Bicornuate, Septate, Didelphys, Rudimentary horn, etc.

**\*\*Values will vary between machines. Use your own discretion when selecting values.\*\***

Reviewed by Dr. Becker 6/2024

\*Subject to change at the discretion of the radiologist due to clinical circumstances.\*



# MRI Female Pelvis

## Endometrial/Cervical/Vaginal Cancer



Diagnostic & Preventative Imaging Center

Bowel Prep - Avoid bulky, high fiber and spicy foods, and carbonated beverages the day prior to and the day of the examination.

Foods to avoid - Nuts, food with seeds, bulky high-fiber foods, juices with pulp, spicy foods, carbonated beverages.

Acceptable foods - Soup, Jell-O, pudding, yogurt, white bread, rolls without seeds, white rice, plain white pasta noodles

NPO for 4 hours prior to exam. Medications may be taken with sips of water only.

Administer 20 mL ultrasound gel to the vagina. Patient may administer themselves. Do not administer gel to any patient with an unbroken hymen.

Contact radiologist with questions.

1. 3 Plane LOC

2. Coronal HASTE - Sacrum through pelvic cavity

3. Axial T1 - Aortic bifurcation through 1 slice below vaginal canal; 24-26 FOV, use smallest possible; R→L phase encode

4. Axial T2 - Same as Series 3

5. Axial STIR - Top of iliac crests through lesser trochanter; FOV to include bony pelvis, do not need to include all of the muscles or subcutaneous fat

6. Axial DWI 50-400-800

*\*\*Please send only b800 and ADC map*

7. Sagittal T2 - Include all of female anatomy, femoral head to femoral head; 24-26 FOV, use smallest possible; S→I phase encode

8. Coronal T2 - Sacrum through pelvic cavity; 24-26 FOV, use smallest possible

9. Oblique Axial T2 - PERPENDICULAR to the endometrial canal (endometrial cancer), cervical canal (cervical cancer), or vaginal canal (vaginal cancer); 4 mm skip 0.5 mm; 20 FOV; 256x256; 3 NEX; R→L phase encode

10. Axial T1 FS Pre - (BH) - Cover at least from the top of uterus through the vaginal canal, possibly as high as the aortic bifurcation; 32-36 FOV, phase AP, adjust FOV so that 3/4 of FOV just covers skin to skin

**Post GAD - Inject and wait 10-12 seconds, 3 mL/sec**

10. Axial T1 FS Post - (BH) - Arterial

11. Axial T1 FS Post - (BH) - At 60 seconds

11. Sagittal T1 FS Post - (BH)

**Comments:** 1. (BH) = Breath Hold

## Indications

With and Without Contrast: Endometrial, Cervical or Vaginal Cancer

**\*\*Values will vary between machines. Use your own discretion when selecting values.\*\***

Reviewed by Dr. Becker 6/2024

\*Subject to change at the discretion of the radiologist due to clinical circumstances.\*



# MRI Urethral Diverticulum



Diagnostic & Preventative Imaging Center

Patient needs to urinate just prior to exam.

Center FOV at the pubic symphysis.

1. 3 Plane LOC
2. Coronal T2 HASTE - Anterior pubic symphysis to sacrum
3. Axial T1 - Coverage of the urinary bladder and entire urethra; R→L phase encode
4. Axial T2 Fat Sat - Same as Series 3
5. Sagittal T2 Fat Sat - Coverage of the urinary bladder and urethra; S→I phase encode
6. Oblique Coronal T2 Fat Sat - Angle parallel to urethra, cover entire urethra and bladder
7. Axial Diffusion - Similar coverage and phase encode to sequence 3
8. Axial FS T1 Pre (BH) - Coverage of the urinary bladder and entire urethra; 32-36 FOV, 3/4 FOV; A→P phase encode

**Post GAD - Inject and wait 10-12 seconds, 3 mL/sec**

9. Axial T1 FS Post - (BH) - Arterial
10. Axial T1 FS Post - (BH) - At 60 seconds
11. Oblique Coronal FS T1 Post - (BH) - Same as series 6
12. Sagittal FS T1 Post - (BH) - Same as Series 5; 32-36 FOV, 3/4 FOV, A→P phase encode

**Comments:** 1. (BH) = Breath Hold

## Indications

With and Without Contrast: Concern for Urethral Diverticulum

**\*\*Values will vary between machines. Use your own discretion when selecting values.\*\***

Reviewed by Dr. Becker 6/2024

\*Subject to change at the discretion of the radiologist due to clinical circumstances.\*



# MRI Male Pelvis



Diagnostic & Preventative Imaging Center

Bowel Prep - Avoid bulky, high fiber and spicy foods, and carbonated beverages the day prior to and the day of the examination.

Foods to avoid - Nuts, food with seeds, bulky high-fiber foods, juices with pulp, spicy foods, carbonated beverages.

Acceptable foods - Soup, Jell-O, pudding, yogurt, white bread, rolls without seeds, white rice, plain white pasta noodles

NPO for 4 hours prior to exam. Medications may be taken with sips of water only.

1. Localizer
2. Coronal T2 HASTE - Wide FOV
3. Sagittal T2
4. Axial T2
5. Axial STIR
6. Coronal T2 - Small FOV
7. Axial DWI 50-400-800  
*\*\*Please send only b800 and ADC map*
8. Axial T1 IN/OUT of phase
9. Axial T1 FS Pre

## **GAD IV Contrast**

10. Axial T1 FS Post - 15 second
11. Axial T1 FS Post - 70 second
12. Axial T1 FS Post - 2 minute
13. Sagittal T1 FS Post
14. Axial T1 FS Post - 4 minute

## Indications

With and Without Contrast: Hematospermia

**\*\*Values will vary between machines. Use your own discretion when selecting values.\*\***

Reviewed by Dr. Becker 6/2024

\*Subject to change at the discretion of the radiologist due to clinical circumstances.\*



# MRI Perirectal Abscess



Glucagon, Water, Center FOV at pubic symphysis

1. 3 Plane LOC
2. Coronal Haste - Sacrum through pelvic cavity.
3. Set up perpendicular to anal canal. Axial T1 - Iliac crest through rectum and subcutaneous fat. If an abnormality, may go inferiorly into upper thigh. Phase right to left.
4. Axial T2 - Same as Series 3.
5. Sagittal T2 FS - Femoral head to femoral head. Include all pathology if it extends farther down. Phase superior to inferior.
6. Set up along anal canal. Coronal T2 - All of sacrum to anterior part of pubic symphysis.
7. Coronal STIR - Same as Series 6.
8. Axial STIR - Same as Series 3.
9. Axial Diffusion
10. Axial Flash FS Pre (BH) - Cover superiorly as much as a (BH) sequence will allow up to iliac crest. 32-36 FOV. Phase anterior to posterior.

**Post GAD, inject and wait 10-12 sec, 3 mL/sec**

11. and 12. Axial Flash FS Post (BH) - Same as Series 3.
13. Coronal Flash FS Post (BH) - Same as Series 6. 32-36 FOV. Use smallest FOV possible.

**Comments:** (BH) = Breath Hold

**\*\*Values will vary between machines. Use your own discretion when selecting values.\*\***

Reviewed by Dr. Becker 11/2023

\*Subject to change at the discretion of the radiologist due to clinical circumstances.\*



# MRI Breast



Diagnostic & Preventative Imaging Center

Sequence	Plane	FOV	Thickness	Gap	NSA	TI	PE x RO Matrix	FA	TR	TE	Comments
Coronal LOC FE_SLT	Cor	45 x 45	8.0	1.0	1	-	128 x 256	90	133	5	
Ax/Sag LOC FE_SLT	Sag	45 x 45	6.0	1.0	1	-	128 x 256	90	45	5	
MAP/Ref FE_MAP	Ax	65 x 65	8.0	0.0	1	-	64 x 64	20	235	4	
Ax T1 3D FFE	Ax	34 x 34	1.5 recon 0.7	0.0	1	-	356 x 336	10	6.2	3.2	
Shimming FE_AAS	Ax	37 x 37	5.0	10.0	1	-	32 x 32	70	4/9.6	200	
Ax F/S Dynamic FFE 3D	Ax	37 x 26	2.2 recon 1.1	0.0	1	-	368 x 256	10	5.5	2.5	Use lowest TR possible
Ax T2 F/S	Ax	34 x 23	3.0 recon 1.5	0.5	1	-	224 x 256	90	5200	70	Flop - 160

## Comments:

**\*\*Axial Dynamic timing is vendor specific - Please verify with the radiologist before performing exam\*\***

Ax Dynamic: Run Pre, Inject 2 mL per second, wait 50 seconds and run 4 additional passes (1.26 per pass)

**\*\*Resolution must stay below 1.0 per ACR**

**\*\*If any questions, please call Clive MRI (515-226-7442).**

**\*\*Matrix/TR/TE values will vary between machines. Use your own discretion when selecting these values\*\***

Reviewed by Dr. Wolford 1/2020

\*Subject to change at the discretion of the radiologist due to clinical circumstances.\*



# Safely Imaging Pregnant/Breast Feeding Patients



Based on the current information available, Iowa Radiology supports safely imaging pregnant women with CT and MRI exams when medically necessary.

## CT

According to the ACR 2008 Appropriateness Criteria & American Council of Obstetricians and Gynecologists:

"Women should be counseled that x-ray exposure from a single diagnostic procedure does not result in harmful fetal effects. Specifically, exposure to <5 rad (50mGy) has not been associated with an increase in fetal anomalies or pregnancy loss."

Standard single CT scan through the gravid uterus results in a fetal dose of 25 mGy or less (exposure of >150mGy - counsel mother about possible therapeutic abortion). At this dose there is no risk of teratogenic effects to the fetus. The only risk to the fetus is a small increased risk of cancer (specifically small increased risk of childhood cancer ~1% for an exposure of 25 mGy).

Intravenous and oral contrast may be given as necessary for CT.

\*\*Exposure of the newborn child to 10mGy of ionizing radiation increases the absolute lifetime risk of developing cancer by 0.4% and exposure to 50 mGy increases the absolute lifetime risk of developing cancer by 2%.

## MRI

MRI at 1.5T or less is safe in ALL trimesters of pregnancy.

Gadolinium should NOT be administered.

Gadolinium will cross the placental barrier and animal studies have shown congenital anomalies in utero.

## Breast Feeding

According to the 2015 ACR Manual on Contrast Media, it should be safe for the mother and infant to continue breastfeeding after receiving iodinated or gadolinium-based contrast agents. However, if the mother prefers, she may choose to pump and discard the breast milk for 12-24 hours before resuming breast feeding.



# Ultrasound Abdomen



**Liver** – The evaluation of the liver includes both long axis and transverse views. The liver parenchyma is evaluated for possible diffuse or focal abnormalities. The echogenicity of the liver compared to the right kidney should be performed whenever possible. The aorta in the region of the liver should be evaluated as well as the IVC where it passes through the liver. Evaluation should be done of the regions of the ligamentum teres, right hemidiaphragm, dome of the right lobe, and the right pleural space. The right and left portal vein branches and the hepatic veins should be seen within both lobes of the liver.

**Gallbladder and Biliary Tree** – Evaluation of the gallbladder includes both long axis and transverse views. The gallbladder is evaluated with the patient supine and in the left lateral decubitus positions, with additional patient positions as necessary. The gallbladder is evaluated for possible stones, polyps, or other masses and the mobility of these if found. The intrahepatic and extrahepatic bile ducts are evaluated for possible dilatation or any other abnormalities. Evaluation of the common bile duct in the head of the pancreas is done whenever possible.

**Pancreas** – The head, uncinate process, and body of the pancreas are evaluated transversely. When possible the tail of the pancreas is also evaluated. In the head of the pancreas the distal common bile duct and the gastroduodenal artery are evaluated. The pancreas and peripancreatic region are assessed for any fluid collections, adenopathy, vascular abnormalities, or masses.

**Spleen** – The spleen is evaluated in both long axis and transverse views. It is measured in long axis, transverse axis, and anterior to posterior diameter. When possible the echogenicity of the left kidney compared to the spleen is performed as well as the left pleural space.

**Kidneys** – The kidneys are evaluated in long axis visualizing the cortex and renal pelvis. The maximum length of each kidney is recorded. Transverse views of both kidneys include the upper pole, midsection including the renal pelvis, and the lower pole.

**Aorta and IVC** – The aorta and IVC are evaluated in long axis and transverse views. Any aneurysmal dilatation of the aorta is measured in AP and transverse diameters.



# Abdomen Ultrasound Cont.

The following images represent a COMPLETE upper abdominal ultrasound exam. Additional images may be necessary for proper documentation.

## Aorta

- Long – Measure
  - Proximal
  - Mid
  - Distal
- Trans – Measure
  - Proximal
  - Mid
  - Distal
  - Bifurcation
- Document any abnormality

## Pancreas

- Document head, body and tail, if possible
- Document portal flow with color

## IVC

- Long – with color – annotate as IVC

## Liver

- Long
  - Left lobe lateral
  - Left lobe medial
  - Left lobe with caudate and IVC
  - Right lobe lateral with measurement to include image of right kidney
  - Right lobe mid
  - Right lobe medial to include color image of portal vein
- Trans
  - Left lobe superior
  - Left lobe mid
  - Left lobe inferior
  - Right lobe dome
  - Right lobe hepatic veins
  - Right lobe mid
  - Right lobe inferior

## Gallbladder

- Supine
  - Document in long and transverse – several images



# Abdomen Ultrasound Cont.

- LLD
  - Document in long and transverse – several images
  - Measure gallbladder wall

## CBD

- Measure - with color, if able

## Right Kidney

- Long
  - Medial
  - Mid with measurement
  - Lateral
- Trans
  - Superior
  - Mid with measurement
  - Inferior

## Left Kidney

- Long
  - Medial
  - Mid with measurement
  - Lateral
- Trans
  - Superior
  - Mid with measurement
  - Inferior

## Spleen

- Long
  - Measure long and AP
- Trans
  - Measure

Document and measure all pathology  
Annotate all images



# Abdomen Ultrasound Cont.

The following images represent a LIMITED (RUQ) upper abdominal ultrasound exam. Additional images may be necessary for proper documentation.

## Aorta

- Long – measure
  - Proximal
  - Mid
  - Distal
- Trans – measure
  - Proximal
  - Mid
  - Distal
  - Bifurcation
- Document any abnormality

## Pancreas

- Document head, body and tail, if possible
- Document portal flow with color

## IVC

- Long – with color – annotate as IVC

## Liver

- Long
  - Left lobe lateral
  - Left lobe medial
  - Left lobe with caudate and IVC
  - Right lobe lateral with measurement to include image of right kidney
  - Right lobe mid
  - Right lobe medial to include color image of portal vein
- Trans
  - Left lobe superior
  - Left lobe mid
  - Left lobe inferior
  - Right lobe dome
  - Right lobe hepatic veins
  - Right lobe mid
  - Right lobe inferior

## Gallbladder

- Supine
  - Document in long and transverse – several images



# Abdomen Ultrasound Cont.

- LLD
  - Document in long and transverse – several images
  - Measure gallbladder wall

## CBD

- Measure - with color, if able

## Right Kidney

- Long
  - Medial
  - Mid with measurement
  - Lateral
- Trans
  - Superior
  - Mid with measurement
  - Inferior

Document and measure all pathology

Annotate all images



# Abdomen Ultrasound Cont.

The following images represent a LIMITED (LUQ) upper abdominal ultrasound exam. Additional images may be necessary for proper documentation.

## Left Kidney

- Long
  - Medial
  - Mid with measurement
  - Lateral
- Trans
  - Superior
  - Mid with measurement
  - Inferior

## Spleen

- Long
  - Measure long and AP
- Trans
  - Measure and color

Document and measure all pathology  
Annotate all images



# Ultrasound Aorta



**The following images represent an Aorta ultrasound exam. Additional images may be necessary for proper documentation.**

Aorta - The abdominal aorta is imaged in long axis and transverse views. The aorta should be evaluated from the diaphragm to the bifurcation. Any aneurysmal dilatation of the aorta is measured in AP and transverse diameters. The common iliac arteries are also.

## Longitudinal with Measurements

- Proximal
- Mid
- Distal
- Bifurcation
- Right Iliac
- Left Iliac

## Transverse with Measurements

- Proximal
- Mid
- Distal
- Bifurcation
- Right Iliac
- Left Iliac

Color and Spectral Doppler of Proximal, Mid, Distal & both Iliacs with proper Doppler angle

**All Doppler angles are to not exceed 60 degrees**

Document and measure all pathology

Annotate all images



# Ultrasound Breast



**The following images represent a Breast ultrasound exam. Additional images may be necessary for proper documentation.**

Breast - The breast sonogram should be correlated with clinical signs and/or symptoms and with mammographic and other appropriate breast imaging studies. A lesion or any area of the breast being studied should be viewed in 2 perpendicular projections, and real-time scanning by the interpreter is encouraged.

Images should be labeled, and the location of the lesion should be recorded using:

- Laterality
- Clock-face notation
- Distance from the nipple, measured from the nipple itself
- Orientation of the transducer with respect to the breast (i.e. transvers or longitudinal, radial or antiradial)

The size of the lesion should be determined by recording its maximal dimensions in at least 2 planes:

- Orthogonal planes are recommended
- At least 1 set of images of a lesion should be obtained without calipers
- A set of images of the lesion with color/power Doppler to assess/document vascularity of the lesion is also recommended

Sonographic features are important in accurately characterizing breast masses.

- Shape
- Orientation
- Margins
- Echo pattern
- Posterior acoustic features
- Special characteristics
- Vascularity
- Surrounding tissue

For patients with a palpable lump > 2 cm or any mass suspicious for CA:

- Scan the axilla on diagnostic ultrasound
- Findings required to be dictated in report

Document and measure all pathology

Annotate all images



# Ultrasound Carotid



**The following images represent a carotid artery ultrasound exam. Additional images may be necessary for proper documentation.**

All images are to be performed on both carotids

## Transverse

### Carotid

- Proximal
- Mid
- Distal
- Bulb / Bifurcation

## Longitudinal

### Carotid

- Proximal
  - Color
  - Spectral Doppler & Max peak systolic velocities
    - Angle correction to not exceed 60 degrees
- Mid
  - Color
  - Spectral Doppler & Max peak systolic velocities
    - Angle correction to not exceed 60 degrees
- Distal
  - Color
  - Spectral Doppler & Max peak systolic velocities
    - Angle correction to not exceed 60 degrees
- Bulb / Bif
  - Color
  - Spectral Doppler & Max peak systolic velocities
    - Angle correction to not exceed 60 degrees

### ICA

- Proximal
  - Color
  - Spectral Doppler & Max peak systolic velocities
    - Angle correction to not exceed 60 degrees
- Mid
  - Color
  - Spectral Doppler & Max peak systolic velocities
    - Angle correction to not exceed 60 degrees



# Carotid Ultrasound Cont.

- Distal
  - Color
  - Spectral Doppler & Max peak systolic velocities
    - Angle correction to not exceed 60 degrees

## ECA

- Color
- Spectral Doppler & Max peak systolic velocities
  - Angle correction to not exceed 60 degrees

## Vertebral

- Color
- Spectral Doppler & Max peak systolic velocities
  - Angle correction to not exceed 60 degrees

If abnormalities are found, additional images need to be obtained:

- Plaque - location, extent and characteristics documented in both transverse and longitudinal views
- Other vascular or perivascular abnormalities should be documented

If stenosis is found / suspected:

- Color / PW at site of maximum velocity of stenosis
- Color / PW distal to stenosis to document presence or absence of disturbed flow

Stents:

- Color and Doppler proximal, within and distal to stent
  - Record highest velocities

Annotate all images



# Ultrasound Hernia

## Definitions:

### Indirect inguinal hernia:

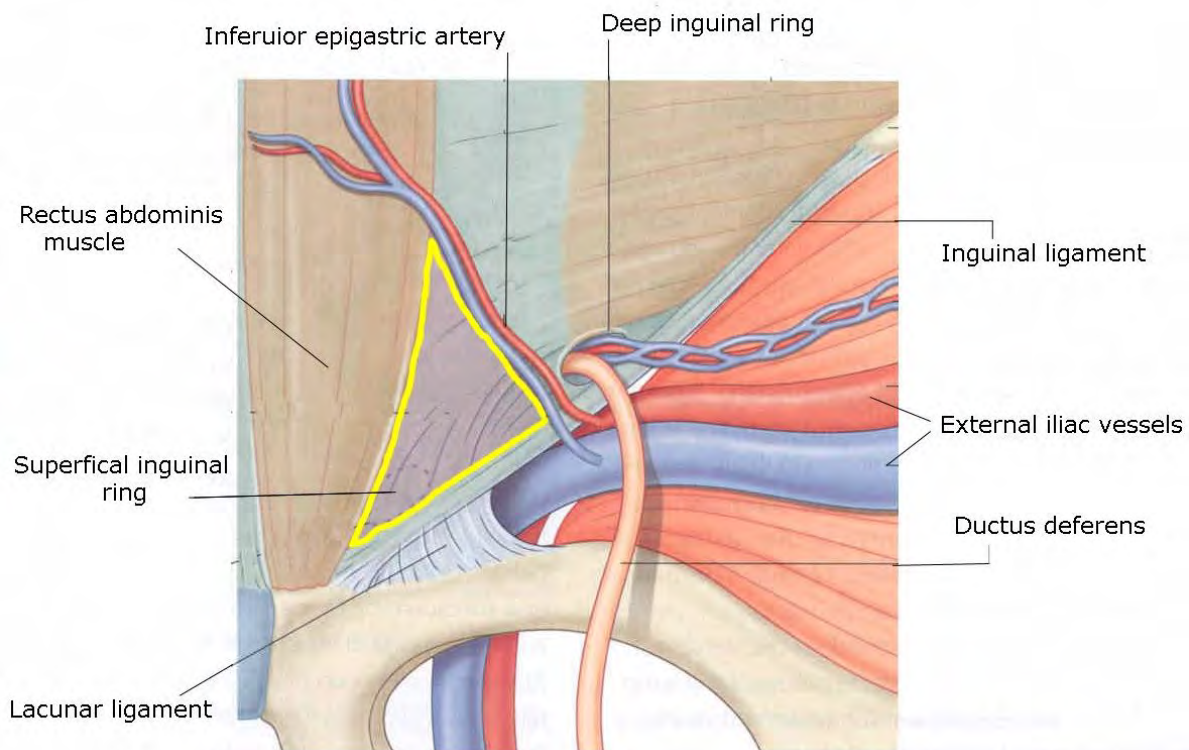
A hernia protruding through the abdominal wall via the deep inguinal ring and passes down the inguinal canal lateral to the inferior epigastric artery. In male patients, follow the spermatic cord – spermatic cord runs in the inguinal ring and plunges down into the abdomen at the deep inguinal ring – which is where the indirect inguinal hernias originate from.

### Direct inguinal hernia:

A hernia protruding through the abdominal wall via the superficial inguinal ring (Hesselbach's triangle) medial to the inferior epigastric artery and lateral to the rectus muscle.

### Femoral hernia:

A hernia through the femoral canal. Extends at least half way over the superior pubic ramus compressing the femoral vein in the cross sectional view.



*Figure 1. Pelvic anatomy of inguinal area*



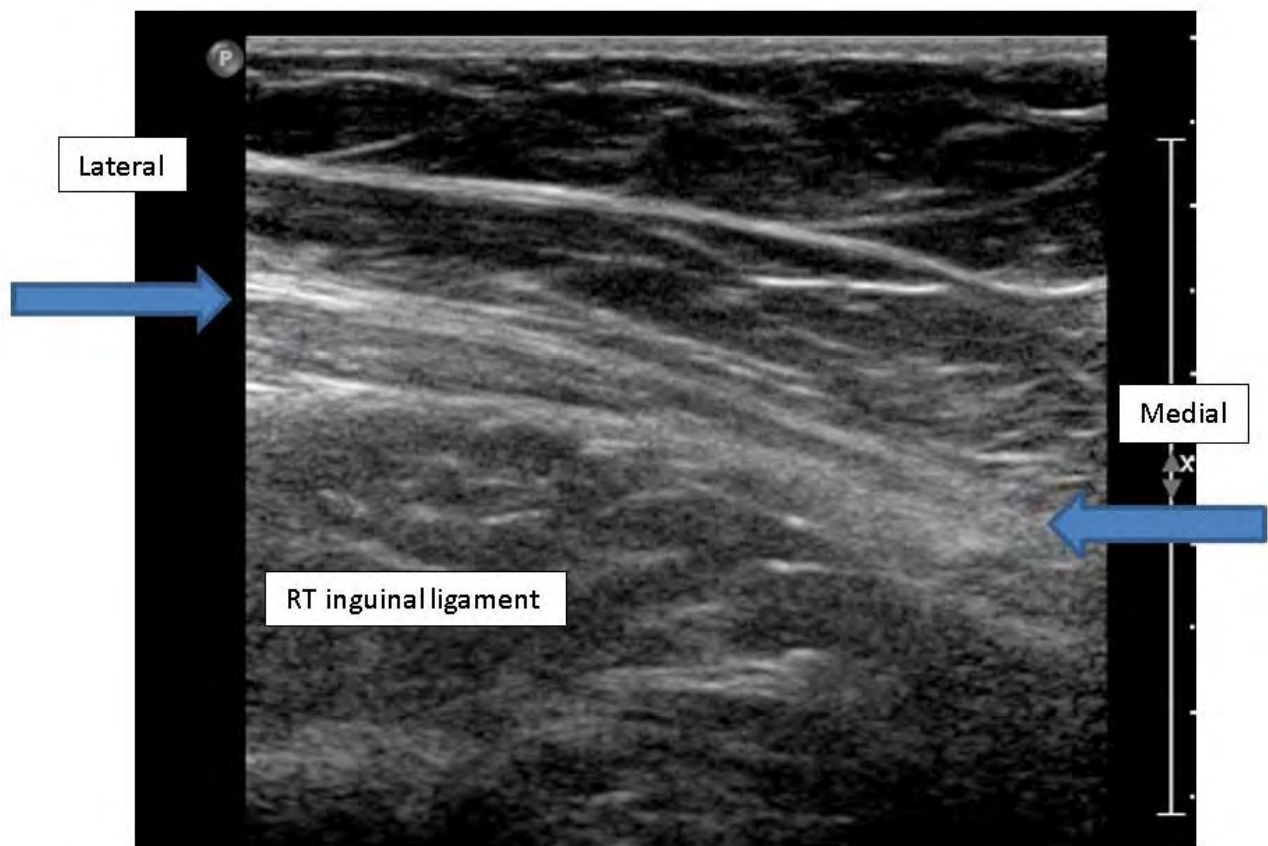

Figure 2. Sonographic appearance of the inguinal ligament

## Ultrasound Imaging Documentation:

Provide imaging to rule out indirect, direct and femoral hernias on both sides of the lower abdomen. Images should be obtained in the supine and standing positions.

### Indirect area documentation:

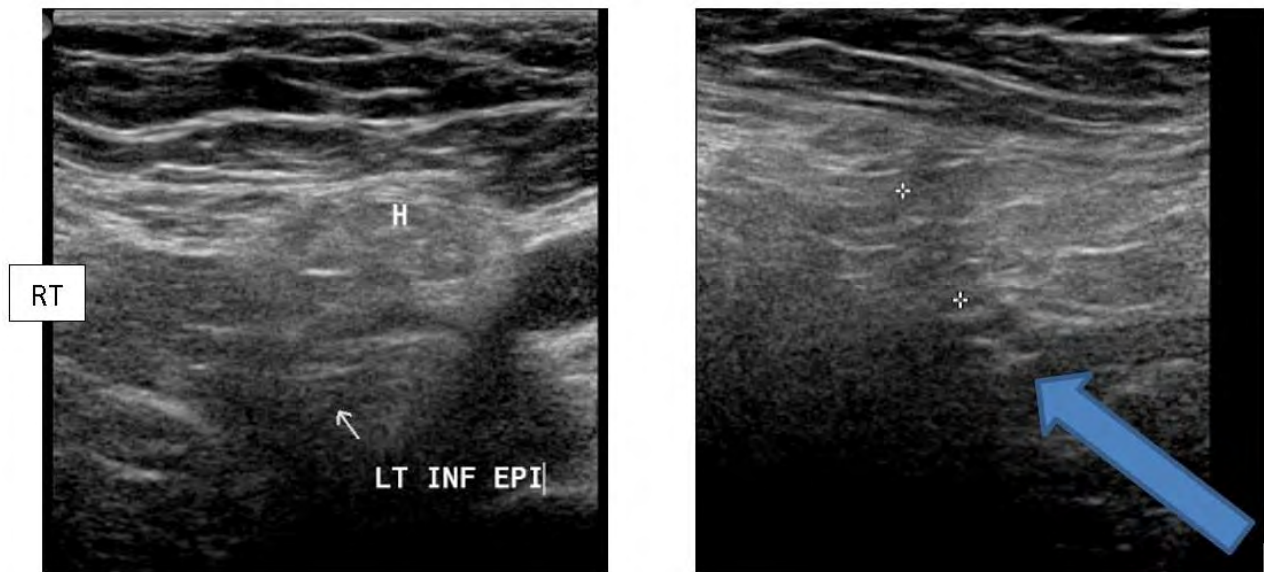
**XS images:** cross section to the inguinal canal at the level of the inferior epigastric artery

1. At least 2 still images. One with valsalva and one without valsalva.
2. At least one cine clip with valsalva

**Sagittal images:** sagittal with the inguinal canal at the level of the inferior epigastric artery. Document from the deep inguinal ring to below the inferior epigastric artery.

1. At least 2 still images. One with valsalva and one without valsalva.
2. At least one cine clip with Valsalva





*Figures 3a and Figure 3b*

Figure 3a shows a left indirect inguinal hernia in cross section. The indirect inguinal hernia is located anterior and lateral to the inferior epigastric vessels.

Figure 3b shows a sagittal view of an indirect inguinal hernia exiting the abdominal cavity through deep inguinal ring anterior to the inferior epigastric vessels during valsalva. The white cursors indicate where the indirect hernia enters the deep inguinal ring. The arrow indicates the inferior epigastric vessels.

## Direct area documentation:

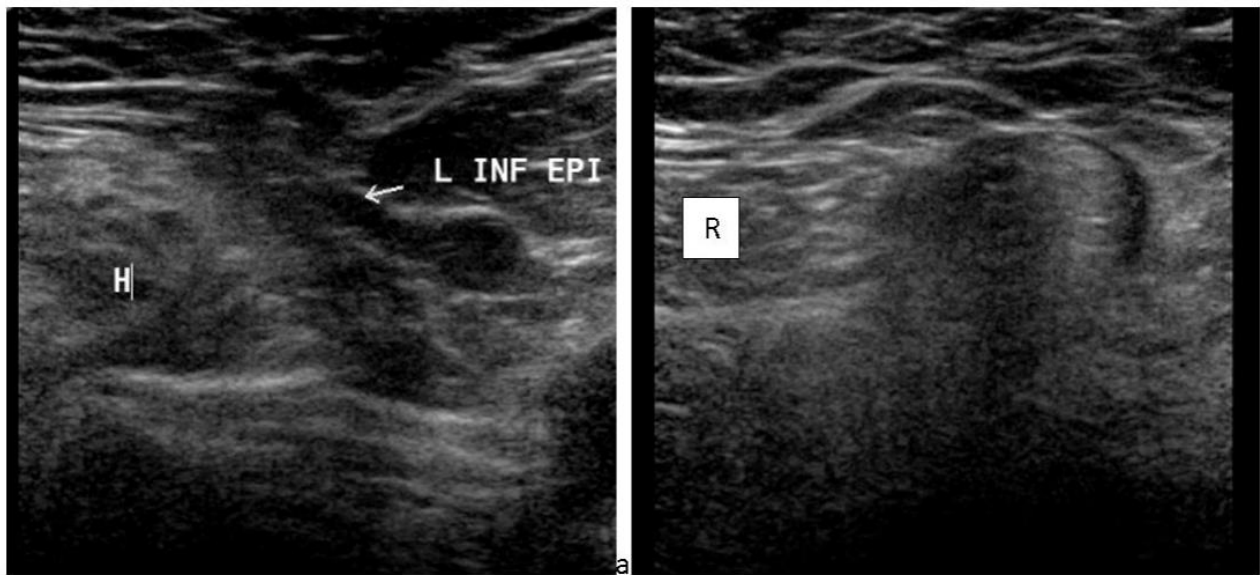
**XS images:** cross section to the inguinal canal at the level of the inferior epigastric artery

1. At least 2 still images. One with valsalva and one without valsalva.
2. At least one cine clip with valsalva

**Sagittal images:** sagittal with the inguinal canal at the level of the inferior epigastric artery. Document from the deep inguinal ring to below the inferior epigastric artery.

1. At least 2 still images. One with valsalva and one without valsalva.
2. At least one cine clip with Valsalva

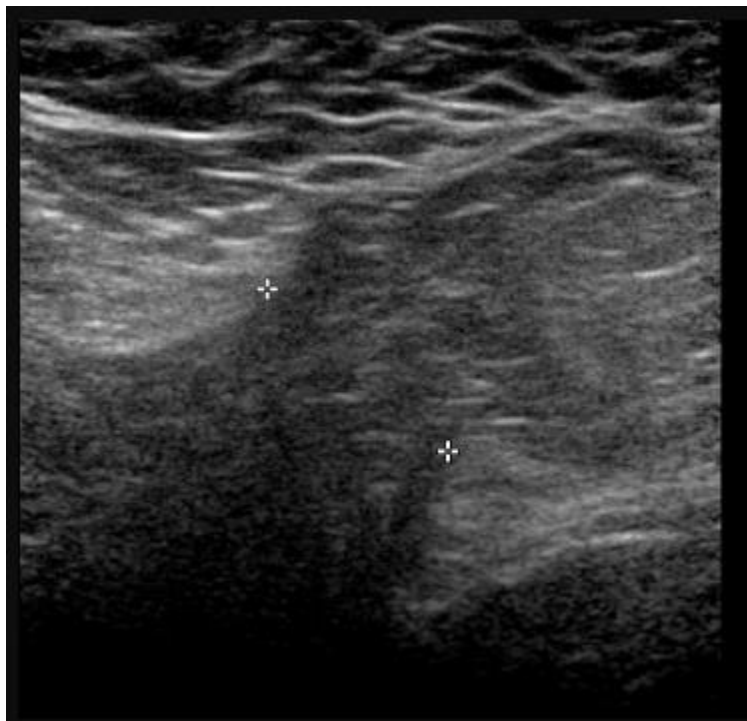




*Figure 4a. left direct inguinal hernia, and Figure 4b. left direct inguinal hernia*

Figure 4a shows direct inguinal hernia medial/posterior to the inferior left epigastric vessels during valsalva. (h) hernia

Figure 4b shows direct hernia displacing left rectus muscle medial and posterior during valsalva. (R) left rectus muscle



*Figure 5.*



Figure 5 shows a sagittal view of a direct inguinal hernia during valsalva. The cursors indicate the broken plane of the superficial inguinal ring by the direct inguinal hernia during valsalva.

## Femoral area documentation:

**Cross sectional images:** cross sectional images at the level of the femoral artery and vein just over the superior pubic ramus just medial to the femoral vein.

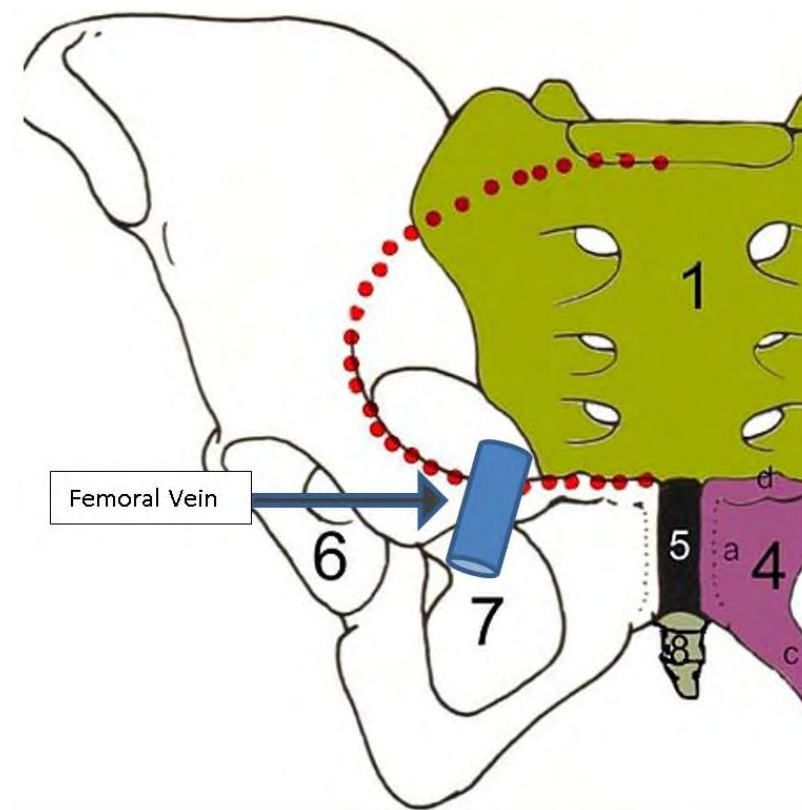
**Sagittal images:** Scan parallel to the medial margin of the femoral vein just inferior to the pubic ramus.

### XS images:

1. At least 2 still images. One with valsalva and one image without valsalva
2. At least one cine clip with valsalva

### Sagittal images:

1. At least 2 still images. One with valsalva and one image without Valsalva
2. At least one cine clip with valsalva



*Superior pubic ramus red dots*



**XS images:**

1. At least 2 still images. One with valsalva and one image without valsalva
2. At least one cine clip with valsalva

**Sagittal images:**

1. At least 2 still images. One with valsalva and one image without Valsalva
2. At least one cine clip with valsalva



# Ultrasound Hip

## INDICATIONS (Harris, 2014 and AIUM, 2013):

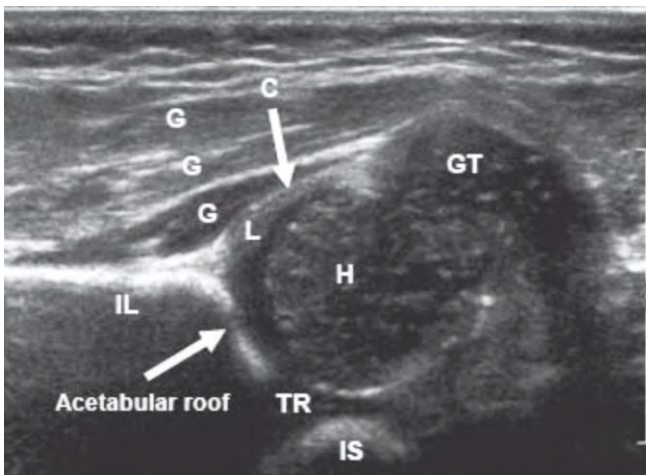
1. Hip Click
2. Limited Abduction
3. Asymmetrical crease
4. Family history of DDH
5. Breech presentation regardless of sex
6. Multiple Gestation
7. Oligohydramnios and other intrauterine causes of postural molding
8. Neuromuscular conditions
9. Monitoring patients with DDH being treated with a Pavlik harness or other splint device
10. Deformities of the foot

\*Two of the strongest risk factors for DDH are a female newborn with a frank breech presentation at birth and a family history of a parent and/or sibling with DDH.<sup>3</sup> (AIUM, 2013). **DDH** “results from an abnormal relationship of the femoral head to the acetabulum” (Harris, 2014).

## WHEN TO PERFORM THIS ULTRASOUND:

- **Optimally between 6 weeks and 6 months.** Hips are more mature / not as lax by the time the infant reaches 6 weeks and become too ossified after 6 months to adequately assess with ultrasound, may need x-ray (Harris, 2014).
- If ordered for screening for developmental dysplasia of the hip, the exam should not be completed until the child is 6 weeks of age. Performing on children younger can lead to false positive results.
- If the clinical history is solely family history of breach, the child was breach or a screening exam, the child needs to be 6 weeks of age after a term pregnancy at 40 weeks.
- If the order is from an orthopedic surgeon or the child has a documented hip click and the ordering physician documents hip instability, the ultrasound can be performed as ordered.

## ANATOMY

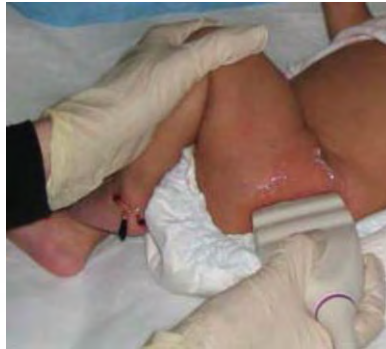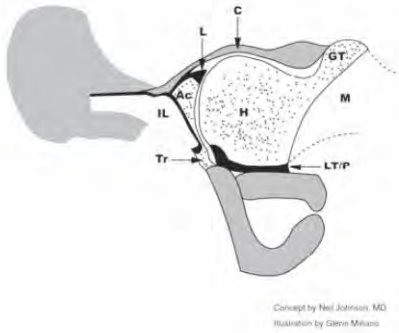


IL – ILIUM  
TR – TRIRADIATE CARTILAGE  
IS – ISCHIUM  
H – HEAD OF FEMUR  
L – LABRUM  
GT – GREATER TROCHANTER  
G – GLUTEUS MUSCLES  
C – CAPSULE

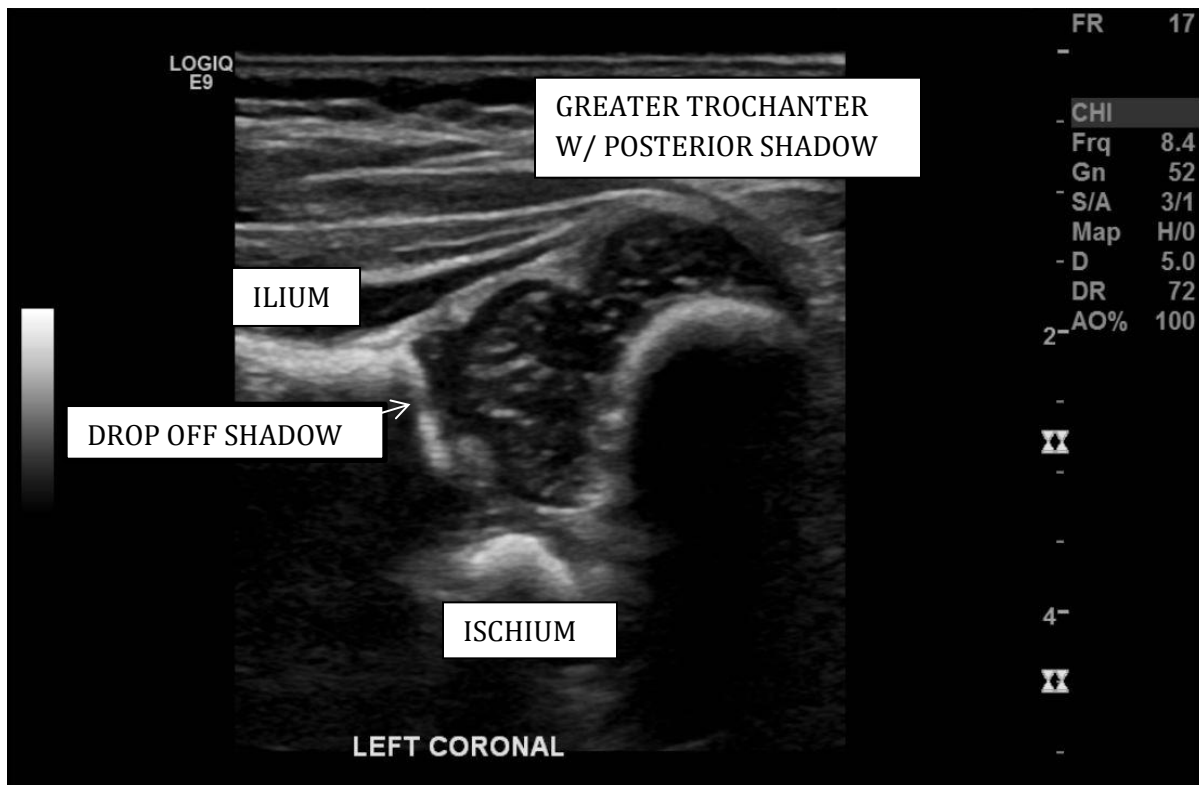


# Hip Ultrasound cont.

## CORONAL VIEW (AIUM, 2013)

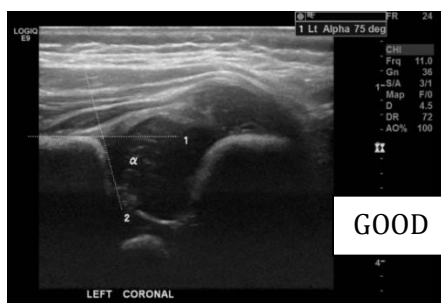


## IDEAL CORONAL IMAGE W/ LANDMARKS

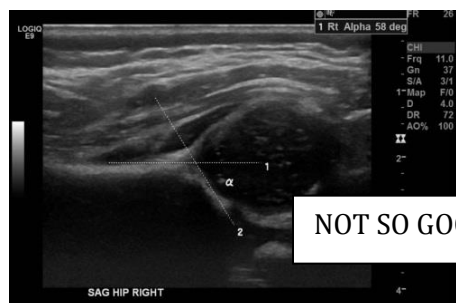

\*Try to straighten the ilium, get a nice sharp beta angle, demonstrate the drop off shadow in the acetabular roof if possible (IF YOU SEE THIS, THE HIP WILL BE NORMAL) and show the ischium and the greater trochanter w/ posterior shadow

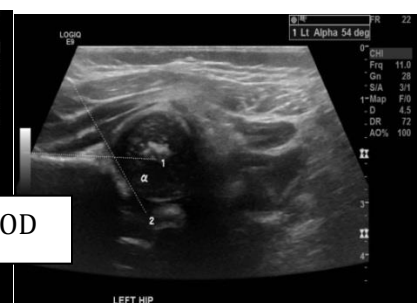.\*\* Images below show correct vs incorrect imaging techniques.



GOOD



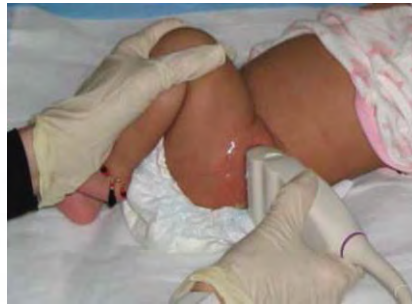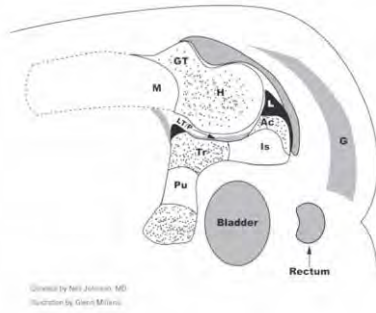
NOT SO GOOD



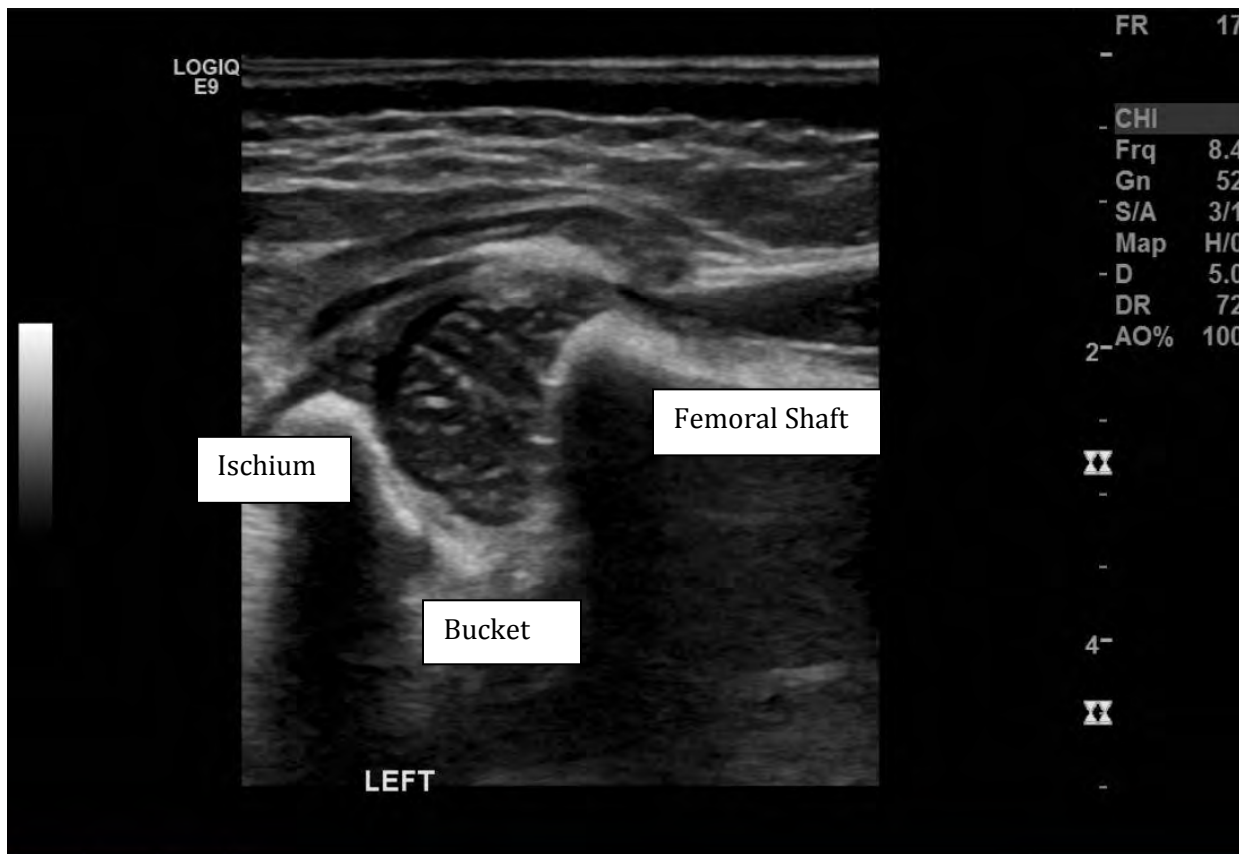


# Hip Ultrasound cont.

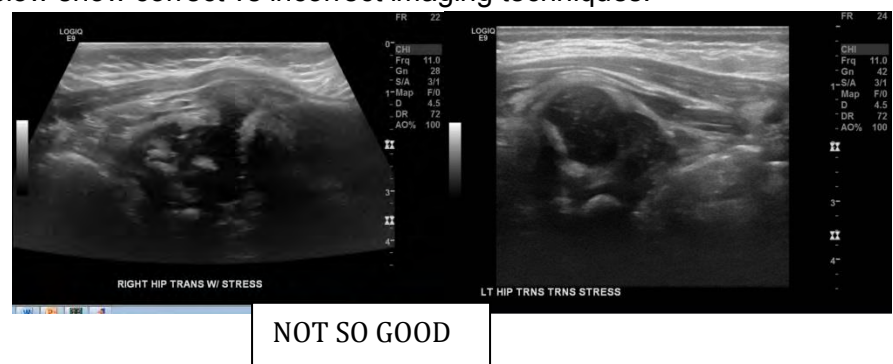
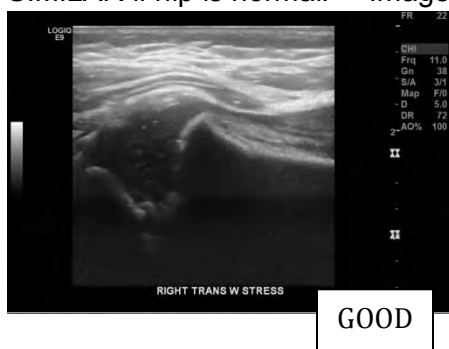## TRANSVERSE VIEW (AIUM, 2013)



## IDEAL TRANSVERSE IMAGE W/ LANDMARKS WITH AND WITHOUT STRESS



**\*\*LOOK FOR ICE CREAM CONE APPEARANCE / bucket should be fully formed. FEMORAL HEAD SHOULD STAY "WELL-SEATED" IN BUCKET W/ STRESS. TRANS W/ AND W/O STRESS SHOULD LOOK VERY SIMILAR if hip is normal!\*\*** Images below show correct vs incorrect imaging techniques.



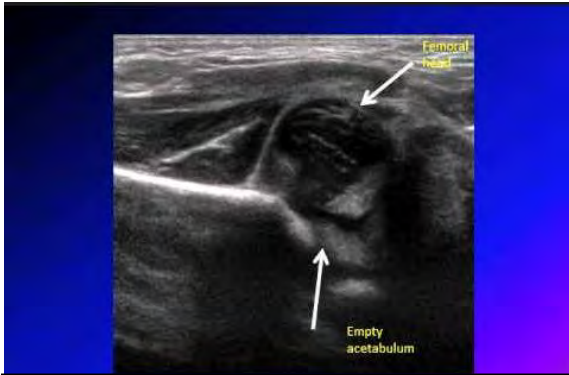
\*Subject to change at the discretion of the radiologist due to clinical circumstances.\*



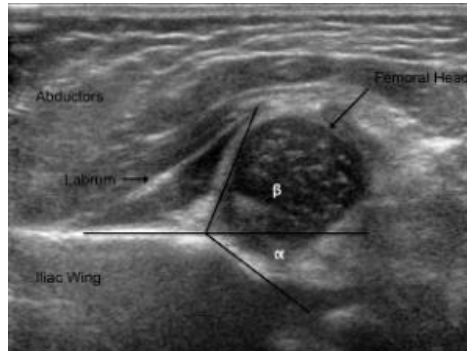
# Hip Ultrasound cont.

## ABNORMAL HIPs

**Subluxation of hip.** In the majority of cases (90%), the femoral head is displaced forward and above the acetabulum. Partial dislocation of the **hip joint (subluxation)** can occur and is typically associated with joint degeneration as with **hip dysplasia** ([www.acvs.org/small-animal/hip-luxation](http://www.acvs.org/small-animal/hip-luxation)).

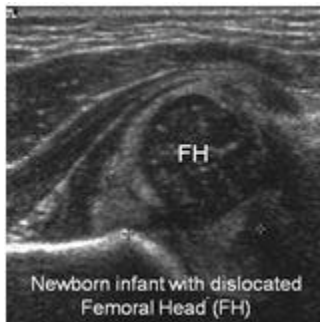

<https://www.youtube.com/watch?v=wUCHi0tUQI8>



<http://www.orthopaedicsone.com/pages/viewpage.action?pageId=30507335>

Femoral Head > 50% coverage if you are to follow the ilium straight across the femoral head. Beta angle < 60 degrees



With stress, femoral head displaced anteriorly.

## PROTOCOL

2 X COR RT HIP + 1 WITH MEASUREMENT  
2 X COR LT HIP + 1 WITH MEASUREMENT  
TRANS LT HIP  
TRANS LT HIP W/ STRESS  
TRANS RT HIP  
TRANS RT HIP W/ STRESS

## REFERENCES

*Ultrasound Examination for Detection and Assessment of Developmental Dysplasia of the Hip.* The Association for Medical Ultrasound, AIUM, 2013. Laurel, MD <http://www.aium.org/resources/guidelines/hip.pdf>

*Evaluation of Neonatal Hips for DDH.* Michelle Harris, Ann and Robert Lurie Children's Hospital, 2014. Chicago, IL.

*DDH, developmental dysplasia of hip, congenital hip dislocation, CHD.* July, 2013. Amr Abdelgawad, MD. Texas Tech University. <https://www.youtube.com/watch?v=wUCHi0tUQI8>

Unity Point Methodist, Infant Hip Ultrasound Images 11/2015 – 11/2016.

<http://www.orthopaedicsone.com/pages/viewpage.action?pageId=30507335>

\*Questions: Contact Abbie Anderson Unity Point Methodist Ultrasound x13381 or [abbie.anderson@unitypoint.org](mailto:abbie.anderson@unitypoint.org)



# Ultrasound Kidney Transplant



The following images represent a kidney transplant ultrasound exam. Additional images may be necessary for proper documentation.

## Transplant Kidney with Doppler

- Long
  - Medial
  - Mid with measurement
  - Mid with Color Doppler
  - Lateral
- Transverse
  - Superior
  - Mid with measurement
  - Inferior
- Intrarenal
  - Spectral Doppler waveforms in the interlobar or segmental arteries in superior, mid and inferior poles
    - Measure RI and acceleration times at each site
- Main Renal Artery (MRA)
  - Color Doppler demonstrating entire course of MRA (transplant to anastomosis), if possible
  - Spectral Doppler at renal hilum, mid, anastomosis and any areas of color-flow aliasing suggestive of high-velocity flow
    - Measure PSV and EDV
- Main Renal Vein (MRV)
  - Color Doppler demonstrating entire course of MRV (transplant to anastomosis), if possible
  - Spectral Doppler mid and anastomosis
- External Iliac Artery (EIA) and Vein (EIV)
  - Color and Spectral Doppler obtained proximal/cephalad to MRA and MRV anastomosis
    - Measure PSV

## Bladder

- Grey-scale
  - Long
  - Transverse
    - Color Doppler to show ureteral jet if possible
  - Ureter (if visualized) with sent location (if present)

**Angle correction is needed for all velocity measurements and should use an angle of  $\leq 60$  degrees**

Document and measure all pathology, including any surrounding fluid collections of present  
Annotate all images



# Liver Doppler



**The following images represent a liver doppler exam. Additional images may be necessary for proper documentation.**

Images should be sent to PACS and organized in the following manner:

Main Portal Vein

Right Anterior Portal Vein

Right Posterior Portal Vein

Left Portal Vein

Recannalized Umbilical Vein, if present

Main Hepatic Artery

Right Hepatic Artery

Left Hepatic Artery

Left Haptic Vein

Middle Hepatic Vein

Right Hepatic Vein

IVC

Aorta

Portosplenic Confluence

Splenic Vein

Splenic Vessels at Splenic Hilum

Relevant varices in LUQ or other

Annotate all images



# Ultrasound Lower Extremity Venous Duplex



The following images represent a lower extremity venous duplex ultrasound exam. Additional images may be necessary for proper documentation.

Gray scale images should be recorded *with and without* compression at each of the following levels:

(Transverse presentation)

- CFV
- CFV/ GSV
- PROX SFV/ PROFUNDA V JUNCTION
- PROX SFV
- MID SFV
- DIST SFV
- PROX POP V
- DIST POP V
- PROX PTV/PERO V
- MID PTV/ PERO V
- DIST PTV/ PERO V

Color flow / pulsed wave images should be recorded at each of the following levels:

When performing the pulsed wave, distal augmentation should also be performed in a normal study.

**If thrombosis is suspected, do NOT perform any augmentations.**

(Longitudinal presentation)

- CFV
  - Color
  - PW w/ distal augment
- GSV
  - Color
  - PW
- PROFUNDA V
  - Color
  - PW
- PROX SFV
  - Color
  - PW w/ distal augment

Reviewed by Dr. Hilpipre 12/2024



# Lower Ext. Venous Ultrasound Cont.

- MID SFV
  - Color
  - PW w/ distal augment
- DIST SFV
  - Color
  - PW w/ distal augment
- MID POP
  - Color
  - PW w/ distal augment
- CALF VEINS (PTV & PERO)
  - MID
    - Color

Abnormal findings and normal variants (i.e.: Bakers Cyst, hematomas, duplicated SFV) require additional images to document the complete extent of the abnormalities and variants.

The extent and location of sites where the veins fail to compress completely should be clearly recorded and generally require additional images.

If thrombus is noted in the great saphenous vein (GSV), measure distance from the saphenofemoral junction to the thrombus and also measure the length of the thrombus itself up to 5 cm (if greater than 5 cm in length, simply measure what is visible on the image and annotate ">5cm").

Annotate all images



# Lower Ext. Venous Ultrasound Cont.

- MID SFV
  - Color
  - PW w/ distal augment
- DIST SFV
  - Color
  - PW w/ distal augment
- MID POP
  - Color
  - PW w/ distal augment
- CALF VEINS (PTV & PERO)
  - MID
    - Color

Abnormal findings and normal variants (i.e.: Bakers Cyst, hematomas, duplicated SFV) require additional images to document the complete extent of the abnormalities and variants.

The extent and location of sites where the veins fail to compress completely should be clearly recorded and generally require additional images.

Annotate all images



# Ultrasound OB < 14 Weeks



The following images represent an OB less than 14 weeks ultrasound exam. Additional images may be necessary for proper documentation.

**Perform pelvic ultrasound protocol in addition to US OB less than 14 weeks protocol**

**Do transvaginal unless patient refuses or is far enough along to adequately visualize pregnancy**

Adnexa's

- Measure, color and Pulse Wave of ovaries, if visualized

Gestational sac (GS)

- Document location
  - Measure in 3 dimensions if no embryo is present
- Evaluate for presence / absence of yolk sac and embryo
  - Measure yolk sac inner to inner

Fetal Pole / Embryo

- Measure CRL
- Document presence / absence of cardiac activity with M-mode or 2D video clip

Fetal Number

- Document amnionicity and chorionicity for all multiple gestations

Anatomy

- Document appropriate first trimester fetal anatomy

Placenta

- Document presence when able to see it

Document any abnormal findings

Annotate all images



# Ultrasound OB > 14 Weeks



The following images represent a OB 2<sup>nd</sup> Trimester (Morphology) ultrasound exam. Exam may be done between 18 weeks – 20 weeks 6 days with a strong preference towards 20 weeks. Additional images may be necessary for proper documentation.

## Adnexa

- Measure, color and Pulse Wave of ovaries, if visualized

## Cervix

- Measure length
  - Transabdominal
  - Transvaginal can be performed if there is a separate TV cervix order
- Document/measure relationship between cervix and placenta

## Placenta

- Location, appearance and relationship to internal cervical os
- Umbilical cord insert documented
  - With color flow
- Umbilical cord vessels (3 vessel view)

## Measurements

- Biparietal diameter
- Head circumference
- Femoral length
- Abdominal circumference

## Fetal anatomic survey

- Head, face & neck
  - Lateral cerebral ventricle
    - Measure at the level of the atrium
  - Choroid plexus
  - Midline falx
  - Cavum septi pellucidi
    - At level of frontal horns – Do not include cerebellum/cm
  - Cine through head to include CSP – Label as “Head”
  - Cerebellum / CM
    - Measure
  - Face
  - Profile
  - Nose / Upper Lip
    - If inadequately visualized, do a cine of nose/lips

Reviewed by Dr. Hilpipte 9/2023



# OB > 14 Weeks Cont.

- Chest
  - Heart
    - Fetal heart beat using M-mode
    - Four chamber
      - With color flow
        - May image dual screen or separate
    - Left ventricular outflow tract
      - With color flow
        - May image dual screen or separate
    - Right ventricular outflow tract
      - With color flow
        - May image dual screen or separate
    - Cine clip of four chamber and outflow tracts
      - Cine clip to include stomach and heart
    - Cine clip of four chamber and outflow tracts with color flow
    - Aortic arch
      - Long with color flow
    - Diaphragm
      - Coronal showing both hemidiaphragms
    - Situs evaluation
      - Heart and stomach on dual screen
      - Annotate fetal position at time of this image
      - Ensure maternal right/left are accurately shown
- Abdomen
  - Stomach
  - Kidneys
    - Renal arteries in coronal
  - Umbilical cord insert into fetal abdomen
    - With color flow
  - Urinary bladder
    - With color flow – Document 2 umbilical arteries
- Spine
  - Cervical, thoracic, lumbar and sacral
    - Long and transverse views
    - Cine clip of transverse lumbar to sacral spine
- Extremities
  - Legs
    - Long bones of both Right and Left side
      - Feet of both Right and Left side
      - Document 5 digits per extremity whenever possible

Reviewed by Dr. Hilpipte 9/2023



# OB > 14 Weeks Cont.

- Arms
  - Long bones of both Right and Left side
    - Hands of both Right and Left side
    - Document 5 digits per extremity whenever possible
- Gender
  - When medically indicated and if patients want to know

Document any abnormalities

Annotate all images



# Ultrasound OB Follow Up/Limited



The following images represent an OB follow up ultrasound exam. Additional images may be necessary for proper documentation.

## OB Follow Up

- Used to follow up morphology, growth, presentation, AFI
  - Used when more than one thing is imaged

## Adnexa's

- Measure, color and Pulse Wave of ovaries, if visualized

## Cervix

- Measure length
  - Transvaginal (if ordered by OB physician)
  - Transabdominal (if patient refused TV)
- Document relationship between cervix and placenta

## Placenta

- Location, appearance and relationship to internal cervical os
- Umbilical cord insert documented
- Umbilical cord vessels

## Measurements

- Biparietal diameter
- Head circumference
- Femoral length
- Abdominal circumference
- Measure fetal heart rate using M-Mode

## Amniotic fluid volume

- Measure in four quadrants

## Cord Doppler's

- **To be done in the 3<sup>rd</sup> Trimester**
  - Measure RI & S/D
    - Take three measurements
      - 1: at placenta
      - 2: mid cord
      - 3: at umbilical cord insert into fetal abdomen

Document any abnormalities

Annotate all images



# Limited OB Ultrasound Cont.

The following images represent a OB limited ultrasound exam. Additional images may be necessary for proper documentation.

## OB Limited

- **Used when only ONE thing is imaged**
  - IE. Provider orders:
    - Presentation – document adnexa's, placenta, heartrate, presentation

## Adnexa's

- Measure, color and Pulse Wave of ovaries, if visualized

## Cervix

- Measure length
  - Transvaginal (if ordered by OB physician)
  - Transabdominal (if patient refused TV)
- Document relationship between cervix and placenta

## Placenta

- Location, appearance and relationship to internal cervical os
- Umbilical cord insert documented

## Measurements

- Biparietal diameter
- Head circumference
- Femoral length
- Abdominal circumference
- Measure fetal heart rate using M-Mode

## Amniotic fluid volume

- Measure in four quadrants

Document any abnormalities

Annotate all images



# Ultrasound OB Biophysical Profile



**The following images represent an OB Biophysical Profile (BPP) ultrasound exam. Additional images may be necessary for proper documentation.**

BPP consists of fetal breathing movements, discrete body movements, fetal tone and amniotic fluid volume.

**BPP is performed until all 4 components are met or until 30 minutes have passed.**

## Fetal Breathing Movement

- 1 episode (minimum) continuing for  $\geq 30$  seconds within the 30-minute BPP

## Discrete Body Movements

- 3 episodes (minimum) of discrete body or limb movements

## Fetal Tone

- 1 or more episodes of active extension and flexion

## Amniotic Fluid Volume

- 1 pocket of fluid measuring 2cm

## Scoring

- Each component of BPP meeting the criteria receives a score of 2 – for a combined score of 8
- If the specified criteria are not met for an individual component, it is scored as 0

## Document Fetal Heartbeat

Document any abnormal findings

Annotate all images



# Ultrasound Pelvic



Diagnostic & Preventative Imaging Center

The following images represent a Pelvic Transabdominal & Transvaginal ultrasound exam. Additional images may be necessary for proper documentation.

## Transabdominal

- **Should be performed with a full bladder**
  - If the patient is under 18, not sexually active or refuses TV, only do transabdominal exam

## Cervix

- Long mid
- Trans
- Document and measure any abnormalities

## Uterus

- Long
  - Document from right to left
    - Measure long and AP mid
    - Measure Endometrium mid
      - Measure at thickest portion from echogenic border to echogenic border
      - If endometrial fluid is present - measure the two separate layers endometrium
- Trans
  - Document from inferior to superior
    - Measure at mid (widest) part
- Document any abnormalities
  - Masses / Fibroids need to be measured in 3 dimensions and location documented

## Ovaries / Adnexa

- Measure ovaries in 3 dimensions (width, length, depth)
  - Obtain color and spectral Doppler
    - **For ER patients: Obtain arterial and venous waveforms whenever possible**
  - Document and Measure any abnormalities (cysts, dermoids, endometriomas, ect.)
- If unable to visualize ovaries document adnexa's in two planes
  - Document and measure any abnormalities

## Cul-de-Sac

- Long image
- Document and measure any abnormalities

Reviewed by Dr. Hilpipe 10/2023



# Pelvic Ultrasound Cont.

## Transvaginal

- **Should be performed with an empty bladder**

## Cervix

- Sagittal
- Coronal
- Document and measure any abnormalities

## Uterus

- Sagittal
  - Document from right to left
    - Measure long and AP mid
    - Measure Endometrium mid
      - Measure at thickest portion from echogenic border to echogenic border
      - If endometrial fluid is present - measure the two separate layers endometrium
- Coronal
  - Document from inferior to superior
    - Measure at mid (widest) part
- Document any abnormalities
  - Masses / Fibroids need to be measured in 3 dimensions and location documented

## Ovaries / Adnexa

- Measure ovaries in 3 dimensions (width, length, depth)
  - Obtain color and spectral Doppler
    - **For ER patients: Obtain arterial and venous waveforms whenever possible**
  - Document and Measure any abnormalities (cysts, dermoids, endometriomas, etc.)
- If unable to visualize ovaries document adnexa's in two planes
  - Document and measure any abnormalities

## Cul-de-Sac

- Sagittal image
- Document and measure any abnormalities

Annotate all images

**For pelvic ultrasounds performed for IUD Placement or Rechecks and Postmenopausal Bleeding:**

## Uterus/Endometrium

- Include 3D images, if available

Reviewed by Dr. Hilpipe 10/2023



# Pelvic Ultrasound Cont.

The following images represent Pelvis for Fertility / Follicle Tracking ultrasound exams. Additional images may be necessary for proper documentation.

CPT 76830 US Pelvis Transvaginal: To be used at the first evaluation and when uterine structures (such as the endometrium) are requested in addition to the ovaries

**For fertility exams, the following detail should be documented *in addition to the Pelvic Ultrasound Transvaginal protocol*:**

## Ovaries / Adnexa

- Document the number of follicles in each ovary and indicate
  - How many are less than 10 mm
  - How many are 10mm or greater
  - Measure, at minimum, the 3 largest follicles in at least 2 perpendicular dimensions

## Uterus and Endometrium

- Describe the appearance of the endometrium

Document and measure all pathology

Annotate all images

CPT 76857 US Pelvis Limited: To be used for repeat follicle evaluation when the provider is requesting follicles/ovaries ONLY

## Ovaries / Adnexa

- Measure ovaries in 3 dimensions (width, length, depth)
- Obtain color and spectral doppler
- Document and measure any abnormalities
- Document the number of follicles in each ovary and indicate
  - How many are less than 10 mm
  - How many are 10mm or greater
  - Measure, at minimum, the 3 largest follicles in at least 2 perpendicular dimensions

Document and measure all pathology

Annotate all images

Reviewed by Dr. Hilpipe 10/2023



# Ultrasound Renal/Bladder



The following images represent a renal ultrasound exam. Additional images may be necessary for proper documentation.

## Right Kidney

- Long
  - Medial
  - Mid with measurement
  - Mid with Color Doppler
  - Lateral
- Trans
  - Superior
  - Mid with measurement
  - Inferior

## Left Kidney

- Long
  - Medial
  - Mid with measurement
  - Mid with Color Doppler
  - Lateral
- Trans
  - Superior
  - Mid with measurement
  - Inferior

## Bladder

- Long
- Trans
- Show ureteral jets

Vessels (With color Doppler, only measure diameter if abnormal in appearance)

- IVC
- Aorta
- Common iliac origins

Document and measure all pathology  
Annotate all images

Reviewed by Dr. Hilpipre 9/2023

\*Subject to change at the discretion of the radiologist due to clinical circumstances.\*



# Bladder Ultrasound Cont.

**The following images represent a Pre- and Post-Void Bladder ultrasound exam. Additional images may be necessary for proper documentation.**

Right Kidney

- Long mid

Left Kidney

- Long mid

Bladder

- Pre-Void
  - Long
    - With measurements
  - Trans
    - With measurement
    - Document ureteral jets
- Post-Void
  - Long
    - With measurements
  - Trans
    - With measurement

If hydronephrosis is present, contact ordering physician's office to obtain order to complete a renal ultrasound.

Document and measure all pathology

Annotate all images



# Ultrasound Renal Artery



The following images represent a renal artery ultrasound exam. Additional images may be necessary for proper documentation.

## Aorta

- Long image with color and Spectral Doppler
  - Measure Peak Systole

## Right Kidney

- Long
  - Medial
  - Mid with measurement
  - Mid with Color Doppler
  - Lateral
- Trans
  - Superior
  - Mid with measurement
  - Inferior
- Main Renal Artery (MRA)
  - Proximal, Mid, Distal with color and Spectral Doppler
    - Measure Peak Systole at each site
      - Peak Systole should also be recorded at any site of color aliasing or suspected stenosis
- Main Renal Vein (MRV)
  - Document patency with color and Spectral Doppler
- Intrarenal
  - Superior, Mid and Inferior Segmental arteries
    - Measure RI and Acceleration times at each site

## Left Kidney

- Long
  - Medial
  - Mid with measurement
  - Mid with Color Doppler
  - Lateral
- Trans
  - Superior
  - Mid with measurement
  - Inferior



# Renal Artery Ultrasound Cont.

- Main Renal Artery (MRA)
  - Proximal, Mid, Distal with color and Spectral Doppler
    - Measure Peak Systole at each site
      - Peak Systole should also be recorded at any site of color aliasing or suspected stenosis
- Main Renal Vein (MRV)
  - Document patency with color and Spectral Doppler
- Intrarenal
  - Superior, Mid and Inferior Segmental arteries
    - Measure RI and Acceleration times at each site

## Bladder

- Long
- Trans
- Show ureteral jets

**All Doppler angles are to not exceed 60 degrees**

Document and measure all pathology

Annotate all images



# Ultrasound Scrotum (Adult)



The following images represent a scrotum ultrasound exam. Additional images may be necessary for proper documentation.

## Right Teste

- Trans
  - Superior
  - Mid – with measurement, color and Doppler
  - Inferior
- Long
  - Medial
  - Mid – with measurement and color
  - Lateral

## Right Epididymis

- Document head, body and tail
- Color image of tail

## Left Teste

- Trans
  - Superior
  - Mid – with measurement, color and Doppler
  - Inferior
- Long
  - Medial
  - Mid – with measurement and color
  - Lateral

## Left Epididymis

- Document head, body and tail
- Color image of tail

## Trans Mid

- Trans to show echo texture and compare color

## Varicocele

- Image with measurement and Valsalva image with measurement

Measure and use color on all abnormal anatomy

Annotate all images



# Ultrasound Spine



**The following images represent a spine exam. Additional images may be necessary for proper documentation.**

Spine exams should be performed with the patient in a prone position.

Images over area of concern

- Trans
- Long

Panoramic or dual image from T12 to S5 and each vertebrae labeled

Trans images

- T12
- L1
- L2
- L3

Long image at location where conus ends with each vertebrae labeled

Trans cine or m-mode showing movement of filum

Long image of filum with thickness measured

Annotate all images



# Ultrasound Thyroid



The following images represent a thyroid ultrasound exam. Additional images may be necessary for proper documentation.

## Right Lobe

- Trans
  - Superior
  - Mid – with measurement and color Doppler
  - Inferior
  - Cine – Superior to Inferior
- Long
  - Medial
  - Mid – with measurement and color Doppler
  - Lateral
  - Cine – Medial to Lateral

## Isthmus

- Mid – with measurement

## Left Lobe

- Trans
  - Superior
  - Mid – with measurement and color Doppler
  - Inferior
  - Cine – Superior to Inferior
- Long
  - Medial
  - Mid – with measurement and color Doppler
  - Lateral
  - Cine – Medial to Lateral

## Nodule Evaluation

- 3-plane measure in Long and Trans on sequential images (or split screen) per nodule
  - AP & Trans measurements should be on the Trans image (easier to determine “taller-than-wide” or “wider-than-tall”)
  - Do not measure multiple nodules on the same image
- Color Doppler on each nodule
- Cine any nodule not fully included on standard cine images of each lobe
- Image nodules from Upper Pole to Lower Pole, annotate as “Upper” or “Superior”, “Mid”, and “Lower” or “Inferior”
  - If applicable, combo annotations such as “Mid/Inf” are also ok

Reviewed by Dr. Hilpipre 9/2023



# Thyroid Ultrasound Cont.

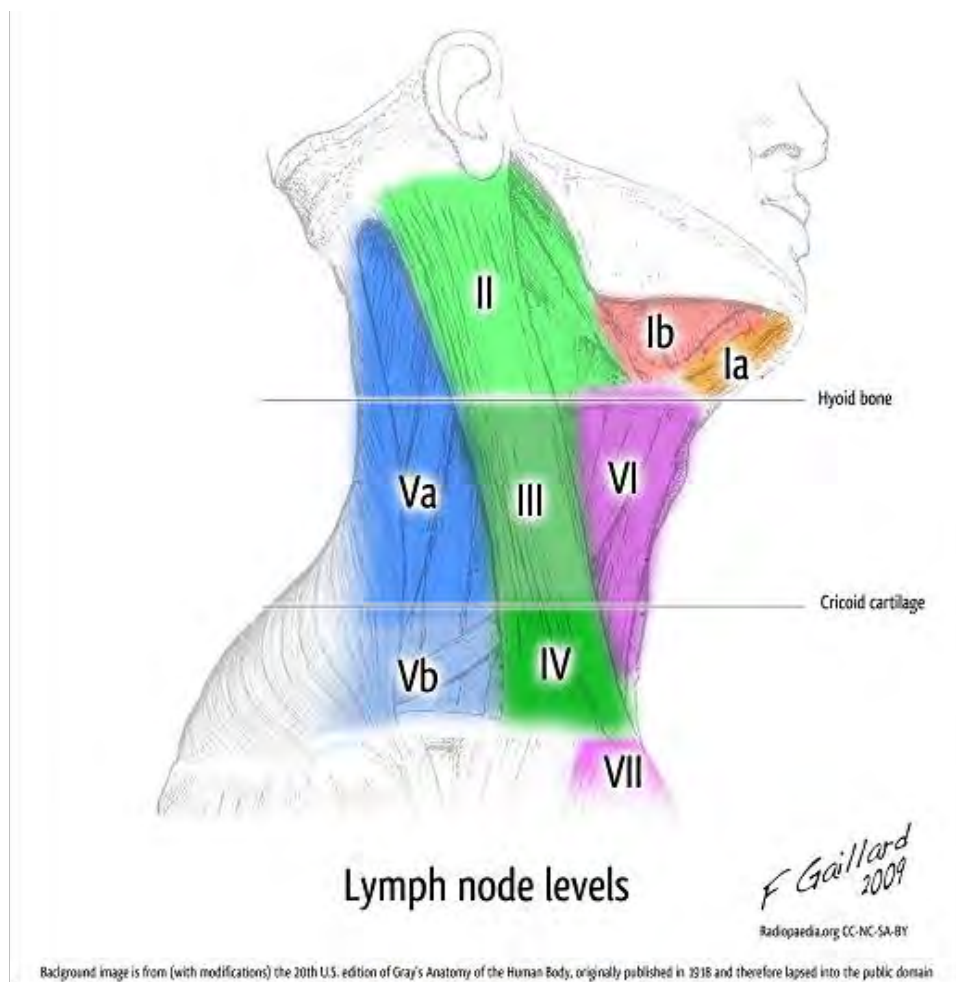
- Sequentially number nodules from Right to Isthmus to Left
  - For example, 2 nodules on Right (“Nodule 1” and “Nodule 2”) and 1 nodule on the Left (“Nodule 3”)
- Still images should show any calcification in a nodule (important for TI-RADS)
- Measure up to 2 of the most suspicious nodules per lobe on baseline
  - Most suspicious features: solid/nearly solid, hypoechoic, taller-than-wide, calcifications
  - Least suspicious: mixed cystic/solid, spongiform
  - If study is for a discretely palpable nodule or cyst, that should also be measured
- For follow up exams, measure all previously described TI-RADS 3/4/5 nodules in radiologist report and any new nodules meeting criteria in this protocol
- Do not measure any cyst or nodule 4mm or smaller
- For colloid cysts, only measure largest per lobe (if there are no solid nodules)

## Post-Thyroidectomy Evaluation:

- Trans, Long & Trans Cine of thyroid bed(s) – 3-plane measure & color Doppler any residual thyroid tissue or nodularity
- Be familiar with Lymph Node Zones in attached illustration (see next page)
  - Anatomic boundary descriptions: <https://radiopaedia.org/articles/lymph-node-levels-of-the-neck?lang=us>
- Scan all bilateral neck zones
- Only image & measure suspicious nodes (unless previously recommended for follow up)
  - Suspicious node features include: round shape, loss of fatty hilum, irregular cortex, heterogeneity, calcifications, cystic spaces & flow outside of hilum
  - Lymph node size is less reliable, but image any node  $\geq 1$  cm on Trans images ( $\geq 1$  cm in AP or Left-Right dimension)
  - If no borderline or suspicious nodes are identified, provide generic still images of bilateral neck at Zone 2 and document this in your notes
- Node images should include Trans, Long & Trans Cine with 3-plane measurements and Zone annotation
  - Do not routinely provide cine clips showing multiple Zones – clips should only be for individual nodes
- If a node is between Zones, for example it may be annotated as “Zone 2/3”
- Image up to 2 abnormal nodes per Zone



# Thyroid Ultrasound Cont.



Case courtesy of Assoc Prof Frank Gaillard, <https://radiopaedia.org/> Radiopaedia.org.  
From the case <https://radiopaedia.org/cases/9618> ID: 9618

Reviewed by Dr. Hilpibre 9/2023

\*Subject to change at the discretion of the radiologist due to clinical circumstances.\*



# Transcranial Doppler (TCD)



**The following images represent a transcranial doppler exam. Additional images may be necessary for proper documentation.**

TCD Exam should be performed with the patient in the supine position. The patient should be awake, quiet and calm.

Obtain color and spectral doppler images from each of the locations listed below:

## Right Transtemporal Window

- RT MCA: Right Middle Cerebral Artery
- RT PCA, P1 and P2: Right Posterior Cerebral Artery, segments P1 and P2
- RT ACA: Right Anterior Cerebral Artery

## Left Transtemporal Window

- LT MCA: Left Middle Cerebral Artery
- LT PCA, P1 and P2: Left Posterior Cerebral Artery, segments P1 and P2
- LT ACA: Left Anterior Cerebral Artery

## Transforaminal Window

- RT VA: Right Vertebral Artery
- LT VA: Left Vertebral Artery
- BA: Basilar Artery

## Right Submandibular Window

- RT ICA Distal: Right Internal Carotid Artery

## Left Submandibular Window

- LT ICA Distal: Left Internal Carotid Artery

Thoroughly interrogate each vessel to identify any signs of stenosis, occlusion or other abnormality

Document the highest MFV (Mean Flow Velocity) for each site

Annotate all images



# Ultrasound Upper Extremity Venous Duplex



The following images represent an upper extremity venous duplex ultrasound exam. Additional images may be necessary for proper documentation.

Gray scale images should be recorded *with and without* compression at each of the following levels:

(Transverse presentation)

- IJV
  - PROX
  - MID
  - DIST
- DIST SUBCLAVIAN V (IF ABLE)
- AXILLARY V
- BRACHIAL (TO LEVEL OF ANTECUBITAL FOSSA)
  - PROX
  - MID
  - DIST
- BASILIC V (TO LEVEL OF ANTECUBITAL FOSSA)
  - PROX
  - MID
  - DIST
- CEPHALIC V (TO LEVEL OF ANTECUBITAL FOSSA)
  - PROX
  - MID
  - DIST

Color flow / pulsed wave images should be recorded at each of the following levels:

When performing the pulsed wave, distal augmentation should also be performed in a normal study.

**If thrombosis is suspected, do NOT perform any augmentations.**

(Longitudinal presentation)

- IJV
  - PROX, MID, DIST
    - Color at all
    - PW at MID
- SUBCLAVIAN V
  - PROX, MID, DIST



# Upper Ext. Venous Ultrasound Cont.

- Color at all
  - PW at all
- AXILLARY V
  - Color
  - PW w/ augment
- BRACHIAL V
  - PROX, MID, DIST
    - Color at all
    - PW w/ augment at MID
- BASILIC V
  - PROX, MID, DISTAL
    - Color at all
    - PW w/ augment at MID
- CEPHALIC V
  - PROX, MID, DISTAL
    - Color at all
    - PW w/ augment at MID

Abnormal findings and normal variants require additional images to document the complete extent of the abnormalities and variants.

The extent and location of sites where the veins fail to compress completely should be clearly recorded and generally require additional images.

Annotate all images



# Radiologist Glove Sizes



Dr. Becker	7.5	R. Miller	6.5
C. Burch	6.5	Dr. Myneni	7 or 7.5
Dr. Choi	7	Dr. Peters	7.5
Dr. Essenmacher	7.5	Dr. Rappleye	7
A. Gieseke	6.5	Dr. Riebe	7.5
Dr. Hilpipre	7.5	Dr. Smith	7
Dr. Holdsworth	7.5	Dr. Soe	8
Dr. Hurlbut	8	Dr. Steinberg	8.5
Dr. Jabour	8	Dr. Stone	8
Dr. Julian	7.5	Dr. Stradling	7.5
Dr. Karibo	7.5	Dr. Waddell	7.5
Dr. Kaufman	8	Dr. Westercamp	7
Dr. King	8.5	Dr. Wolford	7.5
Dr. Kliewer	7.5	Amanda	6.5
Dr. Lacey	7.5	Emily	6.5
Dr. Liudahl	7.5	Yvette	6.5
Dr. Magill	7.5		