

MRI Brain



Diagnostic & Preventative Imaging Center

Without Contrast:

1. Localizer
2. Sagittal T1 - 5 mm slice thickness; Cover whole brain ear to ear
3. Axial DWI - 5 mm slice thickness; Parallel to corpus callosum; Cover vertex to foramen magnum
4. Axial T2 - 5 mm slice thickness; Same coverage and orientation as #3
5. Axial T2* - 5 mm slice thickness; Same coverage and orientation as #3
6. Coronal T2 - 5 mm slice thickness; Cover globes through occipital lobes
7. Sagittal 3D FLAIR - Send thin sagittal images to PACS as well as 5 mm Axial slices in same plane as #3
8. Axial 3D T1 - NO OBLIQUE; Send thin axial images to PACS

Without and With Contrast:

1. Localizer
2. Sagittal T1 - 5 mm slice thickness; Cover whole brain ear to ear
3. Axial DWI - 5 mm slice thickness; Parallel to corpus callosum; Cover vertex to foramen magnum
4. Axial T2 - 5 mm slice thickness; Same coverage and orientation as #3
5. Axial T2* - 5 mm slice thickness; Same coverage and orientation as #3
6. Coronal T2 - 5 mm slice thickness; Cover globes through occipital lobes
7. Axial T1 Fat Sat - 5 mm slice thickness; Same coverage and orientation as #3

*****Inject contrast*****

8. +C Sagittal 3D FLAIR - Send thin sagittal images to PACS as well as 5 mm Axial slices in same plane as #3
9. +C Axial T1 Fat Sat - 5 mm slice thickness; Same coverage and orientation as #3
10. +C Axial 3D T1 - NO OBLIQUE; Send thin axial images to PACS

Notes:

- If seizure is a listed indication, replace the Coronal T2 with 2 mm Oblique Coronal T2 through the temporal lobes.
- If exam is follow-up of a primary brain tumor (astrocytoma, oligodendroglioma, glioblastoma multiforme [GBM]), add MR Perfusion. These patients should predominantly be scheduled at sites where perfusion is available.

Indications

Without Contrast:
(70551)

Headaches, TIA or Stroke Symptoms, Tremors, Seizure (chronic),
Demyelinating Disease/Multiple Sclerosis (asymptomatic follow-up)

With & Without Contrast:
(70553)

Tumor, Infection, Seizure (new onset), Demyelinating Disease/Multiple
Sclerosis (new evaluation or symptoms)

****Values will vary between machines. Use your own discretion when selecting values.****

Reviewed by Dr. Holdsworth 10/2020

MRI Brain Cranial Nerves



Diagnostic & Preventative Imaging Center

1. Localizer
 2. Sagittal T1 - 5 mm slice thickness; Cover whole brain ear to ear
 3. Axial DWI - 5 mm slice thickness; Parallel to corpus callosum; Cover vertex to foramen magnum
 4. Axial T2 - 5 mm slice thickness; Same coverage and orientation as #3
 5. Axial T2* - 5 mm slice thickness; Same coverage and orientation as #3
 6. Axial T2 High Res - Cranial Nerve - See coverage below
 7. Axial T1 Thin - Cranial Nerve - 2 mm slice thickness; See coverage below
- **Inject contrast*****
8. +C Sagittal 3D FLAIR - Send thin sagittal images to PACS as well as 5 mm Axial slices in same plane as #3
 9. +C Axial T1 Fat Sat Thin - Cranial Nerve - 2 mm slice thickness; See coverage below
 10. +C Coronal T1 Fat Sat Thin - Cranial Nerve - 2 mm slice thickness; See coverage below
 11. +C Axial 3D T1 - NO OBLIQUE; Send thin axial images to PACS

Notes:

*****Field of view for cranial nerve sequences:***

- For Hearing Loss, Tinnitus, or Dizziness/Vertigo, center coverage on the Internal Auditory Canals (IACs)
- For all other listed indications, coverage as follows:

Axial: Orbits through skull base/base of the pons

Coronal: Mid orbits through 4th ventricle/back of the brainstem

Indications

With & Without Contrast:
(70553)

Hearing Loss, Tinnitus, Dizziness/Vertigo, CP Angle Tumor, Facial Pain and/or Numbness, Cranial Nerve Palsy, Facial Paralysis, Bell's Palsy

*****Values will vary between machines. Use your own discretion when selecting values.*****

Reviewed by Dr. Holdsworth 10/2020

Subject to change at the discretion of the radiologist due to clinical circumstances.

MRI Brain Shunt Protocol



Diagnostic & Preventative Imaging Center

1. Localizer
2. Axial Single Shot Fast T2 - 5 mm slice thickness
3. Coronal Single Shot Fast T2 - 5 mm slice thickness
4. Sagittal Single Shot Fast T2 - 5 mm slice thickness

Note:

- This exam is ONLY to evaluate for changes in ventricular size, typically in the ER or inpatient setting

Indications

Without Contrast:
(70551 - Reduced charge)

Shunt Malfunction, Assess Ventricular Size

****Values will vary between machines. Use your own discretion when selecting values.****

Reviewed by Dr. Holdsworth 10/2020

Subject to change at the discretion of the radiologist due to clinical circumstances.

MRI Pituitary



Diagnostic & Preventative Imaging Center

1. Localizer
2. Axial DWI - Parallel to corpus callosum; Cover vertex to foramen magnum
3. Sagittal 3D FLAIR - Send thin sagittal images to PACS as well as 5 mm Axial slices in same plane as #2
4. Sagittal T1 Thin - Pituitary - 2 mm slice thickness; Cover entire pituitary/sella
5. Coronal T2 Thin - Pituitary - 2 mm slice thickness; Cover entire pituitary/sella
6. Coronal T1 Thin - Pituitary - 2 mm slice thickness; Cover entire pituitary/sella

*****Inject contrast*****

7. +C Coronal T1 Dynamic - Pituitary - 2 mm slice thickness; Cover entire pituitary/sella
8. +C Sagittal T1 Thin - Pituitary - 2 mm slice thickness; Cover entire pituitary/sella

Note:

- If indication for exam includes additional symptoms beyond the listed indications below (i.e. headaches, altered mental status, etc.), additional whole brain sequences may be required. Check with Radiologist.
- If obvious mass or tumor is noted, include +C Axial 3D T1 whole brain.

Indications

With & Without Contrast:
(70553)

Pituitary Tumor, Growth Hormone Deficiency, Short Stature, Precocious Puberty, Hyperprolactinemia, Craniopharyngioma, Increased Prolactin, Galactorrhea, Amenorrhea, Micro/Macro Adenoma, Diabetes Insipidus

****Values will vary between machines. Use your own discretion when selecting values.****

Reviewed by Dr. Holdsworth 10/2020

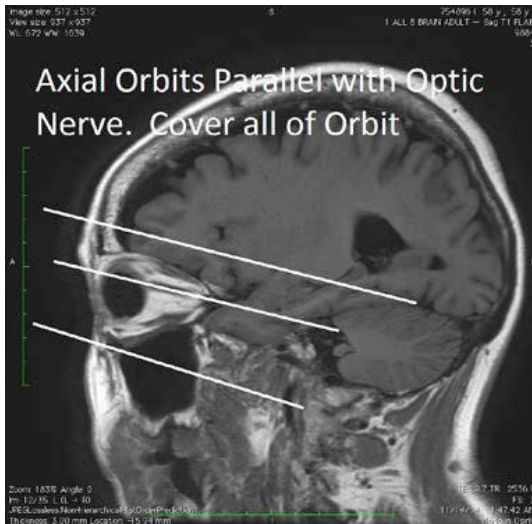
Subject to change at the discretion of the radiologist due to clinical circumstances.

MRI Brain and Orbits



Diagnostic & Preventative Imaging Center

1. Localizer
 2. Sagittal T1 - 5 mm slice thickness; Cover whole brain ear to ear
 3. Axial DWI - 5 mm slice thickness; Parallel to corpus callosum; Cover vertex to foramen magnum
 4. Axial T2 - 5 mm slice thickness; Same coverage and orientation as #3
 5. Axial T2* - 5 mm slice thickness; Same coverage and orientation as #3
 6. Coronal T2 Fat Sat Thin - Orbit - 3 mm slice thickness; Cover front of globes through base of clivus
 7. Axial T2 High Res - Orbit - Cover entire orbit parallel to optic nerve (see example below)
 8. Axial T1 Fat Sat Thin - Orbit - 3 mm slice thickness; Same coverage as #7
- **Inject contrast*****
9. +C Sagittal 3D FLAIR - Send thin sagittal images to PACS as well as 5 mm Axial slices in same plane as #3
 10. +C Axial T1 Fat Sat Thin - Orbit - 3 mm slice thickness; Same coverage as #7
 11. +C Coronal T1 Fat Sat Thin - Orbit - 3 mm slice thickness; Same coverage as #6
 12. +C Axial 3D T1 - NO OBLIQUE; Send thin axial images to PACS



*Image courtesy University of Wisconsin

Indications

With & Without Contrast: Vision Changes, Optic Neuritis
(70553 & 70543)

*****Values will vary between machines. Use your own discretion when selecting values.*****

Reviewed by Dr. Holdsworth 10/2020

Subject to change at the discretion of the radiologist due to clinical circumstances.

MRI TMJ

(Temporomandibular Joint)



Diagnostic & Preventative Imaging Center

Without Contrast:

1. 3 Plane Localizer
2. Axial T1 Quick Localizer

CLOSED JAW

• Coronal: PARALLEL to condyles

- | | | | |
|-----------|--------------------|-------|----------|
| 3. LEFT: | Coronal T1 Oblique | 3/0.2 | 9 slices |
| 4. RIGHT: | Coronal T1 Oblique | 3/0.2 | 9 slices |

• Sagittal: MEDIAL Oblique 20° - 30° off Sagittal Plane

- | | | | |
|------------------|-----------------------------|-------|----------|
| 5. LEFT & RIGHT: | Sagittal PD Oblique | 3/0.2 | 9 slices |
| 6. LEFT & RIGHT: | Sagittal T2 Fat Sat Oblique | 3/0.2 | 9 slices |

OPEN JAW

- | | | | |
|------------------|---------------------|-------|----------|
| 7. LEFT & RIGHT: | Sagittal PD Oblique | 3/0.2 | 9 slices |
|------------------|---------------------|-------|----------|

Without and With Contrast:

1. 3 Plane Localizer
2. Axial T1 Quick Localizer

CLOSED JAW

• Coronal: PARALLEL to condyles

- | | | | |
|-----------|--------------------|-------|----------|
| 3. LEFT: | Coronal T1 Oblique | 3/0.2 | 9 slices |
| 4. RIGHT: | Coronal T1 Oblique | 3/0.2 | 9 slices |

• Sagittal: MEDIAL Oblique 20° - 30° off Sagittal Plane

- | | | | |
|------------------|-----------------------------|-------|----------|
| 5. LEFT & RIGHT: | Sagittal PD Oblique | 3/0.2 | 9 slices |
| 6. LEFT & RIGHT: | Sagittal T2 Fat Sat Oblique | 3/0.2 | 9 slices |
| 7. LEFT & RIGHT: | Sagittal T1 Fat Sat Oblique | 3/0.2 | 9 slices |

OPEN JAW

- | | | | |
|------------------|---------------------|-------|----------|
| 8. LEFT & RIGHT: | Sagittal PD Oblique | 3/0.2 | 9 slices |
|------------------|---------------------|-------|----------|

****Inject contrast****

CLOSED JAW

• Coronal: PARALLEL to condyles

- | | | | |
|-------------|--------------------|-------|----------|
| 9. +C LEFT: | Coronal T1 Fat Sat | 3/0.2 | 9 slices |
|-------------|--------------------|-------|----------|

Continued on next page

Reviewed by Drs. Holdsworth, Hurlbut & Riebe 10/2023

Subject to change at the discretion of the radiologist due to clinical circumstances.

MRI TMJ Cont.

10. +C RIGHT: Coronal T1 Fat Sat 3/0.2 9 slices

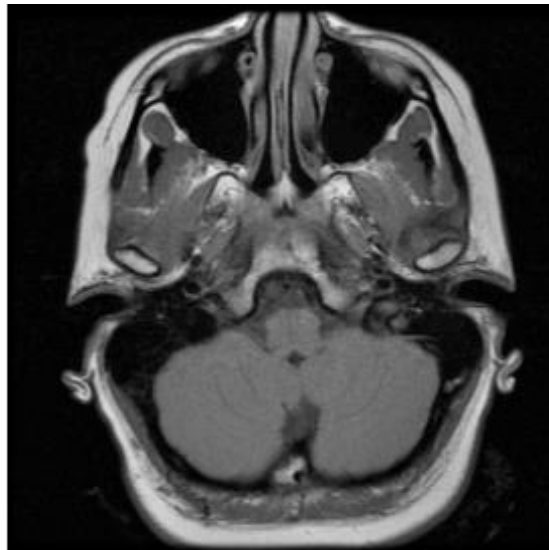
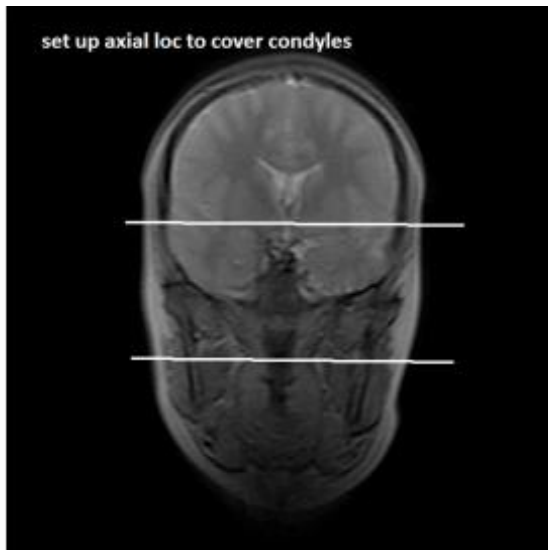
• **Sagittal: MEDIAL Oblique 20° - 30° off Sagittal Plane**

11. +C LEFT & RIGHT: Sagittal T1 Fat Sat Oblique 3/0.2 9 slices

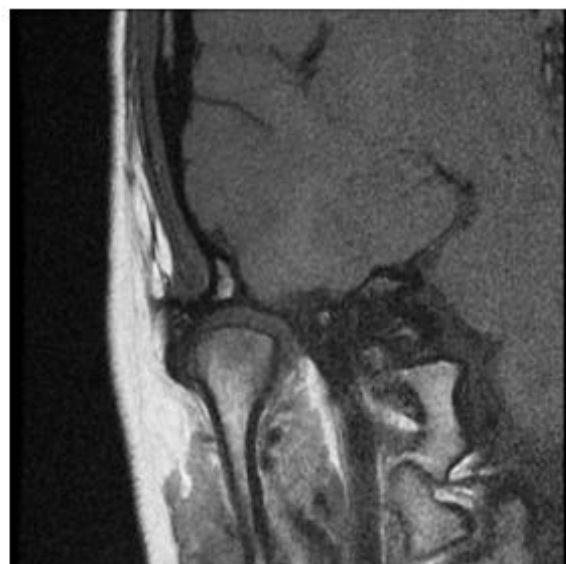
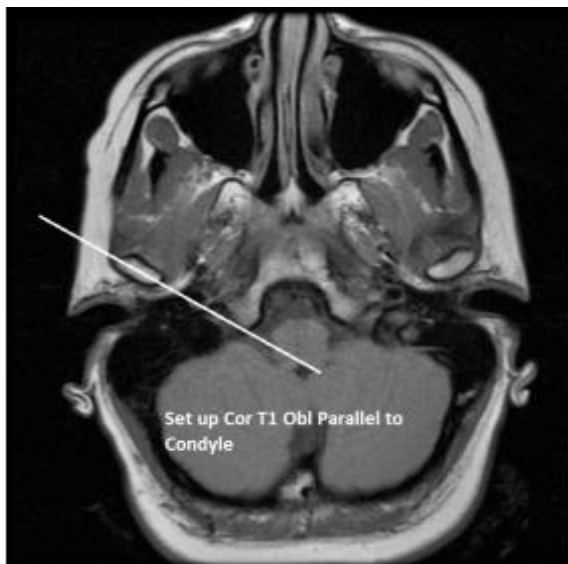
Note:

◦The Open and Closed Oblique PDs are often the most helpful for diagnosis, so making sure those look optimal is appreciated.

TMJ Set Up: Set up axial loc to cover condyles



TMJ Coronal: Set up Cor T1 Obl Parallel to Condyle



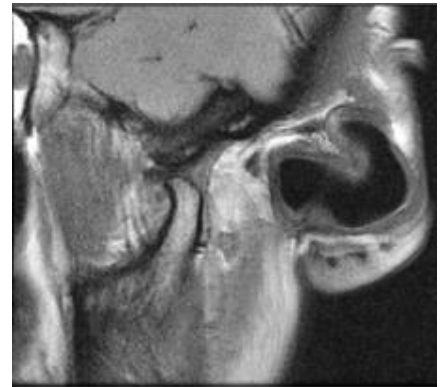
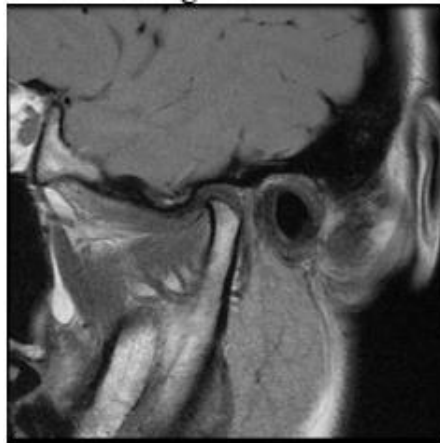
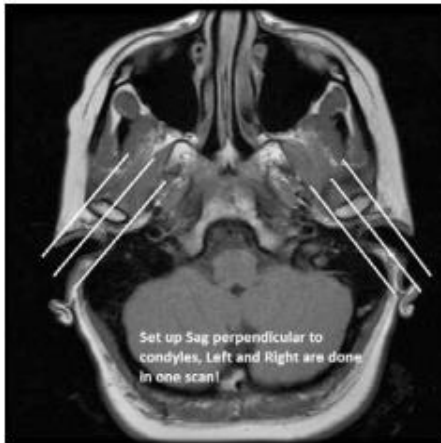
Continued on next page

Reviewed by Drs. Holdsworth, Hurlbut & Riebe 10/2023

Subject to change at the discretion of the radiologist due to clinical circumstances.

MRI TMJ Cont.

TMJ Sagittal: Set up Sag perpendicular to condyles, Left and Right are done in one scan



Indications

Without Contrast:
(70336)

TMJ Dysfunction or Pain, Inflammatory- or Osteo-Arthritis of TMJ, Prior TMJ Dislocation, Prior TMJ Surgery

Without & With Contrast:
(70336)

Inflammatory Arthritis, Synovitis, Mass

****Values will vary between machines. Use your own discretion when selecting values.****

Reviewed by Drs. Holdsworth, Hurlbut & Riebe 10/2023

Subject to change at the discretion of the radiologist due to clinical circumstances.

MRI Mandible



Diagnostic & Preventative Imaging Center

1. Localizer
2. Axial T1 - 3 mm slice thickness; Cover from above temporomandibular joint through entire mandible
3. Axial T2 Fat Sat - 3 mm slice thickness; Same coverage as #2
4. Coronal T1 - 3 mm slice thickness; Include entire mandible from symphysis through temporomandibular joints
5. Coronal T1 Fat Sat - 3 mm slice thickness; Same coverage as #4
6. Coronal T2 Fat Sat - 3 mm slice thickness; Same coverage as #4
7. Sagittal T1 Oblique - 3 mm slice thickness; Angle with affected mandible
8. Sagittal T2 FS Oblique - 3 mm slice thickness; Angle with affected mandible
- **Inject contrast***
9. +C Axial T1 Fat Sat - 3 mm slice thickness; Same coverage as #2
10. +C Coronal T1 Fat Sat - 3 mm slice thickness; Same coverage as #4
11. +C Sagittal T1 Fat Sat Oblique - 3 mm slice thickness; Angle with affected mandible

Indications

With & Without Contrast: Osteomyelitis, Mass/Tumor
(70543)

****Values will vary between machines. Use your own discretion when selecting values.****

Reviewed by Dr. Holdsworth 10/2020

Subject to change at the discretion of the radiologist due to clinical circumstances.

MRI Soft Tissue Neck



Diagnostic & Preventative Imaging Center

1. Localizer
2. Sagittal T1 - 5 mm slice thickness; Cover skin to skin
3. Axial T1 - 5 mm slice thickness; Cover from above sella to the sternal notch
4. Axial T2 Fat Sat - 5 mm slice thickness; Same coverage as #3
5. Axial DWI - 5 mm slice thickness; Same coverage as #3
6. Coronal T2 Fat Sat - 5 mm slice thickness; Cover from lips to posterior aspect of the neck
7. Coronal T1 - 5 mm slice thickness; Same coverage as #6
8. Coronal T1 Fat Sat - 5 mm slice thickness - Same coverage as #6

*****Inject contrast*****

9. +C Axial T1 Fat Sat - 5 mm slice thickness - Same coverage as #3
10. +C Coronal T1 Fat Sat - 5 mm slice thickness; Same coverage as #6

Note:

◦Listed coverage is for most indications. Certain tumors of the nasal cavity, sinuses, or pharynx may require changes in coverage and/or additional sequences. Check with Radiologist if any questions.

Indications

With & Without Contrast: Tumor/Mass, Adenopathy, Infection/Cellulitis, Salivary Gland Abnormality
(70543)

****Values will vary between machines. Use your own discretion when selecting values.****

Reviewed by Dr. Holdsworth 10/2020

Subject to change at the discretion of the radiologist due to clinical circumstances.

MRI Brachial Plexus

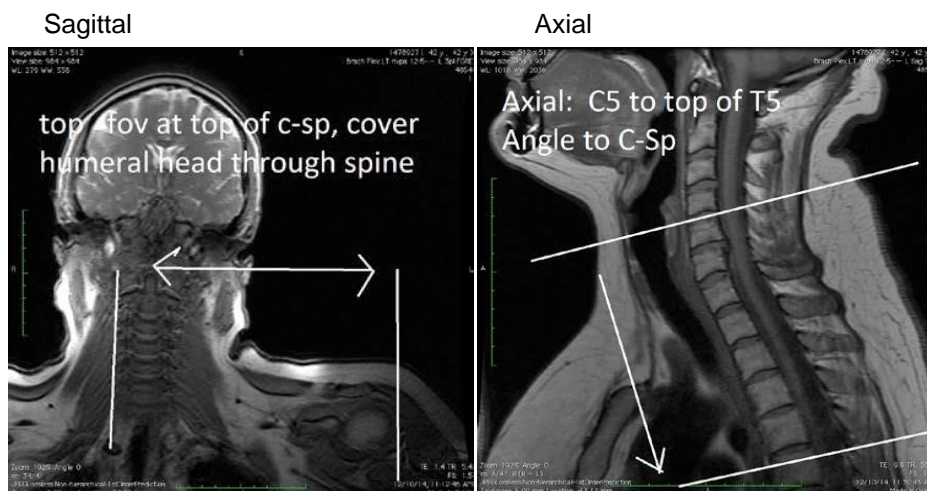


Diagnostic & Preventative Imaging Center

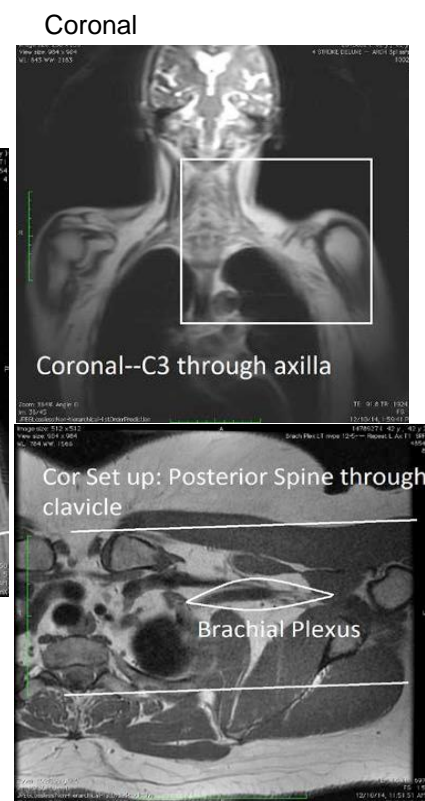1. Localizer
2. Coronal T1 - 4 mm slice thickness; Cover spine through axilla from clavicle through posterior spine (see below)
3. Coronal T1 Fat Sat - 4 mm slice thickness; Same coverage as #2
4. Coronal T2 Fat Sat or Coronal STIR - 4 mm slice thickness; Same coverage as #2
5. Sagittal T1 - 4 mm slice thickness; Cover spine through humeral head (see below)
6. Axial T1 - 4 mm slice thickness; Angle with spine; Cover from above C5 to below T5 (see below)
7. Axial T2 Fat Sat - 4 mm slice thickness - Same coverage as #6

****Inject contrast****

8. +C Coronal T1 Fat Sat - 4 mm slice thickness; Same coverage as #2
9. +C Axial T1 Fat Sat - 4 mm slice thickness; Same coverage as #6
10. +C Sagittal T1 Fat Sat - 4 mm slice thickness; Same coverage as #5



*Images courtesy University of Wisconsin



Indications

With & Without Contrast:
(73220)

Brachial Plexopathy, Upper Extremity Pain or Weakness, Tumor/Mass

****Values will vary between machines. Use your own discretion when selecting values.****

Reviewed by Dr. Holdsworth 10/2020

Subject to change at the discretion of the radiologist due to clinical circumstances.

MRI C-Spine



Diagnostic & Preventative Imaging Center

1. Localizer
2. Sagittal T2 - 4 mm slice thickness; Cover spine side to side; Field of view: Skull base to T2
3. Sagittal STIR - 4 mm slice thickness; Same coverage as #2
4. Sagittal T1 - 4 mm slice thickness; Same coverage as #2
5. Axial T2 - 4 mm slice thickness; Cover C1 through T1
6. Axial T2* - 4 mm slice thickness; Same coverage as #5
7. Axial T1 - 4 mm slice thickness; Same coverage as #5

****Inject contrast - if contrast ordered****

8. +C Sagittal T1 Fat Sat - 4 mm slice thickness; Same coverage as #2
9. +C Axial T1 - 4 mm slice thickness; Same coverage as #5

Notes:

- If Discitis/Osteomyelitis is a listed indication, include Sagittal DWI sequence.
- If Stroke/Infarction is a listed indication, include both Sagittal and Axial DWI sequences.
- If Scoliosis is present, include Coronal T2.
- If the exam is for Acute Trauma, include a non-contrast Sagittal T2 gradient.

Indications

****A history of cervical or thoracic spine surgery DO NOT require contrast****

Without Contrast: (72141)	Neck Pain, Radiculopathy, Upper Extremity Numbness, Tingling or Pain, Demyelinating Disease/Multiple Sclerosis (asymptomatic follow-up)
------------------------------	--

With & Without Contrast: (72156)	Infection, Discitis/Osteomyelitis, Tumor/Mass, Metastatic Disease, Demyelinating Disease/Multiple Sclerosis (new evaluation or symptoms)
-------------------------------------	---

****Values will vary between machines. Use your own discretion when selecting values.****

Reviewed by Dr. Holdsworth 10/2020

Subject to change at the discretion of the radiologist due to clinical circumstances.

MRI T-Spine



Diagnostic & Preventative Imaging Center

1. Localizer
2. Sagittal T2 - 4 mm slice thickness; Cover spine side to side; Field of view: C7 through L1
3. Sagittal STIR - 4 mm slice thickness; Same coverage as #2
4. Sagittal T1 - 4 mm slice thickness; Same coverage as #2
5. Axial T2 - 4 mm slice thickness; Cover T1 through L1
6. Axial T1 - 4 mm slice thickness; Same coverage as #5

*****Inject contrast - if contrast ordered*****

8. +C Sagittal T1 Fat Sat - 4 mm slice thickness; Same coverage as #2
9. +C Axial T1 - 4 mm slice thickness; Same coverage as #5

Notes:

- If Discitis/Osteomyelitis is a listed indication, include a sagittal DWI sequence.
- If Stroke/Infarction is a listed indication, include both Sagittal and Axial DWI sequences.
- If Scoliosis is present, include a non-contrast Coronal T2.
- If the exam is for Acute Trauma, include a non-contrast Sagittal T2 gradient.
- One stack of Axial images is preferred, if possible. If angled axial series is needed, only perform 2 sets of Axial T1 and T2 images.

Indications

*****A history of cervical or thoracic spine surgery DO NOT require contrast*****

Without Contrast: (72146)	Mid-Back Pain, Numbness or Tingling, Pain in the Upper or Lower Extremities, Demyelinating Disease/Multiple Sclerosis (routine follow up)
------------------------------	--

With & Without Contrast: (72157)	Infection, Discitis/Osteomyelitis, Tumor/Mass, Metastatic Disease, Demyelinating Disease/Multiple Sclerosis (new evaluation or symptoms)
-------------------------------------	---

*****Values will vary between machines. Use your own discretion when selecting values.*****

Reviewed by Dr. Holdsworth 10/2020

Subject to change at the discretion of the radiologist due to clinical circumstances.

MRI L-Spine



Diagnostic & Preventative Imaging Center

1. Localizer
2. Sagittal T2 - 4 mm slice thickness; Cover spine side to side; Field of view: T11 through S2/Mid-sacrum
3. Sagittal STIR - 4 mm slice thickness; Same coverage as #2
4. Sagittal T1 - 4 mm slice thickness; Same coverage as #2
5. Axial T2 - 4 mm slice thickness; Cover T12 through S1
6. Axial T1 - 4 mm slice thickness; Same coverage as #5
- **Inject contrast - if contrast ordered***
7. +C Sagittal T1 Fat Sat - 4 mm slice thickness; Same coverage as #2
8. +C Axial T1 - 4 mm slice thickness; Same coverage as #5

Notes:

- If Discitis/Osteomyelitis is a listed indication, include Sagittal DWI sequence.
- If Scoliosis is present, include a non-contrast Coronal T2.
- One stack of Axial images is preferred, if possible. If angled axial series is needed, only perform 2 sets of Axial T1 and T2 images.

Indications

Without Contrast:
(72148)

Low back Pain, Radiculopathy, Degenerative Disc Disease, Pain Radiating to the Hips or Legs, Numbness in the Legs

With & Without Contrast:
(72158)

History of Lumbar Surgery within 7 years (contrast not needed if patient has had another contrast enhanced MR since surgery), Infection/Discitis/Osteomyelitis, Tumor/Mass, Metastatic Disease, Guillain-Barre, Arachnoiditis

****Values will vary between machines. Use your own discretion when selecting values.****

Reviewed by Dr. Holdsworth 10/2020

Subject to change at the discretion of the radiologist due to clinical circumstances.

Neuro MRI Sequence Reference



Diagnostic & Preventative Imaging Center

Standard Whole Brain Sequences:

- Axial DWI: 5mm slices. B Value = 1000. Send B0, B1000 and ADC to PACS.
- Sagittal T1: T1 weighted FSE/TSE or T1 FLAIR. 5 mm slice thickness. Send all images to PACS.
- Axial T2: T2 weighted FSE/TSE. 5 mm slice thickness. Send all images to PACS.
- Axial T2*: T2 weighted Gradient Echo (GRE/T2*). 5 mm slice thickness. Send all images to PACS.
- Coronal T2: T2 weighted FSE/TSE. 5 mm slice thickness. Send all images to PACS.
- Axial T1: T1 weighted FSE/TSE. 5 mm slice thickness. May be with or without Fat Saturation (will be indicated in protocol). Send all images to PACS.
- Sagittal 3D FLAIR: Volumetric 3D FLAIR FSE/TSE (SPACE[Siemens], CUBE[GE], VISTA[Philips], MVOX[Canon]). ~1 mm isotropic or near-isotropic voxels. TR ~8000. Use Fat Suppression. Straight Sagittal - NO OBLIQUES. Send thin sagittal and 5 mm Axial (in the same plane as 2D sequence) to PACS.
 - *If MRI scanner is unable to perform 3D sequence or if significant patient motion, substitute Axial 2D FLAIR: 5 mm slices.
- Axial 3D T1: T1 weighted ultrafast GRE (MPRAGE[Siemens], BRAVO[GE], 3D TFE[Philips], FFE[Canon]). Straight Axial - NO OBLIQUES. Send thin Axial images to PACS.
 - *If MRI scanner is unable to perform 3D sequence, substitute 5 mm slice thickness Axial, Sagittal and Coronal 2D T1 for post contrast sequences.

Additional Whole Brain Sequences:

- Oblique Coronal T2: Oblique coronal T2 weighted sequence orthogonal to the temporal lobes. 2 mm slice thickness.
- Fast T2: Single Shot Fast Spin Echo/Turbo Spin Echo (HASTE[Siemens], SSFSE[GE], Single Shot TSE[Philips], FASE[Canon]). 5 mm slice thickness. For use in limited shunt eval or moving patient.
- Axial Perfusion (select sites only)

Continued on next page

Reviewed by Dr. Holdsworth 10/2020

Subject to change at the discretion of the radiologist due to clinical circumstances.

Neuro MRI Sequence Reference Cont.

Cranial Nerve Sequences:

- Axial T2 High Res: T2 weighted high spatial resolution, small field of view 3D volumetric Balanced Steady State Free Precession (CISS[Siemens], FIESTA[GE], Balanced FFE[Philips], True SSFP[Canon]) **OR** FSE/TSE (SPACE[Siemens], CUBE[GE], VISTA[Philips], MVOX[Canon]). Check protocol for field of view. Send thin images to PACS.
- Axial T1: T1 weighted FSE/TSE sequence through the cranial nerves. 2 mm slice thickness. May be with or without Fat Saturation (will be indicated in protocol). Check protocol for field of view. Send all images to PACS.
- Coronal T1: T1 weighted FSE/TSE sequence through the cranial nerves. 2 mm slice thickness. May be with or without Fat Saturation (will be indicated in protocol). Check protocol for field of view. Send all images to PACS.

Pituitary Sequences:

- Sagittal T1 thin: Sagittal T1 weighted small field of view FSE/TSE sequence through the pituitary. 2 mm slice thickness. Send all images to PACS.
- Coronal T2 thin: Coronal T2 weighted small field of view FSE/TSE sequence through the pituitary. 2 mm slice thickness. Send all images to PACS.
- Coronal T1 thin: Coronal T1 weighted small field of view FSE/TSE sequence through the pituitary. 2 mm slice thickness. Send all images to PACS.
- Coronal T1 dynamic: Multiphase T1 weighted coronal imaging through the pituitary during and after contrast injection. 2 mm slice thickness. ~12 phases. Send all images to PACS as 1 series.

Orbit Sequences:

- Coronal T2: T2 weighted FSE/TSE sequence through the orbits. 3 mm slice thickness. Fat suppressed. Send all images to PACS.
- Axial T2 High Res: T2 weighted high spatial resolution, small field of view 3D volumetric Balanced Steady State Free Precession (CISS[Siemens], FIESTA[GE], Balanced FFE[Philips], True SSFP[Canon]) **OR** FSE/TSE (SPACE[Siemens], CUBE[GE], VISTA[Philips], MVOX[Canon]). Send thin images to PACS.
- Axial T1: T1 weighted FSE/TSE sequence through the orbits. 3 mm slice thickness. Fat suppressed. Send all images to PACS.
- Coronal T1: T1 weighted FSE/TSE sequence through the orbits. 3 mm slice thickness. Fat suppressed. Send all images to PACS.

MRA Head



Diagnostic & Preventative Imaging Center

1. Localizer
2. Axial 3D Time of Flight (TOF) MRA - Send raw data and multiplanar MIPS to PACS

Inject contrast - if contrast ordered

3. Axial 3D Time of Flight (TOF) MRA

Notes:

- Almost always without contrast. Include contrast if history of prior intracranial arterial stent placement

Indications

Without Contrast: Stroke/TIA, Stenosis, Aneurysm
(70544)

****Values will vary between machines. Use your own discretion when selecting values.****

Reviewed by Dr. Holdsworth 10/2020

Subject to change at the discretion of the radiologist due to clinical circumstances.

MRV Head



Diagnostic & Preventative Imaging Center

1. Localizer
2. 3D Phase Contrast (PC) MRV
Inject contrast - if contrast ordered
3. +C 3D Phase Contrast (PC) MRV

Notes:

- Without contrast most common.
- May substitute Time of Flight (TOF) MRV if scanner not able to perform 3D phase contrast.

Indications

Without Contrast: Headache, Venous Sinus Thrombosis, Idiopathic Intracranial Hypertension
(70554)

****Values will vary between machines. Use your own discretion when selecting values.****

Reviewed by Dr. Holdsworth 10/2020

Subject to change at the discretion of the radiologist due to clinical circumstances.

MRI Shoulder



Diagnostic & Preventative Imaging Center

Sequence	Plane	FOV	Thickness	Gap	NSA	F/S	PE x RO Matrix	TI	TR	TE	Comments
Axial LOC	Ax	50 x 50	6.0	1.5	1	-	128 X 256	-	190	9	
3 Plane LOC	-	25 x 25	5.0	0.5	1	-	128 x 256	-	119	9	
Shim	-	18 x 18	5.0	3.0	1	-	64 x 64	-	200	4-8	
PD FS Axial	Ax	15 x 15	3.0	0.3	1	Light	224 x 288	-	2300	36	No Speeder Coil
TS FS Coronal	Cor	14 x 14	3.0	0.3	1	Light	224 x 320	-	3400	60	No Speeder Coil
T1 Sagittal	Sag	15 x 15	3.0	0.3	1	-	224 x 256	-	475	12	Speeder 1.3
T2 FS Sagittal	Sag	15 x 15	3.0	0.3	2	Light	192 x 288	-	3450	60	Speeder 1.3
T2 FS Oblique/Sagittal	Obl	15 x 15	3.0	0.3	2	Light	224 x 288	-	3400	60	Speeder 1.3

Indications

Without Contrast: Pain, Injury, Instability and Limited Range of Motion, Arthritis

With & Without Contrast: Bone and Soft Tissue Masses, Infection of the Bone and Soft Tissue

****Matrix/TR/TE values will vary between machines. Use your own discretion when selecting these values****

Reviewed by Dr. Choi 4/2016

Subject to change at the discretion of the radiologist due to clinical circumstances.

MRI Shoulder Arthrogram

Sequence	Plane	FOV	Thickness	Gap	NSA	F/S	PE x RO Matrix	TI	TR	TE	Comments
3 Plane LOC	-	45 x 45	5.0	0.5	1	-	128 x 256	-	119	9	Large FOV
3 Plane LOC	-	25 x 25	5.0	0.5	1	-	128 x 256	-	119	9	
Shim	-	18 x 18	5.0	3.0	1	-	64 x 64	-	200	4.8	
T1 FS Axial	Ax	15 x 15	3.0	0.3	2	Light	224 x 288	-	590	12	Speeder 1.5
T2 FS Coronal	Cor	15 x 15	3.0	0.3	1	Light	224 x 320	-	3400	60	No Speeder Coil
T1 FS Coronal	Cor	15 x 15	3.0	0.3	1	Light	224 x 288	-	560	12	Speeder 1.5
T1 FS Sagittal	Sag	15 x 15	3.0	0.3	1	Light	224 x 256	-	560	12	Speeder 1.3
<i>Optional (Ask Rad)</i>											Full-thickness Cuff Tear
T2 Sagittal	Sag	15 x 15	3.0	0.3	2		192 x 288	-	3450	60	Speeder 1.3
3 Plane LOC	-	32 x 32	5.0	0.5	1.5	-	192 x 256	-	360	9	Large FOV
Aber LOC	Obl	25 x 25	5.0	0.5	1	-	192 x 256	-	427	60	
Shim	-	18 x 18	5.0	5.0	1	-	64 x 64	-	200	4.8	
T1 FS Aber	Obl	18 x 18	3.0	0.5	2	Light	192 x 256	-	510	10	No Speeder Coil
<i>Optional</i>											
Sagittal T2	Sag	15 x 15	3.0	0.3	2	-	192 x 288	-	3450	60	For RTC Surgery
Axial T1	Ax	15 x 15	3.0	0.3	1	-	224 x 288	-	415	12	For Labral Surgery

Indications

With Contrast:

Shoulder Pain, Labral Tear, Popping, Clicking, Decreased Range of Motion, Pain

****Matrix/TR/TE values will vary between machines. Use your own discretion when selecting these values****

Reviewed by Dr. Choi 11/2016

MRI

Humerus



Diagnostic & Preventative Imaging Center

Sequence	Plane	FOV	Thickness	Gap	NSA	F/S	PE x RO Matrix	TI	TR	TE	Comments
3 Axis Lg LOC	-	42 x 42	5.0	0.5	1	-	128 x 256	-	119	9	
3 Plane LOC	-	19 x 30	5.0	1.0	1	-	144 x 256	-	360	9	
Map	-	23 x 23	6.0	10.0	1	-	64 x 64	-	184	4	
T1 Axial	Ax	16 x 15	6.0	1.5	2	-	224 x 320	-	540	10	
T2 FS Axial	Ax	16 x 15	6.0	1.5	3	Light	192 x 256	-	6300	60	
Shim	-	17 x 17	5.0	16.0	2	-	32 x 32	-	200	4.8/9	
T2 FS Coronal	Cor	26 x 15	3.0	1.0	1	Light	192 x 288	-	4550	60	
T1 Coronal	Cor	26 x 15	3.0	1.0	1	-	192 x 288	-	595	10	
PD FS Sagittal	Sag	14 x 27	3.0	1.0	1	Light	192 x 256	-	3000	30	May need to be T2 FS Cor
T1 Sagittal	Sag	14 x 27	3.0	1.0	2	-	192 x 288	-	490	10	
<i>Optional</i>											
STIR Coronal	Cor	26 x 15	3.0	1.0	1	-	192 x 256	145	4400	60	

Indications

Without Contrast: Pain, Injury, Instability and Limited Range of Motion, Arthritis

With Contrast: Bone and Soft Tissue Masses, Infection of the Bone and Soft Tissue

****Matrix/TR/TE values will vary between machines. Use your own discretion when selecting these values****

Reviewed by Dr. Choi 4/2016

Subject to change at the discretion of the radiologist due to clinical circumstances.

MRI Elbow



Sequence	Plane	FOV	Thickness	Gap	NSA	F/S	PE x RO Matrix	TI	TR	TE	Comments
Axial LOC	Ax	50 x 50	6.0	1.0	1	-	128 x 256	-	290	9	
3 Plane LOC	-	18 x 18	5.0	0.5	1	-	144 x 256	-	360	9	
Map	-	23 x 23	6.0	4.0	1	-	64 x 64	-	184	4	
T1 Axial	Ax	14 x 14	3.0	0.5	3	-	224 x 320	-	595	10	
Shim	-	12 x 12	5.0	2.0	2	-	32 x 32	-	200	4.8	
T2 FS Axial	Ax	14 x 14	3.0	0.5	4	Light	192 x 256	-	3650	60	
T1 Coronal	Cor	14 x 14	3.0	0.5	2	-	224 x 288	-	485	10	
T2 FS Coronal	Cor	14 x 14	3.0	0.5	2	Light	224 x 320	-	3000	60	
PD FS Sagittal	Sag	14 x 14	3.0	0.5	2	Light	192 x 256	-	2600	30	
T1 Sagittal	Sag	14 x 14	3.0	0.5	2	-	224 x 288	-	650	10	

Indications

Without Contrast: Pain, Injury, Instability and Limited Range of Motion, Arthritis

With & Without Contrast: Bone and Soft Tissue Masses, Infection of the Bone and Soft Tissue

****Matrix/TR/TE values will vary between machines. Use your own discretion when selecting these values****

Reviewed by Dr. Choi 4/2016

Subject to change at the discretion of the radiologist due to clinical circumstances.

MRI Elbow Arthrogram

Sequence	Plane	FOV	Thickness	Gap	NSA	F/S	PE x RO Matrix	TI	TR	TE	Comments
Axial LOC	Ax	50 x 50	6.0	1.0	1	-	128 x 256	-	290	9	
3 Plane LOC	-	18 x 18	5.0	1.0	1	-	144 x 256	-	360	9	
Map	-	14 x 14	6.0	0.0	1	-	32 x 64	-	184	4	
Shim	-	14 x 14	5	2	2	-	32 x 32	-	200	4.8	
T1 FS Axial	Ax	14 x 14	3.0	0.5	3	Light	224 x 320	-	570	10	
T1 FS Coronal	Cor	14 x 14	3.0	0.5	2	Light	224 x 288	-	555	10	
T1 FS Sagittal	Sag	14 x 14	3.0	0.5	3	Light	224 x 288	-	430	10	
T2 FS Axial	Ax	14 x 14	3.0	0.5	4	Light	192 x 256	-	5300	108	
PD FS Coronal	Cor	14 x 14	3.0	0.5	2	Light	192 x 256	-	3333	30	
<i>Optional</i>											
T1 Sagittal	Sag	14 x 14	3.0	0.5	3	-	224 x 288	-	540	10	
T1 Coronal	Cor	14 x 14	3.0	0.5	2	-	224 x 288	-	600	10	

Indications

With Contrast:

Ligament Tears

****Matrix/TR/TE values will vary between machines. Use your own discretion when selecting these values****

Reviewed by Dr. Choi 11/2016

MRI Wrist



Diagnostic & Preventative Imaging Center

Sequence	Plane	FOV	Thickness	Gap	NSA	F/S	PE x RO Matrix	TI	TR	TE	Comments
Axial LOC	Ax	50 x 50	6.0	1.0	1	-	128 x 256	-	360	9	
3 Plane LOC	-	18 x 18	5.0	1.0	1	-	128 x 256	-	360	9	
Map	-	13 x 13	6.0	1.0	1	-	64 x 64	-	185	4	
Shim	-	28 x 28	5.0	5.0	1	-	64 x 64	-	200	4.8	
PD FS Axial	Ax	11 x 11	3.0	0.5	1	Light	224 x 256	-	3200	24	
T1 Axial	Ax	11 x 11	3.0	0.5	3	-	224 x 320	-	575	12	
PD FS Coronal	Cor	11 x 11	3.0	0.5	3	Light	224 x 324	-	3000	30	
T1 Coronal	Cor	11 x 11	3.0	0.5	3	-	224 x 320	-	580	12	
T2 FS Sagittal	Sag	11 x 11	3.0	0.5	2	Light	224 x 320	-	3150	60	
T1 Sagittal	Sag	11 x 11	3	0.5	1	-	256 x 352	-	440	12	
3D FE Coronal	Cor	12 x 12	1.0	0.0	1	-	256 x 256	-	45	15	Cartilage Series
<i>Optional</i>											
T1 FS Axial Post	Ax	12 x 12	3.0	0.5	2	Light	192 x 256	-	720	12	
T1 FS Coronal Post	Cor	12 x 12.5	3.0	0.5	2	Light	192 x 320	-	680	12	
T1 FS Sagittal Post	Sag	12 x 12	3.0	0.5	2	Light	192 x 320	-	680	12	

Indications

Without Contrast: Pain, Injury, Instability and Limited Range of Motion, Arthritis

With & Without Contrast: Bone and Soft Tissue Masses, Infection of the Bone and Soft Tissue

****Matrix/TR/TE values will vary between machines. Use your own discretion when selecting these values****

Reviewed by Dr. Choi 11/2016

Subject to change at the discretion of the radiologist due to clinical circumstances.

MRI Wrist Arthrogram



Diagnostic & Preventative Imaging Center

Sequence	Plane	FOV	Thickness	Gap	NSA	F/S	PE x RO Matrix	TI	TR	TE	Comments
Axial LOC	Ax	50 x 50	6.0	1.0	1	-	128 x 256	-	360	9	
3 Plane LOC	-	18 x 18	5.0	1.0	1	-	128 x 256	-	360	9	
Map	-	13 x 13	6.0	1.0	1	-	64 x 64	-	185	4	
Shim	-	11 x 11	5.0	3.0	2	-	32 x 32	-	200	4.8	
T2 FS Axial	Ax	12 x 12	3.0	0.5	3	Light	192 x 256	-	3000	60	
T1 FS Axial	Ax	12 x 12	3.0	0.5	2	Light	192 x 256	-	645	10	
T1 FS Coronal	Cor	12 x 12	2.5	0.5	2	Light	192 x 256	-	745	12	
PD FS Coronal	Cor	12 x 12	2.5	0.5	3	Light	192 x 256	-	3000	30	
T1 FS Sagittal	Sag	12 x 12	2.5	0.5	2	Light	192 x 256	-	735	12	
3D FE Coronal	Cor	12 x 12	1.0	0.0	1	-	256 x 256	-	45	15	Cartilage Series

Indications

With Contrast: TFCC Tear, Ligament Tears

****Matrix/TR/TE values will vary between machines. Use your own discretion when selecting these values****

Reviewed by Dr. Choi 11/2016

Subject to change at the discretion of the radiologist due to clinical circumstances.

MRI Hand



Diagnostic & Preventative Imaging Center

Sequence	Plane	FOV	Thickness	Gap	NSA	F/S	PE x RO Matrix	TI	TR	TE	Comments
Axial LOC	Ax	50 x 50	6.0	1.0	1	-	128 x 256	-	360	9	
3 Plane LOC	-	24 x 24	5.0	1.0	1	-	128 x 256	-	360	9	
Map	-	18 x 21	6.0	5.0	1	-	64 x 64	-	185	4	
Shim	-	14 x 14	5.0	8.0	2	-	32 x 32	-	200	4.8	
T2 FS Axial	Ax	12 x 12	3.0	0.5	4	Light	192 x 256	-	4953	60	
T1 Axial	Ax	12 x 12	3.0	0.5	3	-	256 x 288	-	515	12	
T1 Coronal	Cor	14 x 14	2.5	0.5	2	-	192 x 256	-	580	12	
STIR Coronal	Cor	14 x 14	2.5	0.5	1	-	192 x 256	130	4101	48	
T2 FS Sagittal	Sag	13 x 13	2.5	0.5	4	Light	192 x 256	-	4953	60	
T1 Sagittal	Sag	13 x 13	2.5	0.5	2	-	192 x 256	-	520	12	
<i>Optional</i>											
3D FE Coronal	Cor	14 x 14	1.0	0.0	1	-	256 x 256	-	45	15	Cartilage Series
PD FS Sagittal	Sag	13 x 13	2.5	0.5	2	Light	192 x 256	-	2350	30	

Indications

Without Contrast: Pain, Injury, Instability and Limited Range of Motion, Arthritis

With & Without Contrast: Bone and Soft Tissue Masses, Infection of the Bone and Soft Tissue

****Matrix/TR/TE values will vary between machines. Use your own discretion when selecting these values****

Reviewed by Dr. Choi 4/2016

Subject to change at the discretion of the radiologist due to clinical circumstances.

MRI Sacrum /SI Joints



Diagnostic & Preventative Imaging Center

Sequence	Plane	FOV	Thickness	Gap	NSA	F/S	PE x RO Matrix	TI	TR	TE	Comments
Sagittal LOC	Sag	50 x 50	5.0	1.0	1	-	128 x 256	-	265	9	
Coronal LOC	Cor	45 x 45	5.0	1.0	1	-	128 x 256	-	285	9	
Map	-	40 x 60	6.0	10.0	1	-	64 x 64	-	235	4	
T1 Coronal	Cor	28 x 28	5.0	1.0	2	-	256 x 352	-	495	10	
STIR Coronal	Cor	28 x 28	5.0	1.0	2	-	224 x 256	150	5526	84	
T1 Axial	Ax	30 x 15	5.0	1.0	1	-	224 x 512	-	615	15	
T2 FS Axial	Ax	30 x 15	5.0	1.0	2	Light	256 x 352	-	4850	90	
T2 FS Sagittal	Sag	26 x 24	5.0	1.0	2	Light	192 x 304	-	4621	90	

Indications

Without Contrast: Pain, Injury

****Matrix/TR/TE values will vary between machines. Use your own discretion when selecting these values****

Reviewed by Dr. Choi 4/2016

Subject to change at the discretion of the radiologist due to clinical circumstances.

MRI Bony Pelvis / Hip

(Over 65 y/o)



Sequence	Plane	FOV	Thickness	Gap	NSA	F/S	PE x RO Matrix	TI	TR	TE	Comments
3 Plane LOC	-	45 x 45	7.0	0.0	1	-	128 x 256	-	45	5	
Map	-	50 x 55	6.0	14.0	1	-	32 x 64	-	185	4	
STIR Coronal (Bilat)	Cor	37 x 32	5.0	1.0	2	-	192 x 256	135	6023	48	Entire Pelvis
T1 Coronal (Bilat)	Cor	37 x 32	5.0	1.0	1	-	256 x 320	-	777	10	Entire Pelvis
Shim	-	28 x 28	5.0	5.0	1	-	64 x 64	-	200	4.8	
T2 FS Axial	Ax	35 x 35	5.0	1.0	1	Light	192 x 256	-	4700	60	Entire Pelvis
T1 Axial	Ax	35 x 35	5.0	1.0	1	-	192 x 256	-	650	10	Entire Pelvis
PD FS Sagittal	Sag	20 x 20	4.0	0.5	1	Light	224 x 288	-	2555	36	Cover Joint
<i>Optional</i>											
T1 Sagittal	Sag	20 x 20	4.0	0.5	1	-	192 x 256	-	480	12	Cover Joint
T1 Axial	Ax	24 x 24	4.0	0.5	2	-	256 x 320	-	777	10	Cover Joint
T1 Coronal	Cor	20 x 20	4.0	0.5	2	-	256 x 256	-	410	10	Cover Joint
<i>Optional Contrast</i>											
T1 FS Coronal Post	Cor	35 x 35	5.0	1.0	2	Light	192 x 256	-	625	10	Entire Pelvis
T1 FS Axial Post	Ax	35 x 35	5.0	1.0	2	Light	192 x 256	-	560	10	Entire Pelvis
T1 FS Sagittal Post	Sag	35 x 35	5.0	1.0	2	Light	192 x 256	-	560	10	Entire Pelvis

Indications

Without Contrast: Evaluate for Fracture, Pain, Injury, Instability and Limited Range of Motion, Arthritis

With & Without Contrast: Bone and Soft Tissue Masses, Infection of the Bone and Soft Tissue

****Matrix/TR/TE values will vary between machines. Use your own discretion when selecting these values****

Reviewed by Dr. Choi 11/2017

MRI Bony Pelvis / Hip

(65 y/o & Younger)



Sequence	Plane	FOV	Thickness	Gap	NSA	F/S	PE x RO Matrix	TI	TR	TE	Comments
3 Plane LOC	-	45 x 45	7.0	0.0	1	-	128 x 256	-	45	5	
Map	-	50 x 55	6.0	14.0	1	-	32 x 64	-	185	4	
STIR Coronal (Bilat)	Cor	37 x 32	5.0	1.0	2	-	192 x 256	135	6023	48	Entire Pelvis
T1 Coronal (Bilat)	Cor	37 x 32	5.0	1.0	1	-	256 x 320	-	777	10	Entire Pelvis
Shim	-	28 x 28	5.0	5.0	1	-	64 x 64	-	200	4.8	
T2 FS Axial	Ax	24 x 24	4.0	0.5	3	Light	192 x 256	-	4656	60	ASIS thru Symphysis
T2 FS Coronal	Cor	20 x 20	4.0	0.5	2	Light	224 x 288	-	5796	60	
PD FS Sagittal	Sag	20 x 20	4.0	0.5	1	Light	224 x 288	-	2555	36	\ Include
T1 Sagittal	Sag	20 x 20	4.0	0.5	1	-	192 x 256	-	480	12	/ Symphysis
T1 Axial	Ax	24 x 24	4.0	0.5	2	-	256 x 320	-	777	10	ASIS thru Symphysis
T1 Coronal	Cor	20 x 20	4.0	0.5	2	-	256 x 256	-	410	10	
<i>Optional Contrast</i>											
T1 FS Coronal Post	Cor	20 x 20	4.0	0.5	2	Light	192 x 256	-	625	10	
T1 FS Axial Post	Ax	24 x 24	4.0	0.5	2	Light	192 x 256	-	560	10	ASIS thru Symphysis

Indications

Without Contrast: Pain, Injury, Instability and Limited Range of Motion, Arthritis

With & Without Contrast: Bone and Soft Tissue Masses, Infection of the Bone and Soft Tissue

****Matrix/TR/TE values will vary between machines. Use your own discretion when selecting these values****

Reviewed by Dr. Choi 11/2017

MRI Hip Arthrogram



Diagnostic & Preventative Imaging Center

Sequence	Plane	FOV	Thickness	Gap	NSA	F/S	PE x RO Matrix	TI	TR	TE	Comments
3 Plane LOC	-	45 x 45	7.0	0.0	1	-	128 x 256	-	45	5	
Map	-	50 x 65	6.0	14.0	1	-	32 x 64	-	185	4	
T1 Axial	Ax	20 x 20	4.0	0.4	2	-	256 x 384	-	475	10	
Shim	-	22 x 22	5.0	5.0	1	-	64 x 64	-	200	4.8	
T1 FS Coronal	Cor	20 x 20	4.0	0.4	2	Light	192 x 256	-	615	10	
T2 FS Coronal	Cor	20 x 20	4.0	0.4	3	Light	192 x 256	-	4000	60	
T1 FS Sagittal	Sag	20 x 20	4.0	0.4	2	Light	192 x 256	-	460	10	
T1 FS Parallel	Obl	20 x 20	4.0	0.4	2	Light	224 x 256	-	510	10	Parallel to Neck
<i>Optional</i>											
T1 FS Perpendicular	Obl	20 x 20	4.0	0.4	2	Light	192 x 256	-	460	10	Perpendicular To Neck

Indications

With Contrast:

Pain, Decreased Range of Motion, Tears, Groin Pain, Catching, Evaluate for labral tear

****Matrix/TR/TE values will vary between machines. Use your own discretion when selecting these values****

Reviewed by Dr. Choi 11/2022

Subject to change at the discretion of the radiologist due to clinical circumstances.

MRI Femur



Diagnostic & Preventative Imaging Center

Sequence	Plane	FOV	Thickness	Gap	NSA	F/S	PE x RO Matrix	TI	TR	TE	Comments
Coronal LOC	Cor	28 x 50	6.0	2.0	1	-	128 x 256	-	2000	15	
3 Plane LOC	-	28 x 50	6.0	2.0	1	-	128 x 256	-	190	9	
Map	-	50 x 55	6.0	16.0	1	-	32 x 64	-	185	4	
T1 Sagittal	Sag	17 x 47	5.0	1.0	1	-	224 x 320	-	400	12	
Shim	-	21 x 21	5.0	23.0	1	-	64 x 64	-	200	4.8	
STIR Coronal	Cor	47 x 21	5.0	1.0	1	-	192 x 256	-	3250	60	
T2 FS Sagittal	Sag	17 x 47	5.0	1.0	1	Light	192 x 256	-	3250	60	
T2 FS Axial	Ax	16 x 18	6.0	2.0	2	Light	224 x 256	-	7100	60	
T1 Axial	Ax	16 x 18	6.0	2.0	1	-	256 x 336	-	580	12	
T1 Coronal	Cor	47 x 21	5.0	1.0	1	-	192 x 256	-	630	10	
<i>Optional</i>											
STIR Sagittal	Sag	17 x 47	5.0	1.0	1	-	192 x 256	140	6409	60	
<i>Optional Contrast</i>											
T1 FS Coronal Post	Cor	47 x 21	5.0	1.0	1	Light	192 x 256	-	620	10	
T1 FS Sagittal Post	Sag	17 x 47	5.0	1.0	1	Light	192 x 256	-	700	10	
T1 FS Axial Post	Ax	16 x 18	6.0	2.0	1	Light	192 x 256	-	560	10	

Indications

Without Contrast: Pain, Injury, Instability and Limited Range of Motion, Arthritis

With & Without Contrast: Bone and Soft Tissue Masses, Infection of the Bone and Soft Tissue

****Matrix/TR/TE values will vary between machines. Use your own discretion when selecting these values****

Reviewed by Dr. Choi 11/2016

Subject to change at the discretion of the radiologist due to clinical circumstances.

MRI Knee



Sequence	Plane	FOV	Thickness	Gap	NSA	F/S	PE x RO Matrix	TI	TR	TE	Comments
Coronal LOC	Cor	50 x 50	5.0	1.0	1	-	128 x 256	-	356	9	
3 Plane LOC	-	50 x 50	5.0	1.0	1	-	128 x 256	-	356	9	
Shim	-	20 x 20	5.0	5.0	1	-	64 x 64	-	200	4.8	
PD FS Axial	Ax	15 x 16	3.5	0.5	1	Light	224 x 256	-	2900	30	
PD Sagittal	Sag	15 x 15	3.5	0.3	1	-	256 x 320	-	1728	24	
T2 FS Sagittal	Sag	15 x 15	3.5	0.3	1	Light	256 x 320	-	3850	60	
PD FS Coronal	Cor	15 x 15	3.5	0.5	1	Light	224 x 256	-	3000	24	
T1 Coronal	Cor	15 x 15	3.5	0.5	1	-	256 x 320	-	485	10	
Sagittal Oblique ACL	Obl	16 x 16	3.0	0.5	1	Light	224 x 256	-	3400	60	

Indications

Without Contrast: Pain, Injury, Instability and Limited Range of Motion, Arthritis

With & Without Contrast: Bone and Soft Tissue Masses, Infection of the Bone and Soft Tissue

****Matrix/TR/TE values will vary between machines. Use your own discretion when selecting these values****

Reviewed by Dr. Choi 4/2016

Subject to change at the discretion of the radiologist due to clinical circumstances.

MRI Knee Arthrogram



Diagnostic & Preventative Imaging Center

Sequence	Plane	FOV	Thickness	Gap	NSA	F/S	PE x RO Matrix	TI	TR	TE	Comments
LOCS											
T2 FS Axial	Ax	17 x 17	3.5	0.5	2	-	192 x 288	-	4800	60	
PD Sagittal	Sag	16 x 16	3.0	0.3	1	-	256 x 320	-	2514	30	
T1 FS Coronal	Cor	16 x 16	3.0	0.5	1	-	224 x 256	-	500	10	
T2 FS Sagittal	Sag	16 x 16	3.0	0.3	1	-	256 x 288	-	3304	48	
T1 FS Sagittal	Sag	16 x 16	3.0	0.3	1	-	256 x 320	-	450	10	

Indications

With Contrast:

Ligament Tears

****Matrix/TR/TE values will vary between machines. Use your own discretion when selecting these values****

Reviewed by Dr. Choi 11/2016

Subject to change at the discretion of the radiologist due to clinical circumstances.

MRI Tib/Fib

Sequence	Plane	FOV	Thickness	Gap	NSA	F/S	PE x RO Matrix	TI	TR	TE	Comments
Coronal LOC	Cor	28 x 50	6.0	2.0	1	-	128 x 256	-	2000	15	
3 Plane LOC	-	28 x 50	6.0	2.0	1	-	128 x 256	-	190	9	
Map	-	50 x 55	6.0	16.0	1	-	32 x 64	-	185	4	
T1 Sagittal	Sag	14 x 40	5.0	1.0	1	-	224 x 320	-	400	12	
T2 FS Sagittal	Sag	14 x 40	5.0	1.0	1	Light	192 x 256	140	6409	60	
Shim	-	21 x 21	5.0	23.0	1	-	64 x 64	-	200	4.8	
T1 Coronal	Cor	40 x 14	5.0	1.0	1	-	192 x 256	-	630	10	
STIR Coronal	Cor	40 x 14	5.0	1.0	1	-	192 x 256	140	6409	60	
T2 FS Axial	Ax	15 x 15	6.0	2.0	2	Light	224 x 256	-	7100	60	
T1 Axial	Ax	15 x 15	6.0	2.0	1	-	256 x 336	-	580	12	
<i>Optional Contrast</i>											
T1 FS Coronal Post	Cor	40 x 14	5.0	1.0	1	Light	192 x 256	-	620	10	
T1 FS Sagittal Post	Sag	14 x 40	5.0	1.0	1	Light	192 x 256	-	700	10	
T1 FS Axial Post	Ax	15 x 15	6.0	2.0	1	Light	192 x 256	-	560	10	

Indications

Without Contrast: Pain, Injury, Instability and Limited Range of Motion, Arthritis, Evaluate for Stress Fracture, Running Injury

With & Without Contrast: Bone and Soft Tissue Masses, Infection of the Bone and Soft Tissue

****Matrix/TR/TE values will vary between machines. Use your own discretion when selecting these values****

Reviewed by Dr. Choi 11/2016

MRI

Ankle/Hindfoot

Sequence	Plane	FOV	Thickness	Gap	NSA	F/S	PE x RO Matrix	TI	TR	TE	Comments
Coronal LOC	Cor	28 x 28	5.0	1.0	1	-	128 x 256	-	2000	15	
3 Plane LOC	-	25 x 25	6.0	2.0	1	-	128 x 256	-	213	9	
Shim	-	28 x 28	5.0	5.0	1	-	64 x 64	-	200	4.8	
T2 FS Axial	Ax	14 x 14	3.5	0.5	1	Light	224 x 256	-	4800	60	Long Axis
T1 Axial	Ax	14 x 14	3.5	0.5	1	-	256 x 320	-	595	10	Long Axis
T1 Sagittal	Sag	14 x 14	3.0	0.3	1	-	256 x 320	-	595	10	
STIR Sagittal	Sag	14 x 14	3.0	0.3	2	-	192 x 288	130	4500	100	
T1 Coronal	Cor	14 x 14	3.0	0.3	1	-	256 x 320	-	655	10	Short Axis
T2 FS Coronal	Cor	14 x 14	3.0	0.3	1	Light	192 x 256	-	3900	48	Short Axis
PD Coronal Tendon	Obl	14 x 14	3.0	0.3	1	-	192 x 256	-	3000	30	Peroneal Tendon
<i>Optional Contrast</i>											
T1 FS Axial Post	Ax	14 x 14	3.5	0.5	1	Light	256 x 320	-	595	10	
T1 FS Coronal Post	Cor	14 x 14	3.0	0.3	1	Light	256 x 320	-	655	10	
T1 FS Sagittal Post	Sag	14 x 14	3.5	0.3	1	Light	192 x 256	-	570	10	

Indications

Without Contrast: Pain, Injury, Instability and Limited Range of Motion, Arthritis

With & Without Contrast: Bone and Soft Tissue Masses, Infection of the Bone and Soft Tissue

****Matrix/TR/TE values will vary between machines. Use your own discretion when selecting these values****

Reviewed by Dr. Choi 11/2016

MRI Ankle Arthrogram



Sequence	Plane	FOV	Thickness	Gap	NSA	F/S	PE x RO Matrix	TI	TR	TE	Comments
LOCS											
T1 FS Axial	Ax	14 x 14	3.0	1.0	1	-	224 x 256	-	600	12	
T1 FS Sagittal	Sag	14 x 14	3.0	0.5	1	-	224 x 256	-	600	12	
STIR Sagittal	Sag	14 x 14	3.0	0.5	2	-	192 x 288	130	4750	100	
T1 FS Coronal	Cor	14 x 14	3.0	0.5	1	-	224 x 256	-	705	12	
PD FS Coronal	Cor	14 x 14	3.0	0.5	2	-	224 x 240	-	3665	40	
3D FE Coronal	Cor	14 x 14	1.5	0.0	1	-	224 x 224	-	41.9	15	

Indications

With Contrast:

Ligament Tears

****Matrix/TR/TE values will vary between machines. Use your own discretion when selecting these values****

Reviewed by Dr. Choi 11/2016

Subject to change at the discretion of the radiologist due to clinical circumstances.

MRI Lisfranc



Diagnostic & Preventative Imaging Center

Sequence	Plane	FOV	Thickness	Gap	NSA	F/S	PE x RO Matrix	TI	TR	TE	Comments
Coronal LOC	Cor	28 x 28	5.0	1.0	1	-	128 x 256	-	2000	15	
3 Plane LOC	-	25 x 25	6.0	0.0	1	-	128 x 256	-	119	9	
Shim	-	28 x 28	5.0	5.0	1	-	64 x 64	-	200	4.8	
PD FS Axial	Ax	14 x 14	3.5	0.3	1	Light	224 x 256	-	3500	30	Short Axis: 1st TMT
T1 Axial	Ax	14 x 14	3.5	0.3	1	-	256 x 336	-	375	12	Short Axis: 1st TMT
T1 Sagittal	Sag	14 x 14	3.0	0.3	1	-	256 x 320	-	603	12	
STIR Sagittal	Sag	14 x 14	3.0	0.3	1	-	192 x 256	145	7073	60	
T1 Coronal	Cor	14 x 14	3.0	0.3	1	-	224 x 256	-	575	10	Long Axis: 1st TMT
PD FS Coronal	Cor	14 x 14	3.0	0.3	1	Light	224 x 256	-	3500	30	Long Axis: 1st TMT

Indications

Without Contrast: Pain midfoot, Evaluate for lisfranc ligament injury

With & Without Contrast: Bone and Soft Tissue Masses, Infection of the Bone and Soft Tissue

****Matrix/TR/TE values will vary between machines. Use your own discretion when selecting these values****

Reviewed by Dr. Choi 11/2016

Subject to change at the discretion of the radiologist due to clinical circumstances.

MRI

Mid/Forefoot



Diagnostic & Preventative Imaging Center

Sequence	Plane	FOV	Thickness	Gap	NSA	F/S	PE x RO Matrix	TI	TR	TE	Comments
Coronal LOC	Cor	28 x 28	5.0	1.0	1	-	128 x 256	-	2000	15	
3 Plane LOC	-	25 x 25	6.0	0.0	1	-	128 x 256	-	119	9	
Shim	-	28 x 28	5.0	5.0	1	-	64 x 64	-	200	4.8	
T2 FS Axial	Ax	14 x 14	3.5	0.3	1	Light	224 x 256	-	4550	60	Short Axis
T1 Axial	Ax	14 x 14	3.5	0.3	1	-	256 x 336	-	375	12	Short Axis
T1 Sagittal	Sag	14 x 14	3.0	0.3	1	-	256 x 320	-	603	12	
STIR Sagittal	Sag	14 x 14	3.0	0.3	1	-	192 x 256	145	7073	60	
T1 Coronal	Cor	14 x 14	3.0	0.3	1	-	224 x 256	-	575	10	Long Axis
T2 FS Coronal	Cor	14 x 14	3.0	0.3	1	Light	224 x 256	-	4656	60	Long Axis
<i>Optional Contrast</i>											
T1 FS Axial Post	Ax	14 x 14	3.5	0.5	2	Light	192 x 256	-	650	10	
T1 FS Sagittal Post	Sag	14 x 14	3.0	0.3	3	Light	192 x 256	-	570	10	
T1 FS Coronal Post	Cor	14 x 14	3.0	0.3	1	Light	192 x 256	-	650	10	

Indications

Without Contrast: Pain, Injury, Instability and Limited Range of Motion, Arthritis

With & Without Contrast: Bone and Soft Tissue Masses, Infection of the Bone and Soft Tissue

****Matrix/TR/TE values will vary between machines. Use your own discretion when selecting these values****

Reviewed by Dr. Choi 11/2016

Subject to change at the discretion of the radiologist due to clinical circumstances.

MRI Midfoot Stress Fracture



Diagnostic & Preventative Imaging Center

Sequence	Plane	FOV	Thickness	Gap	NSA	F/S	PE x RO Matrix	TI	TR	TE	Comments
Coronal LOC	Cor	28 x 28	5.0	1.0	1	-	128 x 256	-	2000	15	
3 Plane LOC	-	25 x 25	6.0	0.0	1	-	128 x 256	-	119	9	
Shim	-	28 x 28	5.0	5.0	1	-	64 x 64	-	200	4.8	
T2 FS Axial	Ax	14 x 14	3.5	0.3	1	Light	224 x 256	-	4550	60	Short Axis to Metatarsal
T1 Axial	Ax	14 x 14	3.5	0.3	1	-	256 x 336	-	375	12	Short Axis to Metatarsal
T1 Sagittal	Sag	14 x 14	3.0	0.3	1	-	256 x 320	-	603	12	Sagittal to Metatarsal
STIR Sagittal	Sag	14 x 14	3.0	0.3	1	-	192 x 256	145	7073	60	Sagittal to Metatarsal
T1 Coronal	Cor	14 x 14	3.0	0.3	1	-	224 x 256	-	575	10	Long Axis to Metatarsal
T2 FS Coronal	Cor	14 x 14	3.0	0.3	1	Light	224 x 256	-	4656	60	Long Axis to Metatarsal
<i>Optional Contrast</i>											
T1 FS Axial Post	Ax	14 x 14	3.5	0.5	2	Light	192 x 256	-	650	10	
T1 FS Sagittal Post	Sag	14 x 14	3.0	0.3	3	Light	192 x 256	-	570	10	
T1 FS Coronal Post	Cor	14 x 14	3.0	0.3	1	Light	192 x 256	-	650	10	

Indications

Without Contrast: Midfoot stress fracture, Running injury, Runner

With & Without Contrast: Bone and Soft Tissue Masses, Infection of the Bone and Soft Tissue

****Matrix/TR/TE values will vary between machines. Use your own discretion when selecting these values****

Reviewed by Dr. Choi 11/2016

Subject to change at the discretion of the radiologist due to clinical circumstances.

MRI Plantar Plate/Turf Toe



Diagnostic & Preventative Imaging Center

Sequence	Plane	FOV	Thickness	Gap	NSA	F/S	PE x RO Matrix	TI	TR	TE	Comments
Coronal LOC	Cor	28 x 28	5.0	1.0	1	-	128 x 256	-	2000	15	
3 Plane LOC	-	25 x 25	6.0	0.0	1	-	128 x 256	-	119	9	
Shim	-	28 x 28	5.0	5.0	1	-	64 x 64	-	200	4.8	
PD FS Axial	Ax	14 x 14	3.5	0.3	1	Light	224 x 256	-	3500	30	Short Axis: 1st MTP
T1 Axial	Ax	14 x 14	3.5	0.3	1	-	256 x 336	-	375	12	Short Axis: 1st MTP
T1 Sagittal	Sag	14 x 14	3.0	0.3	1	-	256 x 320	-	603	12	Sagittal: 1st MTP
PD FS Sagittal	Sag	14 x 14	3.0	0.3	1	Light	192 x 256	-	3500	30	Sagittal: 1st MTP
T1 Coronal	Cor	14 x 14	3.0	0.3	1	-	224 x 256	-	575	10	Long Axis: 1st MTP
PD FS Coronal	Cor	14 x 14	3.0	0.3	1	Light	224 x 256	-	3500	30	Long Axis: 1st MTP

Indications

Without Contrast: 1st MTP Pain, Evaluate plantar plate

With & Without Contrast: Bone and Soft Tissue Masses, Infection of the Bone and Soft Tissue

****Matrix/TR/TE values will vary between machines. Use your own discretion when selecting these values****

Reviewed by Dr. Choi 11/2016

Subject to change at the discretion of the radiologist due to clinical circumstances.

Body MRI General Comments



1. All body imaging should be performed on a 1.5 T magnet unless body habitus necessitates the larger bore of the 3 T.
2. DWI is now considered standard protocol for all solid organ or mass workup with MRI.
3. Blade or propeller techniques for T2WI should be performed whenever possible in the setting of a poor breath-holder or other movement. These techniques should not be used otherwise.
4. If not using Eovist for liver MRI, omit only the delayed hepatocyte phase.
5. Continue to contact a radiologist for female pelvis MRI protocol = "Nish Pelvis" vs. "King Pelvis". Please note that all female pelvis MRI should have a straight sagittal T2 (not FS) and a T1 FS Pre GAD.
6. Contrast dose is weight based, per manufacturer guidelines, except when using Eovist. Patients who receive Eovist should always be given 10 mL of contrast.

MRI Chest

Pectus Excavatum



Diagnostic & Preventative Imaging Center

1. 3 Plane LOC
2. Sagittal HASTE - Free breathing
3. Axial HASTE - Respiratory Navigator/(BH) - Coverage: Entire chest to include region of pectus deformity as seen on sagittal sequence (Series 2)

Comments: (BH) = Breath Hold

Indications

Without Contrast: Evaluate pectus deformity; Haller index

****Values will vary between machines. Use your own discretion when selecting values.****

Reviewed by Dr. Becker 11/2023

Subject to change at the discretion of the radiologist due to clinical circumstances.

MRI Liver



Diagnostic & Preventative Imaging Center

1.5 T Magnet

Eovist 10 mL for all patients except young peds; Call radiologist for large patients to consider dose doubling.

No Eovist if Bilirubin at or above 3 mg/dL

If not using Eovist, omit #9

If ordered with MRCP, must do before administration of Eovist

1. 3 Plane LOC, Non-Breath Hold

2. Coronal HASTE Localizer - (BH) - Must include superior dome of diaphragm

3. Axial In/Out - (BH) - Top of diaphragm through duodenal c-loop; Use (BH) Localizer

4. ADC, DWI B50, B400 and B800

5. Axial FLASH FS, Pre GAD - Same as Series 3; Run immediately before GAD dose.

ST = 4mm, no gap

Post GAD FLASH (FS): Inject 1 mL/sec and 20 mL NS chaser at 2 mL/sec; Run 4 acquisitions - 1st = 20 sec delay, may need 30 sec delay if CHF/over 70 y/o; 2nd = Allow a breath then run again; 3rd = ~70 sec after injection; 4th = ~4 min after injection

****Do not bolus track with Eovist.**

****Optimal hepatic arterial phase is when the hepatic artery is heavily contrasted and there is a trace amount of contrast in the portal vein.****

6. Axial T2 FS with TE 90 - Same coverage as Series 3; Respiratory gated; Use non-breath hold Loc; User propeller technique if possible on breathing pts, but ONLY when T2's are poor due to breathing or other motion

7. Axial T2 FS, long TE (TE 180) - Match Series 6

8. T1 FS Axial and Coronal - Long delays after these T2WI Sequences; Must be 20 minutes after injection; Use FA 40 degrees for these delayed images only, 1.8mm

Indications

With and Without Contrast: Mass/Lesion seen on other imaging, Increased Liver Enzymes

****Values will vary between machines. Use your own discretion when selecting values.****

Reviewed by Dr. King 12/2018

Subject to change at the discretion of the radiologist due to clinical circumstances.

MRCP



1 cup of water (~8 oz) right before exam.

Call radiologist if known ascites

****Call radiologist if clinical statement is for infection or tumor. This may warrant contrast.****

1. 3 Plane LOC, Non-Breath Hold
2. Coronal HASTE Localizer - Navigator, center slices on liver, ensure dome is covered
3. Axial T2 HASTE FS with Nav - Cover bile ducts
4. Coronal T2 HASTE FS with Nav - Cover bile ducts
5. Coronal 3D TSE with Navigator - Cover bile ducts

Comments: Send dataset to 3D Workstation (Vitrea Bridge or TeraRecon)
Call radiologist for Secretin Stimulation MRCP, if needed. This is done at IMMC.

Indications

Without Contrast: Common Bile Duct Dilation, Pancreatic Duct Dilation

****Values will vary between machines. Use your own discretion when selecting values.****

Reviewed by Dr. King 4/2016

Subject to change at the discretion of the radiologist due to clinical circumstances.

MRI Renal



Water Prep and IV

1. 3 Plane LOC, Non-Breath Hold
2. Coronal HASTE Localizer - (BH)
3. Axial In/Out - (BH) - Use (BH) Loc (Do not alter transmit gain)
4. Axial T2 FS with TE ~ 140. Resp Gated, use Non-Breath Hold Loc to determine superior starting location, same end as in-phase axials
5. ADC, DWI B50, B400 and B800
6. Axial FLASH FS, Pre GAD
- 7.-9. Axial FLASH, Post GAD Dynamics - 2 mL gad/sec and 20 mL saline flush at 2 mL/sec. Run 3 dynamic acquisitions T1 Axial FS - 25 seconds after injection, then at 100 seconds, then at 10 minutes
10. Coronal Post at 10 minutes

Comments: (BH) = Breath Hold

Do subtractions for all post-contrast acquisitions if renal mass is T1 bright.

Indications

With and Without Contrast: Mass/Cyst seen on other imaging, Decreased Kidney Function

****Values will vary between machines. Use your own discretion when selecting values.****

Reviewed by Dr. King 4/2016

MRI Adrenal



Diagnostic & Preventative Imaging Center

Body Array

1. 3 Plane Localizer, Non-BH
2. Coronal HASTE T2 Localizer - (BH) - Cover adrenal glands +/- mass
3. Axial HASTE T2 - (BH) - Cover both adrenal glands; Use (BH) localizer to determine coverage
4. Axial HASTE T2 FS - (BH) - Same location as Series 3
5. Axial T1 In/Out Phase - (BH) - Same location as Series 3
6. Axial DWI 50-400-800
***Please send only b800 and ADC map*
7. Axial T1 FS - (BH) - Same location as Series 3

CONTRAST

8. Axial T1 FS Arterial - (BH) - Same location as Series 3
9. Axial T1 FS - Immediately after Arterial phase (Series 8), allowing time for patient to exhale and perform second set of breathing instructions - (BH) - Same location as Series 3
10. Axial T1 FS - Run scan at 150 seconds after contrast injection - (BH) - Same location as Series 3

Comments: (BH) = Breath Hold

Indications

Without Contrast: Mass seen on other imaging

****Values will vary between machines. Use your own discretion when selecting values.****

Reviewed by Dr. Becker 4/2025

Subject to change at the discretion of the radiologist due to clinical circumstances.

MRI Pancreas



Diagnostic & Preventative Imaging Center

***If following pancreatic cancer, or after whipple procedure for any reason, use Eovist and cover entire liver.**

Include 20 minute delayed FatSat through entire liver. Use timing for post-contrast series as per Liver protocol.

IV and water

1. 3 Plane LOC, Non-Breath Hold
2. Coronal HASTE Localizer - (BH) - Do as many slices as possible in the breath hold.
3. Axial In/Out - Cover top of diaphragm though c-loop of duodenum or bottom of the liver (whichever is lowest), use (BH) LOC
4. ADC, DWI B50, B400, B800
5. Axial T2 RT FS, RG
6. 3D MRCP, include rotating MIPS
7. Axial FLASH FS Pre-GAD THIN ST/SG 3.0/0 (no gaps), just cover pancreas
- 8.-11. Axial FLASH Post-GAD, like #5, first 25 seconds after injection, then breath and run second phase, then another phase at 70 seconds. Fourth phase at 4 minutes.

Comments: (BH) = Breath Hold

If bolus tracking, run first scan 8 seconds after blush in abdominal aorta.

If working up pancreas cancer for metastatic disease, call radiologist. Might need liver instead.

****Values will vary between machines. Use your own discretion when selecting values.****

Reviewed by Dr. King 6/2021

Subject to change at the discretion of the radiologist due to clinical circumstances.

MRI Enterography



Diagnostic & Preventative Imaging Center

1.5 T Magnet
Coil: Body Array

Setup:

1. NPO x 6 hours
2. 3 total bottles of Breeza at 15 minute increments over the course of 1 hour prior to scan
3. 1mg IM glucagon - IF patient is NOT insulin dependent diabetic
To be given 2 minutes before start of study/first localizer
Onset of action is 8-10 minutes, duration is 12-27 minutes

Series:

Series 1: Localizer
Series 2: Localizer BH
Series 3: Cor T2 HASTE LOC
Series 4: Cor T2 cine TruFISP Free Breath

Series 5: Cor T2 HASTE
Series 6 Ax T2 HASTE
Series 7: Ax T2 HASTE FS Composed
Series 8: Cor T2 TruFISP FS

Series 9: Ax T1 FS pre, breath hold
Series 10: Coronal T1 FS pre, breath hold

Setup: Contrast - Gadavist 0.15 mL/kg, 3cc/second

Series 11: Cor T1 FS 3D VIBE POST (40 seconds)
Series 12: Cor T1 FS 3D VIBE POST (2 minutes)
Series 13: Ax T1 FS VIBE POST

Series 14: FB DW 50-800 composed
***Please send only b800 and ADC map*

Comments: (BH) = Breath Hold

****Values will vary between machines. Use your own discretion when selecting values.****

Reviewed by Drs. Becker, King and Smith 1/2023

Subject to change at the discretion of the radiologist due to clinical circumstances.

MRI of Right Sided Abdominal Pain in Pregnancy



1.5 T Phased Array Surface Coil
Non Contrast Technique

1. Axial, Coronal, Sagittal T2 SSFSE (4 skip 1) - Limit FOV to right abdomen unless patient is small then may need to expand coverage.
2. Axial dual echo T1 in/out phase AND T1 Fat Sat Axial.
3. Repeat Axial SSFSE T2 with above parameters with Fat Sat.
4. ****Call radiologist to review.**** May need multiplanar T2 FS's, may need additional imaging such as below or may be done.
5. T2 thick slab (slice thickness between 20-60 mm) SSFSE for patients with suspected choledocholithiasis or ureterolithiasis. This is optional.
6. Axial T2* = TR 30 msec, 45 degree flip, 3-skip-1, 256 x 128, 35 cm FOV.
7. DWI Coronal B-400 and B-800.

Indications

Without Contrast: Right-sided abdominal pain in pregnancy

****Values will vary between machines. Use your own discretion when selecting values.****

Reviewed by Dr. King 4/2016

Subject to change at the discretion of the radiologist due to clinical circumstances.

MRI Female Pelvis

Generic



Diagnostic & Preventative Imaging Center

Bowel Prep - Avoid bulky, high fiber and spicy foods, and carbonated beverages the day prior to and the day of the examination.

Foods to avoid - Nuts, food with seeds, bulky high-fiber foods, juices with pulp, spicy foods, carbonated beverages.

Acceptable foods - Soup, Jell-O, pudding, yogurt, white bread, rolls without seeds, white rice, plain white pasta noodles

NPO for 4 hours prior to exam. Medications may be taken with sips of water only.

For diagnoses involving the cervix and uterus, including endometriosis, administer 20 mL ultrasound gel to the vagina. Patient may administer themselves. Do not administer gel to any patient with an unbroken hymen. Contact radiologist with questions.

1. 3 Plane LOC
2. Coronal HASTE - Sacrum through pelvic cavity
3. Axial T1 - Aortic bifurcation through 1 slice below vaginal canal; 24-26 FOV, use smallest possible; R→L phase encode
4. Axial T2 - Same as Series 3
5. Axial STIR - Top of iliac crests through lesser trochanter; FOV to include bony pelvis, do not need to include all of the muscles or subcutaneous fat
6. Axial DWI 50-400-800
***Please send only b800 and ADC map*
7. Sagittal T2 - Include all of female anatomy, femoral head to femoral head; 24-26 FOV, use smallest possible; S→I phase encode
8. Coronal T2 - Sacrum through pelvic cavity; 24-26 FOV, use smallest possible
9. Axial T1 FS Pre - (BH) - Cover at least from the top of uterus through the vaginal canal, possibly as high as the aortic bifurcation; 32-36 FOV, phase AP, adjust FOV so that 3/4 of FOV just covers skin to skin

Post GAD - Inject and wait 10-12 seconds, 3 mL/sec

10. Axial T1 FS Post - (BH) - Arterial
11. Axial T1 FS Post - (BH) - At 60 seconds
12. Sagittal T1 FS Post - (BH)

Comments: 1. (BH) = Breath Hold

Indications

With and Without Contrast: Pelvic Pain, Mass seen on other imaging, Abnormal Bleeding, Amenorrhea, Fibroids

****Values will vary between machines. Use your own discretion when selecting values.****

Reviewed by Dr. Becker 6/2024

Subject to change at the discretion of the radiologist due to clinical circumstances.

MRI Female Pelvis

Uterine/Mullerian Formation Anomaly



Diagnostic & Preventative Imaging Center

Bowel Prep - Avoid bulky, high fiber and spicy foods, and carbonated beverages the day prior to and the day of the examination.

Foods to avoid - Nuts, food with seeds, bulky high-fiber foods, juices with pulp, spicy foods, carbonated beverages.

Acceptable foods - Soup, Jell-O, pudding, yogurt, white bread, rolls without seeds, white rice, plain white pasta noodles

NPO for 4 hours prior to exam. Medications may be taken with sips of water only.

1. 3 Plane LOC

2. Coronal HASTE - Sacrum through pelvic cavity

3. Axial T1 - Aortic bifurcation through 1 slice below vaginal canal; 24-26 FOV, use smallest possible; R→L phase encode

4. Axial T2 - Same as Series 3

5. Axial T2 SPAIR SPACE

6. Axial STIR

7. Axial DWI 50-400-800

***Please send only b800 and ADC map*

8. Sagittal T2 - Include all of female anatomy, femoral head to femoral head; 24-26 FOV, use smallest possible; S→I phase encode

9. Coronal T2 - Sacrum through pelvic cavity; 24-26 FOV, use smallest possible

10. #1 Oblique Axial T2 - PERPENDICULAR to the endometrial canal; 5mm skip 1mm

11. #2 Oblique Axial T2 - PARALLEL to the endometrial canal; 5mm skip 1 mm

12. Axial T1 FS Pre - (BH) - Cover at least from the top of uterus through the vaginal canal, possibly as high as the aortic bifurcation; 32-36 FOV, phase AP, adjust FOV so that 3/4 of FOV just covers skin to skin

****These studies can be completed without intravenous contrast; if the ordering provider specifically requests contrast, continue with acquisitions as below.*

Post GAD - Inject and wait 10-12 seconds, 3 mL/sec

13. Axial T1 FS Post - (BH) - Arterial

14. Axial T1 FS Post - (BH) - At 60 seconds

15. Sagittal T1 FS Post - (BH)

Comments: 1. (BH) = Breath Hold

Indications

Without Contrast: Workup for Uterine/Mullerian Formation Anomaly; Bicornuate, Septate, Didelphys, Rudimentary horn, etc.

****Values will vary between machines. Use your own discretion when selecting values.****

Reviewed by Dr. Becker 6/2024

Subject to change at the discretion of the radiologist due to clinical circumstances.

MRI Female Pelvis

Endometrial/Cervical/Vaginal Cancer



Diagnostic & Preventative Imaging Center

Bowel Prep - Avoid bulky, high fiber and spicy foods, and carbonated beverages the day prior to and the day of the examination.

Foods to avoid - Nuts, food with seeds, bulky high-fiber foods, juices with pulp, spicy foods, carbonated beverages.

Acceptable foods - Soup, Jell-O, pudding, yogurt, white bread, rolls without seeds, white rice, plain white pasta noodles

NPO for 4 hours prior to exam. Medications may be taken with sips of water only.

Administer 20 mL ultrasound gel to the vagina. Patient may administer themselves. Do not administer gel to any patient with an unbroken hymen.

Contact radiologist with questions.

1. 3 Plane LOC

2. Coronal HASTE - Sacrum through pelvic cavity

3. Axial T1 - Aortic bifurcation through 1 slice below vaginal canal; 24-26 FOV, use smallest possible; R→L phase encode

4. Axial T2 - Same as Series 3

5. Axial STIR - Top of iliac crests through lesser trochanter; FOV to include bony pelvis, do not need to include all of the muscles or subcutaneous fat

6. Axial DWI 50-400-800

***Please send only b800 and ADC map*

7. Sagittal T2 - Include all of female anatomy, femoral head to femoral head; 24-26 FOV, use smallest possible; S→I phase encode

8. Coronal T2 - Sacrum through pelvic cavity; 24-26 FOV, use smallest possible

9. Oblique Axial T2 - PERPENDICULAR to the endometrial canal (endometrial cancer), cervical canal (cervical cancer), or vaginal canal (vaginal cancer); 4 mm skip 0.5 mm; 20 FOV; 256x256; 3 NEX; R→L phase encode

10. Axial T1 FS Pre - (BH) - Cover at least from the top of uterus through the vaginal canal, possibly as high as the aortic bifurcation; 32-36 FOV, phase AP, adjust FOV so that 3/4 of FOV just covers skin to skin

Post GAD - Inject and wait 10-12 seconds, 3 mL/sec

10. Axial T1 FS Post - (BH) - Arterial

11. Axial T1 FS Post - (BH) - At 60 seconds

11. Sagittal T1 FS Post - (BH)

Comments: 1. (BH) = Breath Hold

Indications

With and Without Contrast: Endometrial, Cervical or Vaginal Cancer

****Values will vary between machines. Use your own discretion when selecting values.****

Reviewed by Dr. Becker 6/2024

Subject to change at the discretion of the radiologist due to clinical circumstances.

MRI Urethral Diverticulum



Diagnostic & Preventative Imaging Center

Patient needs to urinate just prior to exam.

Center FOV at the pubic symphysis.

1. 3 Plane LOC
2. Coronal T2 HASTE - Anterior pubic symphysis to sacrum
3. Axial T1 - Coverage of the urinary bladder and entire urethra; R→L phase encode
4. Axial T2 Fat Sat - Same as Series 3
5. Sagittal T2 Fat Sat - Coverage of the urinary bladder and urethra; S→I phase encode
6. Oblique Coronal T2 Fat Sat - Angle parallel to urethra, cover entire urethra and bladder
7. Axial Diffusion - Similar coverage and phase encode to sequence 3
8. Axial FS T1 Pre (BH) - Coverage of the urinary bladder and entire urethra; 32-36 FOV, 3/4 FOV; A→P phase encode

Post GAD - Inject and wait 10-12 seconds, 3 mL/sec

9. Axial T1 FS Post - (BH) - Arterial
10. Axial T1 FS Post - (BH) - At 60 seconds
11. Oblique Coronal FS T1 Post - (BH) - Same as series 6
12. Sagittal FS T1 Post - (BH) - Same as Series 5; 32-36 FOV, 3/4 FOV, A→P phase encode

Comments: 1. (BH) = Breath Hold

Indications

With and Without Contrast: Concern for Urethral Diverticulum

****Values will vary between machines. Use your own discretion when selecting values.****

Reviewed by Dr. Becker 6/2024

Subject to change at the discretion of the radiologist due to clinical circumstances.

MRI Male Pelvis



Diagnostic & Preventative Imaging Center

Bowel Prep - Avoid bulky, high fiber and spicy foods, and carbonated beverages the day prior to and the day of the examination.

Foods to avoid - Nuts, food with seeds, bulky high-fiber foods, juices with pulp, spicy foods, carbonated beverages.

Acceptable foods - Soup, Jell-O, pudding, yogurt, white bread, rolls without seeds, white rice, plain white pasta noodles

NPO for 4 hours prior to exam. Medications may be taken with sips of water only.

1. Localizer
2. Coronal T2 HASTE - Wide FOV
3. Sagittal T2
4. Axial T2
5. Axial STIR
6. Coronal T2 - Small FOV
7. Axial DWI 50-400-800
***Please send only b800 and ADC map*
8. Axial T1 IN/OUT of phase
9. Axial T1 FS Pre

GAD IV Contrast

10. Axial T1 FS Post - 15 second
11. Axial T1 FS Post - 70 second
12. Axial T1 FS Post - 2 minute
13. Sagittal T1 FS Post
14. Axial T1 FS Post - 4 minute

Indications

With and Without Contrast: Hematospermia

****Values will vary between machines. Use your own discretion when selecting values.****

Reviewed by Dr. Becker 6/2024

Subject to change at the discretion of the radiologist due to clinical circumstances.

MRI Perirectal Abscess



Diagnostic & Preventative Imaging Center

Glucagon, Water, Center FOV at pubic symphysis

1. 3 Plane LOC
2. Coronal Haste - Sacrum through pelvic cavity.
3. Set up perpendicular to anal canal. Axial T1 - Iliac crest through rectum and subcutaneous fat. If an abnormality, may go inferiorly into upper thigh. Phase right to left.
4. Axial T2 - Same as Series 3.
5. Sagittal T2 FS - Femoral head to femoral head. Include all pathology if it extends farther down. Phase superior to inferior.
6. Set up along anal canal. Coronal T2 - All of sacrum to anterior part of pubic symphysis.
7. Coronal STIR - Same as Series 6.
8. Axial STIR - Same as Series 3.
9. Axial Diffusion
10. Axial Flash FS Pre (BH) - Cover superiorly as much as a (BH) sequence will allow up to iliac crest. 32-36 FOV. Phase anterior to posterior.

Post GAD, inject and wait 10-12 sec, 3 mL/sec

11. and 12. Axial Flash FS Post (BH) - Same as Series 3.
13. Coronal Flash FS Post (BH) - Same as Series 6. 32-36 FOV. Use smallest FOV possible.

Comments: (BH) = Breath Hold

****Values will vary between machines. Use your own discretion when selecting values.****

Reviewed by Dr. Becker 11/2023

Subject to change at the discretion of the radiologist due to clinical circumstances.

MRI Breast



Diagnostic & Preventative Imaging Center

Sequence	Plane	FOV	Thickness	Gap	NSA	TI	PE x RO Matrix	FA	TR	TE	Comments
Coronal LOC FE_SLT	Cor	45 x 45	8.0	1.0	1	-	128 x 256	90	133	5	
Ax/Sag LOC FE_SLT	Sag	45 x 45	6.0	1.0	1	-	128 x 256	90	45	5	
MAP/Ref FE_MAP	Ax	65 x 65	8.0	0.0	1	-	64 x 64	20	235	4	
Ax T1 3D FFE	Ax	34 x 34	1.5 recon 0.7	0.0	1	-	356 x 336	10	6.2	3.2	
Shimming FE_AAS	Ax	37 x 37	5.0	10.0	1	-	32 x 32	70	4/9.6	200	
Ax F/S Dynamic FFE 3D	Ax	37 x 26	2.2 recon 1.1	0.0	1	-	368 x 256	10	5.5	2.5	Use lowest TR possible
Ax T2 F/S	Ax	34 x 23	3.0 recon 1.5	0.5	1	-	224 x 256	90	5200	70	Flop - 160

Comments:

****Axial Dynamic timing is vendor specific - Please verify with the radiologist before performing exam****

Ax Dynamic: Run Pre, Inject 2 mL per second, wait 50 seconds and run 4 additional passes (1.26 per pass)

****Resolution must stay below 1.0 per ACR**

****If any questions, please call Clive MRI (515-226-7442).**

****Matrix/TR/TE values will vary between machines. Use your own discretion when selecting these values****

Reviewed by Dr. Wolford 1/2020

Subject to change at the discretion of the radiologist due to clinical circumstances.