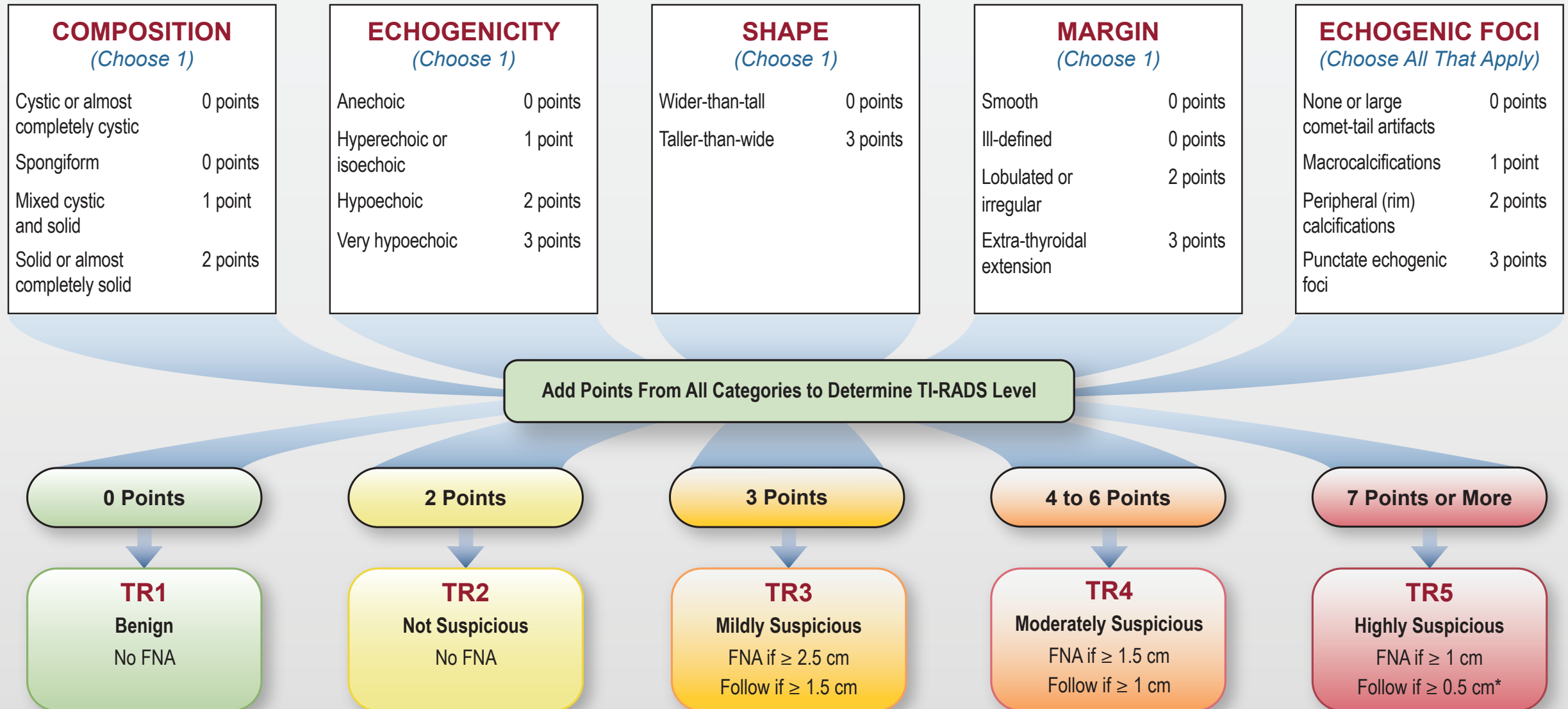




ACR Thyroid Imaging, Reporting and Data System Lexicon Directory

ACR TI-RADS



| COMPOSITION | ECHOGENICITY | SHAPE | MARGIN | ECHOGENIC FOCI |
|--|--|---|--|---|
| <p><i>Spongiform</i>: Composed predominantly (>50%) of small cystic spaces. Do not add further points for other categories.</p> <p><i>Mixed cystic and solid</i>: Assign points for predominant solid component.</p> <p>Assign 2 points if composition cannot be determined because of calcification.</p> | <p><i>Anechoic</i>: Applies to cystic or almost completely cystic nodules.</p> <p><i>Hyperechoic/isoechoic/hypoechoic</i>: Compared to adjacent parenchyma.</p> <p><i>Very hypoechoic</i>: More hypoechoic than strap muscles.</p> <p>Assign 1 point if echogenicity cannot be determined.</p> | <p><i>Taller-than-wide</i>: Should be assessed on a transverse image with measurements parallel to sound beam for height and perpendicular to sound beam for width.</p> <p>This can usually be assessed by visual inspection.</p> | <p><i>Lobulated</i>: Protrusions into adjacent tissue.</p> <p><i>Irregular</i>: Jagged, spiculated, or sharp angles.</p> <p><i>Extrathyroidal extension</i>: Obvious invasion = malignancy.</p> <p>Assign 0 points if margin cannot be determined.</p> | <p><i>Large comet-tail artifacts</i>: V-shaped, >1 mm, in cystic components.</p> <p><i>Macrocalcifications</i>: Cause acoustic shadowing.</p> <p><i>Peripheral</i>: Complete or incomplete along margin.</p> <p><i>Punctate echogenic foci</i>: May have small comet-tail artifacts.</p> |

*Refer to discussion of papillary microcarcinomas for 5-9 mm TR5 nodules.

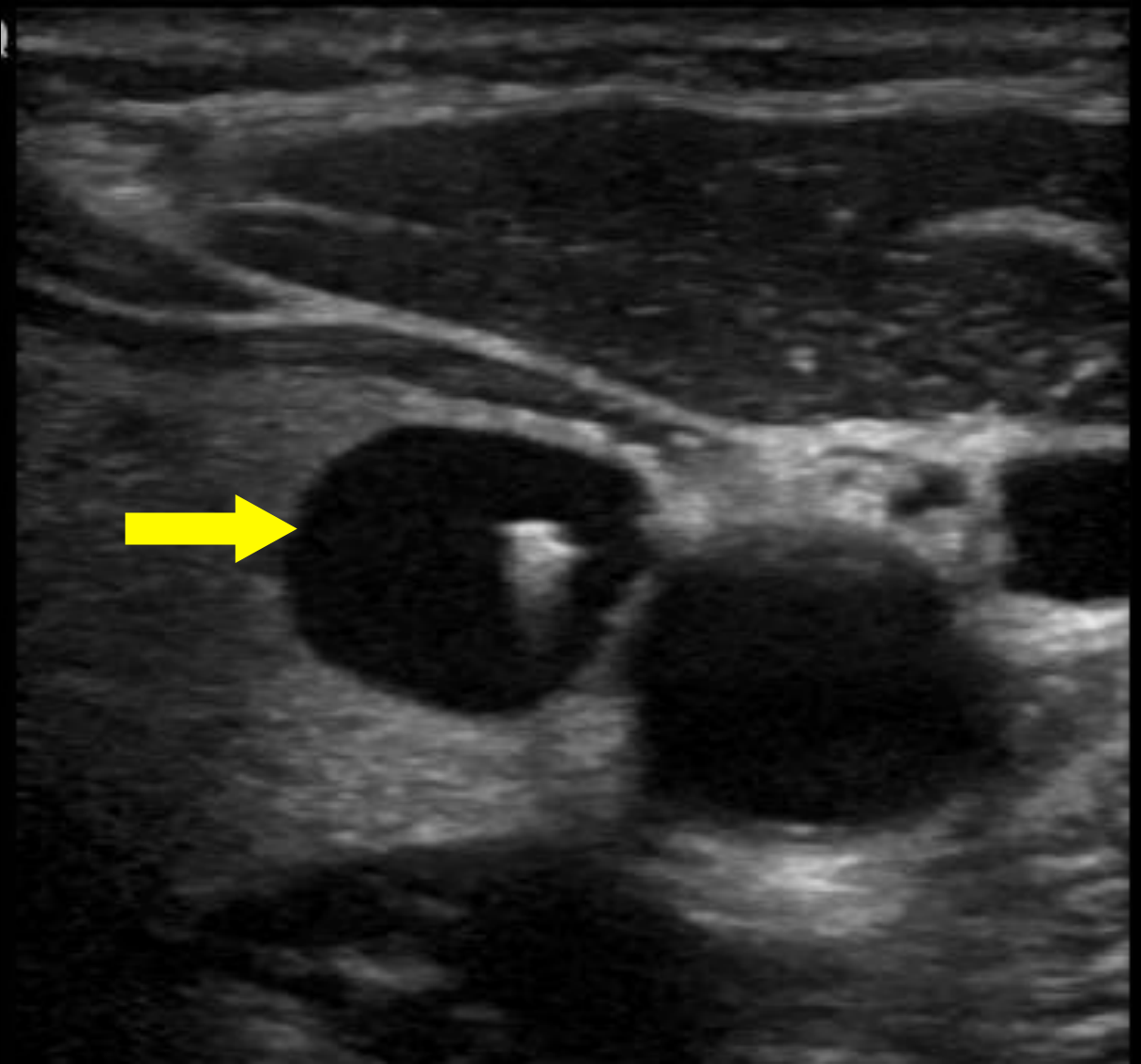
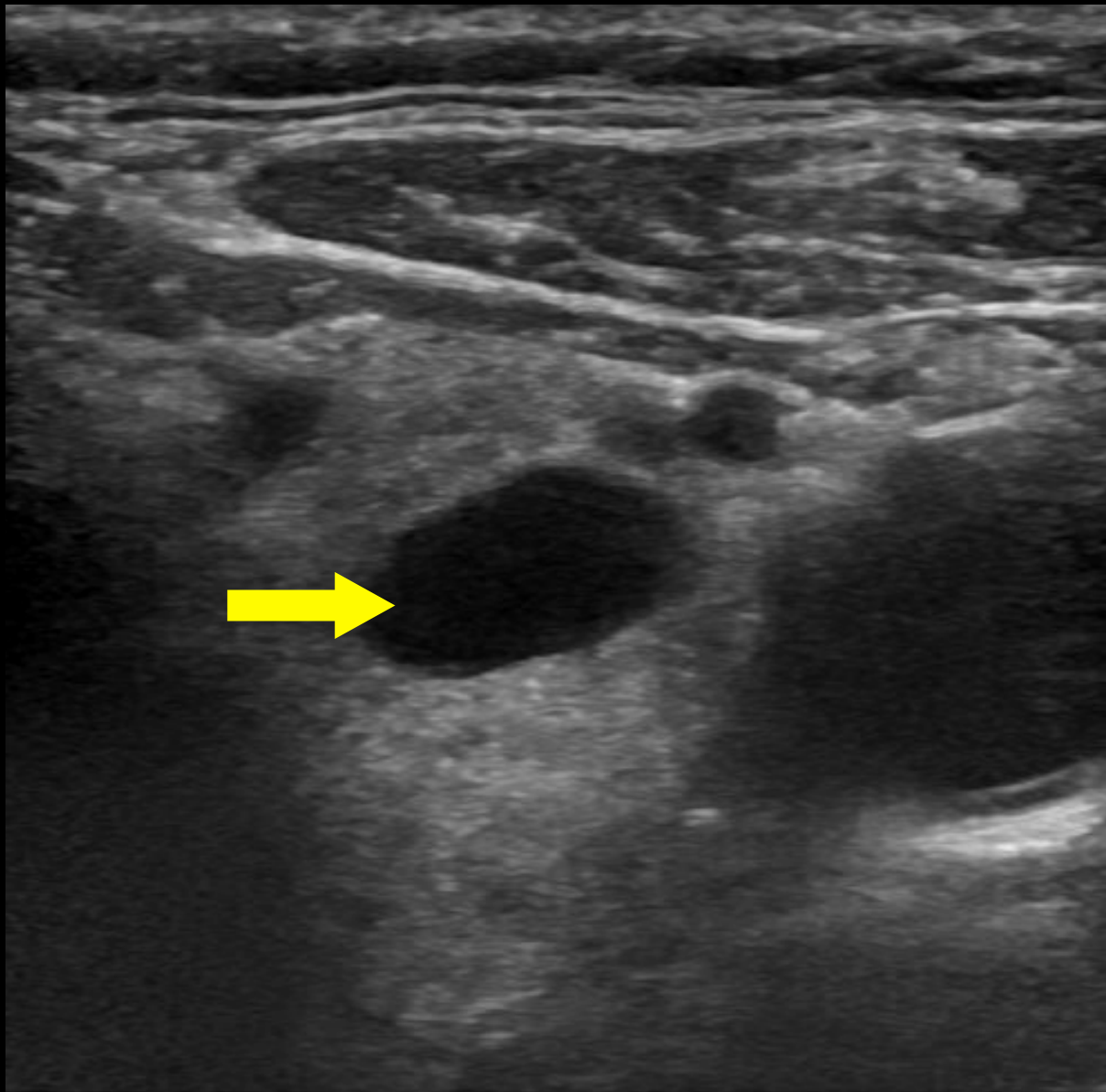
ACR TI-RADS Categories

- Composition - Choose 1
- Echogenicity - Choose 1
- Shape - Choose 1
- Margin - If more than one type, choose the most suspicious
- Echogenic foci - Choose all that apply

Assumptions

- If rim calcifications obscure the nodule completely, choose composition to be “solid” and echogenicity to be “isoechoic”.
- If the margin cannot be determined, choose “ill-defined margin”.
- If echogenicity cannot be determined, choose “isoechoic”.
- If composition cannot be determined, choose “solid”.

Composition: Cystic or almost completely cystic

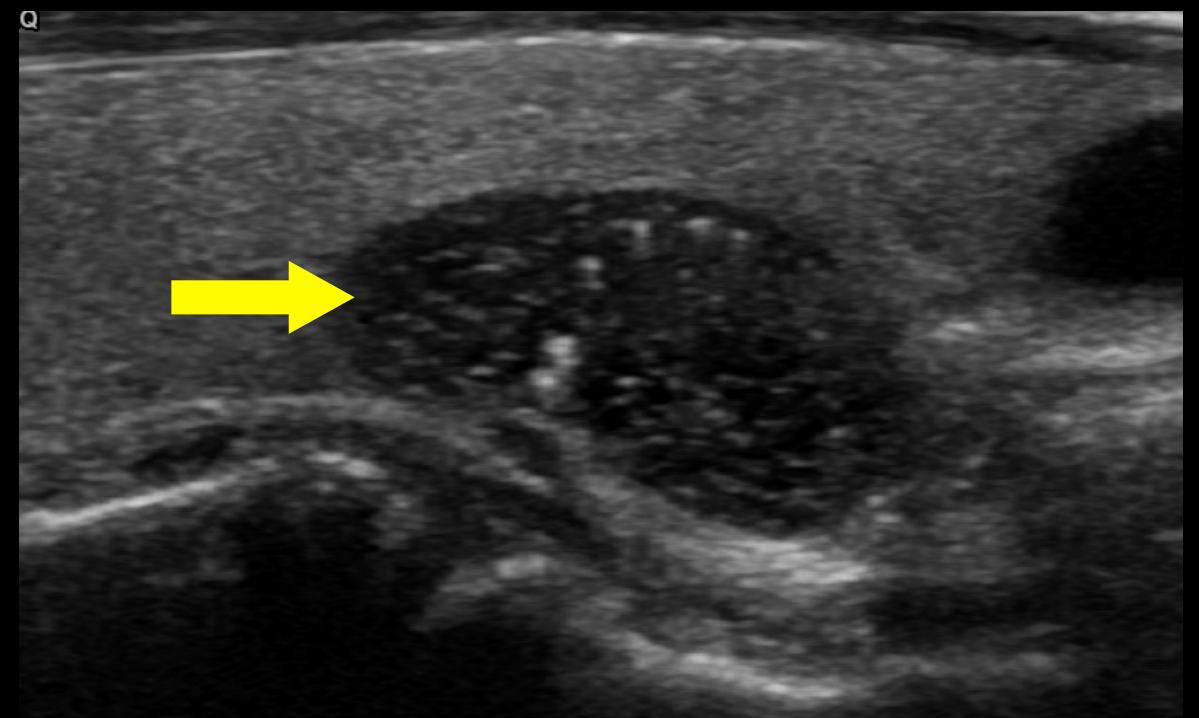
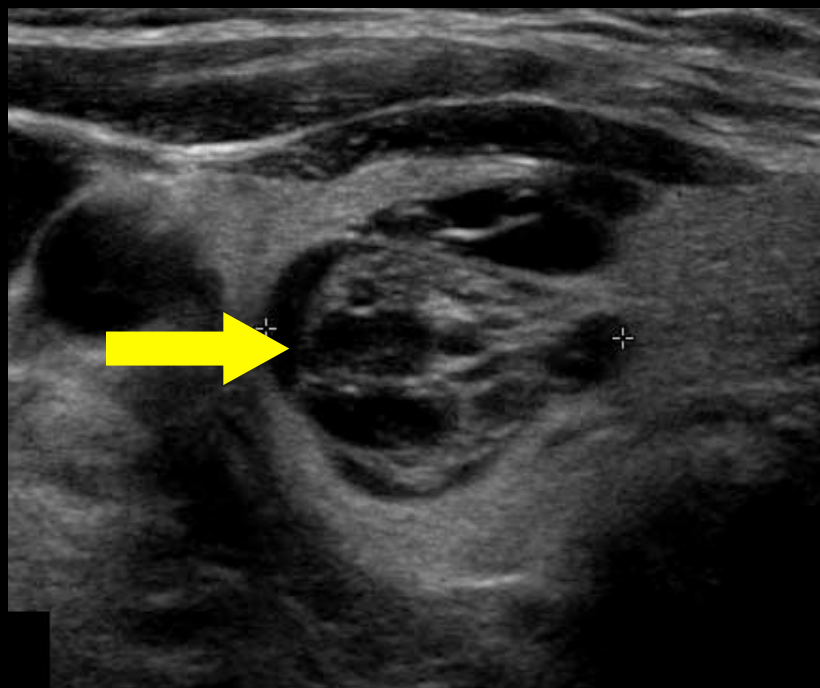
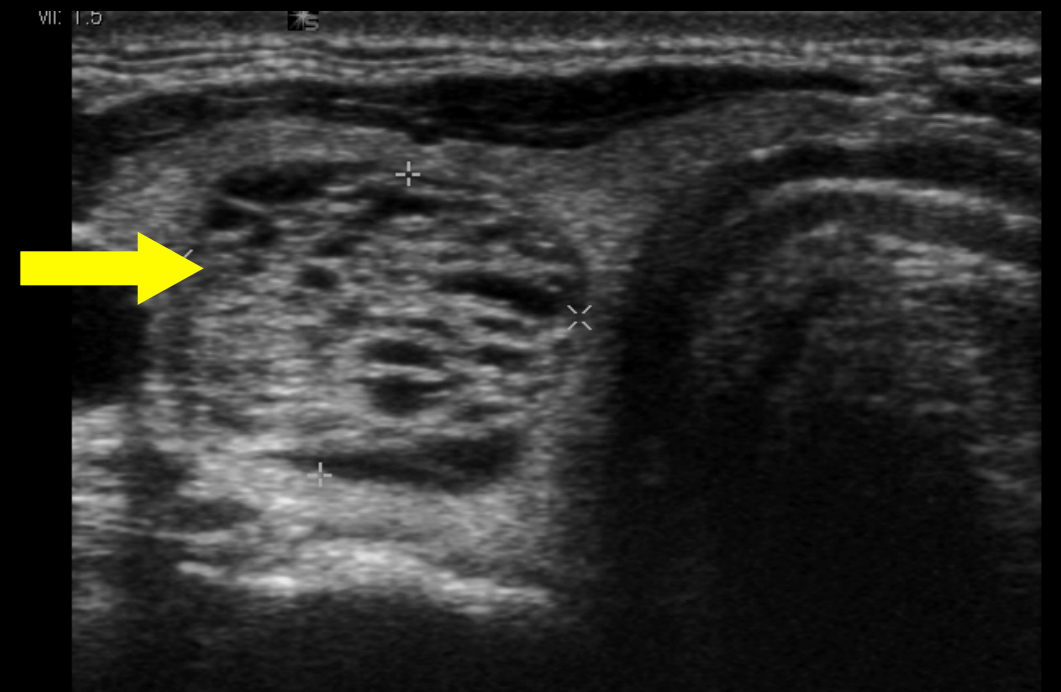
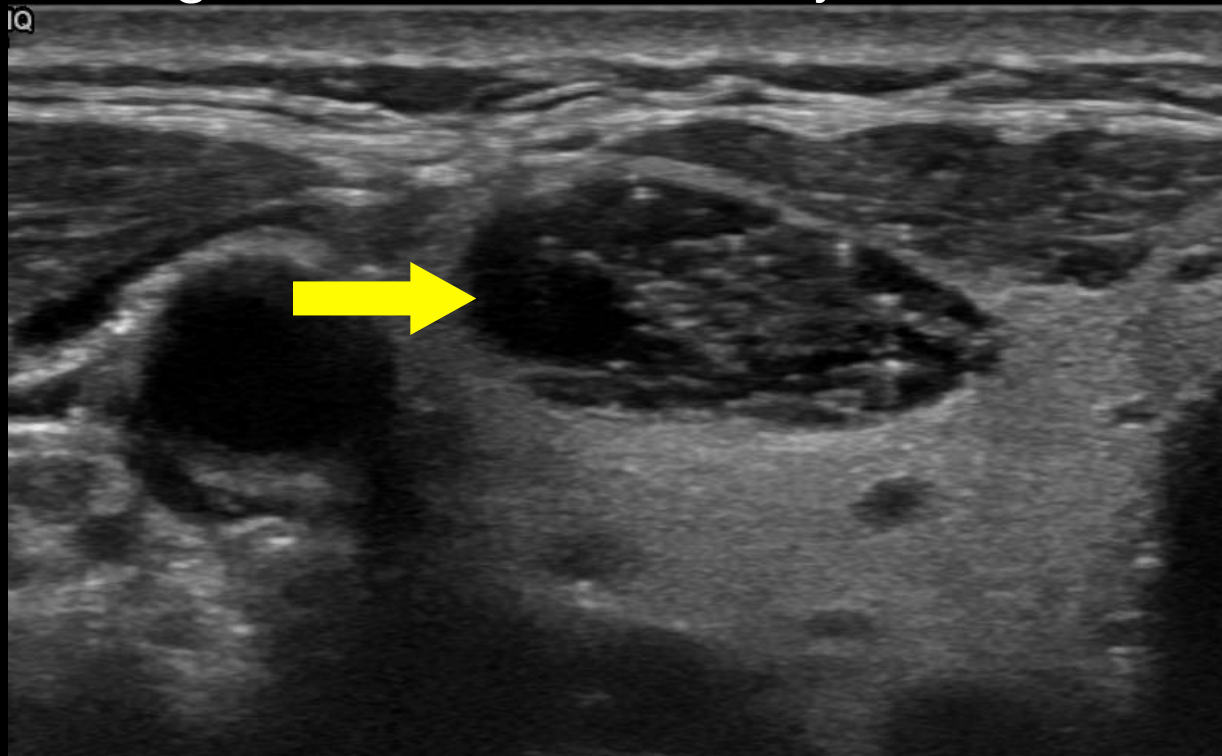


Entirely or nearly entirely cystic

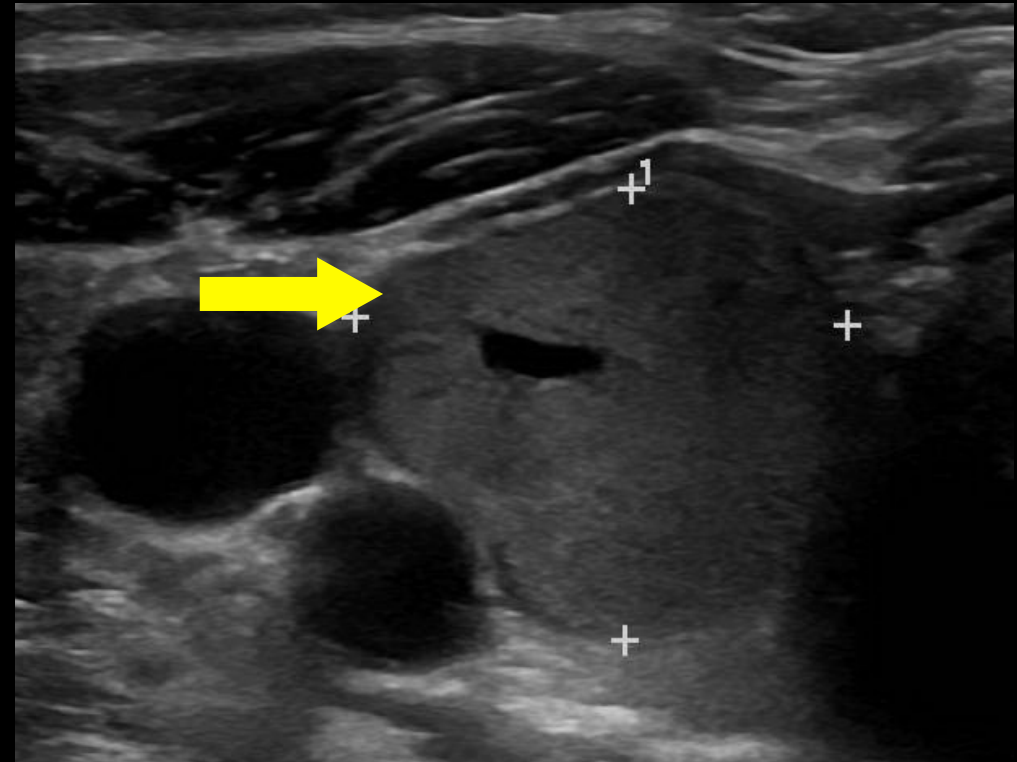
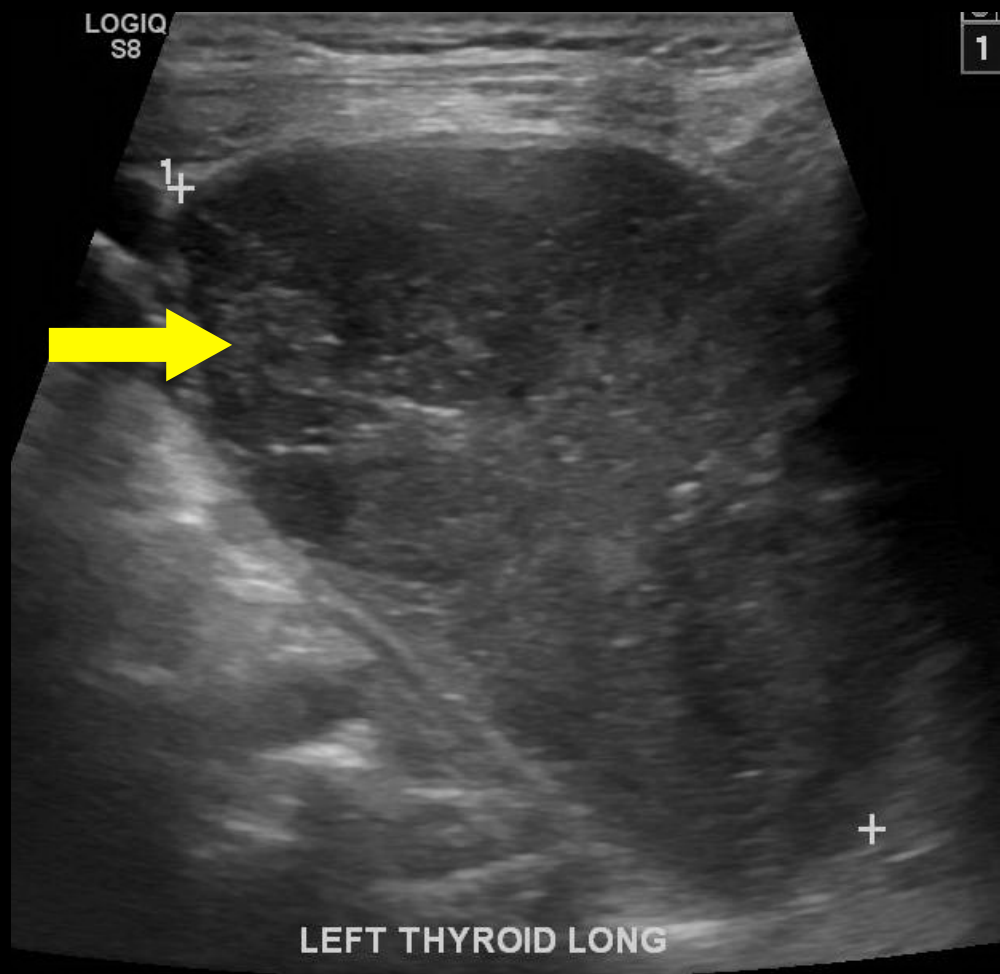
Composition: Spongiform

Composed predominately of tiny cystic spaces.

Spongiform is a benign finding. If there is concern for irregular margins or suspicious echogenic foci, reconsider your choice of spongiform.

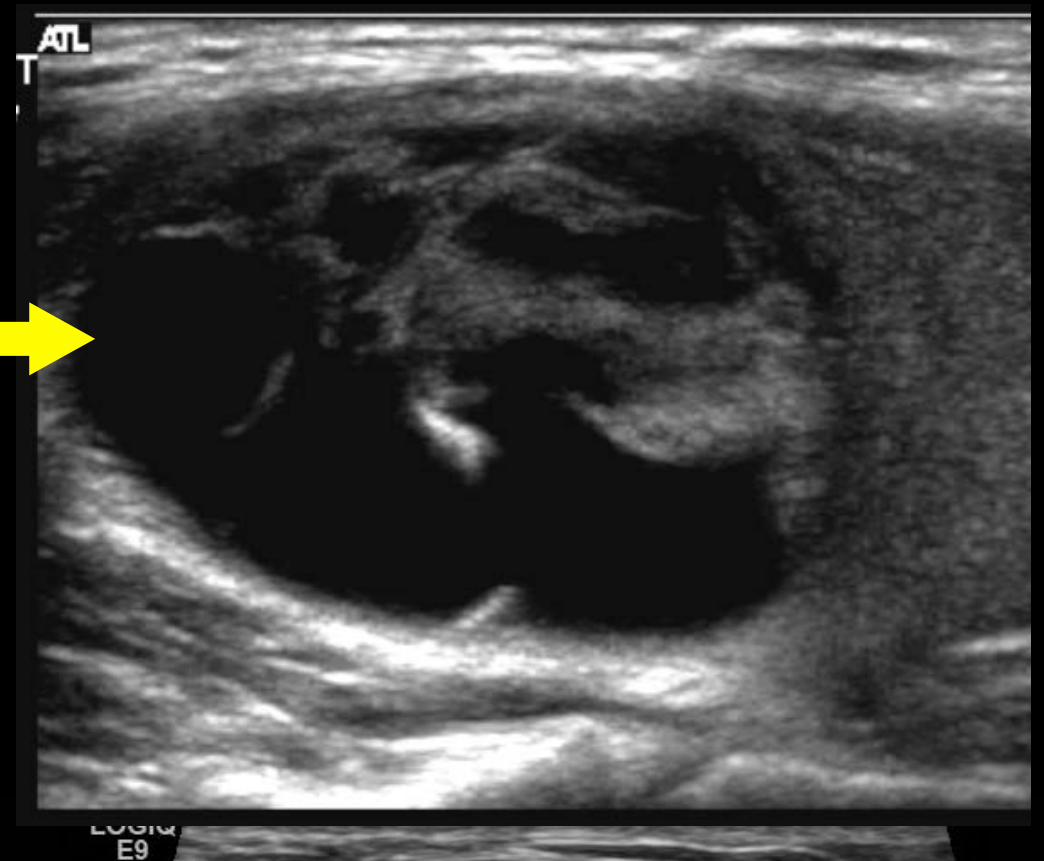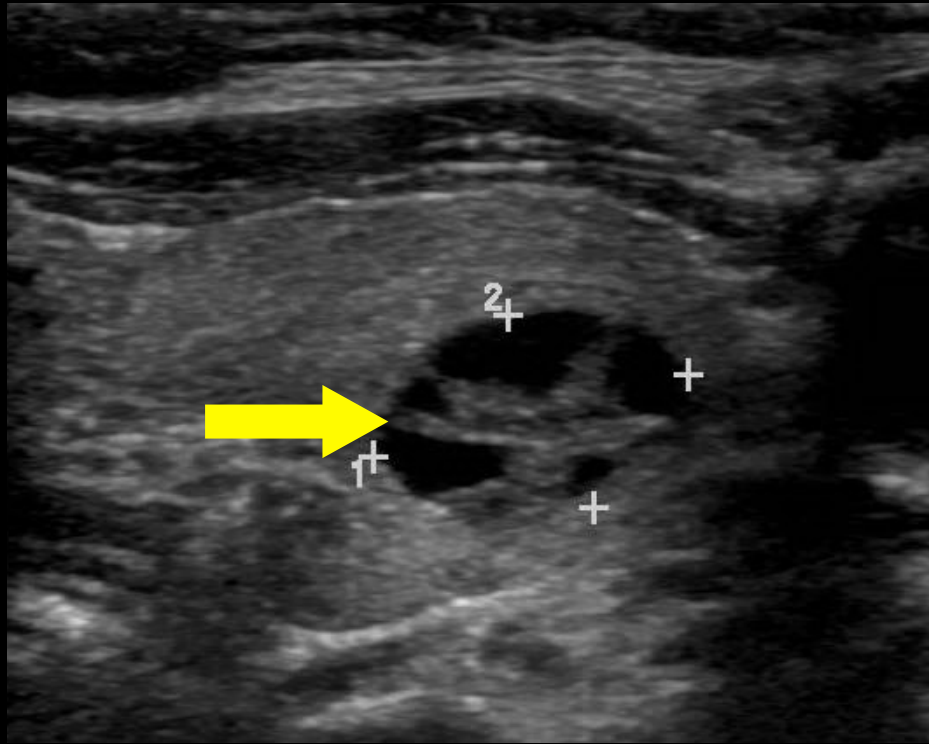


Composition: Solid or almost completely solid

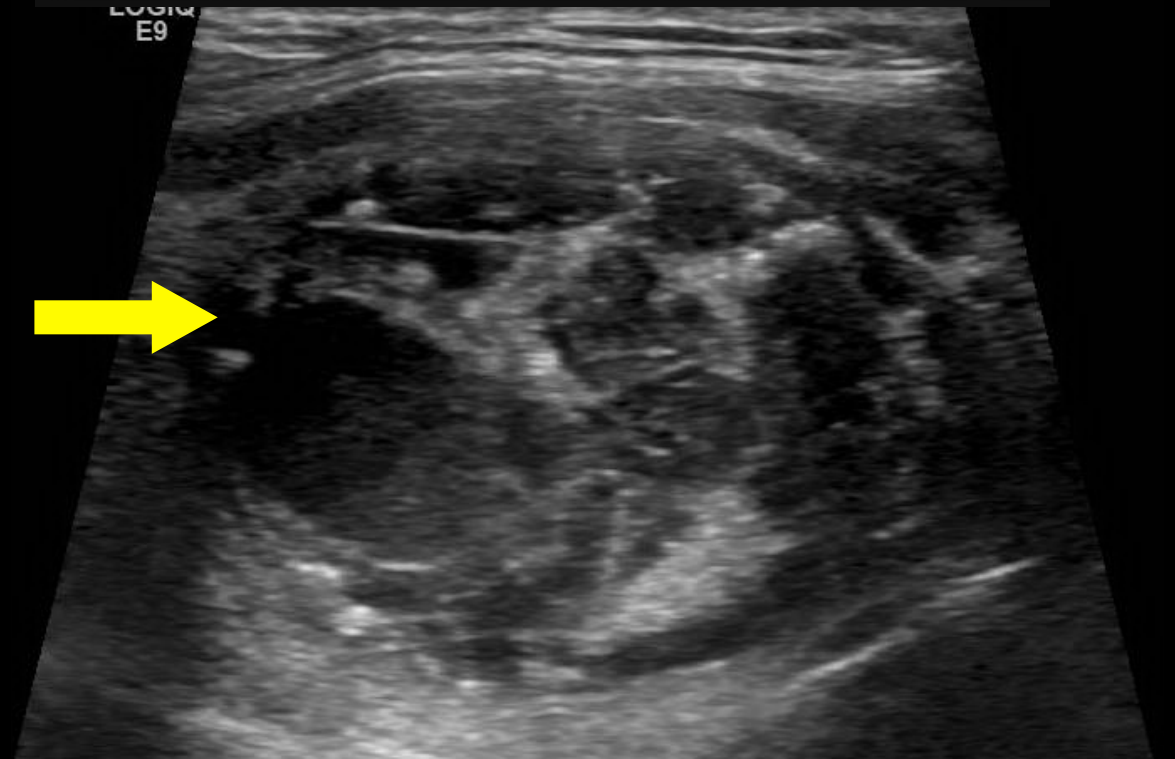


Composed entirely or nearly entirely of soft tissue, with only a few tiny cystic spaces

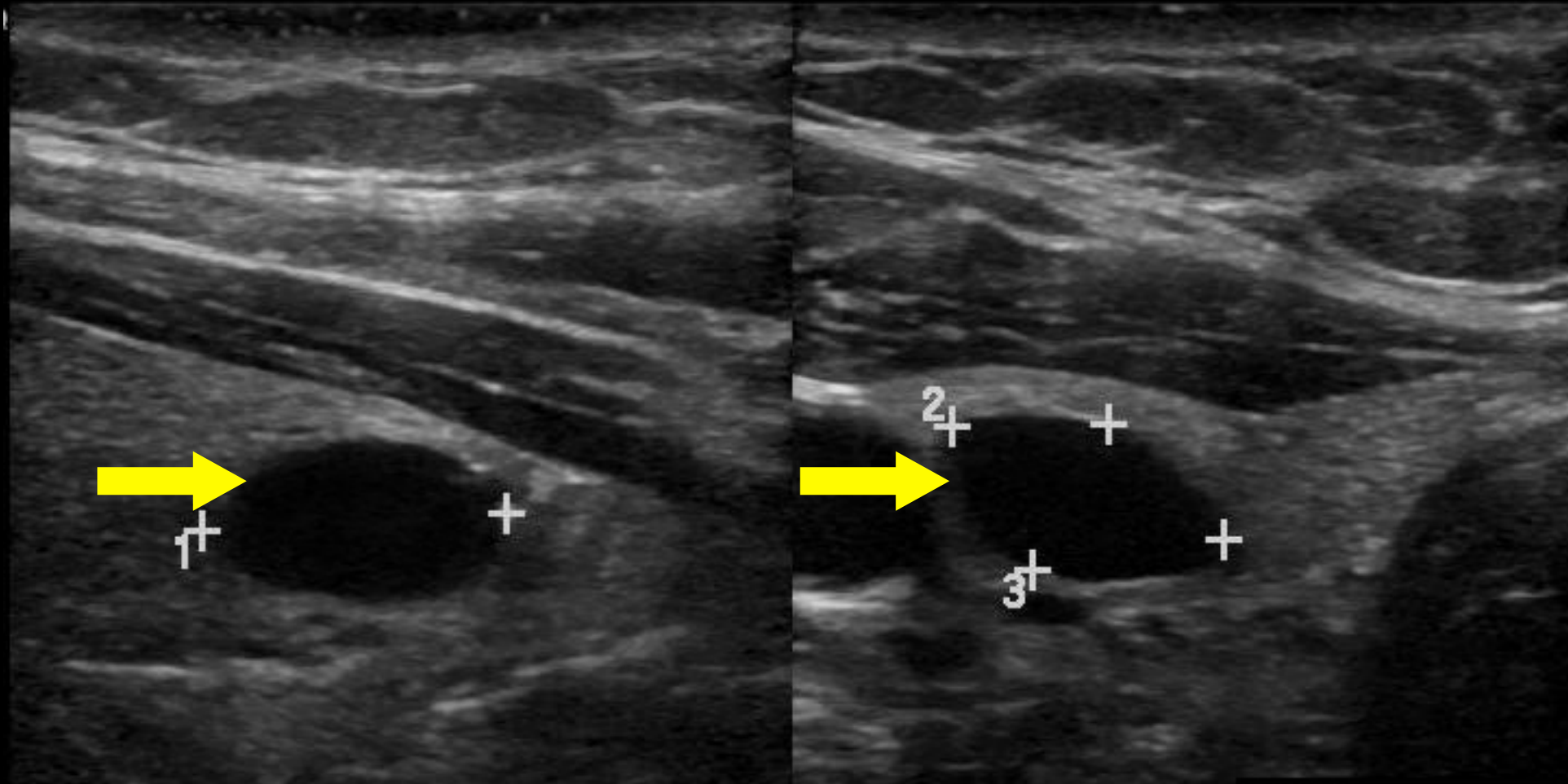
Composition: Mixed cystic solid



Composed of soft tissue and cystic spaces. Base all other lexicon nodule characteristics on the solid component.

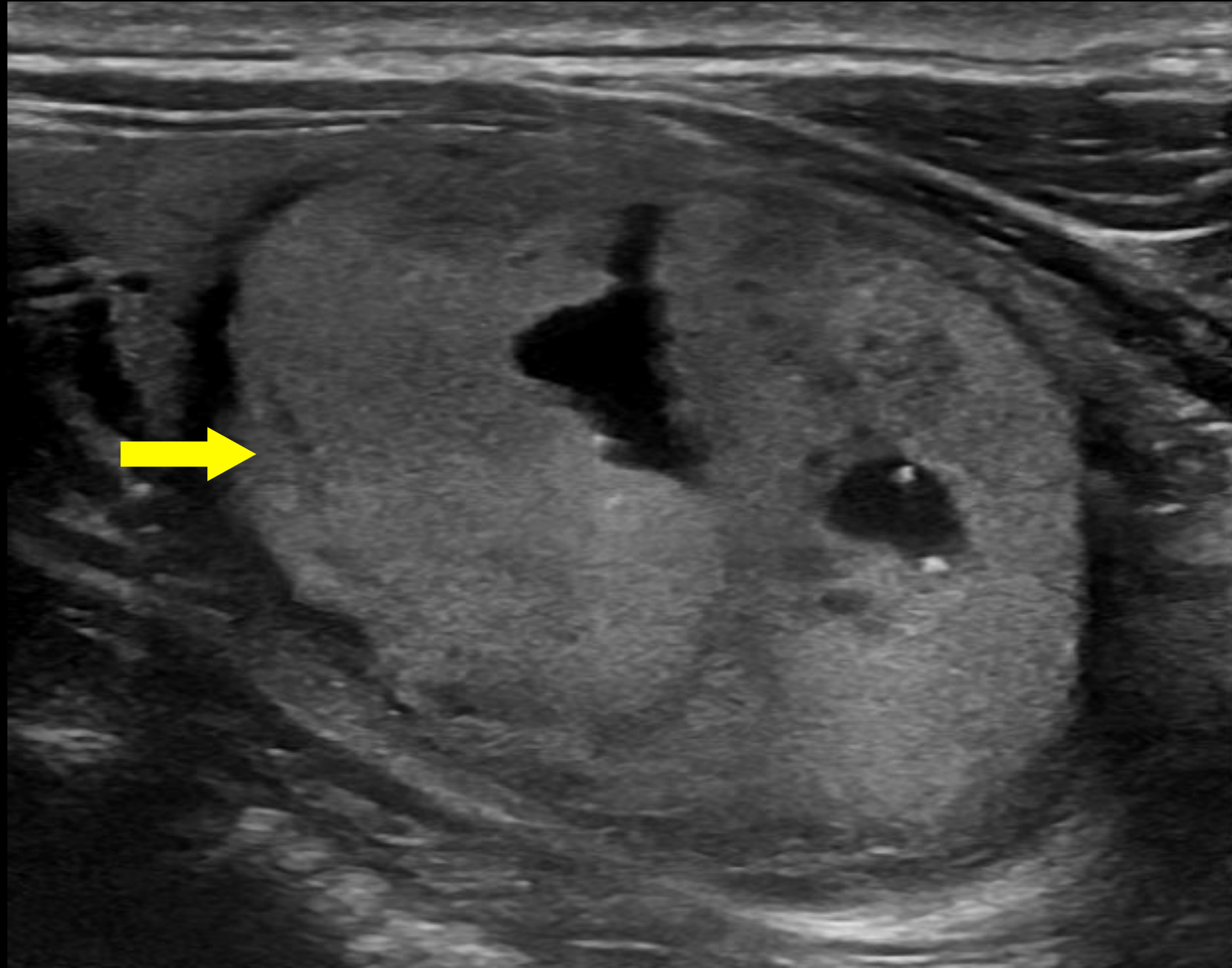


Echogenicity: Anechoic



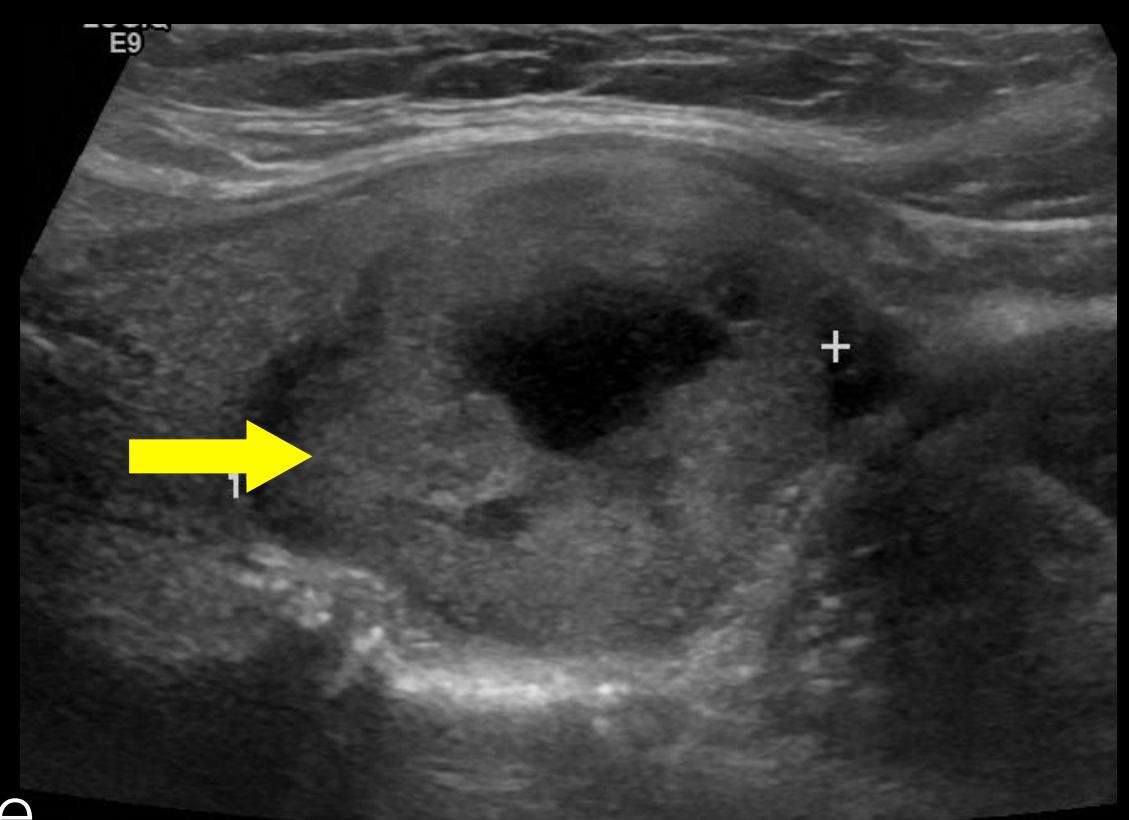
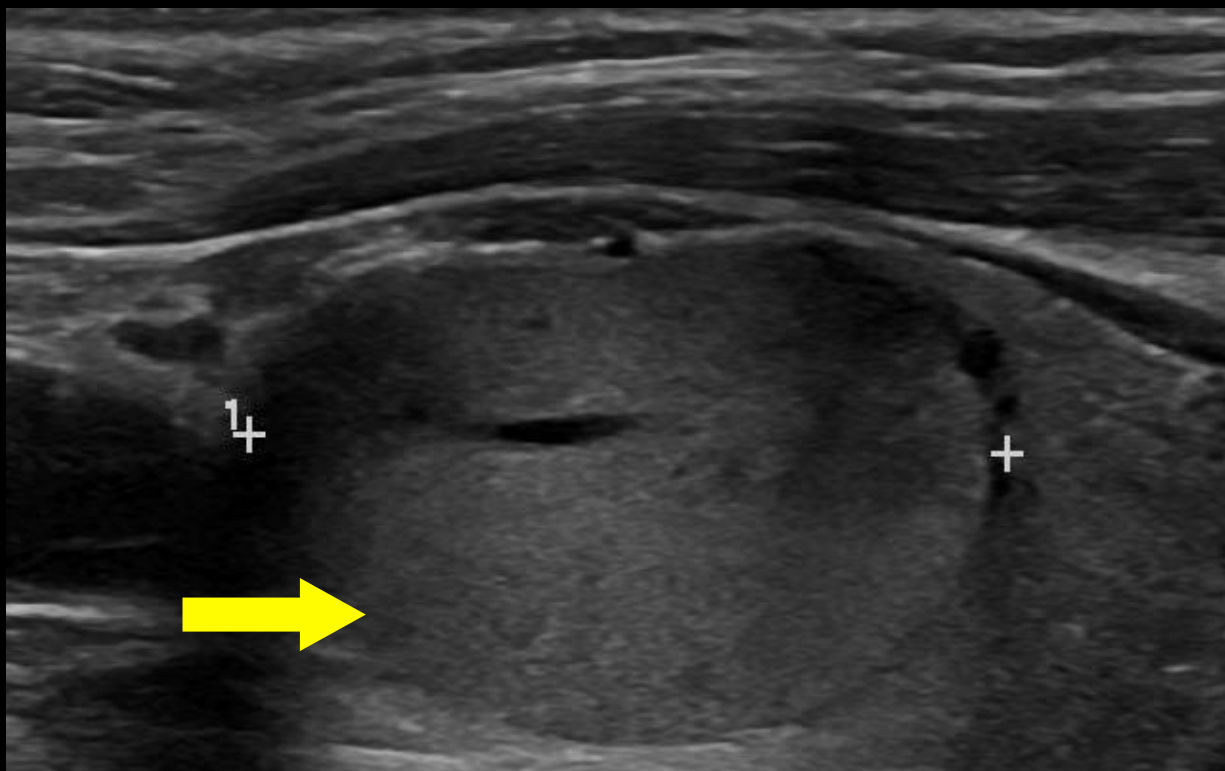
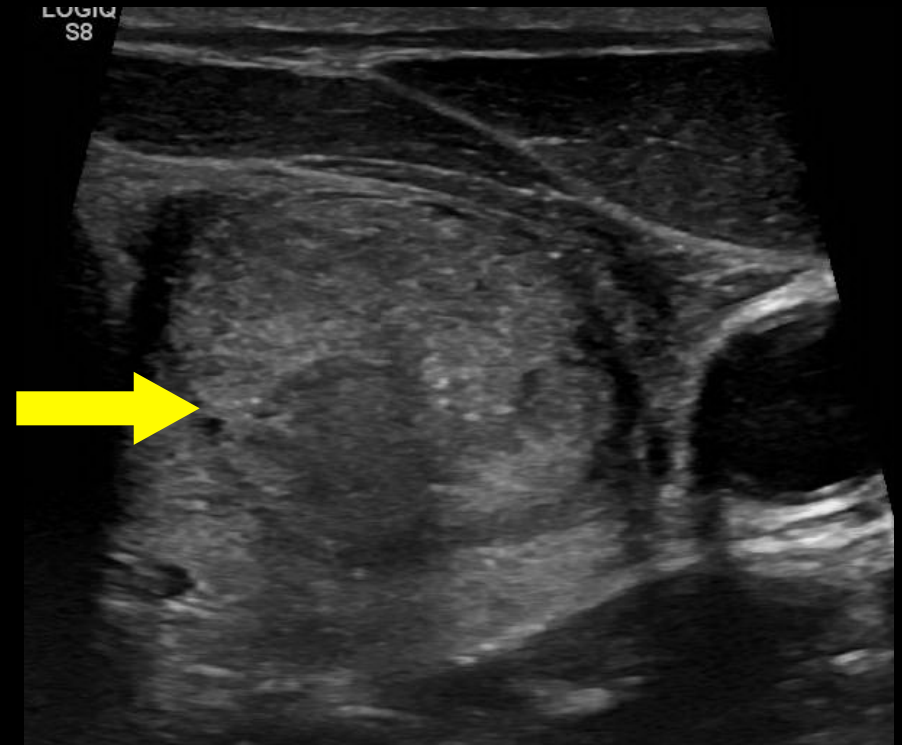
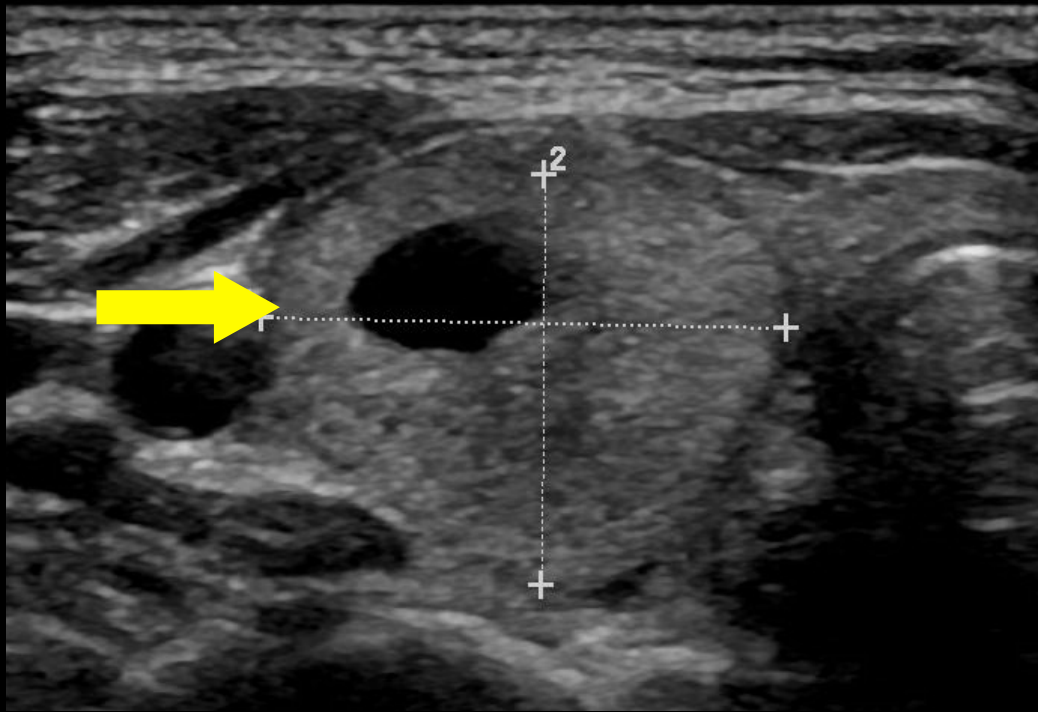
Without soft tissue component. Applies to cystic or almost completely cystic nodules.

Echogenicity: Hyperechoic



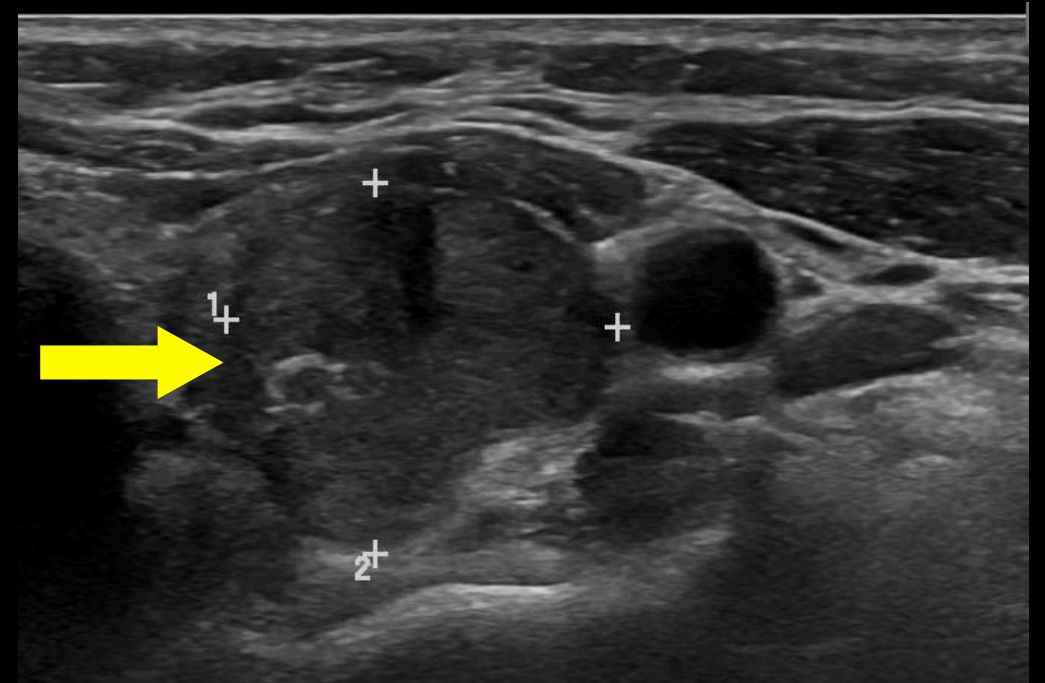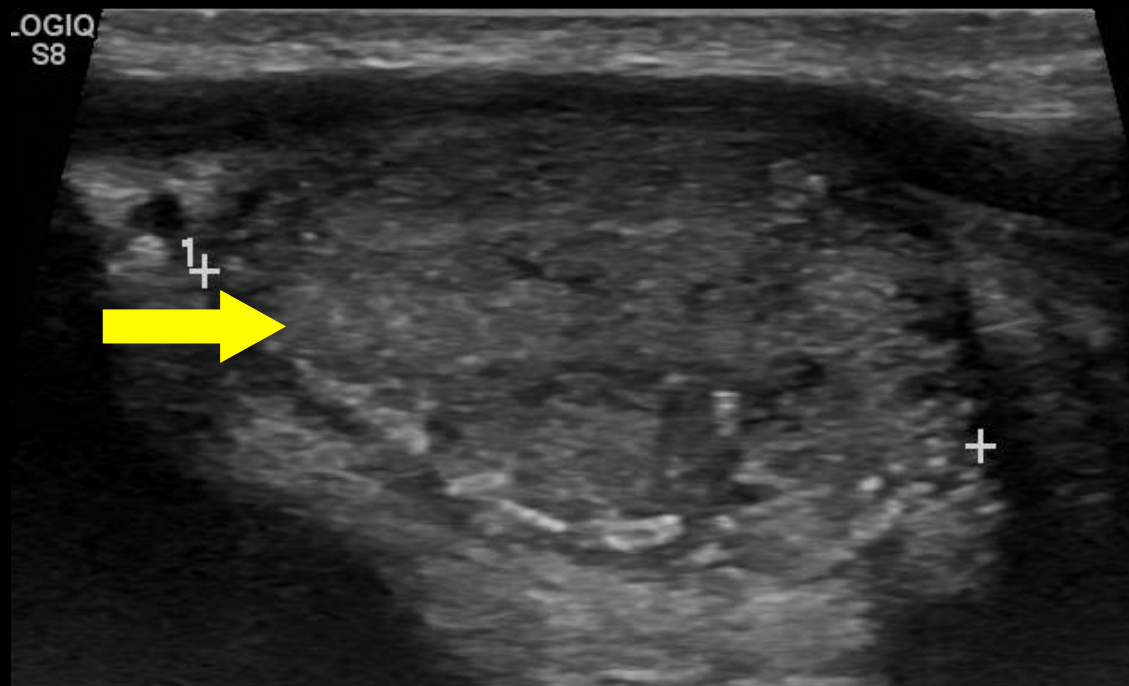
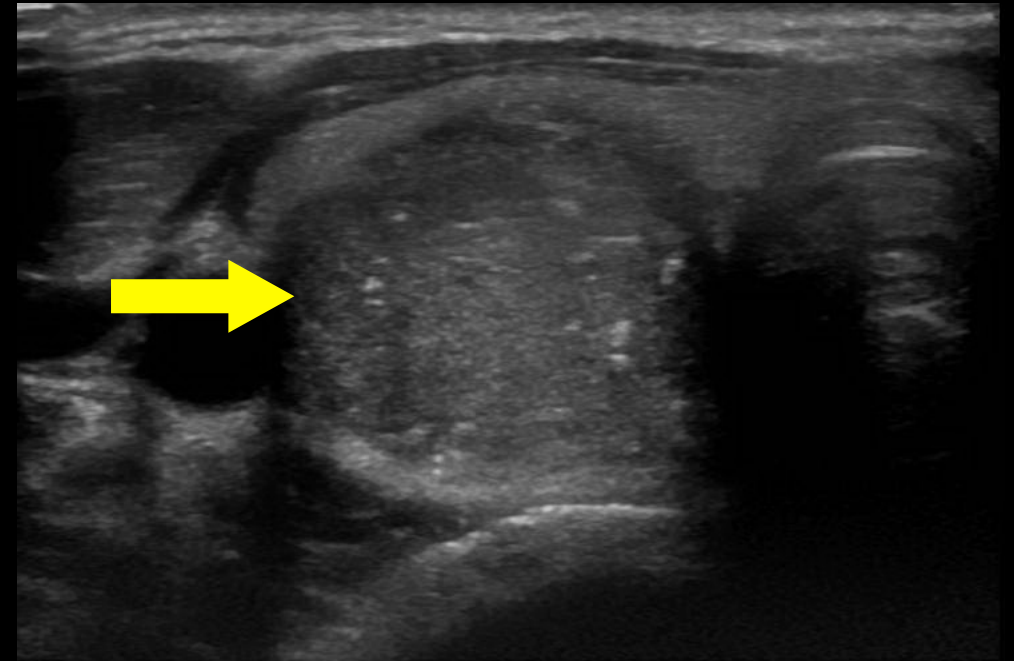
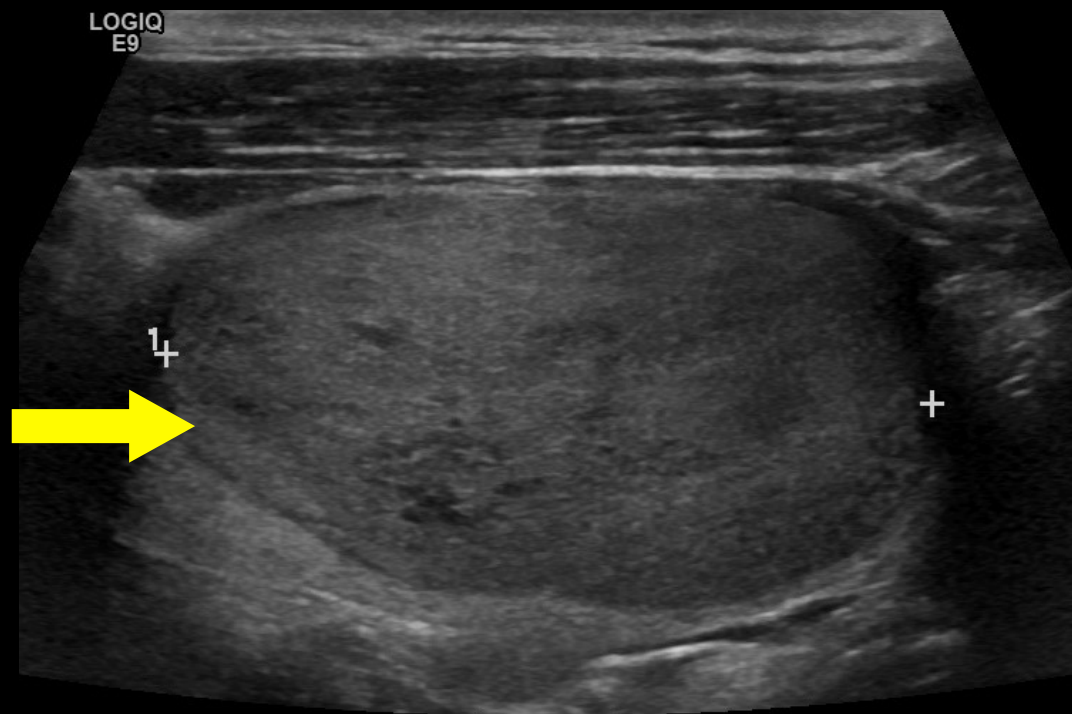
Increased echogenicity relative to thyroid tissue

Echogenicity: Isoechoic



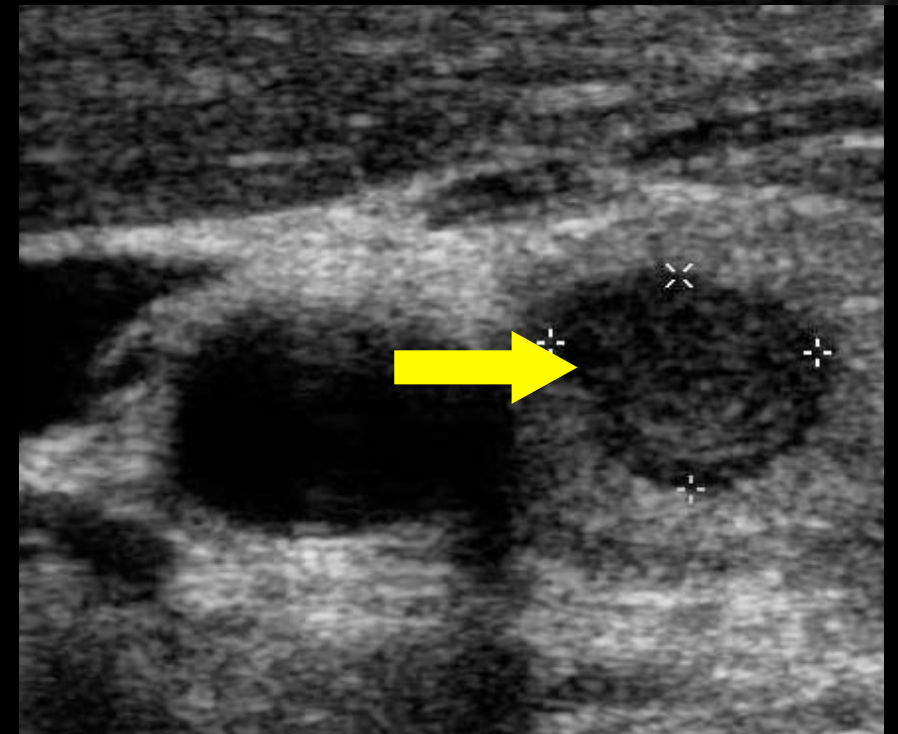
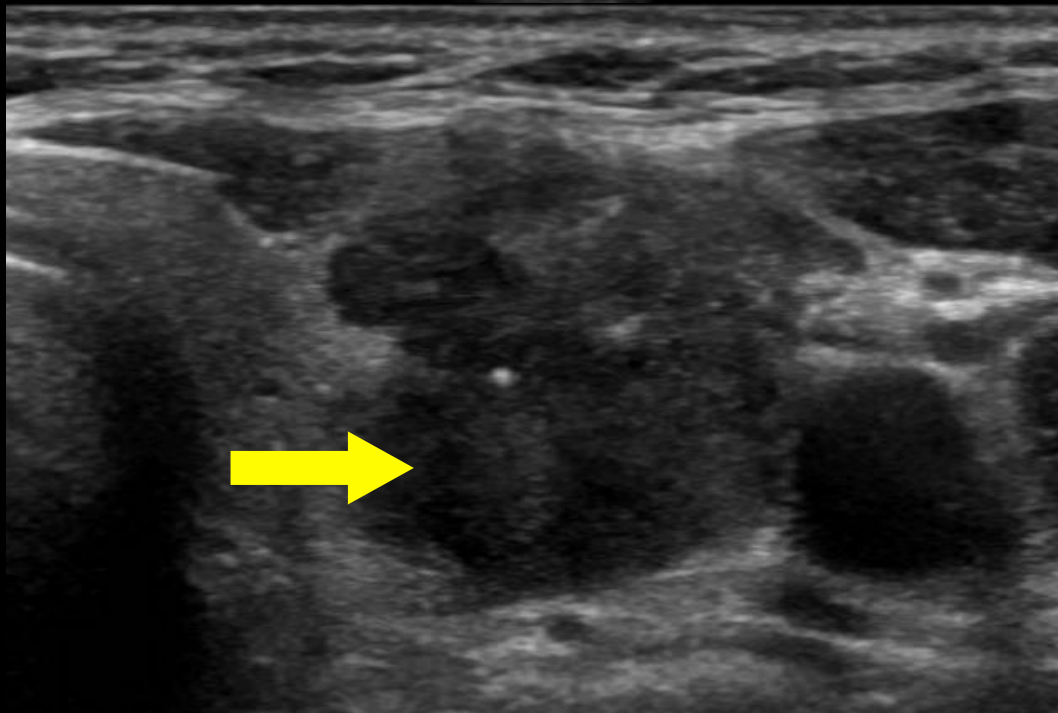
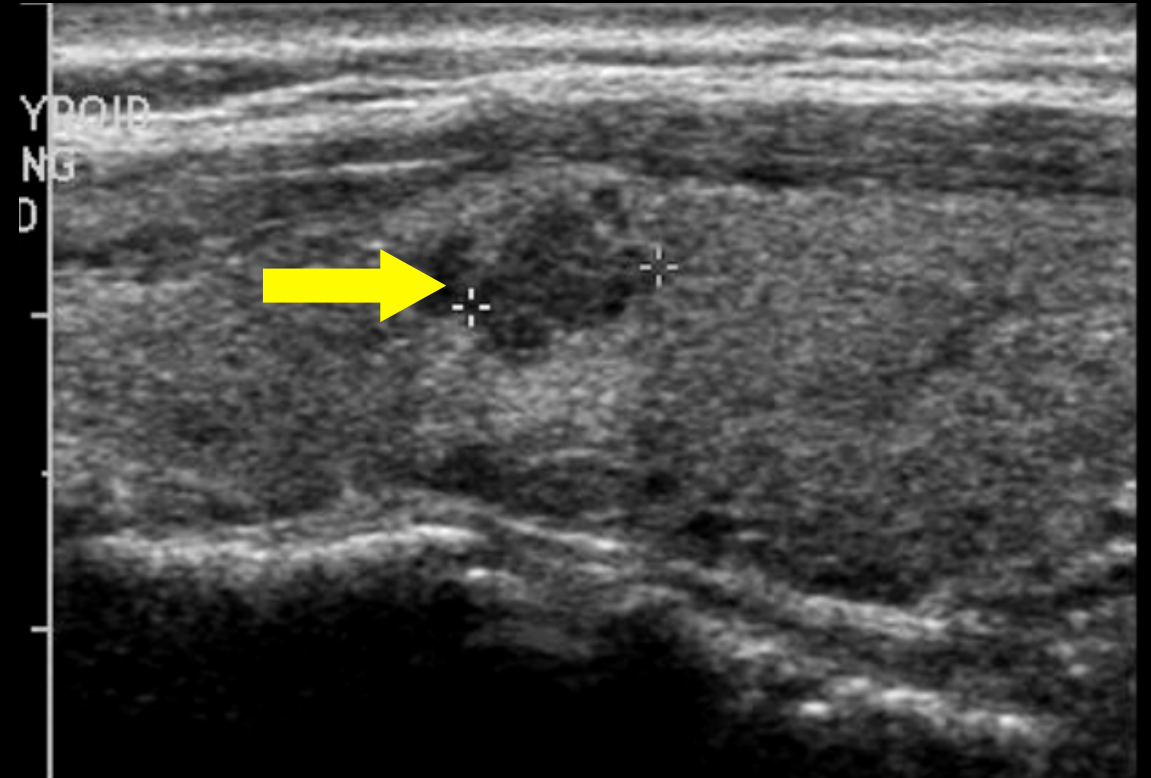
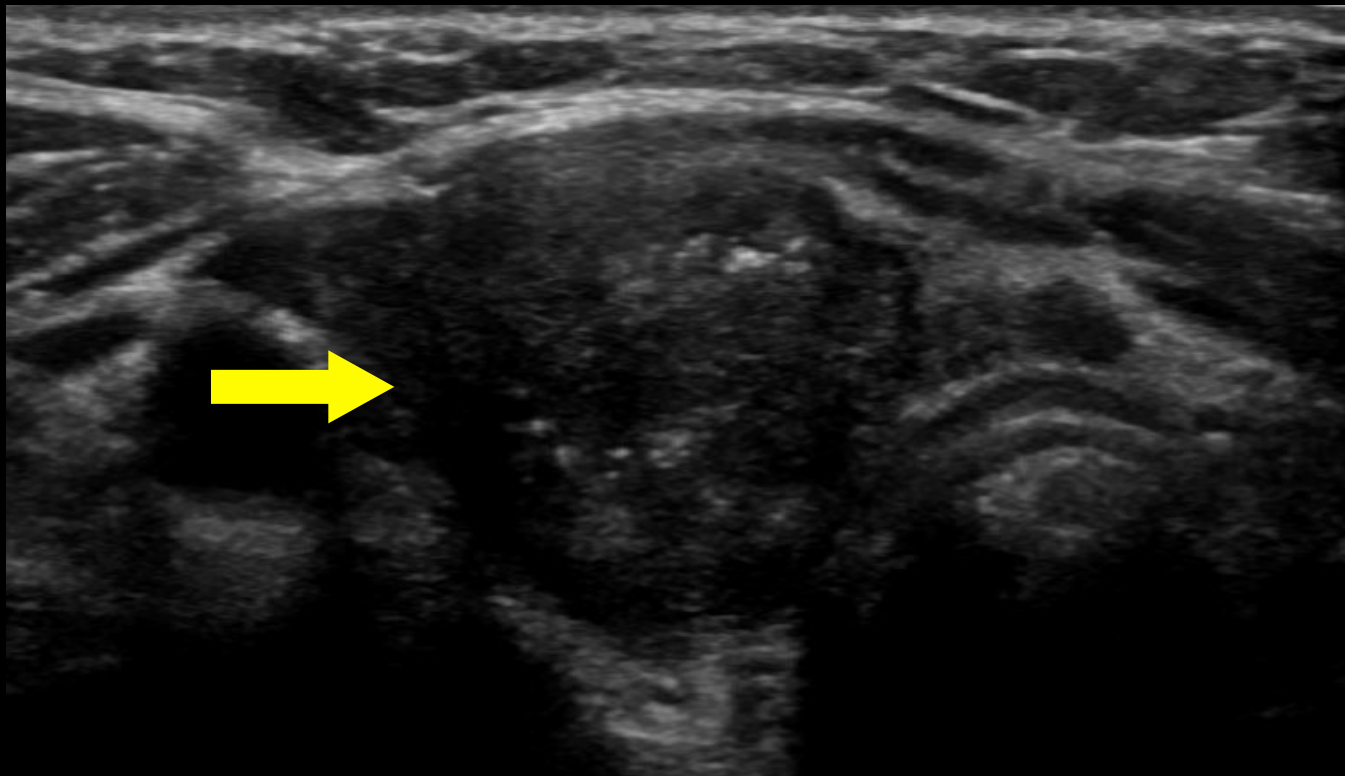
Similar echogenicity relative to thyroid tissue

Echogenicity: Hypoechoic



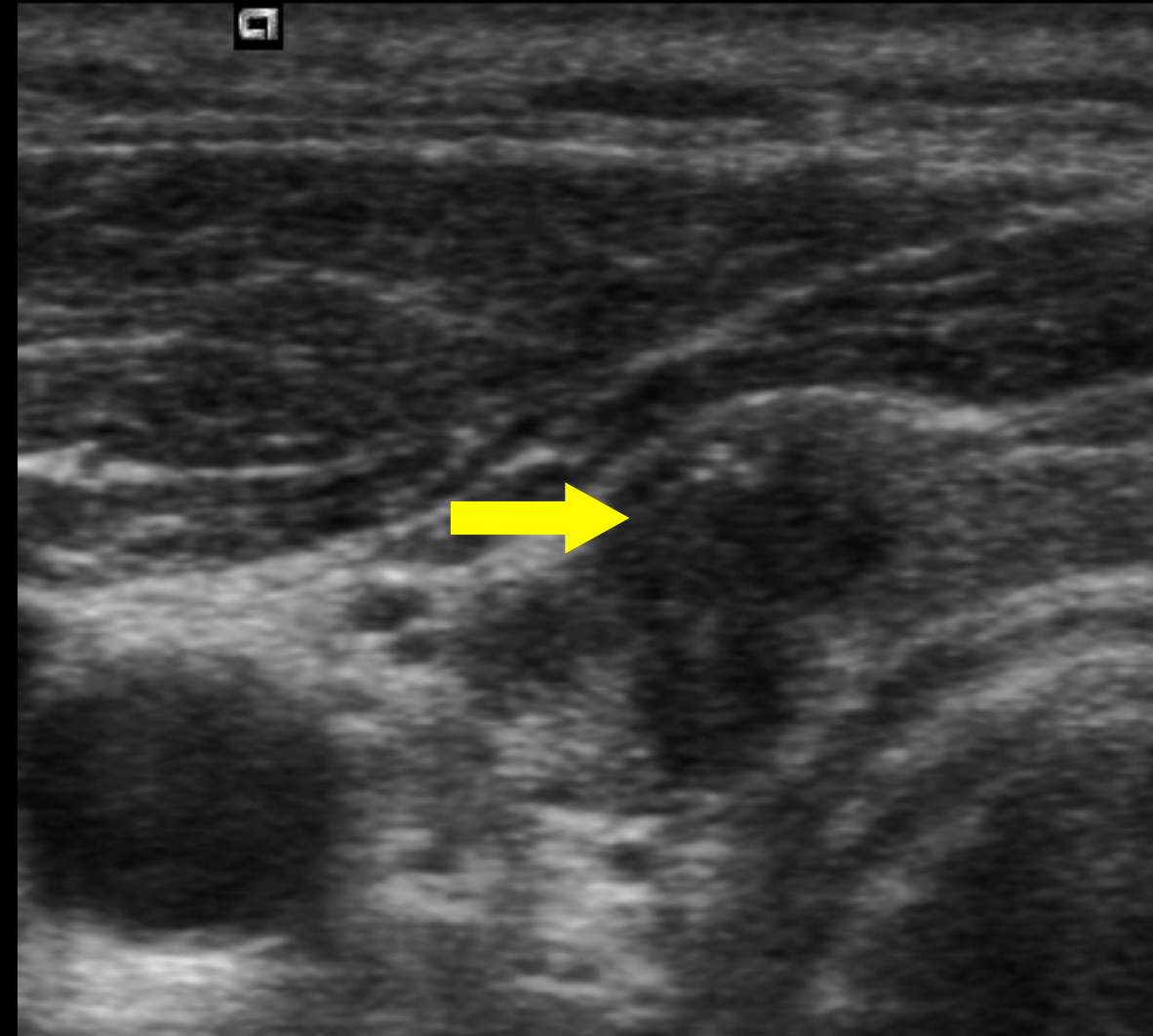
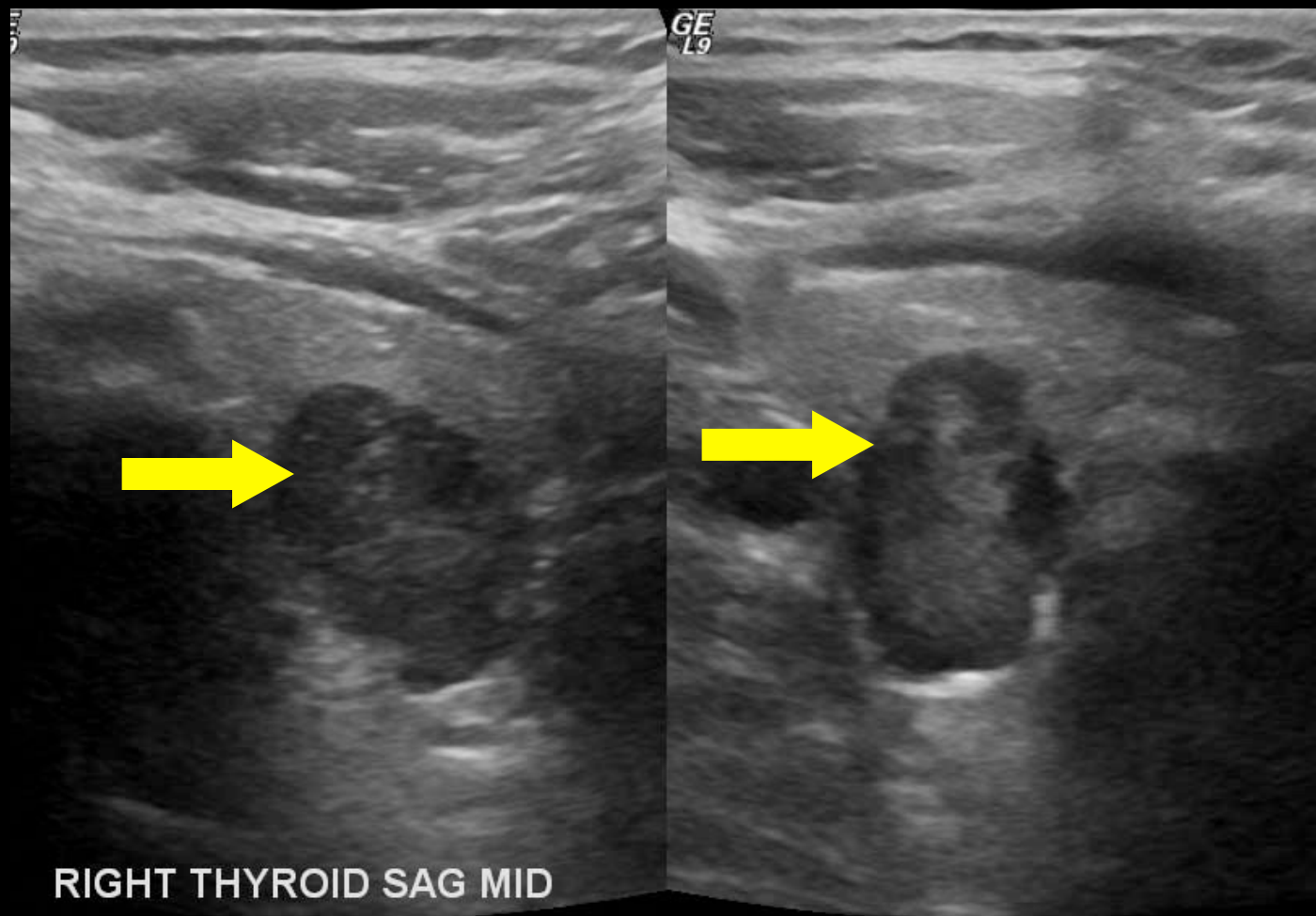
Decreased echogenicity relative to thyroid tissue

Echogenicity: Very Hypoechoic



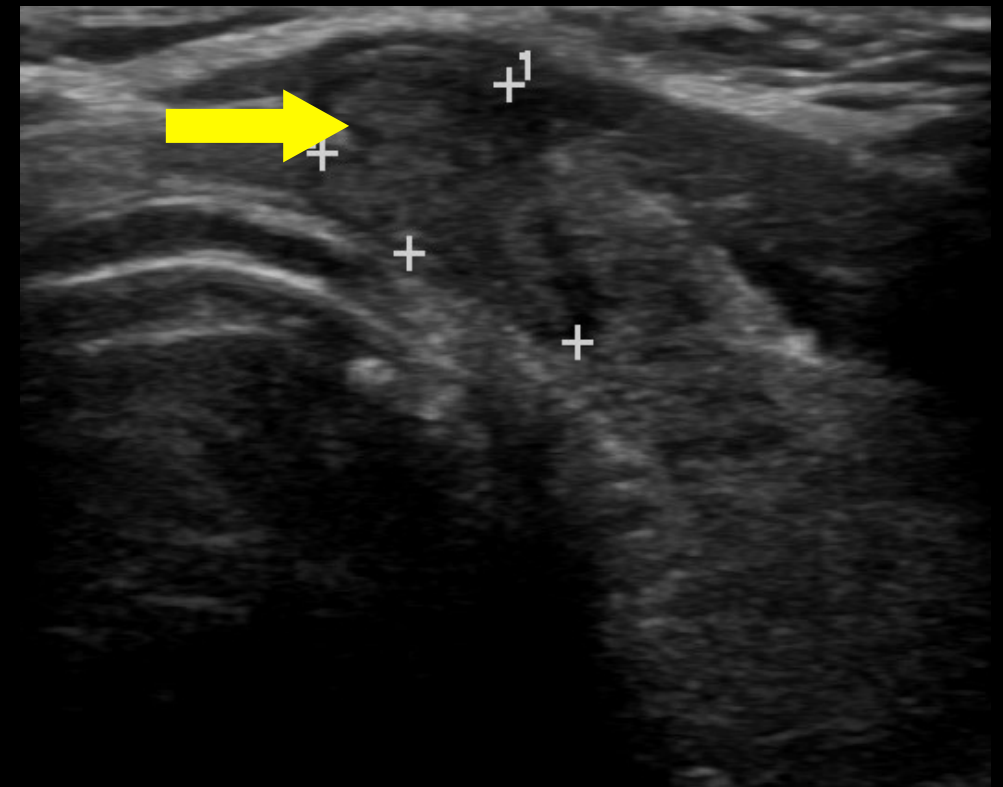
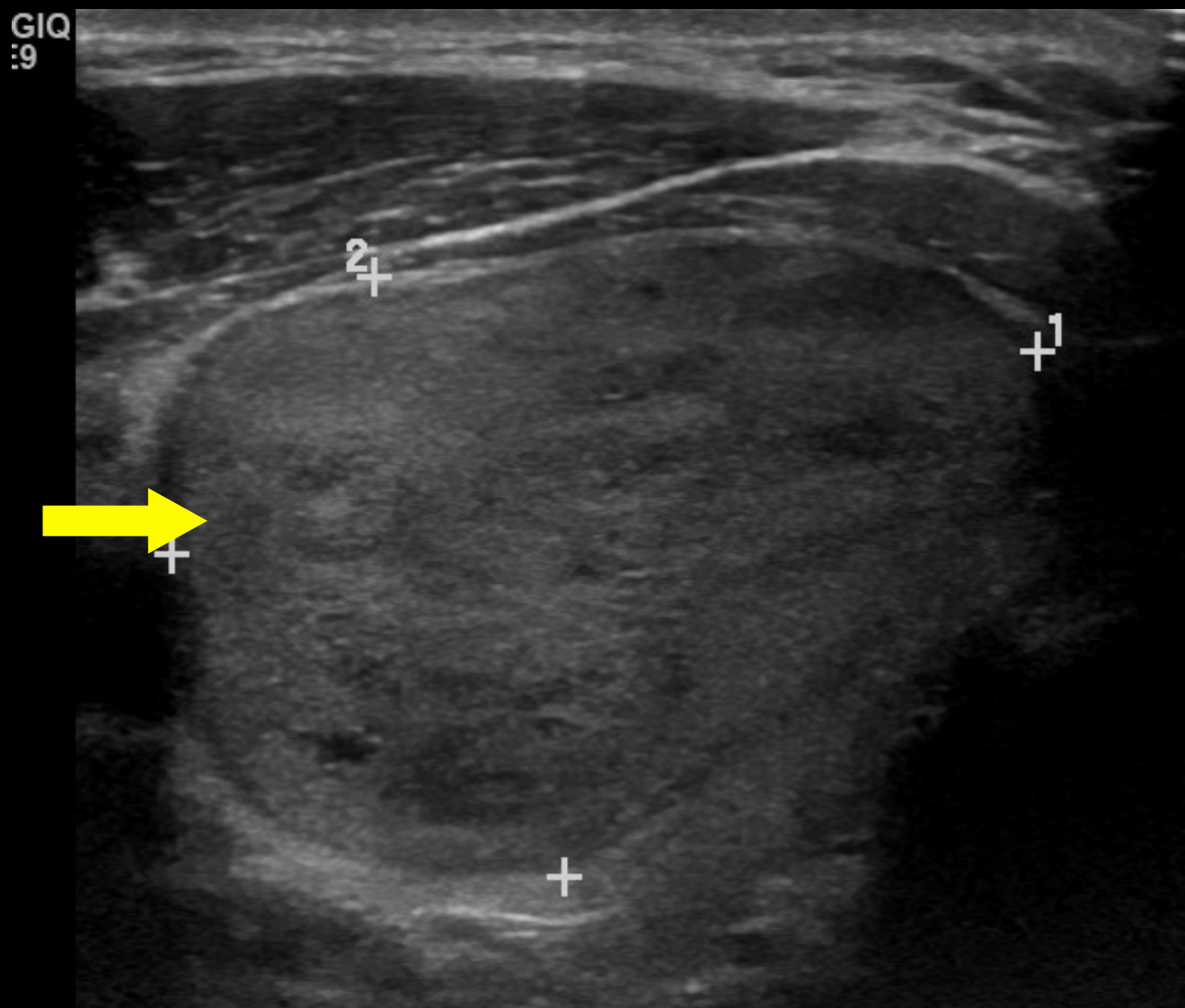
Decreased echogenicity relative to adjacent neck musculature

Shape: Taller-than-wide



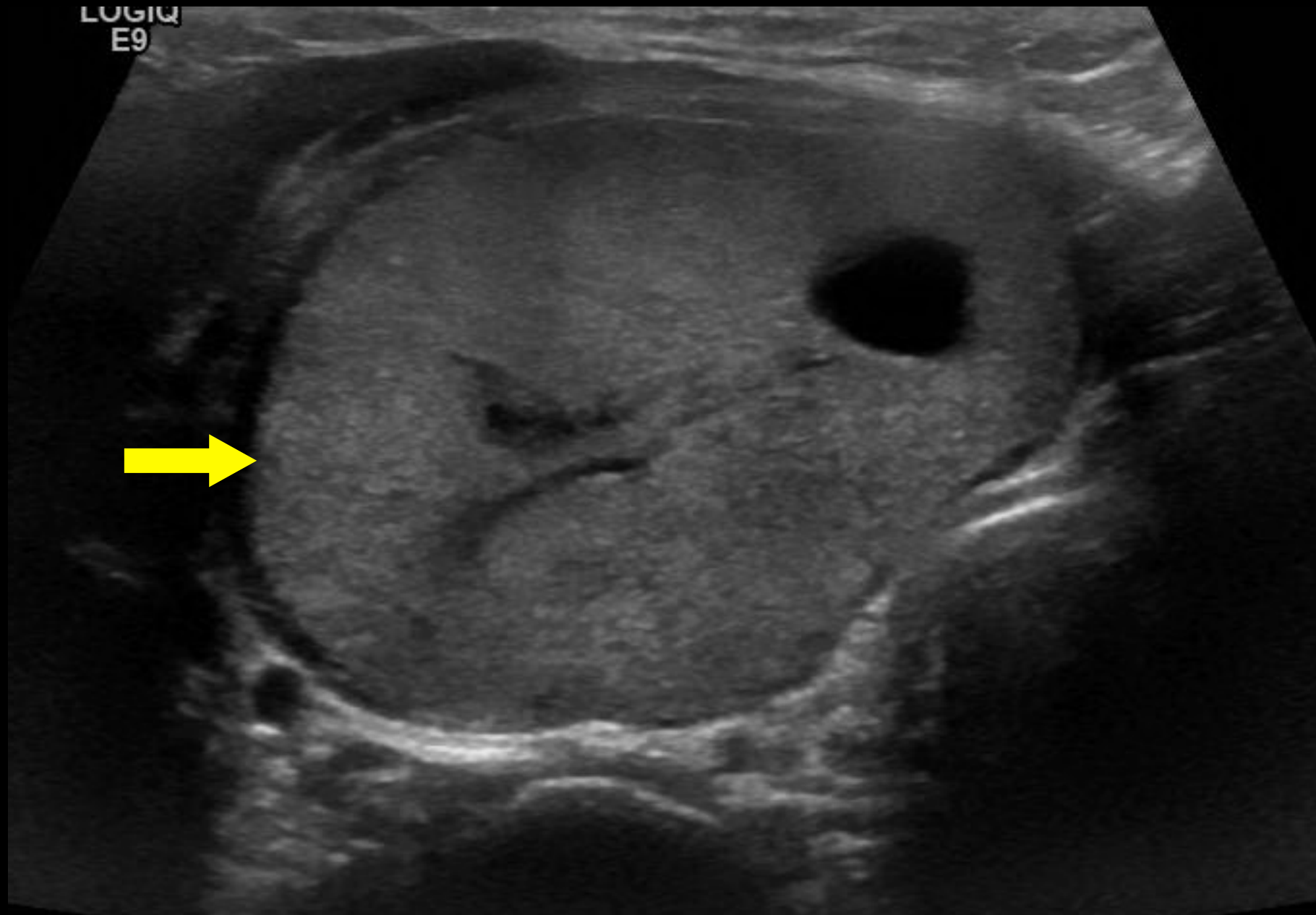
A taller-than-wide shape is defined as a ratio of >1 in the anteroposterior diameter to the horizontal diameter when measured in the **transverse** plane

Shape: Wider-than-tall



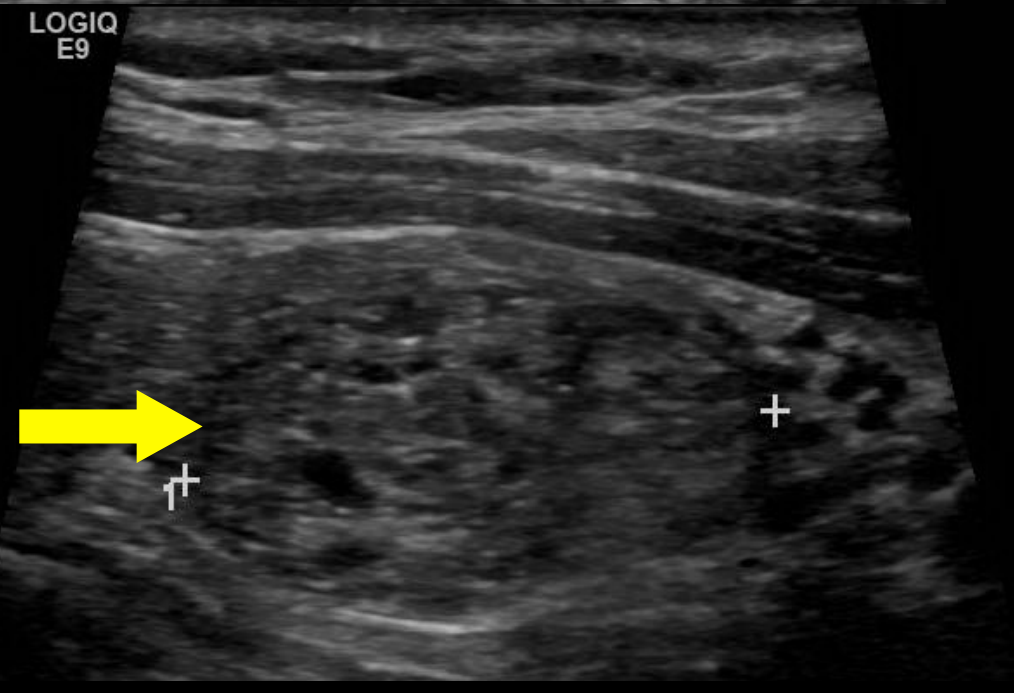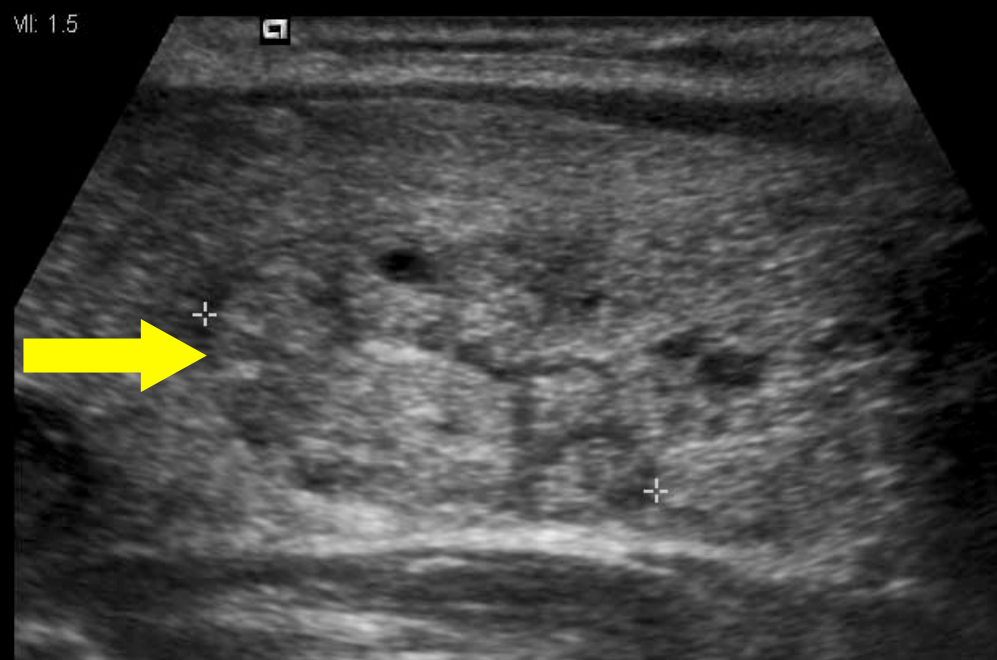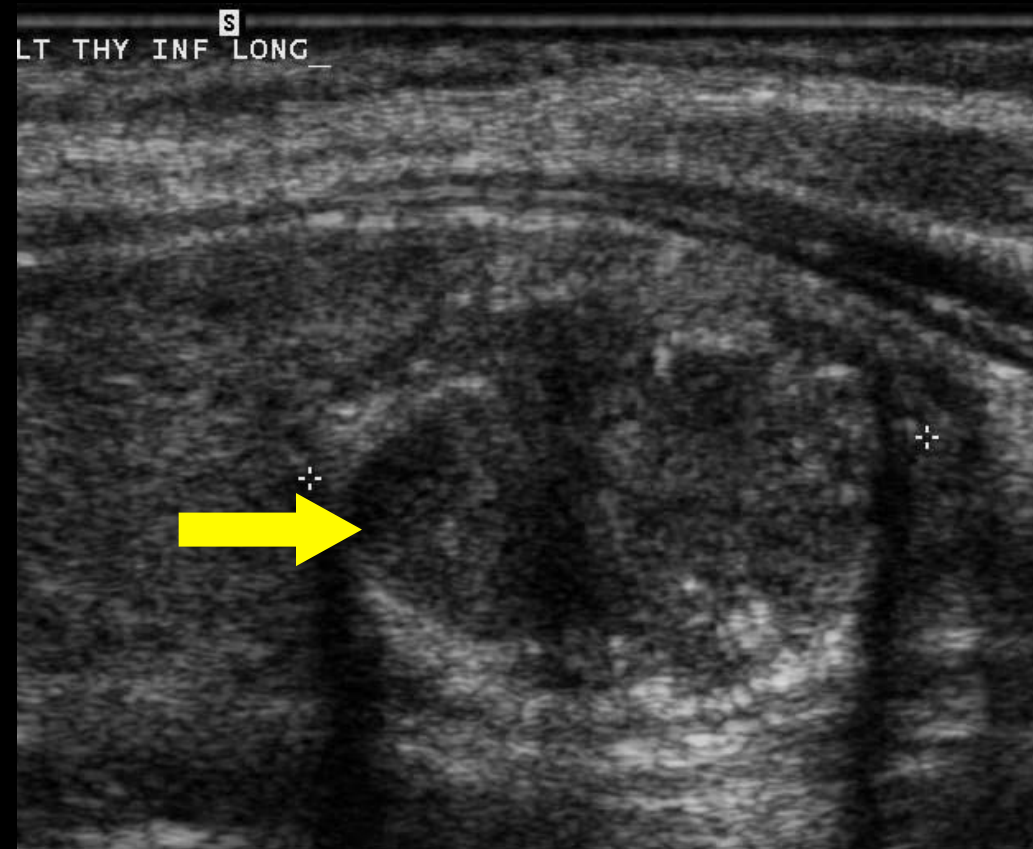
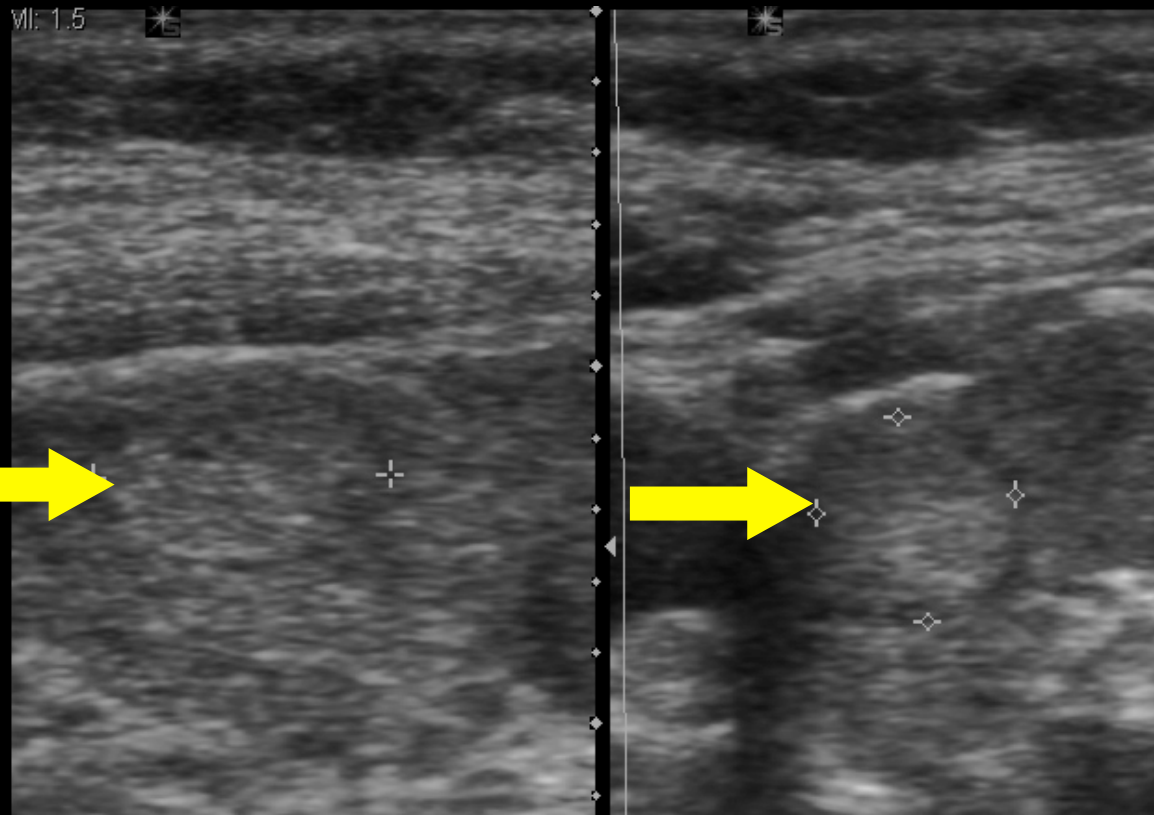
A wider-than-tall shape (not taller-than-wide) is defined as a ratio of ≤ 1 in the anteroposterior diameter to the horizontal diameter when measured in the **transverse** plane.

Margin: Smooth



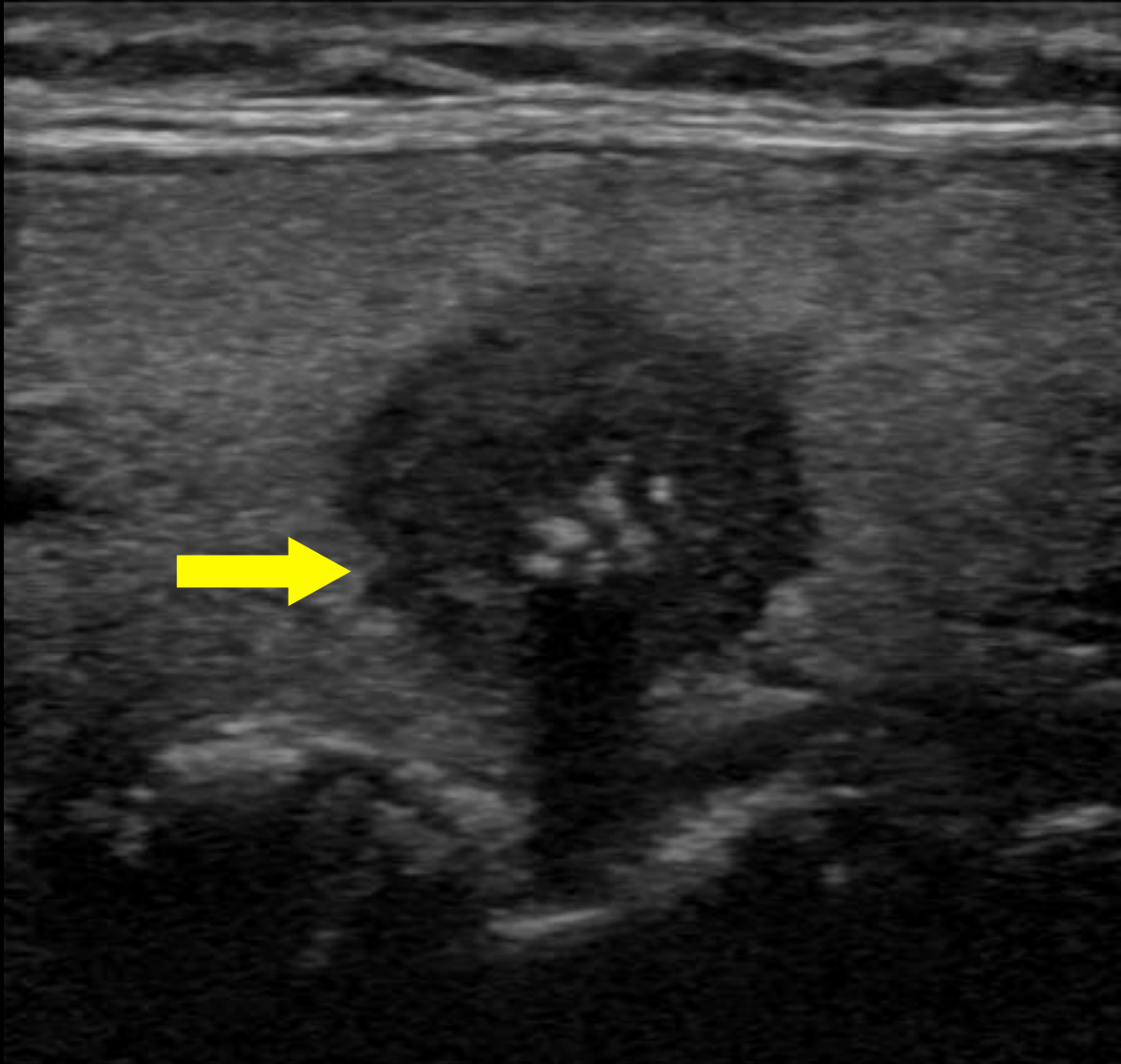
Uninterrupted, well-defined, curvilinear edge typically forming a spherical or elliptical shape

Margin: Ill-defined



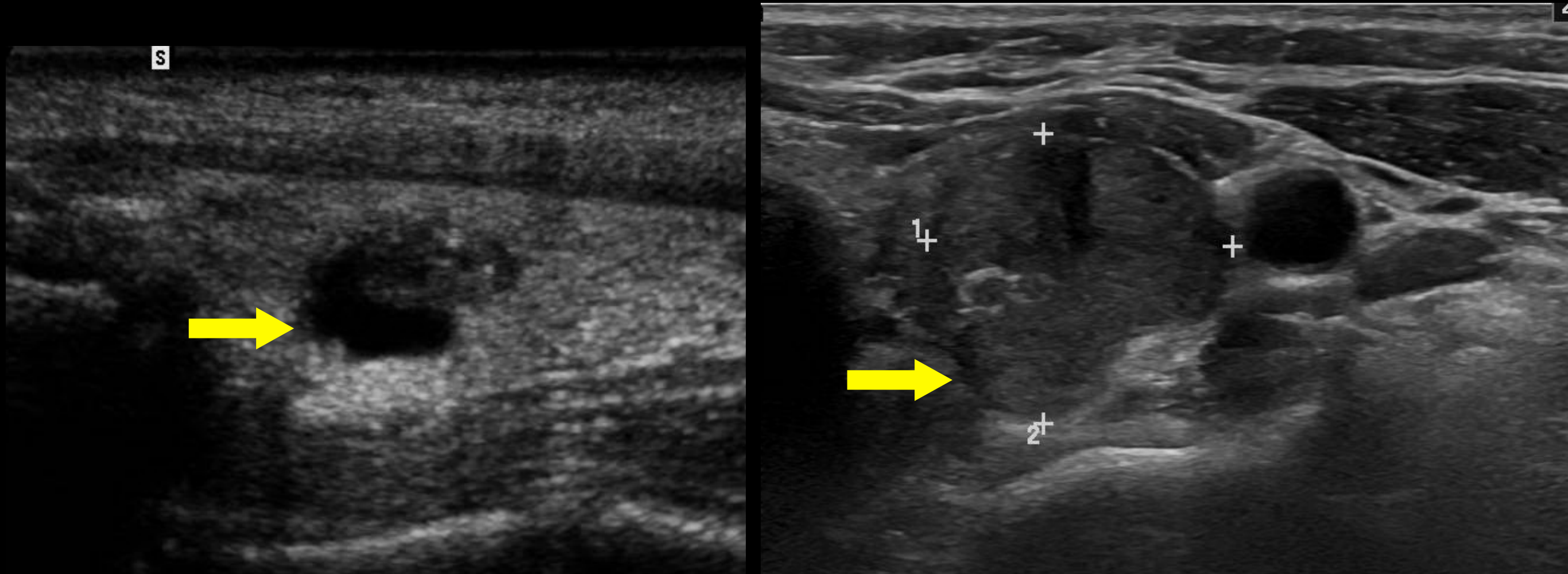
Border of the nodule is difficult to distinguish from thyroid parenchyma

Margin: Irregular



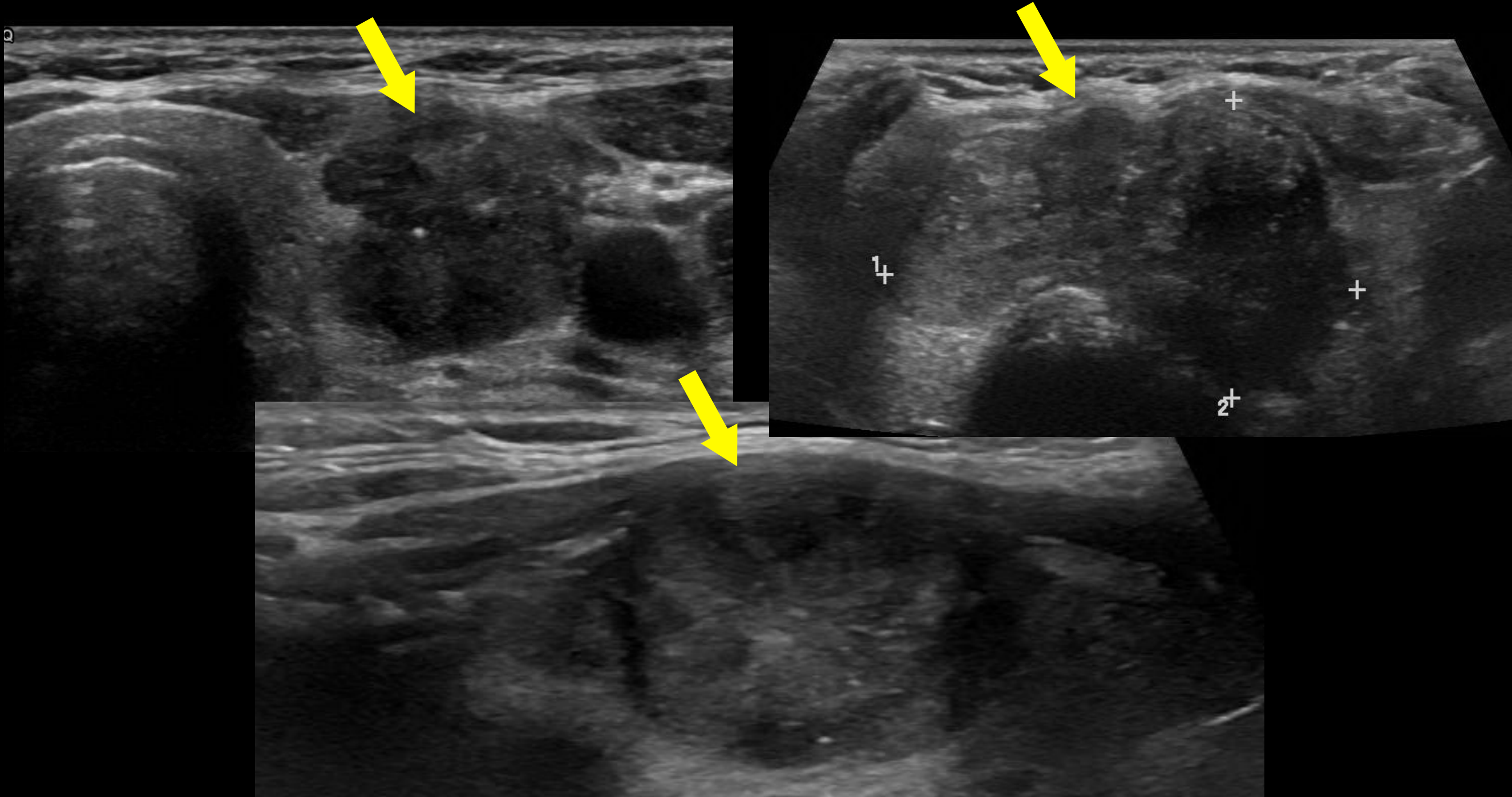
The outer border of the nodule is spiculated, jagged, or with sharp angles with or without clear soft tissue protrusions into the parenchyma. The protrusions may vary in size and conspicuity and may be present in only one portion of the nodule

Margin: Lobulated



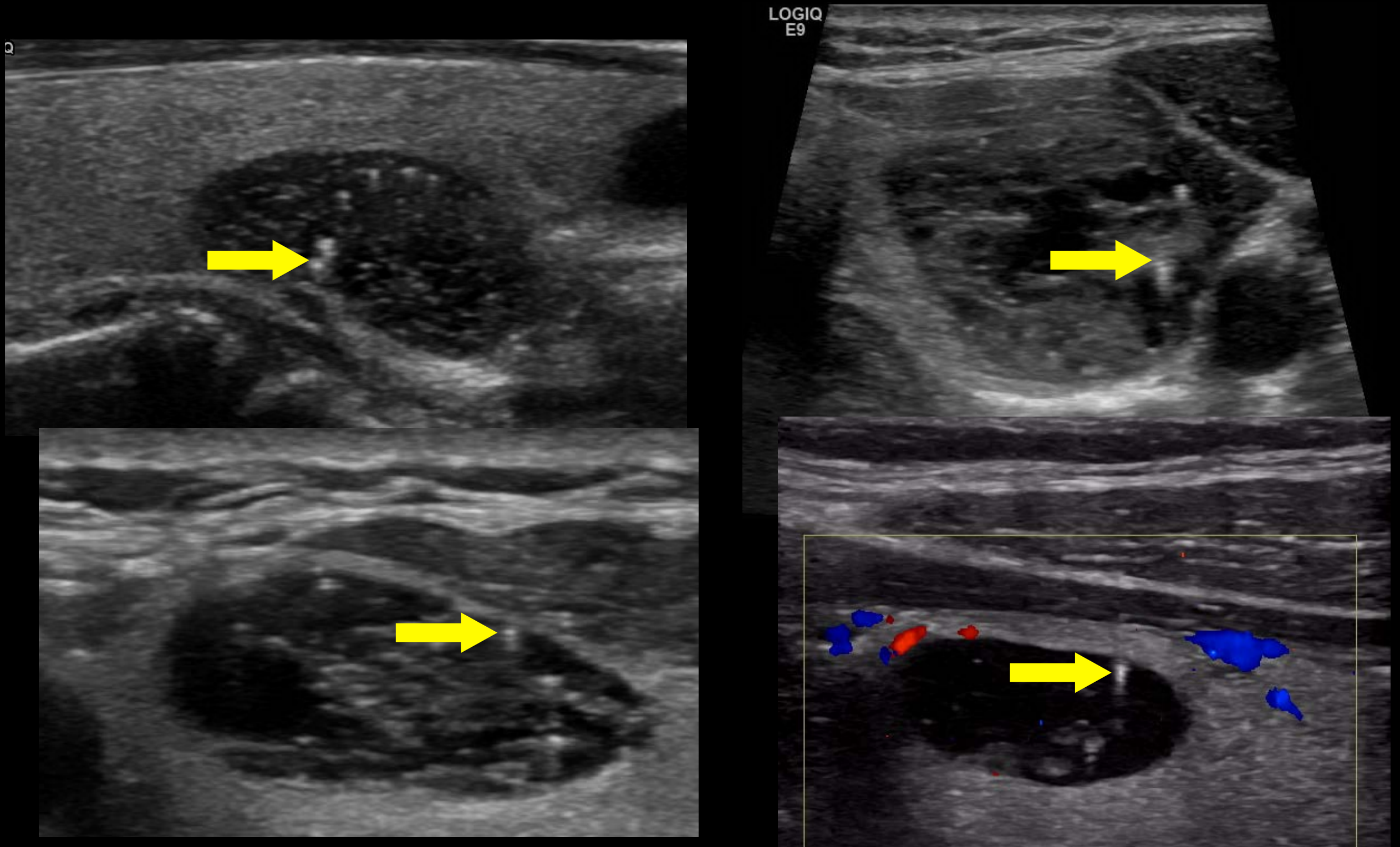
Border has focal rounded soft tissue protrusions that extend into the adjacent parenchyma. The lobulations may be single or multiple and may vary in conspicuity and size (small lobulations are referred to as microlobulated)

Margin: Extrathyroidal Extension



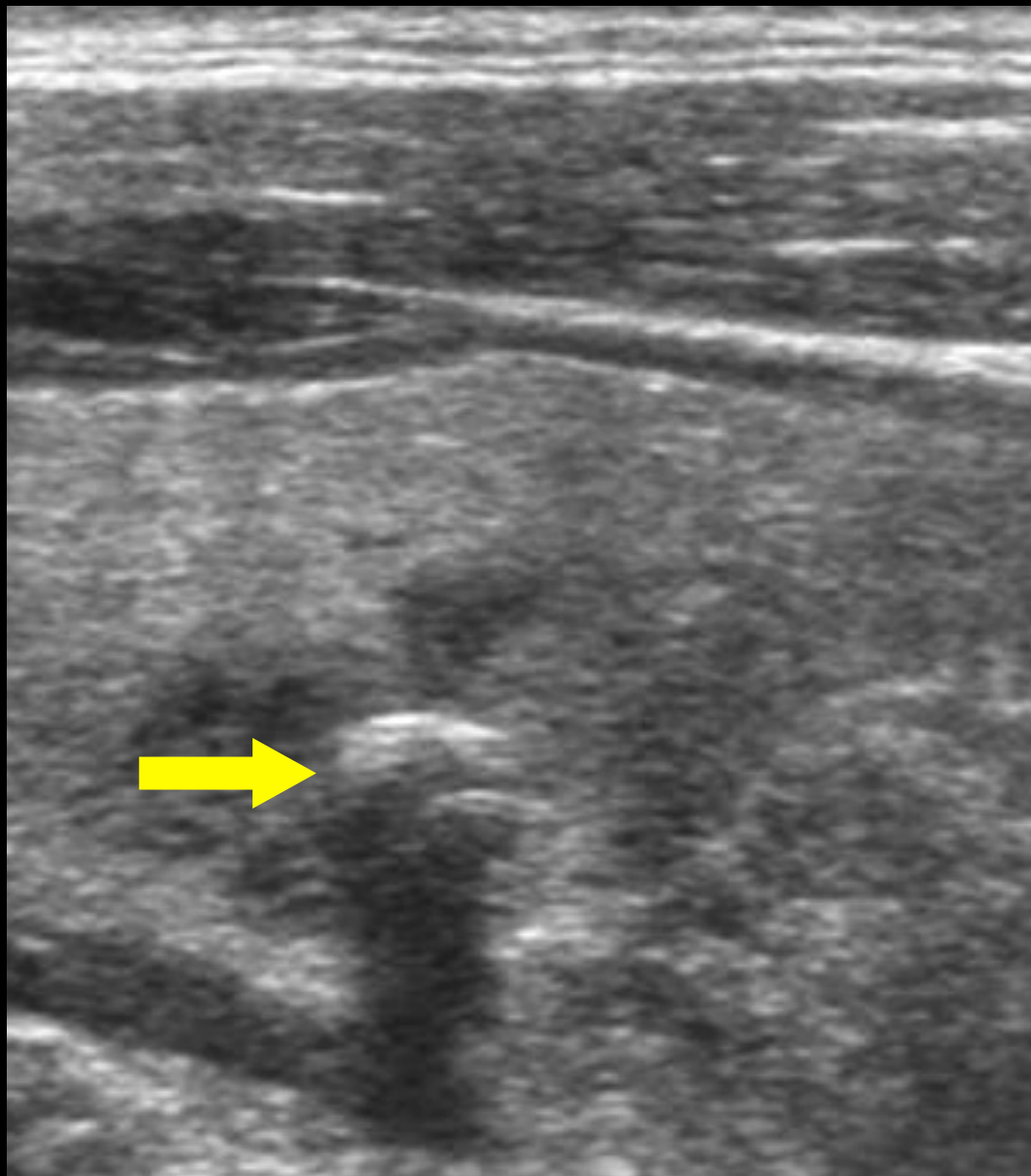
Nodule extends through the thyroid margin

Echogenic Foci: Large Comet Tail

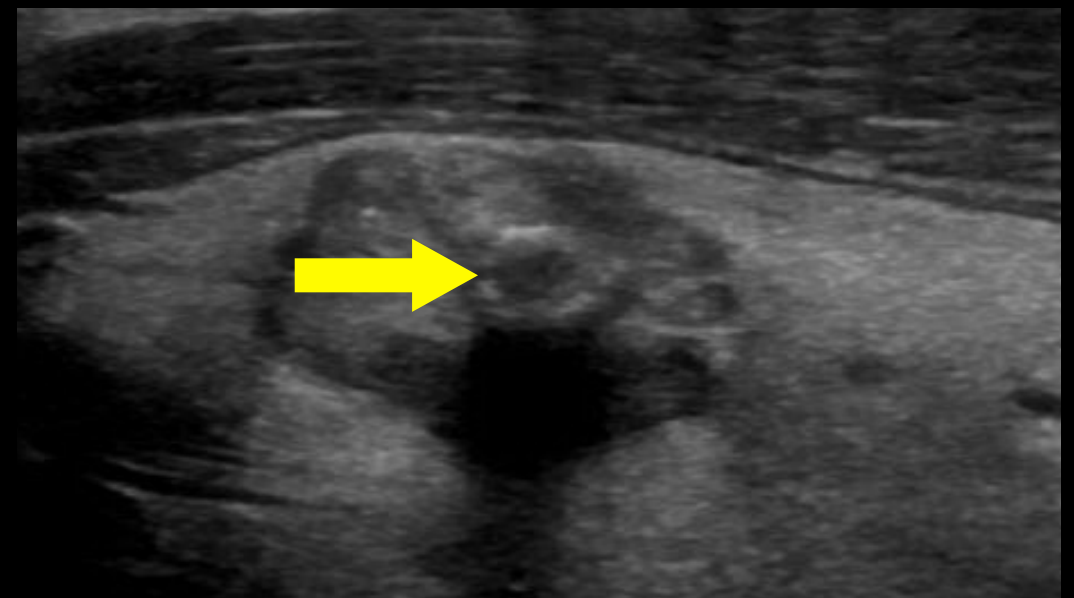
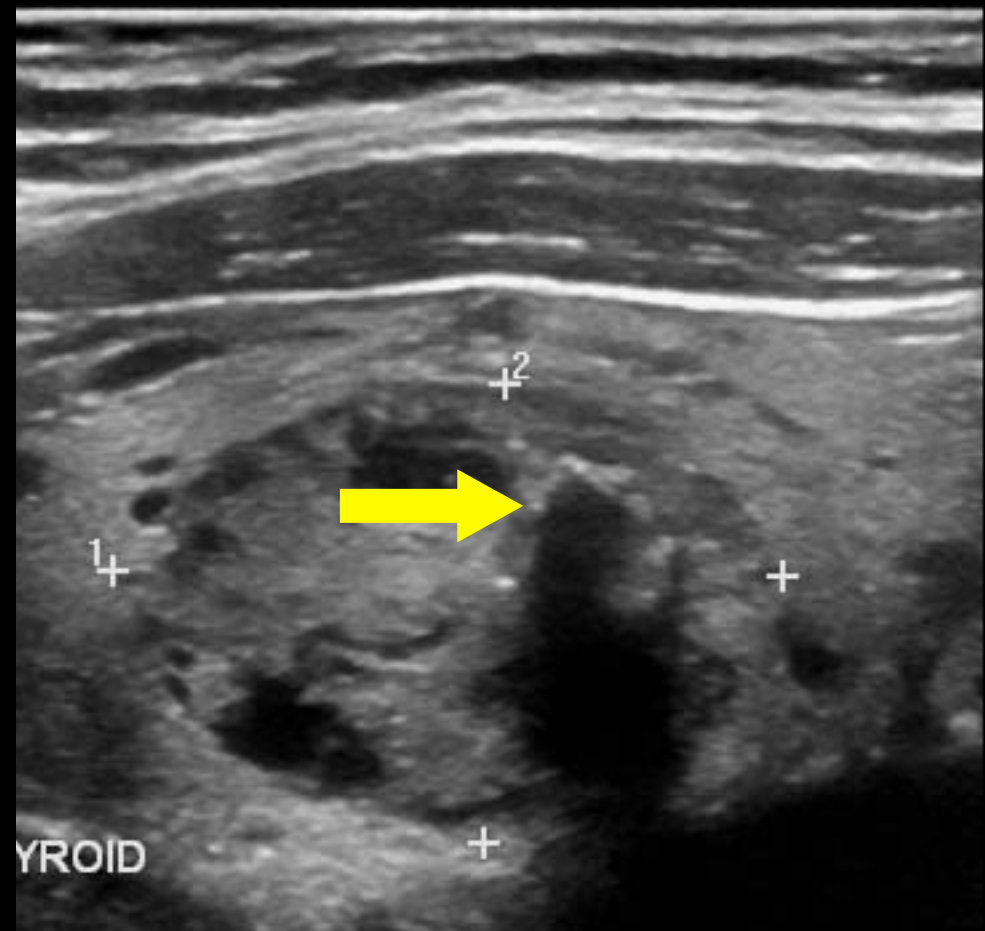


A comet-tail artifact is a type of reverberation artifact. The deeper echoes become attenuated and are displayed as decreased width, resulting in a triangular shape.

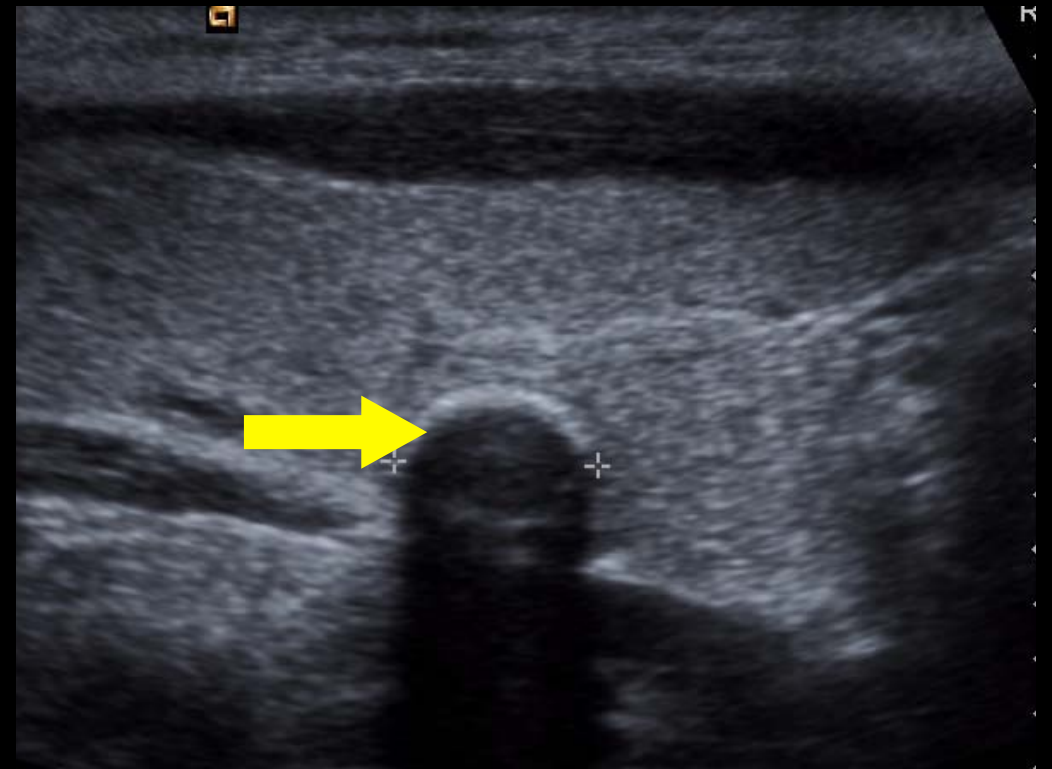
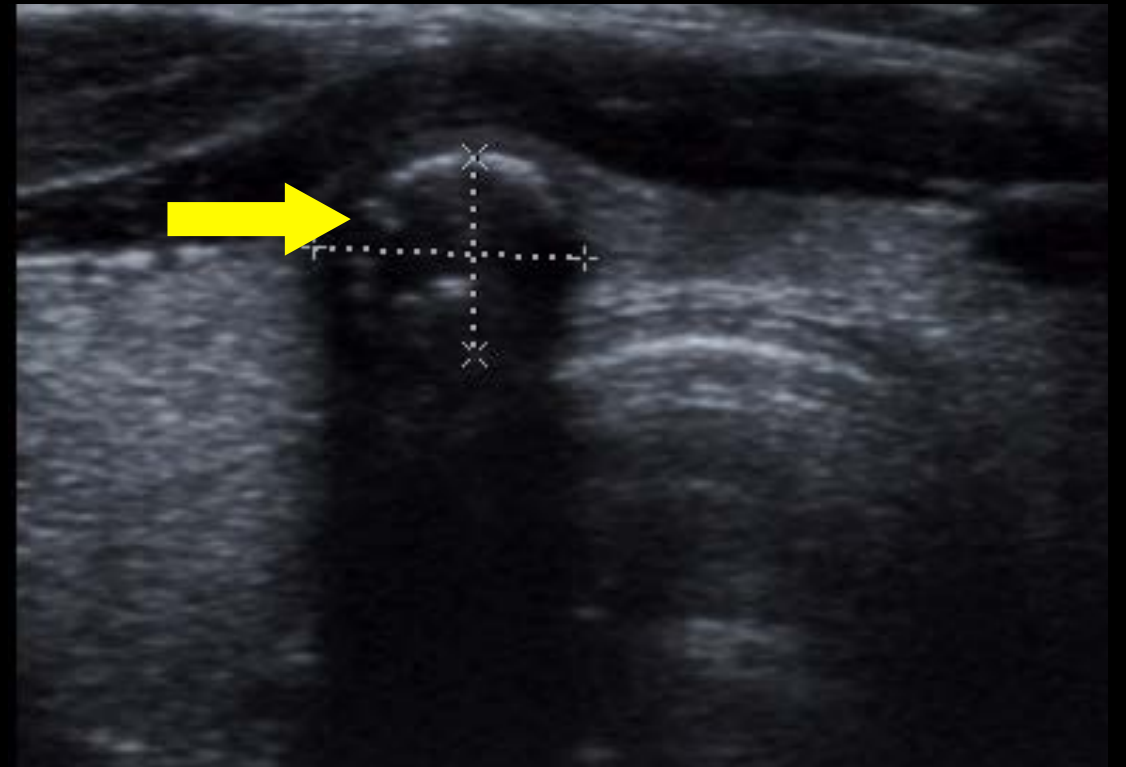
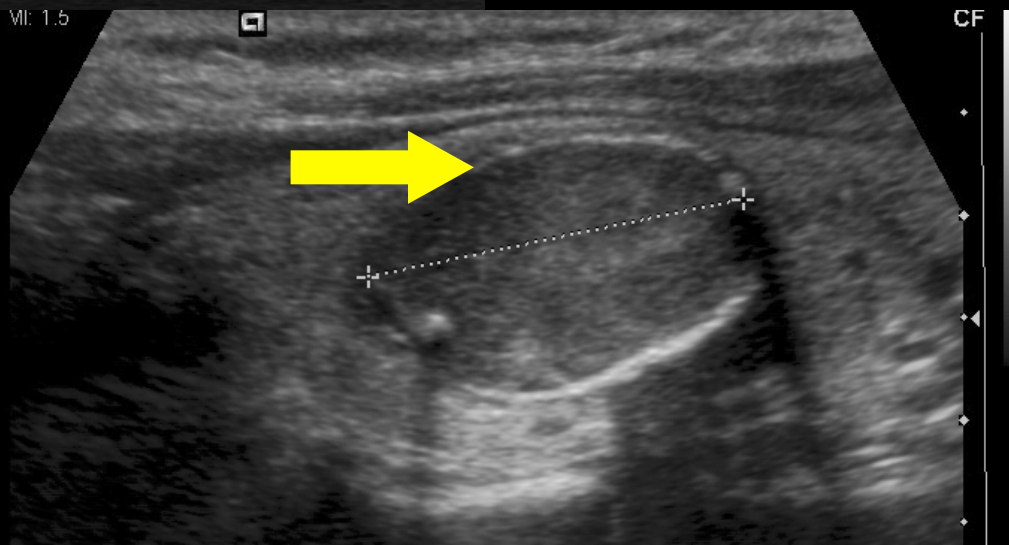
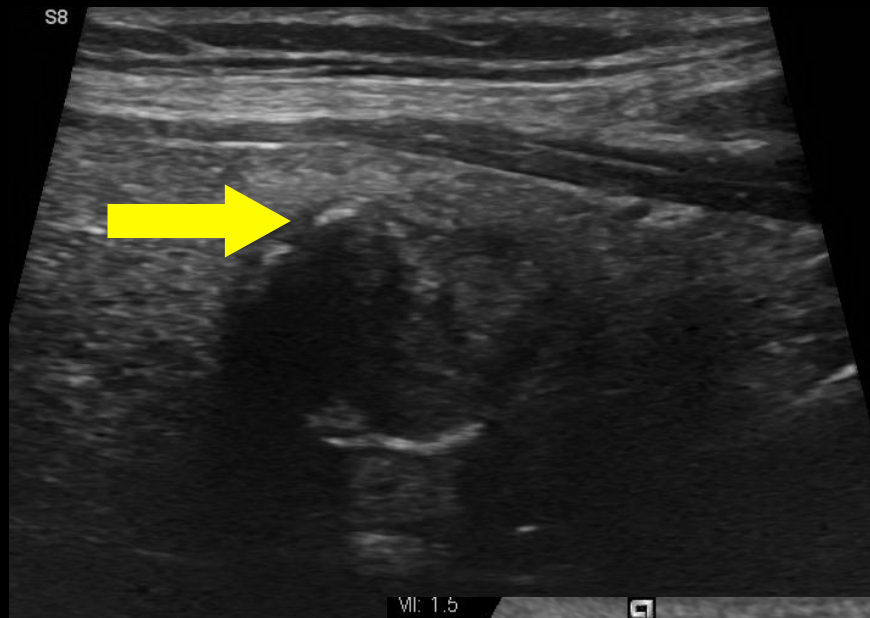Echogenic Foci: Macrocalcifications



Calcifications that are large enough to result in posterior acoustic shadowing

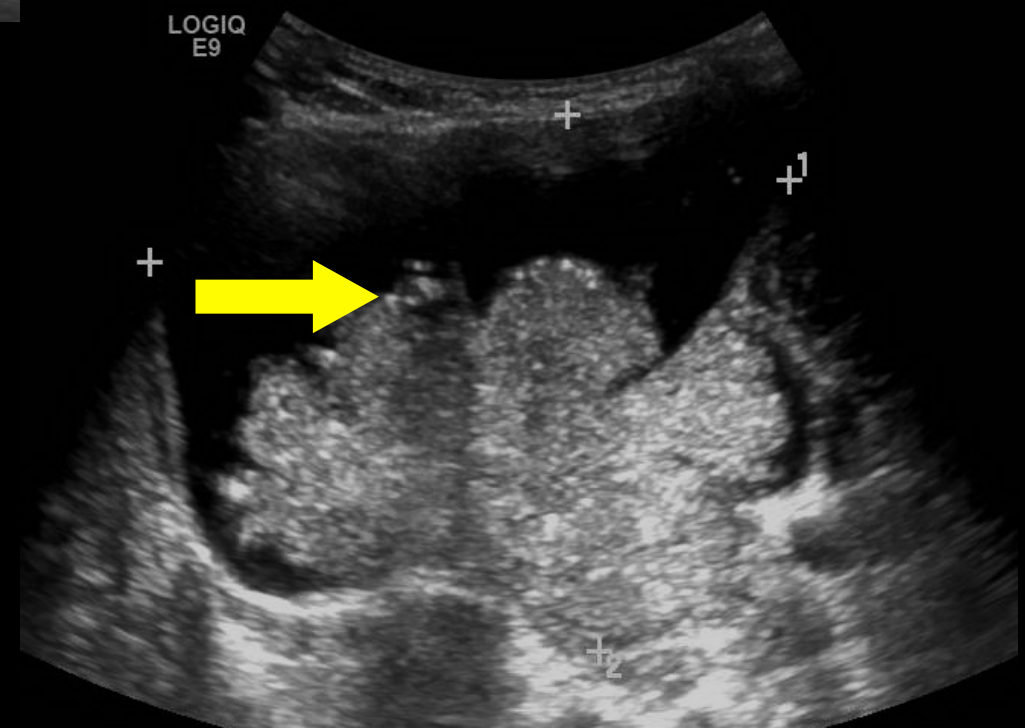
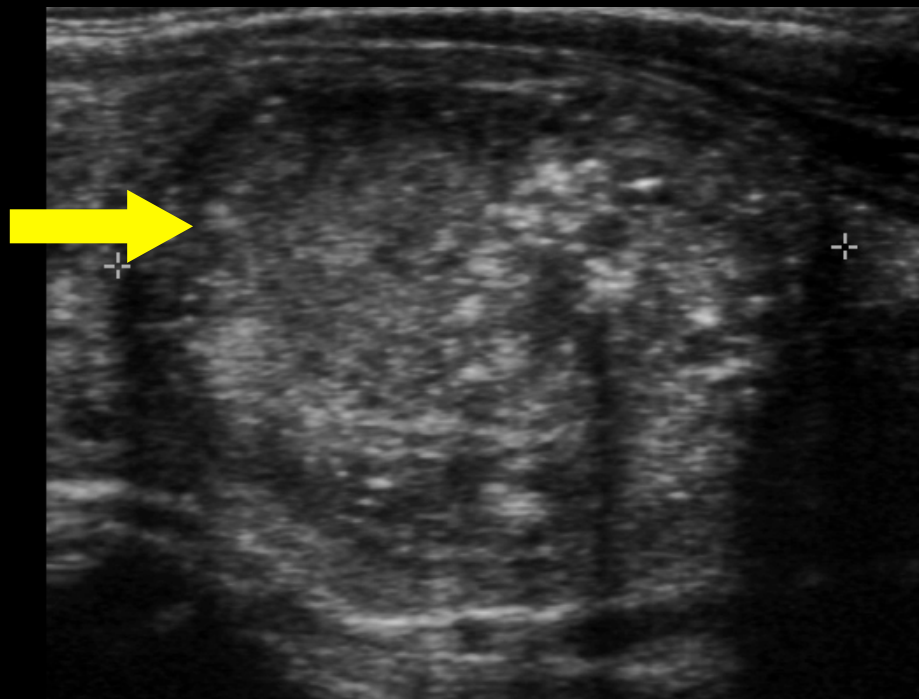
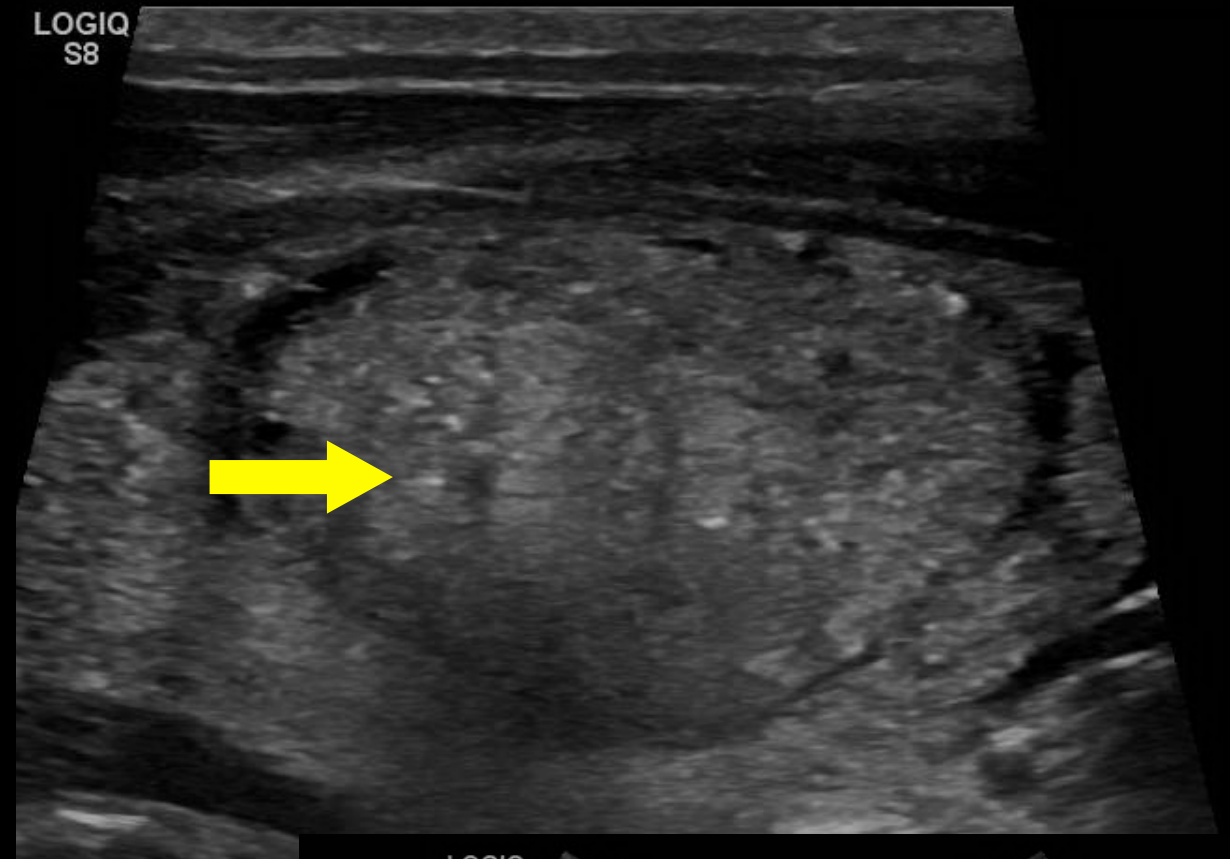
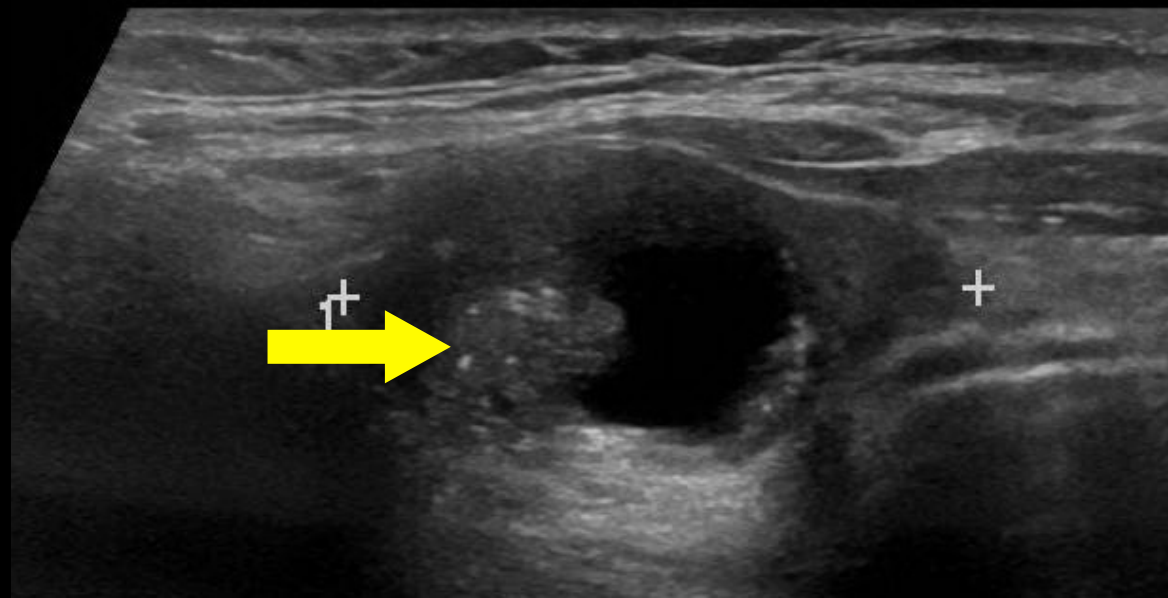


Echogenic Foci: Peripheral Calcifications



Calcifications occupy the periphery of the nodule. May not be continuous but generally involves the majority of the margin. Often dense enough to obscure the central components of the nodule (see Assumptions).

Echogenic Foci: Punctate Echogenic Foci



“Dot-like” foci less than 1 mm in diameter.
Occasionally can have small comet tail artifacts.

REFERENCE

[http://www.jacr.org/article/S1546-1440\(15\)00684-5/abstract](http://www.jacr.org/article/S1546-1440(15)00684-5/abstract)

Grant EG, Tessler FN, Hoang JK, Langer JE, Beland MD, Berland LL, Cronan JJ, Desser TS, Frates MC, Hamper UM, Middleton WD, Reading CC, Scoutt LM, Stavros AT, Teefey SA. Thyroid Ultrasound Reporting Lexicon: White Paper of the ACR Thyroid Imaging, Reporting and Data System (TIRADS) Committee. J Am Coll Radiol. 2015 Dec;12(12 Pt A):1272-9. Review. PubMed PMID: 26419308.

ORIGINAL ARTICLE

CLINICAL PRACTICE MANAGEMENT



Thyroid Ultrasound Reporting Lexicon: White Paper of the ACR Thyroid Imaging, Reporting and Data System (TIRADS) Committee



Edward G. Grant, MD^a, Franklin N. Tessler, MD^b, Jenny K. Hoang, MBBS^c, Jill E. Langer, MD^d, Michael D. Beland, MD^e, Lincoln L. Berland, MD^b, John J. Cronan, MD^e, Terry S. Desser, MD^f, Mary C. Frates, MD^g, Ulrike M. Hamper, MD^h, William D. Middleton, MDⁱ, Carl C. Reading, MD^j, Leslie M. Scoutt, MD^k, A. Thomas Stavros, MD^l, Sharlene A. Teefey, MDⁱ

Images from Sharlene A. Teehey

Compiled by Jenny K. Hoang