Volume 3, No. 1

December/January 2011

JIACD

The Journal of Implant & Advanced Clinical Dentistry

Sinus Perforation Treatment & Classifications

by Dr. Leon Chen

Dr. Paul Fuggazzotto on the Role of Guided Tissue Regneration in Modern Practice

Sinus Perforation: Treatment and Classifications

Leon Chen, DMS, MS[1] • Jennifer Cha, DMS, MS[2]
Hsin-Chen Chen, MD[3]

Abstract

Background: Tooth loss in the posterior area of the maxilla will result in the atrophying of bone along the alveolar ridge over time. This can make implant placement in the sinus area impossible without first re-establishing sufficient bone height. The traditional answer to this problem is the lateral window sinus lift.

Methods: In this article, we present a system of classifications and reparations of the sinus membrane perforations while performing sinus augmentation from the crestal approach. The classification consists of 5 classes of varying perforation severity, each with corresponding management techniques. We will also introduce two medical terms, sinus cavity space (SCS), and sinus membrane space (SMS). It is very important to distinguish between these two spaces in this article as they both occupy the same sinus area and are distinguished by the existence of a perforation.

Conclusions: This article presents a new identification method and treatment planning guide for sinus membrane perforations. We have attempted to account for all sizes and types of sinus membrane perforations and to create a method for treatment that is both simple to perform and will minimize further complications.

KEY WORDS: Maxillary sinus, bone graft, sinus augmentation, complication, repair

1. CEO and Co-Founder of the Dental Implant Institute, Las Vegas, Nevada
2. President and Co-Founder of the Dental Implant Institute, Las Vegas, Nevada
3. Private Practice limited to otolaryngology, Chang-Hwa City, Taiwan

INTRODUCTION

The advent of crestal approached based sinus lift methods have produced methods to perform a sinus lift procedure with fewer complications, less trauma, and a shorter healing time than the traditional lateral window.[1-10] There are currently only two principle techniques of penetrating the crestal bone in order to reach the sinus membrane. The first involves cracking the bone, better known as the osteotome technique.[6] The second includes drilling through the bone, which is known as hydraulic sinus condensing technique.[2] Once through the bone, there are many modifications that have been developed for actually dissecting the sinus membrane in order to create sinus membrane space (SMS). These methods use a variety of tools and materials such as: bone,[2] sinus elevators,[11] balloon,[14] collagen,[4] sinus condensers,[2] and sinus curettes.[5] Two important terms are introduced in this paper. The aforementioned SMS refers to the space between the sinus membrane and its underlying bone. This space can only be created by elevating the Schneiderian membrane away from the underlying bone. The sinus cavity space (SCS) is that space which can only be reached by perforating the Schneiderian membrane. Under normal circumstances, this space is fully surrounded by intact sinus membrane.

Sinus membrane perforation is a potential obstacle that must be avoided or managed while performing any type of sinus augmentation procedure, whether through crestal or lateral access. Few papers have been published on lateral sinus membrane perforation and their corresponding repair techniques.[4,8] These techniques have been tested and clinically proven successful. This report, however, will show a method of classifying and repairing sinus membrane perforations from a crestal approach.

Whether preexisting, or created during the procedure itself, a sinus perforation can cause short and long term complications[5,8,9] and should be dealt with immediately. By classifying the perforations we provide a simple set of rules to follow when performing these procedures. These procedures allow the clinician to quickly identify and execute the proper technique necessary to promote the healing of the sinus membrane and the overall health of the patient.

CLASSIFICATION OF SINUS MEMBRANE PERFORATIONS

The classification of membrane perforations will be made primarily by size and degree of separation of the soft and hard tissues. Perforations will be separated into 5 classes, each with their own severity and course of action.

Class 1 Perforation – Utilize Grafting Material

A class 1 perforation is less than 2mm in diameter. A membrane perforation into the SCS of less than 2mm is not typically cause for concern[8,9] and will not usually require any special treatment. Simply continue the bone graft and implant placement exercising extreme care not to enlarge the perforation. The act of elevating the sinus membrane will naturally cause the perforated membrane to fold over itself, causing the membrane to close and heal. The perforation should heal on its own with no repercussions.

Class 2 Perforation – Sinus Membrane Folding Technique

If the membrane perforation is larger than 2mm but less than 5mm, you may consider per-

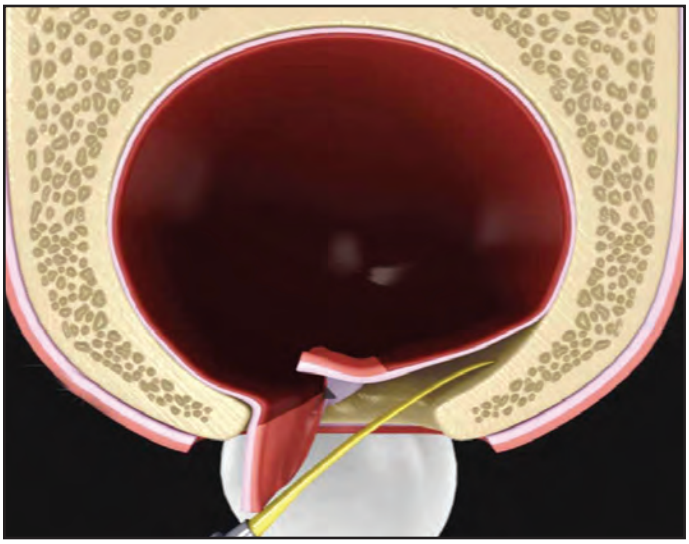

Figure 1a: Dissecting sinus membrane away from underlying bone in a Class 2 membrane perforation.

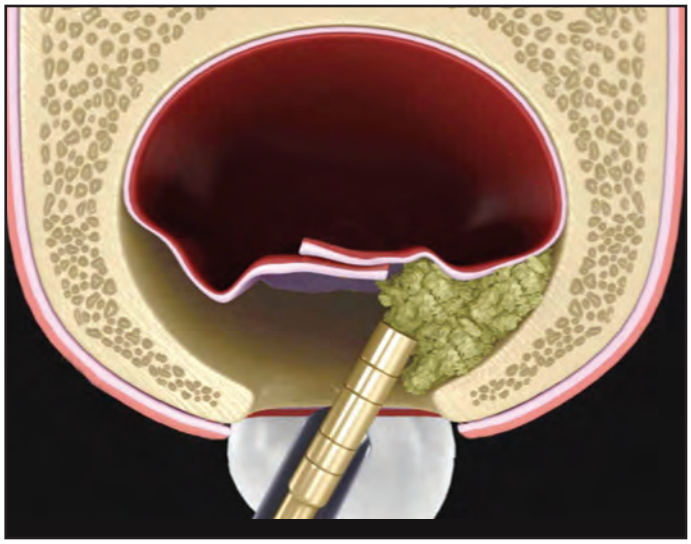

Figure 1b: Condensing bone into the SMS after the sinus membrane has folded itself close in a Class 2 membrane perforation.

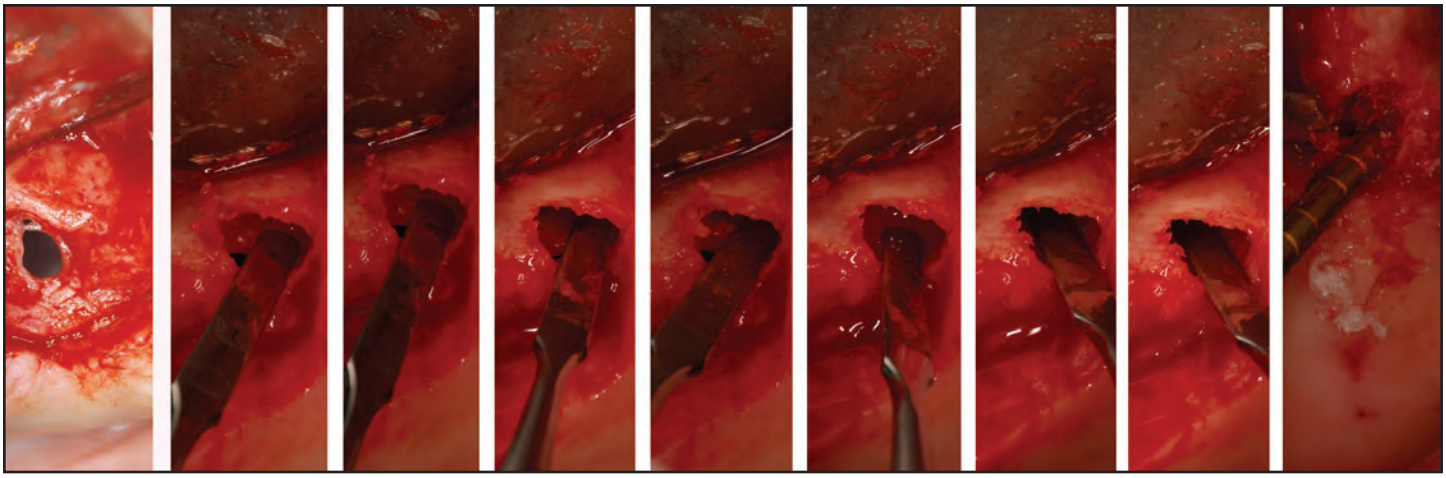

Figure 1c: Multiple clinical photographs depicting closure of a Class 2 membrane perforation utilizing the Sinus Membrane Folding Technique.

forming the Sinus Membrane Folding Technique. This technique can be immediately performed when the space is discovered and the clinician will not need to postpone the bone grafting or placement of implants. This type of perforation is most commonly created during a traumatic extraction or while lifting the sinus membrane and can be seen more in patients with a very thin mucosa.[10]

Gently dissect approximately 5 to 10 mm of membrane from around the edges of the bone. Once this has been accomplished, fold the membrane in on itself while gently elevating the membrane. After folding the mem-

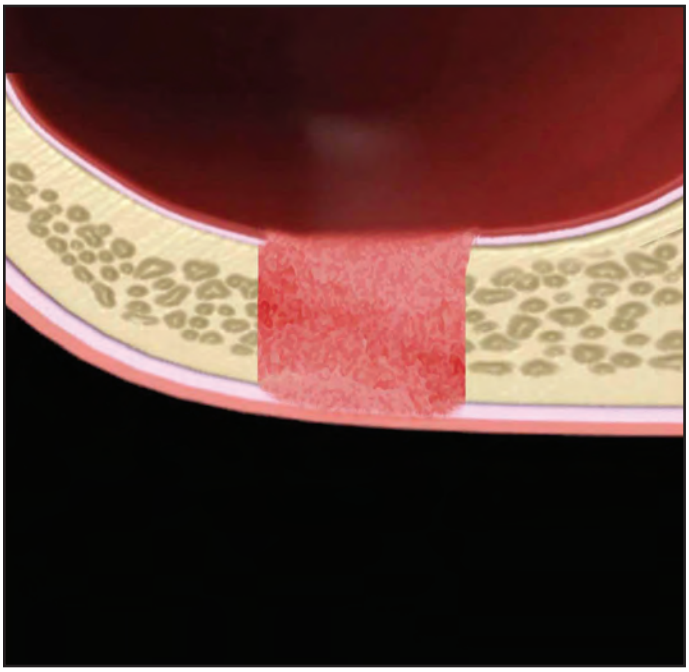

Figure 2a: Primarily healed Class 3 membrane perforation prior to grafting. Note that a soft tissue plug closes the oro-antral communication.

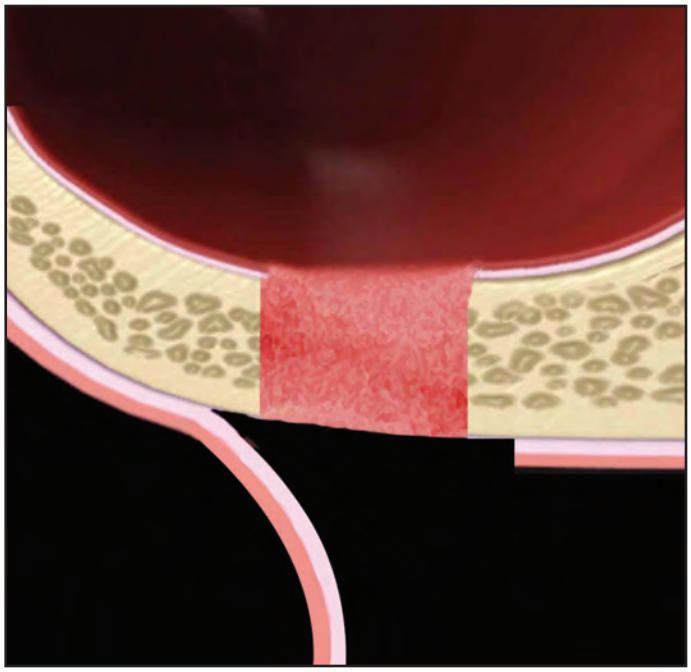

Figure 2b: Split thickness incision allowing the granulation tissue plug to remain fused to the sinus membrane.

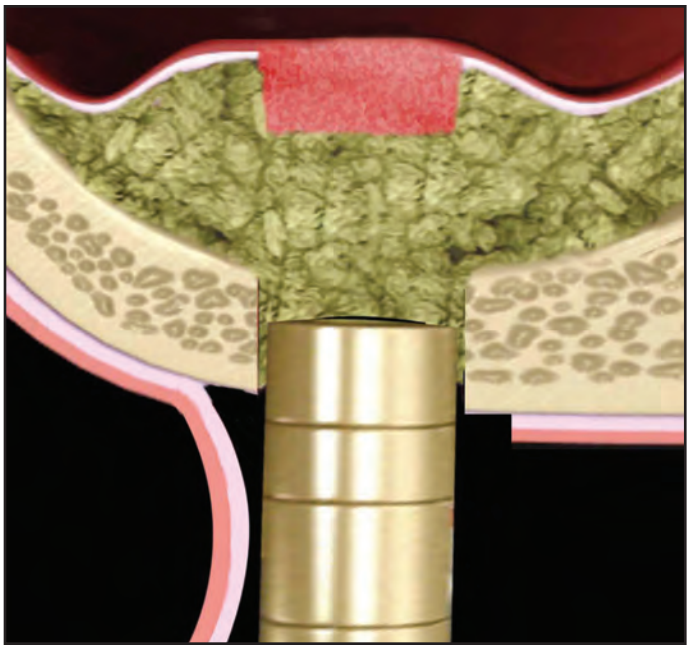

Figure 2c: Bone condensation into the SMS utilizing the granulation tissue plug to close the Class 3 sinus membrane perforation.

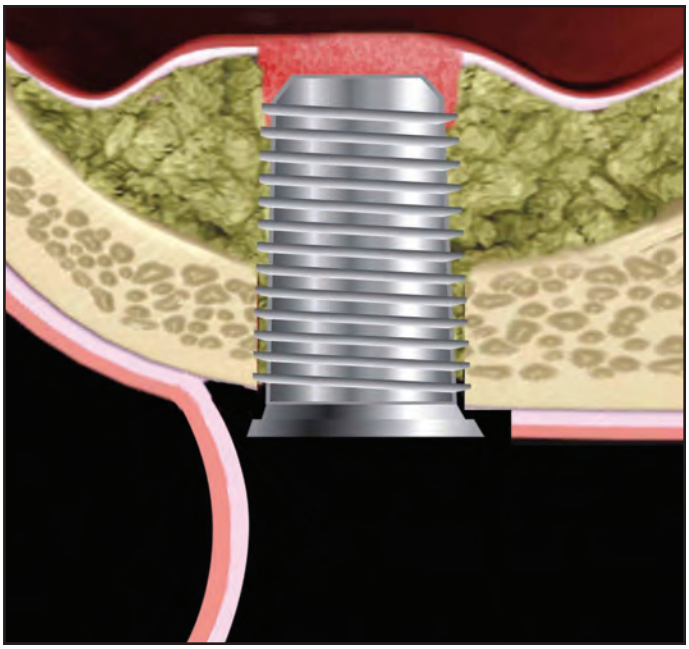

Figure 2d: Dental implant delivery into repaired/grafted Class 3 sinus membrane perforation.

Table 1: Definition of SCS and SMS			
Sinus Cavity Space (SCS)	**Can only be reached through a perforation in the sinus membrane**	**Must remain a cavity**	**Naturally occuring from birth**
Sinus Membrane Space (SMS)	**Cannot exist in an area where a sinus membrane perforation exists**	**Can be filled in**	**Created by dissecting the sinus membrane from the bone**

brane and gently elevating, place your bone grafting material inside the SMS. Using bone grafting material to compact the membrane will adequately seal the perforation, allowing you to continue normally with the implant procedure. Demonstration of Class 2 sinus perforation and repair is shown in figures 1a-1c.

Class 3 Perforation – Delayed Membrane Sandwich Technique

A class 3 perforation will consist of a complete tear (greater than 5mm) of the sinus membrane occurring during a surgical procedure causing the SCS to be fully exposed. In a class 3 situation, you will not be able to locate the SMS. The patient will not be eligible for a sinus lift procedure until the gingival tissue is fully formed. As the membrane is already perforated beyond repair, you should not sequential drill the osteotomy. Instead, utilize the final drill size to efficiently complete the osteotomy through to the SCS. While apparently counter-intuitive, this will create a uniform osteotomy, which will allow for predictable healing results and a safer re-entry into the SMS once the osteotomy has healed. Close the site and allow it to heal for a minimum of 3 weeks. This will allow gingival tissue to grow in the area of the perforation and granulation tissue to form in the osteotomy.

Once this tissue has fully healed, you can then reopen the site and make a split thickness incision in order to create a flap with the gingival tissue and expose both the osteotomy and the granulation tissue plug. Over the course of 3 weeks the sinus membrane or gingival connective tissue will have had a chance to repair and attach to the granulation tissue. The newly formed granulated plug will have fully compartmentalized the SCS and SMS. Using a condenser, elevate the sinus membrane/gingival connective tissue gently using bone graft material (in effect, this "sandwiches" the bone between the connective tissue.) You are now able to place an implant in the SMS. Demonstration of Class 3 sinus perforation and repair is shown in figures 2a-2d.

Class 4 Perforation - Split Thickness Sinus "Membrane Sandwich" Technique

While class 1, 2, and 3, perforations are typically encountered and repaired during the surgical procedure, class 4 and 5 perforations

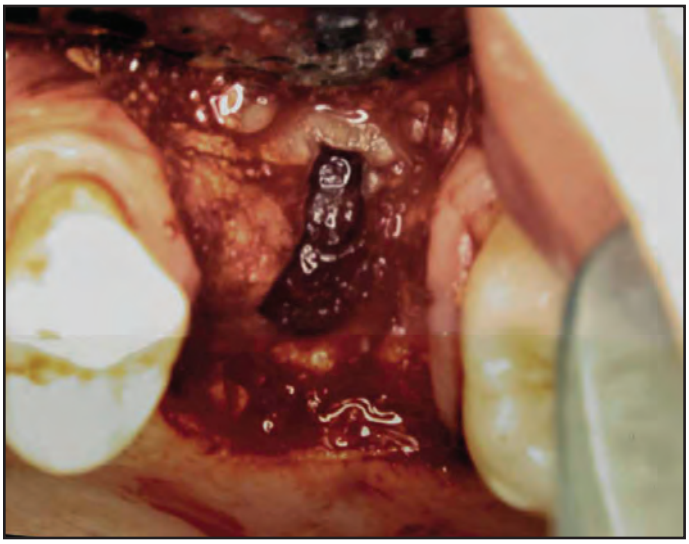

Figure 3a: Intra-surgical photograph of Class 4 sinus membrane perforation prior to treatment.

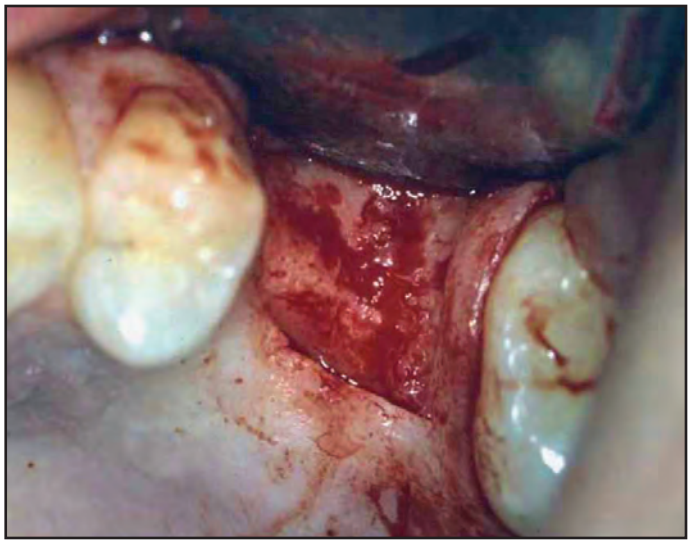

Figure 3b: Intra-surgical photograph of Class 4 sinus membrane perforation after treatment.

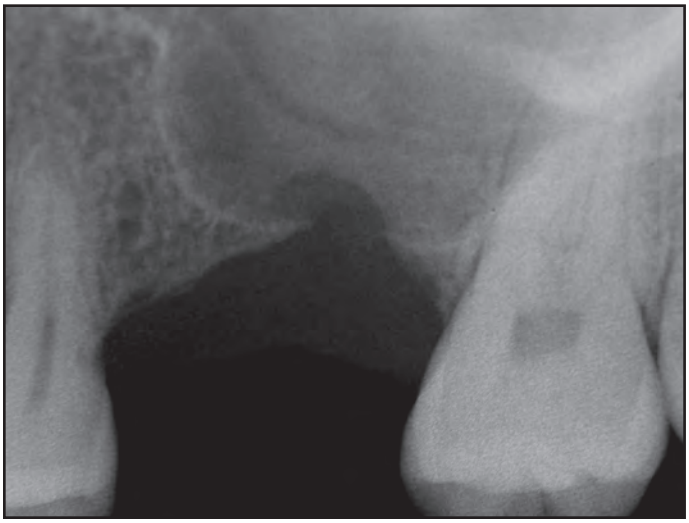

Figure 3c: Radiograph of Class 4 sinus membrane perforation prior to treatment.

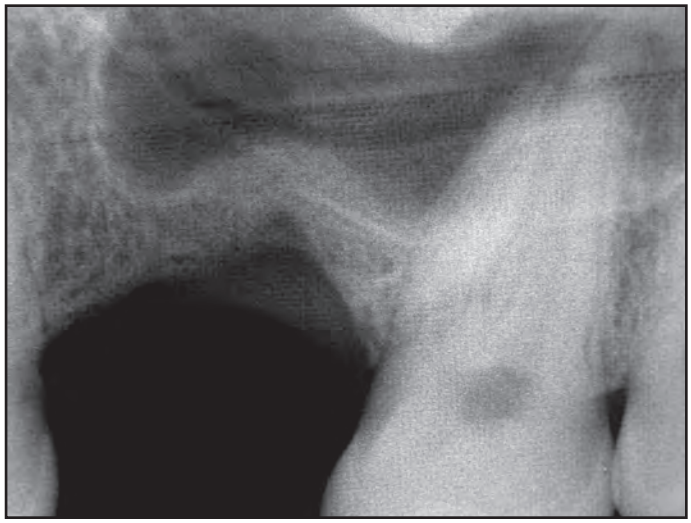

Figure 3d: Radiograph of Class 4 sinus membrane perforation after treatment.

will be encountered after the perforation has occurred and typically has attempted to heal. These perforations are usually created during extraction complications, or multiple failed sinus lift attempts. A class 4 perforation will show bony antra-oral communication, with only the soft tissue intact. This type of perforation will require the "Membrane Sandwich Technique". This technique is identical to the "Delayed Membrane Sandwich Technique" with one difference. Instead of making a final osteotomy and waiting for it to heal, we are using the site as it has naturally healed. This is basically the delayed technique without the delay, and again

Table 2: Perforation Size, Classification, and Repair Technique					
	Class 1 Perforation	Class 2 Perforation	Class 3 Perforation	Class 4 Perforation	C lass 5 Perforation
Size	< 2mm	2 - 5mm	Complete tear	Bony oro-antral communication, soft tissue intact	Complete communication. Soft and hard tissues are separated
Repair Technique	Continue with bone grafting	Sinus membrane folding technique	Delayed membrane sandwich technique	Split thickness sinus membrane sandwich technique	Invagination technique

is only suitable in those cases where the patient has had a perforated sinus membrane present long enough for tissue to grow into the tooth socket or osteotomy. Make a split thickness incision, and create a gingival connective tissue flap, exposing the healed tissue inside. Use a condenser; elevate the gingival connective tissue flap. Use the connective tissue flap as if it were the sinus membrane itself. Gently "sandwich" bone grafting material between the two gingival connective tissue flaps to create a new SMS. Demonstration of Class 3 sinus perforation and repair is shown in figures 3a-3d.

Class 5 Perforation - Invagination Technique

A class 5 perforation usually results from severe extraction complications or multiple perforations resulting from repeated attempts to perform a sinus lift when both the bone and the gingival tissue fail to heal properly. This perforation is classified by the fact that there is complete antra-oral communication ranging in size from a pinhole, to several centimeters in diameter. In every class 5 perforation, the gingival tissue will have grown into the opening which will prevent the bone or sinus from naturally closing the wound. In order to repair this type of a perforation we need to use the "Invagination Technique."

Start by making an incision in the gingival tissue about 2 mm around the opening. Gently remove the gingival tissue from the bone, and elevate the sinus membrane within the cavity. Due to the antra-oral communication, the sinus membrane will now have extra tissue attached to it in the form of gingival tissue that will have flapped from the bone. It is important to be very gentle while working with this gingival tissue. Fold the gingival connective tissue together and secure with a resorbable suture on the extra gingival tissue. By suturing the gingival tissue together, the SCS and

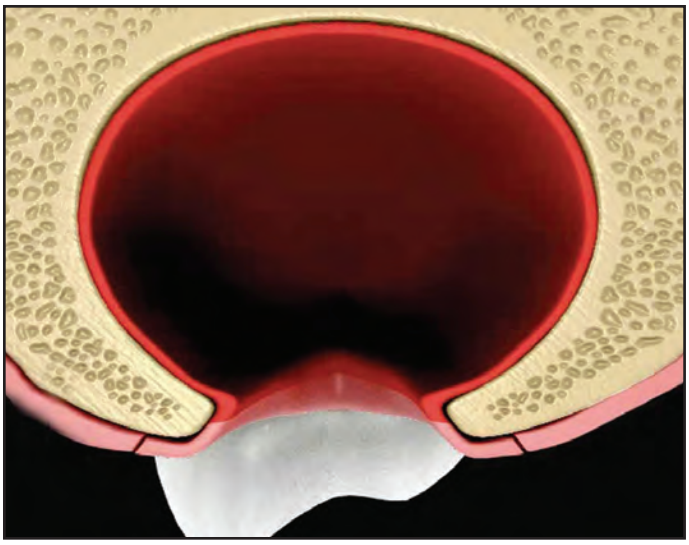

Figure 4a: Class 5 sinus membrane perforation.

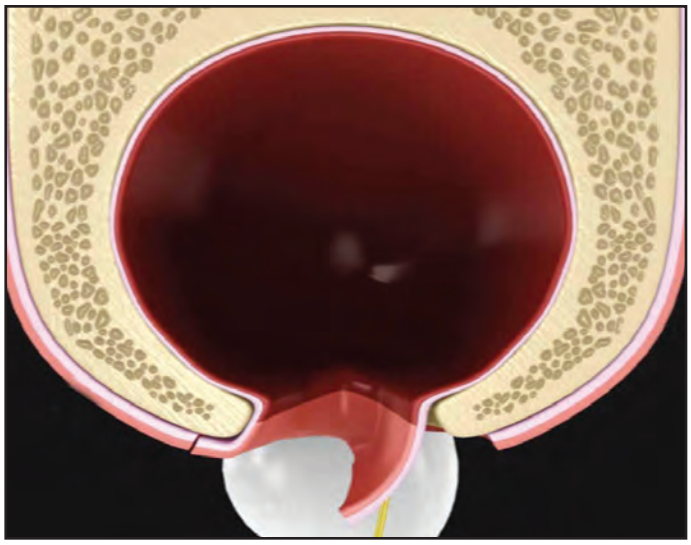

Figure 4b: Split thickness dissection of gingival tissue surrounding Class 5 sinus membrane perforation. Note that the gingival tissue remains attached to the Schneiderian membrane at the perimeter of the perforation.

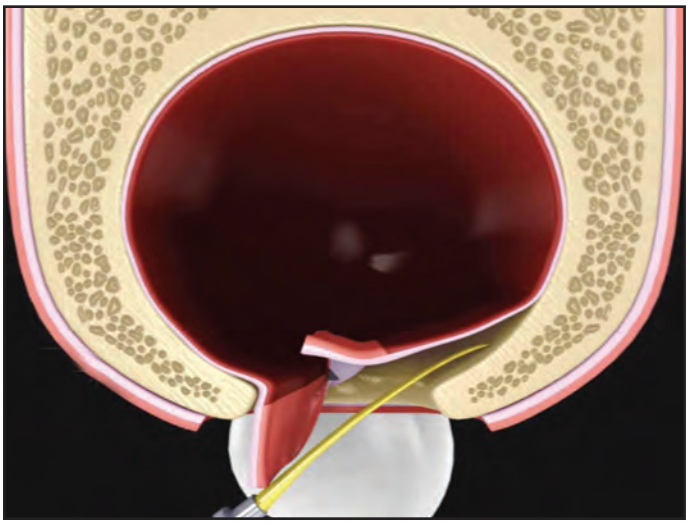

Figure 4c: Initial elevation of sinus membrane/gingival tissue in the Class 5 sinus membrane perforation repair.

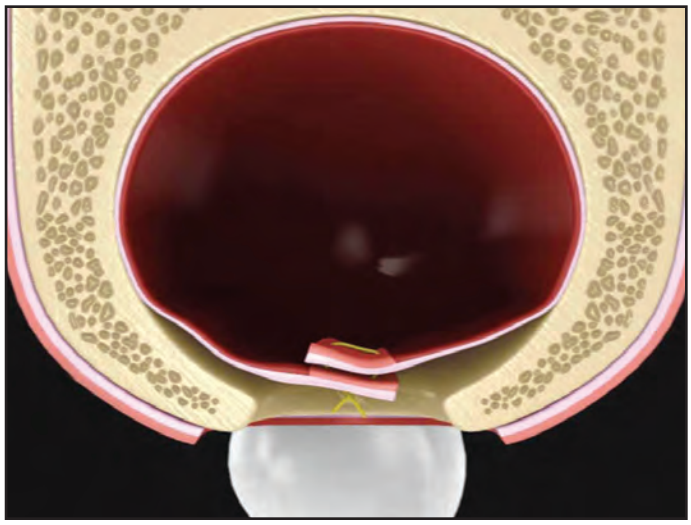

Figure 4d: Once the sinus membrane/gingival tissues have been fully elevated away from the underlying bone, the gingival tissue ring surrounding the perimeter of the Class 5 sinus membrane perforation is sutured together to separate the SMS from the SCS.

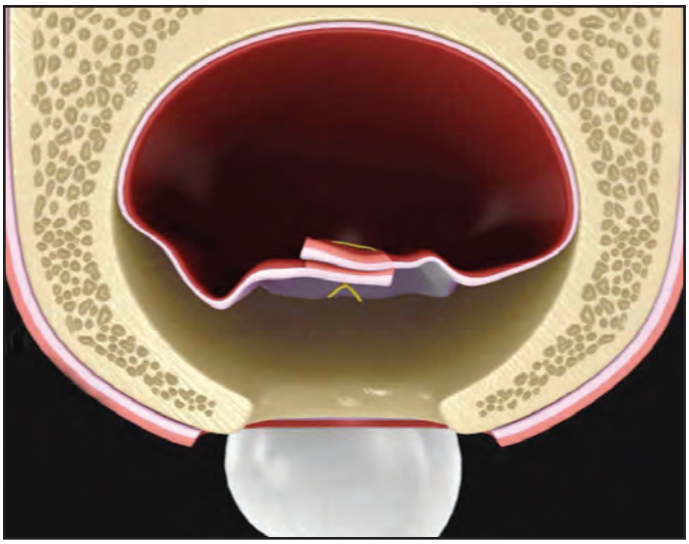

Figure 4e: Continued elevation of the repaired sinus membrane creates a larger SMS.

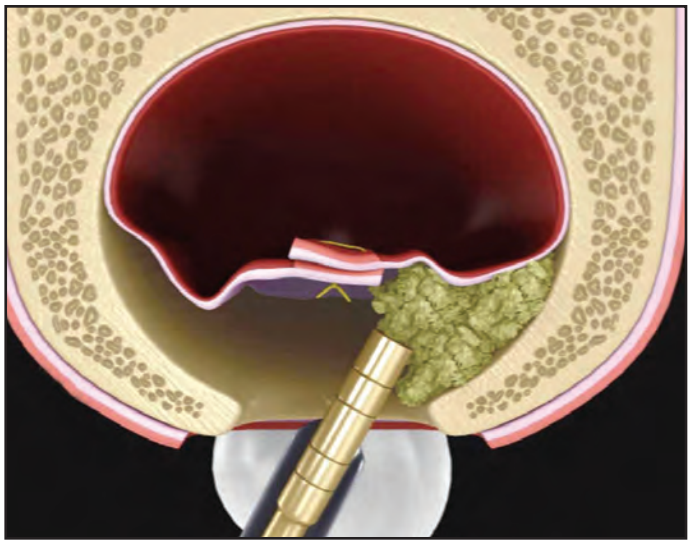

Figure 4f: Initial bone condensation into the SMS following repair of the Class 5 sinus membrane perforation.

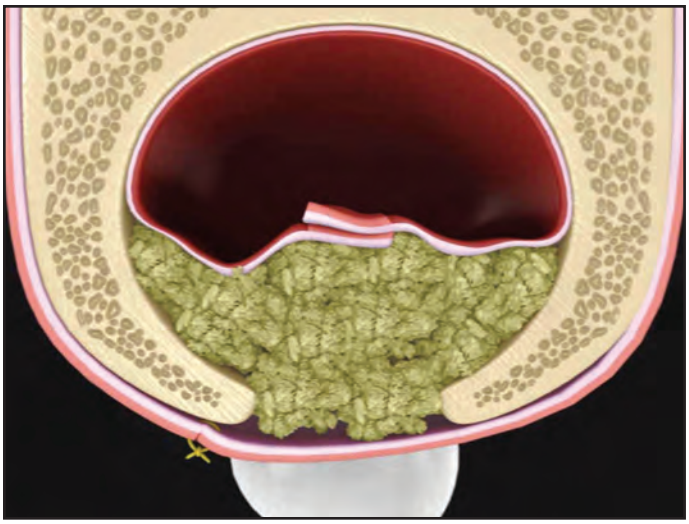

Figure 4g: A buccal flap is advanced to close the crestal access to the repaired/grafted Class 5 sinus membrane perforation.

SMS will separate into two separate spaces. Compact the new SMS with bone grafting material and vertically translate the existing gingival tissue over the site for primary closure.[17] After allowing this area to heal for 3 months, the site will be ideal for implant placement. Demonstration of Class 5 sinus perforation and repair is shown in figures 4a-4o.

DISCUSSION

In order to successfully treat a patient, it is important to be prepared to handle any situation that may arise. The sinus membrane can create many variables in the placement of implants in the maxillary posterior. While membrane perforations are rarer and much easier to repair from a crestal approach than a lateral approach,[3,6] they are still a reality. Membrane perforations can also be created during

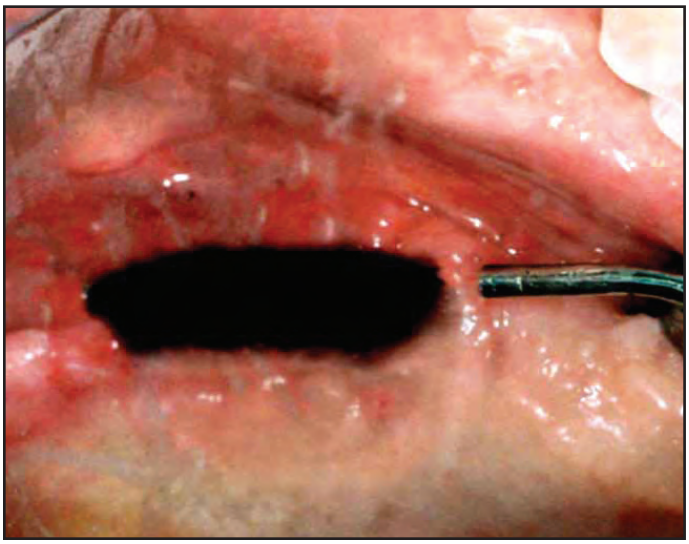

Figure 4h: Intra-surgical photograph of Class 5 sinus membrane perforation.

Figure 4i: Demonstration of split thickness incision around perimeter of Class 5 sinus membrane perforation (corresponds to figure 4b).

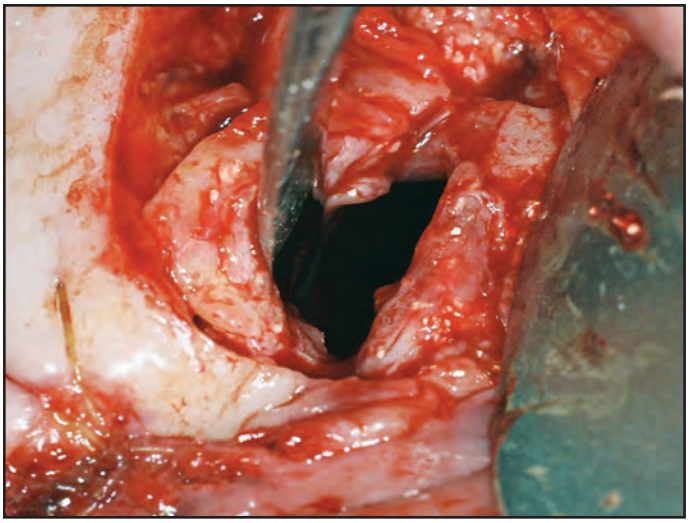

Figure 4j: Intra-surgical photograph of initial elevation of sinus membrane/gingival tissue in the Class 5 sinus membrane perforation repair (corresponds to figure 4c.

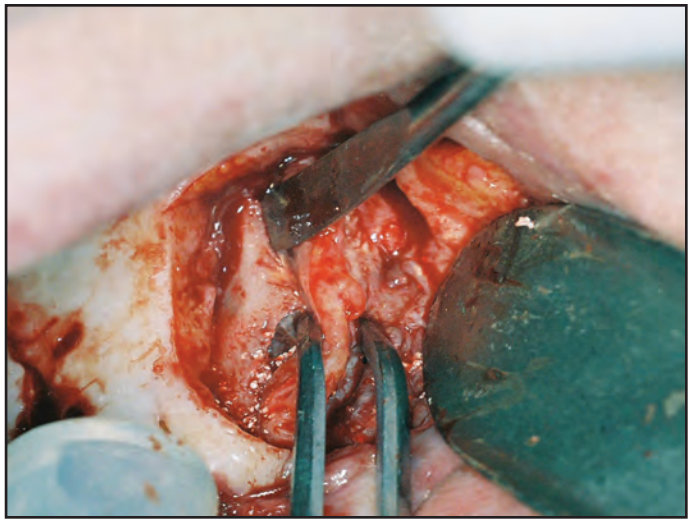

Figure 4k: Intra-surgical photograph showing the gingival tissue ring surrounding the perimeter of the Class 5 sinus membrane perforation being sutured together to separate the SMS from the SCS (corresponds to figure 4d).

extraction or implant placement. Therefore, the membrane could have been perforated months or even years before it is discovered. Knowing how to handle perforations of any size and type will increase your overall success rate and give you more confidence to perform and repair sinus lift procedures in patients regardless of membrane health or bone height.

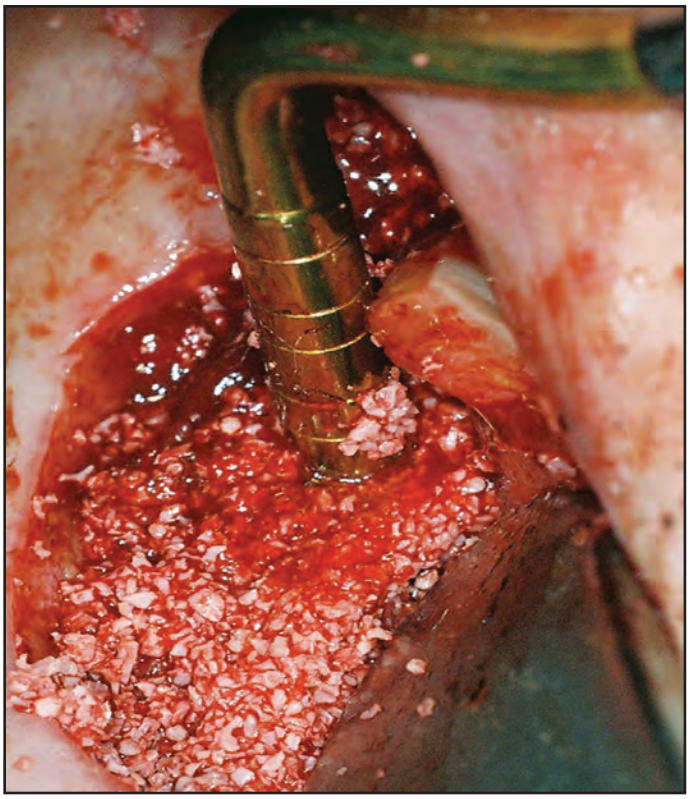

Figure 4l: Intra-surgical photograph of initial bone condensation into the SMS following repair of the Class 5 sinus membrane perforation (corresponds to figure 4f).

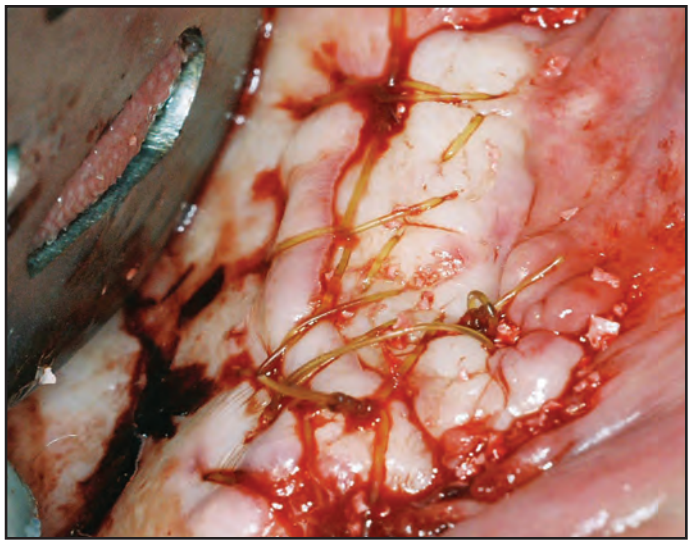

Figure 4m: Intra-surgical photograph of buccal flap being advanced to close the crestal access to the repaired/grafted Class 5 sinus membrane perforation (corresponds to figure 4g).

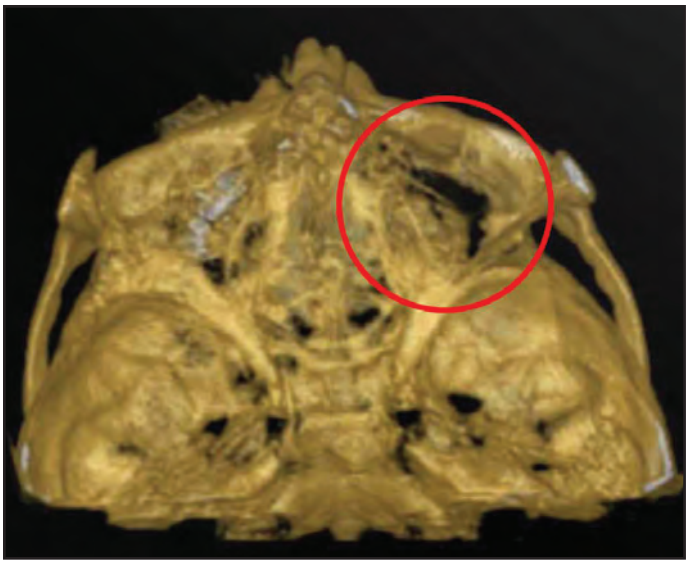

Figure 4n: Pre-surgical CBCT of Class 5 sinus membrane perforation prior to repair.

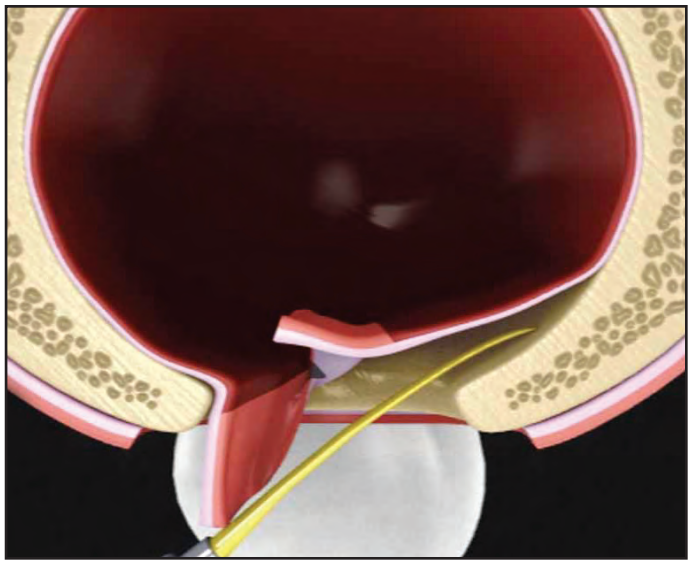

Figure 4o: Post-surgical CBCT of Class 5 sinus membrane perforation after repair.

One thing to note with the Invagination Technique is that the gingival epithelium, that at one time was in the oral cavity, will fold in and become part of the membrane facing the SCS. The gingival connective tissue will then be in the SMS. This will make sure that the sinus cavity is completely covered with epithelial tissue, while the non-epithelial connective tissue will be facing the graft material.

While more research and long term follow-up studies need to be performed, the goal of these techniques is that clinicians using this guide will be able to repair any sinus membrane perforation that they encounter.

CONCLUSIONS

This article presents a new identification method and treatment planning guide for sinus membrane perforations. We have attempted to account for all sizes and types of sinus membrane perforation, and to create a method for treatment that is both simple to perform and will minimize further complications.

Correspondence:
Dr. Chen
Dental Implant Institute
6170 W Desert Inn Rd.
Las Vegas, Nevada, USA 89146
Phone: (702) 220-5000
Fax: (702) 247-4014
E-mail: drchen@diilv.com

Disclosure
The authors report no conflicts of interest with anything mentioned in this article.

References

1: Ferrigno N, Laureti M, Fanali S. Dental implant placement in conjunction with osteotom sinus floor elevation: a 12-year life-table analysis from a prospective study on 588 ITI implants. Clin Oral Implants Res 2006; 17(2):194-205.

2: Chen, Leon, & Cha, Jennifer. An 8-Year Retrospective Study: 1,100 Patients Receiving 1,557 Implants using the Minimally Invasive Hydraulic Sinus Condensing Technique. Innovations in Periodontics 2005; 76(3):482-491.

3: Hernández-Alfaro F, Torradeflot MM, Marti C. Prevalence and management of Schneidarian membrane perforations during sinus-lift procedures. Clin Oral Implants Res 2008; 19(1): 91-98.

4: Pikos MA. Maxillary sinus membrane repair: update on technique for large and complete perforations. Implant Dent 2008; 17(1):24-31.

5: Misch CE. The maxillary sinus lift and sinus graft surgery. In: Misch CE, ed. Contemporary Implant Dentistry. Chicago, IL:Mosby;1999:469-495.

6: Summers, RB. The osteotome technique: part 3. Less invasive methods of elevating the sinus floor. Compendium Cont Educat Dent 1994. 15(6):698-708.

7: Chanavaz, M. Maxillary sinus: anatomy, physiology, surgery, and bone grafting related to implantology - eleven years of surgical experience (1979-1990). J Oral Implantology 1990; 16(3):199-209.

8: Fugazzotto P, Vlassis J. A Simplified Classification and Repair System for Sinus Membrane Perforations. Innovations in Periodontics 2003; 73(10): 1534-1542.

9: Aimetti M, Romognoli R, Ricci G, Massei G. Maxillary sinus elevation: the effect of macrolacerations and microlacerations of the sinus membrane as determined by endoscopy. Int J Periodontics and Rest Dent 2001; 21(6):581-589.

10: Nkenke E, Schlegel A, Schultze-Mosgau S, Neukam FW, Wiltfang J. The endoscopically controlled osteotome sinus floor elevation: a preliminary prospective study. Int J Oral Maxillofac Implants 2002; 17(4):557-566.

11: Tatum, O.H. Jr., Maxillary and sinus implant reconstruction, Dental Clinics of North America 1986; 30:207-229.

12: Wood RM, Moore DL. Grafting of the maxillary sinus floor with intraorally harvested autogenous bone prior to implant placement. Int J Oral Maxillofac Implants 1988; 3: 209-214.

13: Zinner I, Small S. Sinus lift graft: using the maxillary sinuses to support implants. J Am Dent Assoc 1996; 127:51-57.

14: Soltan, Muna, Smiler, Dennis G. Antral Membrane Balloon Elevation. J Oral Implantology 2005; 31(2):85-90.

15: Wallace SS, Mazor Z, Froum SJ, Cho SC, Tarnow DP. Schneiderian membrane perforation rate during sinus elevation using piezosurgery: clinical results of 100 consecutive cases. Int J Periodontics Rest Dent 2007; 27(5):413-419.

16: Tatum OH, Maxillary sinus grafting for endosseous implants. Presented at the annual meeting of the Alabama Implant Study Group. Birmingham Alabama, April 1977.

17: Chen L, Cha J, Chih-Hsiang H. A Three-Point-Translation Technique for Root Coverage With 4 Year Follow-up. Dentistry Today 2002; 21(10):112-115.