

# Brain morphological changes in patients with Tourette syndrome: a voxel- and surface-based morphometry multi-site study

S Schmitt<sup>1</sup>, K Müller<sup>2</sup>, A S Kanaan<sup>2</sup>, R Torrecuso<sup>2</sup>, H Möller<sup>2</sup> and K R Müller-Vahl<sup>1</sup>

<sup>1</sup>Clinic of Psychiatry, Social Psychiatry and Psychotherapy, Hannover Medical School, Hannover, Germany

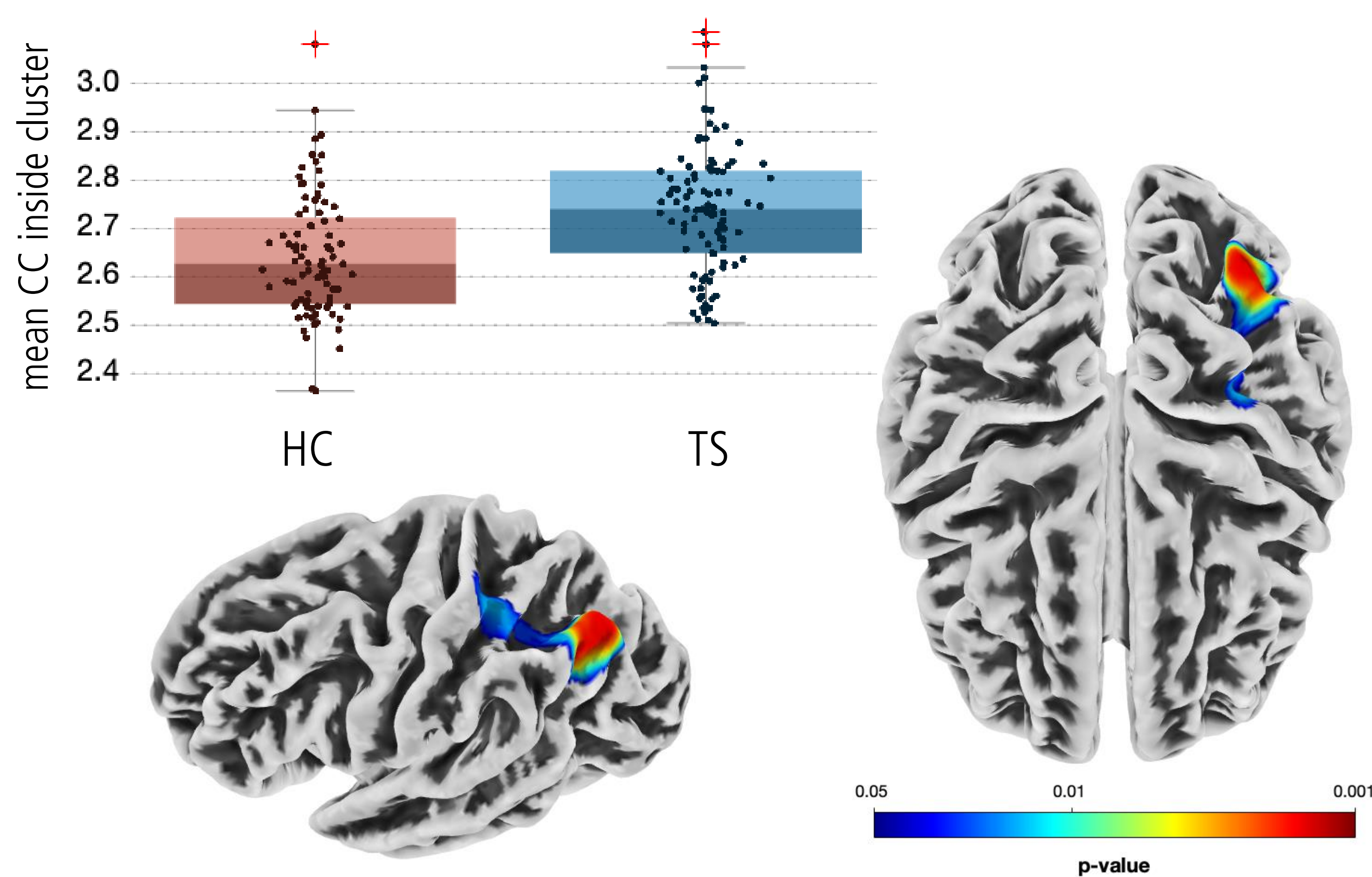
<sup>2</sup>Max Planck Institute for Human Cognitive and Brain Sciences, Leipzig, Germany

## Background

- Brain morphological imaging studies in Tourette syndrome (TS) mainly investigated grey matter volumes which have overall yielded mixed results. Brain folding parameters have rarely been explored.
- These cortical folding parameters could be a promising biomarker since the genesis of brain folding is more genetically influenced and TS is highly heritable. Additionally, brain folding markers are temporally more stable than biomarkers measuring grey matter volumes or cortical thickness increasing the validity of potential results.
- In this study, we would also like to address the issue that the quality of MRI scans may be worse in TS patients due to their tics, which has often not been considered in previous studies.

## Results

- TS patients showed significant more cortical complexity in a vertex cluster ranging over the inferior parietal (65%), superior parietal (28%), postcentral (6%) and supramarginal cortex (1%) in the left hemisphere ( $k=846$ ,  $p=0.0016$ , FWE-corrected).
- Groups did not differ significantly regarding grey matter volumes, cortical thickness and gyrification.



cluster peaks inside cluster	k (cluster size)	TFCE (test statistic)	p <sub>FWE</sub>
		8787.53	0.002
	846	8762.24	0.002
		5825.39	0.027

## Methods

- We present a large sample of TS patients and healthy controls (HC) including data from four different German studies (99 TS patients and 89 HC).
- Using CAT12, we extracted grey matter volumes, cortical thickness, gyrification and cortical complexity (CC) from t1-weighted images.
- We used a non-parametric TFCE-statistic (threshold free cluster enhancement) with  $\alpha = 0.05$  and FWE (family-wise error correction) to analyse brain morphological differences between groups.
- Weighted image quality ratings (IQR) were calculated and compared across groups.

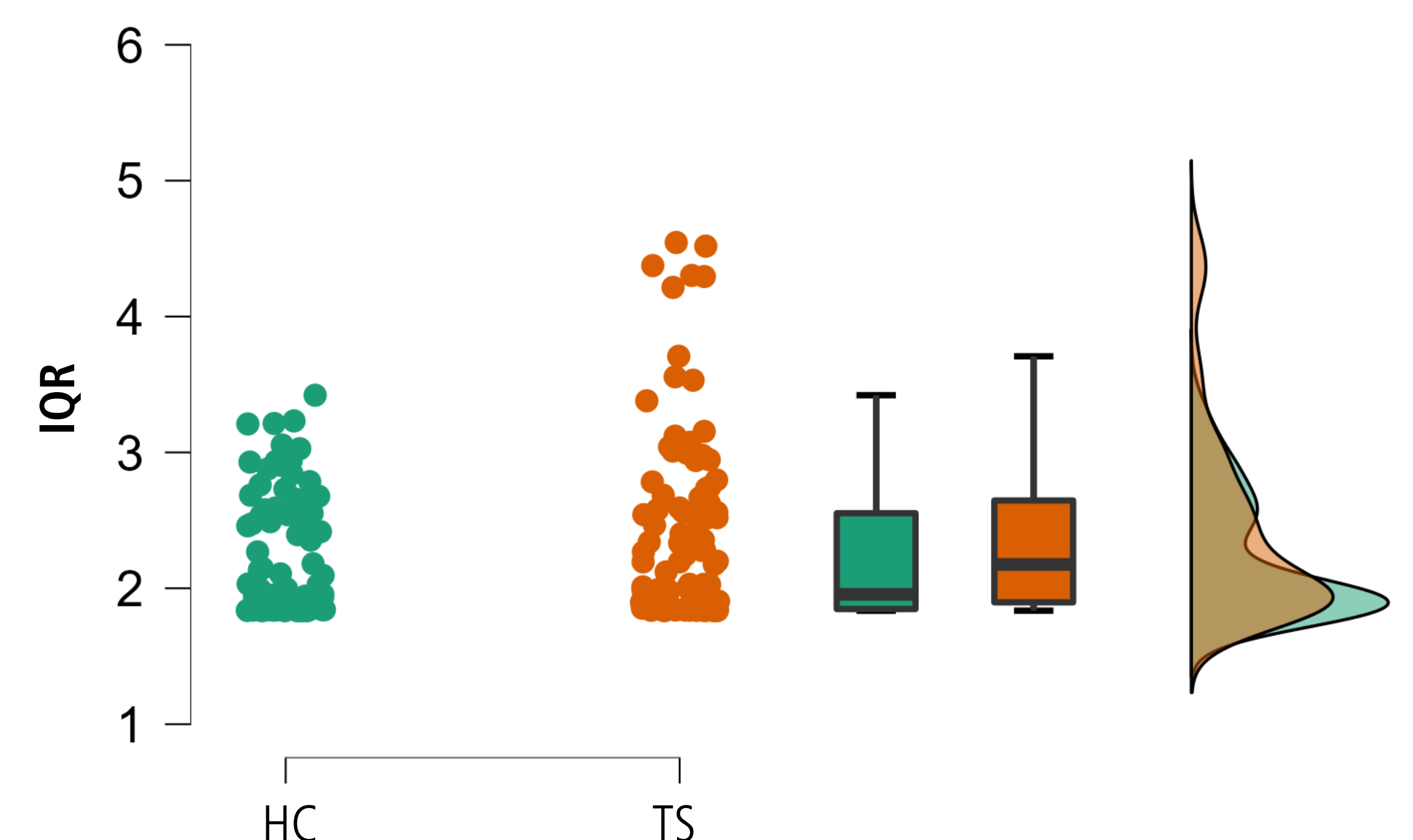
- Automated anatomical labelling showed that the significant vertex cluster is reaching over these cortical areas:

- 65% inferiorparietal
- 28% superiorparietal
- 6% postcentral
- 1% supramarginal

- IQR were significantly poorer in TS patients compared to healthy controls.

	group	mean	SD	t(df)	p	Cohen's d
IQR	HC	2.215	0.441	-2.206	0.029	-0.322
	TS	2.402	0.682	(186)		

*Note.* Low IQR indicate higher mean correlation, i.e. reflect better imaging quality



## Conclusions

- All morphologically altered brain regions are part of the parietal lobe which plays a key role in the integration and interpretation of (somato)sensory information.
- This finding could help to better understand the neurobiological basis of premonitory urges observed in TS patients.
- Interpretation of results from brain morphological studies in TS in general should be drawn with caution since head motion during MRI acquisition impacts on VBM/SBM estimates.