

THE DISTAL BICEPS TENDON: NEW INSIGHTS IN
DIAGNOSIS AND TREATMENT

Pieter CAEKEBEKE

ABBREVIATIONS AND GLOSSARY

**INTRODUCTION: ACUTE COMPLETE AND PARTIAL DISTAL BICEPS
TENDON RUPTURES**

OBJECTIVES AND RESEARCH QUESTIONS

**PART 1: IMPROVEMENT AND EVALUATION OF DIAGNOSTIC TOOLS
FOR DISTAL BICEPS TENDON PATHOLOGY**

CLINICAL DIAGNOSIS

CHAPTER 1: DEVELOPMENT OF A SPECIFIC TEST FOR PARTIAL DISTAL
BICEPS TENDON RUPTURES, BICIPITAL BURSITIS AND TENDINOSIS

CHAPTER 2: EVALUATION OF CLINICAL TESTS FOR PARTIAL DISTAL
BICEPS TENDON RUPTURES, BICIPITAL BURSITIS AND TENDINOSIS

TECHNICAL DIAGNOSIS

CHAPTER 3: EVALUATION OF MRI SIGNAL CHANGES OF THE DISTAL
BICEPS TENDON IN ASYMPTOMATIC PATIENTS

CHAPTER 4: COMPARISON OF TWO MRI TECHNIQUES IN THE DIAGNOSIS
OF PARTIAL DISTAL BICEPS TENDON RUPTURES

**PART 2: IMPROVEMENT AND EVALUATION OF TREATMENT OPTIONS
FOR DISTAL BICEPS TENDON PATHOLOGY**

TREATMENT OF PARTIAL RUPTURES

CHAPTER 5: EVALUATION OF THE SAFETY OF THE SINGLE-INCISION
ENDOSCOPY OF THE DISTAL BICEPS TENDON

TREATMENT OF COMPLETE RUPTURES

CHAPTER 6: IDENTIFYING ANATOMIC LANDMARKS IMPORTANT FOR
INTRAMEDULLAR DISTAL BICEPS TENDON FIXATION

CHAPTER 7: BIOMECHANICAL EVALUATION OF AN INTRAMEDULLAR
DISTAL BICEPS TENDON FIXATION DEVICE

CHAPTER 8: CLINICAL EVALUATION OF THE INTRAMEDULLARY
FIXATION DEVICE

CHAPTER 9: DOES INTRAMEDULLAR ANATOMICAL REINSERTION LEAD
TO BETTER SUPINATION STRENGTH?

DISCUSSION AND CONCLUSIONS

ENGLISH SUMMARY

NEDERLANDSTALIGE SAMENVATTING

ACKNOWLEDGEMENTS

CURRICULUM VITAE

ABBREVIATIONS AND GLOSSARY

DBT	Distal biceps tendon
BPT	Biceps provocation test
BPTs	Supination part of the biceps provocation test
BPTp	Pronation part of the biceps provocation test
ECU	Extensor carpi ulnaris
EDC	Extensor digitorum communis
HO	Heterotopic bone formation
LACN	Lateral antebrachial cutaneous nerve
MRI	Magnetic resonance imaging
PIN	Posterior interosseous nerve
aPIN	Anterior part PIN
pPIN	Posterior part PIN
PEEK	Poly-ether ether ketone
PLLA	Poly-L-lactide
IRR	Inter-rater (observer) reliability
MRI	Magnetic resonance imaging
US	Ultrasound
ASES elbow score	The American Shoulder and Elbow Surgeons elbow score
DASH score	Disabilities of the arm, shoulder and hand score
PREE score	patient-rated elbow evaluation score

INTRODUCTION:

ACUTE COMPLETE AND PARTIAL DISTAL BICEPS TENDON RUPTURES

Adapted from:

Caekebeke P, Duerinckx J, van Riet R, *Acute complete and partial distal biceps tendon ruptures: what have we learned? A review.* EFORT Open Rev 2021; 6: 956-965

Caekebeke P, Bain GI, van Riet R, *Distal biceps tendon repair with the Endobutton technique.* Book chapter in *Surgical techniques for trauma and sports related injuries of the elbow*, G.I. Bain, D. Eygendaal and R. van Riet, Editors. 2019, Springer.

Caekebeke P, van Riet R, *Distal biceps endoscopy.* Book chapter in *Surgical Techniques for trauma and sports related injuries of the elbow*, G.I. Bain, D. Eygendaal and R. van Riet, Editors. 2019, Springer.

The biceps muscle is the main supinator and an important flexor of the elbow. Tendon ruptures can occur both in the proximal and the distal tendon insertion. Distal biceps tendon ruptures are relatively uncommon and comprise approximately 3% of all biceps tendon ruptures. A rupture of the distal biceps tendon may lead to significant functional and esthetical impairment for the patient. Clinical and technical diagnostic tools are important to ensure accurate and timely identification of the pathology. Treatment of these pathologies aims to restore optimal function and strength for the patient without potential complications. The purpose of this thesis is to identify, evaluate and improve shortcomings in current diagnostic strategies and treatment options. This starts with an understanding of the relevant anatomy, epidemiology and pathophysiology as this will dictate further improvements in diagnosis and treatment.

ANATOMY

The biceps muscle consists of two distinct muscle heads and is innervated by the musculocutaneous nerve. Distally, the biceps inserts with a tendon and the lacertus fibrosus. The tendon has long been described as one single structure, but Eames et al. clearly showed the distinction between the long and short heads at the distal insertion (Eames et al. 2007). Both tendons attach to the posterior aspect of the radial tuberosity (Athwal et al. 2007). At the level of the musculotendinous junction the short head lies medial to long head. The tendon externally rotates 90° while it traverses the bicipital tunnel. This rotation positions the short head distal to the long head. The tendon of the long head inserts proximal and posterior on the bicipital tuberosity of the radius. This location dictates a contribution mostly to a supination moment of the forearm. The tendon of the short head inserts more distal on the radial tuberosity giving it a greater elbow flexion moment (Jarrett et al. 2012). The radial tuberosity has a protuberance just

anterior to the distal biceps insertion which acts as a cam increasing the supination force (Schmidt et al. 2015, Schmidt et al. 2010) (Figure 1).

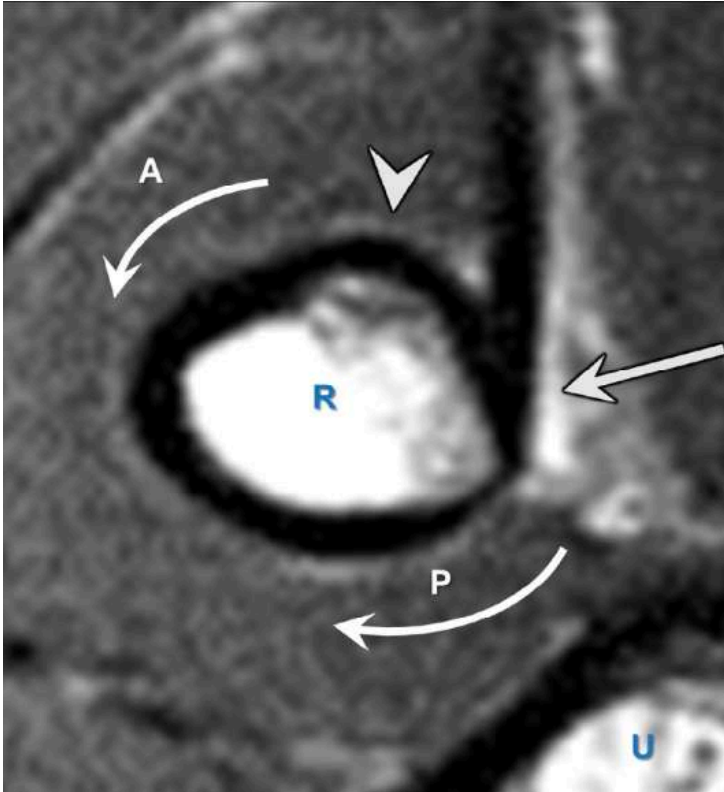


Figure 1: An axial magnetic resonance imaging cut through the biceps tendon insertion site. The protuberance (*arrowhead*) is a specialized geographic part of the radial tuberosity located anterior to the biceps insertion. The protuberance functions as a supination cam. *A*, area of radius anterior to the insertion site; *P*, posterior to the insertion site; *R*, radius; *U*, ulna; *BT*, biceps tendon). From Schmidt CC, Brown BT, Williams BG, Rubright JH, Schmidt DL, Pic AC, et al. The Importance of Preserving the Radial Tuberosity During Distal Biceps Repair. *J Bone Joint Surg Am.* 2015;97:2014-23. DOI: 10.2106/JBJS.N.01221.

The lacertus fibrosus originates at the level of the musculotendinous junction and consists of three distinct layers, enveloping the forearm flexors and serving as a stabilizer

to the distal biceps tendon (Bhatia et al. 2017). A tense lacertus fibrosus secondary to contraction of the forearm flexors may contribute to tendon rupture due to a medial pull at the time of injury (Miyamoto et al. 2010). The preservation of the lacertus at the time of surgery remains controversial (Landa et al. 2009).

The vascularity of the distal biceps tendon can be categorized in a proximal, middle and distal zone. The proximal zone is comprised of the musculotendinous junction and the proximal tendon. It is supplied by branches of the brachial artery which continue in the paratenon. The distal zone is supplied by the posterior interosseous recurrent artery. The middle zone is a hypovascular zone which averages 2.14 cm in length and is supplied by the two beforementioned arteries although only through its thin extratendinous paratenon cover (Seiler et al. 1995). The radial recurrent artery branched of the radial artery lies superficial to the distal biceps tendon and is often accompanied by 2 to 4 venous structures. Variations in number and branches of the artery have been described (Zeltser et al. 2016).

Several nerves run across the forearm. Two are of special interest as they are at risk during surgical repair. Anteriorly, the lateral antebrachial cutaneous nerve (LABCN) is a terminal sensory branch of the musculocutaneous nerve. It bifurcates in two branches that supply the volar-radial portion of the wrist, portions of the thumb and the distal two-thirds of the dorsolateral forearm. It has been shown to run at the lateral aspect of the distal biceps tendon, often with the cephalic vein (Figure 2). Posteriorly, the posterior interosseous nerve (PIN) is the terminal motor branch of the radial nerve. It supplies hand and wrist extensors. It runs in close contact with the radius circling the bone from anterior to posterior. The exact position with regard to the distal biceps tendon and radial tuberosity depends on the position of the forearm in supination or pronation. The biceps itself is innervated by the musculocutaneous nerve (Figure 3).

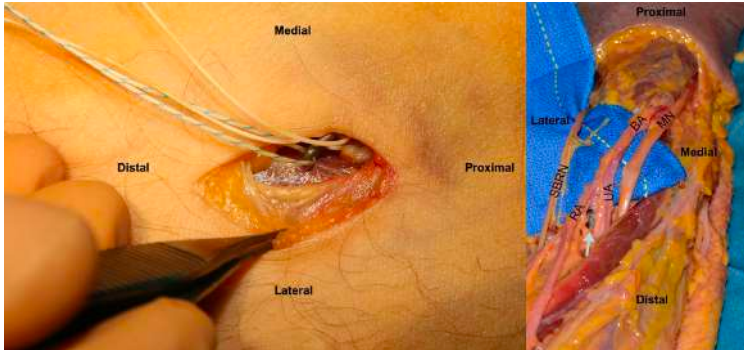


Figure 2: Localization of the lateral antebrachial cutaneous nerve (LACN), the superficial branch of radial nerve (SBRN), the median nerve (MN), the ulnar artery (UA), radial and recurrent radial arteries (RA), and their bifurcation. Biceps flagged with white arrow.

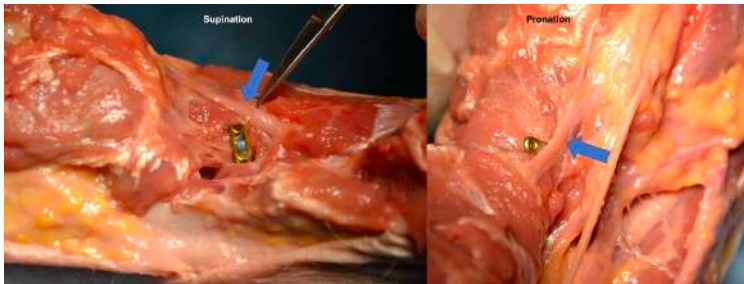


Figure 3: The posterior interosseous nerve runs in close contact with the radius, circling the bone from anterior to posterior. The exact position with regard to the distal biceps tendon and radial tuberosity depends on the position of the forearm in supination or pronation. Position shown in relation to a bicortical button.

EPIDEMIOLOGY

We found no clear record of the exact incidence of partial distal biceps tears. This is mainly due to the fact that certainly not all patients with partial ruptures seek medical care. Kelly and colleagues reported an incidence of complete distal biceps tendon tears of 2.55 cases per 100.000 patients in a large population database (Kelly et al. 2015). Because they only evaluated surgically treated patients, the actual incidence will likely

be higher. The vast majority of complete distal biceps tendon ruptures occurs in men between 40 and 60 years of age (Kelly, Perkinson et al. 2015, Safran et al. 2002). The dominant limb is involved in 52% of the cases. Interestingly, an 8% cumulative incidence of bilateral biceps tendon ruptures has been reported (Green et al. 2012). Besides the lower incidence in women, an evaluation of distal biceps tendon ruptures in women described a more gradual onset of symptoms and higher incidence of partial tears (Jockel et al. 2010).

PATHOPHYSIOLOGY

The mechanism of injury is typically an eccentric force applied to a flexed and supinated elbow. Preexisting inflammatory or degenerative changes involving the distal biceps tendon, relative hypovascularity and anatomic factors such as a tuberosity spur, might explain why distal biceps tendon ruptures occur. Other predisposing factors include an elevated body mass index (BMI), smoking and steroid use. Elevated BMI, possibly secondary to greater muscle mass, would increase the load on the tendon and may predispose to rupture. Furthermore, obesity has been shown to decrease immune response to acute tendon injury (Del Buono et al. 2011). 36-66% of patients with a distal biceps tendon rupture have been reported to be obese (Kelly, Perkinson et al. 2015, Safran and Graham 2002). The exact incidence of smoking in patients with distal biceps tendon ruptures is unknown, but it is widely accepted that smoking is a predisposing factor in tendon injuries. A possible effect of smoking involves an increased zone of hypovascularity in the tendon between the proximal and distal blood supply (Seiler, Parker et al. 1995). Anabolic steroid use, combined with exercise may lead to dysplasia of collagen fibrils, which can decrease the tensile strength of the tendon. Changes in tendon's crimp morphology have been shown to occur as well, which again may alter the tensile strength of the tendon (Laseter et al. 1991).

There may also be a biomechanical reason for distal biceps tendon rupture. The dynamics of the distal biceps tendon in its excursion from supination to pronation at different flexion angles may result in abrasion and damage to the tendon against the margin of the radial tuberosity, especially as it passes deeper to insert into a more posterior surface of the radius in the pronated position. As shown by computed tomography the narrow passage between the lateral ulnar border and the radial tuberosity was found to decrease by roughly 50% in pronation when compared with supination. In a study of forearm motion, Ray et al. (Ray et al. 1951) demonstrated that during pronation not only does the radius rotate over the ulna, but the distal ulna actually moves laterally in its relationship to the radius. This "ulnar abduction" may account for the significant decrease in the proximal radioulnar canal space. Bony irregularities bordering this osseous canal or inflammation in the biceps tendon could further compromise this narrow inlet, leading to impingement of the biceps tendon as it is rotated through pronation and supination (Seiler et al. 1995, Hilgersom et al. 2021). Although some authors contest this statement (Kodde et al. 2016), a recent study warns that mechanical impingement might explain complications after anatomical reinsertion (Rausch et al. 2020).

DIAGNOSIS OF DISTAL BICEPS TENDON INJURY

Clinical diagnosis

In complete distal biceps tendon ruptures, patients commonly report a history of a sudden eccentric load on a flexed elbow. Patients often report a traumatic "pop". They may present with acute pain and ecchymosis in the antecubital fossa, although the pain may subside quite rapidly. Clinically they present with local tenderness, weakened supination and flexion strength, although the weakness may be difficult to demonstrate especially in stronger patients. A palpable defect is often appreciated. If the lacertus fibrosus is also

torn, the biceps muscle belly is seen to retract proximally which is often referred to as a reverse Popeye sign (Figure 4). Several clinical tests have been described to confirm the diagnosis.

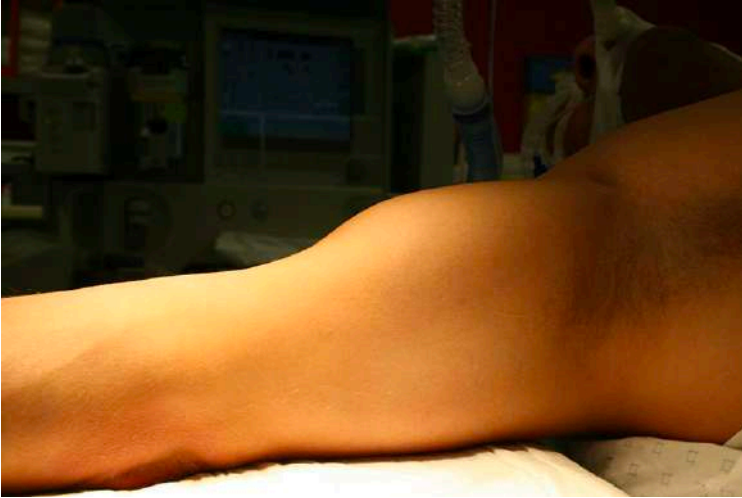

Figure 4: A reverse Popeye sign can be seen in complete distal biceps tendon ruptures.

In complete tears, the cordlike tendon cannot be palpated and sometimes, the biceps stump can be found proximal to the elbow crease. The hook test, described by O'Driscoll, is based on the fact that an attached distal tendon feels like a tight cord in isometric resisted supination (O'Driscoll et al. 2007). To perform this test the patient is asked to abduct the shoulder, actively flex the elbow to 90° and to supinate the forearm. The examiner then uses the index finger to hook the lateral edge of the biceps tendon. With an intact tendon, a finger can be inserted approximately 1 cm beneath the tendon. The test is reported to be 100% sensitive and 100% specific in detecting complete distal biceps tendon ruptures (O'Driscoll, Goncalves et al. 2007). Other tests include the biceps squeeze test, passive rotation test and the biceps crease interval test. Squeezing the muscle belly simulates contraction and in case of an intact tendon the arm will supinate

passively (Ruland et al. 2005). Alternatively, passively rotating the forearm with an intact tendon would cause the muscle belly to move proximally with pronation and distally with passive supination. With the crease interval test, the hypothesis is that complete distal biceps tendon ruptures result in an objectively measurable anatomic landmark (the distance between the antecubital crease of the elbow and the cusp of distal descent of the biceps muscle, or the biceps crease interval), as a result of proximal retraction of the musculotendinous complex. Using a diagnostic threshold of a biceps crease interval greater than 6.0 cm or biceps crease ratio greater than 1.2, the biceps crease interval test had a sensitivity of 96% and a diagnostic accuracy of 93% for complete tears (ElMaraghy et al. 2008). Musculotendinous junction tears, albeit extremely rare, can also present with antecubital pain, ecchymosis, swelling or weakness with elbow flexion and supination (Schamblin et al. 2007).

The clinical findings associated with partial distal biceps tendon ruptures, tendinitis or bicipital bursitis typically include antecubital pain with activity, leading to minor weakness to resisted flexion and supination. These findings can be vague and diagnosis is therefore often delayed or may be missed altogether.

Imaging studies

If doubt still remains, an elbow ultrasound (US) or Magnetic resonance imaging (MRI) can aid in the diagnosis. The accuracy of MRI and US was 86.4% and 45.5% in diagnosis of complete distal biceps tendon rupture, respectively. These findings suggest that MRI is a more accurate imaging modality at correctly identifying distal biceps tendon tear although US is more cost-effective (Lynch et al. 2019). The sensitivity and specificity of an MRI for complete tears determined on small cohorts is reported to be 100% and 82.8% respectively (Festa et al. 2010). The sensitivity for partial tears or other distal biceps tendon pathology is significantly lower (sensitivity 59.1% and specificity 100%) (Festa,

Mulieri et al. 2010, de la Fuente et al. 2018, Fitzgerald et al. 1994, Falchook et al. 1994). In 2004, Giuffrè et al. suggested a new flexion abduction supination view (FABS) to optimally view distal biceps tendon from the musculotendinous junction to its insertion, usually on a single image (in one or, at most, two sections) (Giuffrè et al. 2004). To obtain this view, the patient is positioned prone on MRI table with the shoulder in abduction, the elbow flexed and the forearm supinated. Although this MRI view is commonly used in the daily practice of dedicated elbow surgeons, the sensitivity and specificity are unknown (Figure 5).

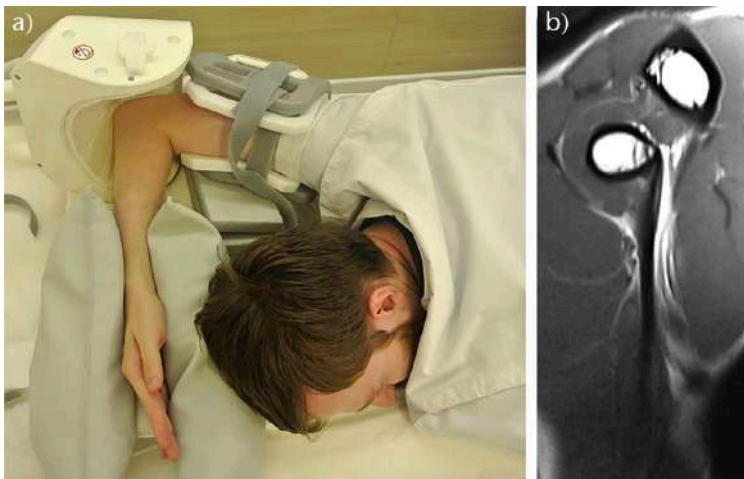


Figure 6: A Flexion-abduction-supination view positioning with shoulder abduction and elbow flexion-supination. B Flexionabduction- supination magnetic resonance imaging view (threedimensional double-echo steady state with water excitation) showing normal distal biceps tendon. The entire tendon can be viewed from the insertion to the musculotendinous junction on a single image.

TREATMENT OF DISTAL BICEPS TENDON INJURY

Partial tears, bicipital bursitis and tendinosis

Partial biceps tendon ruptures were initially treated either conservative (Rokito et al. 1996) or operative (Bourne et al. 1991). Conservative treatment options are generally tried first and consist of a period of rest and avoidance of aggravating activity. They are sometimes combined with brace therapy and steroid injection (Bourne and Morrey 1991, Bain et al. 2008, Hobbs et al. 2009). A recent paper by Bauer and colleagues showed that up to 55.7% of patients who tried a nonoperative treatment ultimately underwent surgery (Bauer et al. 2018). Furthermore, high-need patients as defined by occupation were more likely to report that they recovered better if they underwent surgery as compared with patients who did not undergo surgery (Bauer et al. 2018). Schmidt and colleagues noted that a significant decrease of supination strength was present when the tear was larger than 75% of the footprint (Tomizuka et al. 2021). The initial surgical option was a complete release of the tendon with formal reinsertion (Bourne et al. 1991, Nielson 1987). This technique had similar outcomes as the treatment of complete distal biceps tendon ruptures (Rokito et al. 1996, Bain et al. 2008, Ramsey 1999). Gabel and Nolla suggested that open visualization, debridement and repair of the torn section of the tendon is possible and yields satisfactory results in their case series (Berger et al. 2004). Other authors consider this technique for solitary short head ruptures and evaluation of the partial rupture but to advise former release and repair for degenerative tears (Rokito et al. 1996, Bourne et al. 1991, Ramsey 1999, Bain et al. 2019). One issue of this technique may be that to inspect the radial side of the tendon, it needs to be dissected and retracted (Kelly et al. 2003). This may potentially have a detrimental effect on the already weakened insertion or disturb a tendon that is essentially intact. Bhatia et al. suggested that as the radial side of the tendon and subsequent repair cannot be inspected optimally through an open technique (Bain et al. 2019), minimal tears which do not react to conservative therapy have to be released and formally reinserted which may be

overshooting as a therapy. With the popularization of endoscopic techniques this was also applied to partial distal biceps tendon ruptures (Eames et al. 2006, Vandenberghe et al. 2016, Gregory et al. 2009, Bhatia et al. 2018). The biggest advantage is the ability to evaluate the degree of the tears (Eames et al. 2006). Thus, minimal tears can be treated differently to tears that are more progressed (Vandenberghe et al. 2016). Minimal tears and bicipital bursitis can be treated with debridement under endoscopic visualization. Slightly larger tears can be reinforced with anchor fixation of the torn part of the tendon. There seems to be a tendency to treat tears affecting more than 50% of the tendon with release of the tendon and formal reinsertion.

Acute complete tears

Although patients do not always report a subjective loss of strength (Freeman et al. 2009), a number of biomechanical studies clearly showed a loss in strength and endurance of conservative treatment when compared to surgical repair. Conservative treatment can lead to problems with repetitive and forceful supination activities such as turning a screwdriver (Baker et al. 1985, Meherin et al. 1960). Mechanical testing showed a 40% loss of supination strength, 79% loss of supination endurance, 30% loss of flexion strength and 30% loss of flexion endurance (Morrey et al. 1985). Therefore, non-surgical treatment may be considered in low-demand patients with concerns regarding anesthesia and surgery after discussion of previously mentioned aspects with the patient. Both costs (Feller et al. 2020) and complications are higher when the surgical repair is performed at later stages (Amarasooriya et al. 2020). Early surgical repair is therefore preferred.

Surgical Approach

Surgical repair of the torn DBT can be performed through a single or double incision approach. Both approaches have been extensively described and evaluated. Both provide good clinical results, and each has its own advantages and disadvantages. The 2-incision

technique is performed through a relatively small anterior incision through which the tendon is retrieved, prepared and passed posteriorly to a larger posterior approach. This second approach is used for tendon reinsertion at the anatomical footprint at the radial tuberosity. Most surgeons adopting the 2-incision approach use either bone tunnels or suture anchors. The biggest advantage of the 2-incision is the anatomical reinsertion. A reinsertion at the native reinsertion site has been shown to yield superior supination strength and endurance compared to a non-anatomical reinsertion (Schmidt et al. 2015, Schmidt et al. 2010, Bellringer et al. 2020). Separate anatomical insertion of the short and long head has shown no added benefit compared reinsertion as a single tendon (Schmidt et al. 2019). The 2-incision technique has been shown to have less LACN neuropraxia compared to the single incision technique. Heterotopic ossification (HO) however, remains the major complication of the 2-incision technique. It was postulated that the bone formation might result from damaging the periosteum while lifting the anconeus from the ulna and possibly the interosseous membrane (Failla et al. 1990, Morrey 1993). To prevent symptomatic HO, some authors recommend splitting the extensor carpi ulnaris (ECU) or the extensor digitorum communis (EDC) instead of elevating the anconeus. Care should be taken to remove all bone debris created through burring (Failla, Amadio et al. 1990, Morrey 1993). However, this did not completely avoid symptomatic HO using the 2-incision technique (Bisson et al. 2008). Supination strength may also be influenced by the 2-incision repair as the damage to the supinator muscle due to the posterior incision may decrease postoperative supination strength (Schmidt et al. 2016).

In the single anterior approach, a 2-3 cm incision is made anteriorly through which the tendon is retrieved, prepared and reinserted. This approach decreases the risk of HO but may increase the risk of neurological complications. Multiple fixation methods can be used with the single incision approach. Options include bone tunnels, suture anchors, cortical buttons, interference screws or a combination of interference screws with a

cortical button. The use of the bicortical button construct prohibits an anatomical reinsertion. The technique of placing a button at the far cortex of the radius endangers the PIN. Therefore, a non-anatomical reinsertion is advised. Even with non-anatomical reinsertion, the average distance between the button and the PIN is 11.6mm (Tat et al. 2018). This distance decreases when the tunnel is placed anatomically.

A randomized controlled trial comparing both approaches showed similar results regarding pain, the American Shoulder and Elbow Surgeons (ASES) elbow scores, DASH score, patient-rated elbow evaluation (PREE) score and isometric extension, pronation and supination strength. The double incision approach resulted in higher elbow flexion strength when compared to the single incision approach (104% vs 94%, respectively) (Grewal et al. 2012). A recent systematic review on complications showed an overall complication rate of 25% (Amarasooriya, Bain et al. 2020). This is similar to the results of a systematic review by Watson et al., who showed an overall complication rate of 23,9% of the single-incision approach and 25,7% of the double incision approach. The major complication rate was 4,6% and included a 1.6% rate of posterior interosseous nerve injury; 0.3% median nerve injury; 1.4% re-rupture and 0.1% (n = 4), synostosis. Synostosis occurred only with the double incision approach. Minor complications included stiffness (1.8% in de single incision and 5.7% in de double incision), LACN neuropraxia (11.6% in the single incision and 5.8% in the double incision) (Watson et al. 2014).

Tendon fixation

Multiple fixation methods have been proposed since the transosseous suture technique described by Morrey et al (Morrey, Askew et al. 1985). Biomechanical evidence showed a significantly stronger initial fixation strength of the cortical button and the cortical

button/interference screw construct compared to suture anchor and the interference screw alone (Mazzocca et al. 2007, Idler et al. 2006). Initial fixation strength allows early active motion and loading. This is believed to improve outcome. These studies have also shown a possible problem of gap formation using suture anchors which was not seen with techniques using a bone socket. The addition of an interference screw to the cortical button construct has not resulted in an improved clinical outcome (Caekebeke et al. 2016, Caekebeke et al. 2016). Furthermore, radial osteolysis may pose a problem as this may lead to radial fracture and possible disastrous outcome (Caekebeke et al. 2016, Potapov et al. 2011). Owing to the smaller size of the proximal radius, the risk of fracture through the surgically created bone tunnel for distal biceps tendon repair could be a potential problem. Another important reported complication is rerupture of the repaired distal biceps tendon. Several authors have debated the reason for the occurrence of rerupture after surgical repair of the distal biceps tendon. Although rates of rerupture differ between incisional approach groups, it must be considered that the rate of rerupture can be affected by fixation technique. Cain et al reported 4 cases of rerupture after distal biceps tendon repair with the single-incision suture anchor fixation technique (Cain et al. 2012). Similarly, Citak et al reported 3 cases of rerupture with a single-incision suture fixation as well (Citak et al. 2011). The reruptures were attributed to patient compliance and excessive force across the fresh repair, and all reruptures occurred in the immediate 3-week postoperative period. They recommend protecting the patient for at least 3 weeks before engaging in physical activity. This can possibly be avoided with a strong initial fixation allowing immediate range of motion.

In recent years, the lack of anatomical reinsertion options with the single incision technique sparked the interest for alternative fixation methods. Siebenlist and colleagues proposed a double intramedullar button fixation device (Siebenlist et al. 2015, Siebenlist et al. 2011, Siebenlist et al. 2019). The biomechanical results of this double intramedullar button fixation are comparable to other currently used techniques (Mazzocca, Burton et

al. 2007, Siebenlist et al. 2011). Intramedullary placement of the button allows reinsertion of the distal biceps tendon at its anatomical footprint through a single anterior approach without the risk of PIN injury. Added benefit of the anatomical reinsertion is restoration of the native cam effect of the bicipital tuberosity. The strong initial fixation allows an early active motion. From a patient's perspective, the proposed benefit of this technique includes the restoration of supination strength using a single incision. This technique is, however, an onlay technique comparable to suture anchors. Gap formation has been shown to be a problem in patients with persistent radial sided forearm pain and weakness on provocative testing after distal biceps repair with a seemingly intact repair (Rashid et al. 2016). When gapping is confirmed on FABS MRI a revision repair with an in-bone technique can lead to good results.

REFERENCES

- Eames, M. H., et al. (2007). "Distal biceps tendon anatomy: a cadaveric study." *J Bone Joint Surg Am* 89(5): 1044-1049.
- Athwal, G. S., et al. (2007). "The distal biceps tendon: footprint and relevant clinical anatomy." *J Hand Surg Am* 32(8): 1225-1229.
- Jarrett, C. D., et al. (2012). "Anatomic and biomechanical analysis of the short and long head components of the distal biceps tendon." *J Shoulder Elbow Surg* 21(7): 942-948.
- Schmidt, C. C., et al. (2015). "The Importance of Preserving the Radial Tuberosity During Distal Biceps Repair." *J Bone Joint Surg Am* 97(24): 2014-2023.
- Schmidt, C. C., et al. (2010). "The effect of biceps reattachment site." *J Shoulder Elbow Surg* 19(8): 1157-1165.
- Bhatia, D. N., et al. (2017). "Cadaveric Study of Insertional Anatomy of Distal Biceps Tendon and its Relationship to the Dynamic Proximal Radioulnar Space." *J Hand Surg Am* 42(1): e15-e23.
- Miyamoto, R. G., et al. (2010). "Distal biceps tendon injuries." *J Bone Joint Surg Am* 92(11): 2128-2138.
- Landa, J., et al. (2009). "The effect of repair of the lacertus fibrosus on distal biceps tendon repairs: a biomechanical, functional, and anatomic study." *Am J Sports Med* 37(1): 120-123.
- Seiler, J. G., 3rd, et al. (1995). "The distal biceps tendon. Two potential mechanisms involved in its rupture: arterial supply and mechanical impingement." *J Shoulder Elbow Surg* 4(3): 149-156.

Zeltser, D. W. and R. J. Strauch (2016). "Vascular anatomy relevant to distal biceps tendon repair." *J Shoulder Elbow Surg* 25(2): 283-288.

Kelly, M. P., et al. (2015). "Distal Biceps Tendon Ruptures: An Epidemiological Analysis Using a Large Population Database." *Am J Sports Med* 43(8): 2012-2017.

Safran, M. R. and S. M. Graham (2002). "Distal biceps tendon ruptures: incidence, demographics, and the effect of smoking." *Clin Orthop Relat Res*(404): 275-283.

Green, J. B., et al. (2012). "Bilateral distal biceps tendon ruptures." *J Hand Surg Am* 37(1): 120-123.

Jockel, C. R., et al. (2010). "Distal biceps tendon tears in women." *J Shoulder Elbow Surg* 19(5): 645-650.

Del Buono, A., et al. (2011). "Tendinopathy and inflammation: some truths." *Int J Immunopathol Pharmacol*. 24: 45-50.

Laseter, J. T. and J. A. Russell (1991). "Anabolic steroid-induced tendon pathology: a review of the literature." *Med Sci Sports Exerc* 23(1): 1-3.

Ray, R. D., et al. (1951). "Rotation of the forearm; an experimental study of pronation and supination." *J Bone Joint Surg Am* 33-A(4): 993-996.

Hilgersom, N. F. J., et al. (2021). "Greater radial tuberosity size is associated with distal biceps tendon rupture: a quantitative 3-D CT case-control study." *Knee Surg Sports Traumatol Arthrosc* 29(12): 4075-4081.

Kodde, I. F., et al. (2016). "The Size of the Radial Tuberosity is Not Related to the Occurrence of Distal Biceps Tendon Ruptures: A Case-Control Study." *Open Orthop J* 10: 1-6.

Rausch, V., et al. (2020). "Pressure Distribution to the Distal Biceps Tendon at the Radial Tuberosity: A Biomechanical Study." *J Hand Surg Am* 45(8): 776 e771-776 e779.

O'Driscoll, S. W., et al. (2007). "The hook test for distal biceps tendon avulsion." *Am J Sports Med* 35(11): 1865-1869.

Ruland, R. T., et al. (2005). "The biceps squeeze test for diagnosis of distal biceps tendon ruptures." *Clin Orthop Relat Res*(437): 128-131.

ElMaraghy, A., et al. (2008). "The biceps crease interval for diagnosing complete distal biceps tendon ruptures." *Clin Orthop Relat Res* 466(9): 2255-2262.

Schamblin, M. L. and M. R. Safran (2007). "Injury of the distal biceps at the musculotendinous junction." *J Shoulder Elbow Surg* 16(2): 208-212.

Lynch, J., et al. (2019). "Magnetic resonance imaging versus ultrasound in diagnosis of distal biceps tendon avulsion." *Orthop Traumatol Surg Res* 105(5): 861-866.

Festa, A., et al. (2010). "Effectiveness of magnetic resonance imaging in detecting partial and complete distal biceps tendon rupture." *J Hand Surg Am* 35(1): 77-83.

de la Fuente, J., et al. (2018). "Ultrasound classification of traumatic distal biceps brachii tendon injuries." *Skeletal Radiol* 47(4): 519-532.

Fitzgerald, S. W., et al. (1994). "Distal biceps tendon injury: MR imaging diagnosis." *Radiology* 191(1): 203-206.

Falchhook, F. S., et al. (1994). "Rupture of the distal biceps tendon: evaluation with MR imaging." *Radiology* 190(3): 659-663.

Giuffrè, B. M. and M. J. Moss (2004). "Optimal positioning for MRI of the distal biceps brachii tendon: flexed abducted supinated view." *AJR Am J Roentgenol* 182(4): 944-946.

Freeman, C. R., et al. (2009). "Nonoperative treatment of distal biceps tendon ruptures compared with a historical control group." *J Bone Joint Surg Am* 91(10): 2329-2334.

Baker, B. E. and D. Bierwagen (1985). "Rupture of the distal tendon of the biceps brachii. Operative versus non-operative treatment." *J Bone Joint Surg Am* 67(3): 414-417.

Meherin, J. M. and K. S. Kilgore (1960). "The treatment of the distal biceps brachii tendon." *Am J Surg* 99: 636-640.

Morrey, B. F., et al. (1985). "Rupture of the distal tendon of the biceps brachii. A biomechanical study." *J Bone Joint Surg Am* 67(3): 418-421.

Feller, R., et al. (2020). "Evaluation of factors influencing surgical treatment costs for distal biceps rupture." *J Shoulder Elbow Surg* 29(6): e229-e237.

Amarasooriya, M., et al. (2020). "Complications After Distal Biceps Tendon Repair: A Systematic Review." *Am J Sports Med* 48(12): 3103-3111.

Bellringer, S. F., et al. (2020). "Biomechanical comparison of transosseous cortical button and Footprint repair techniques for acute distal biceps tendon ruptures." *Shoulder Elbow* 12(1): 54-62.

Schmidt, C. C., et al. (2019). "The effect of tendon rotation on distal biceps repair." *JSES Open Access* 3(3): 225-231.

Failla, J. M., et al. (1990). "Proximal radioulnar synostosis after repair of distal biceps brachii rupture by the two-incision technique. Report of four cases." *Clin Orthop Relat Res*(253): 133-136.

Morrey, B. F. (1993). Tendon injuries around the elbow. *The elbow and its disorders*. B. F. Morrey and J. Sanchez-Sotelo, Saunders: 492-504.

Bisson, L., et al. (2008). "Complications associated with repair of a distal biceps rupture using the modified two-incision technique." *J Shoulder Elbow Surg* 17(1 Suppl): 67S-71S.

Schmidt, C. C., et al. (2016). "Factors That Determine Supination Strength Following Distal Biceps Repair." *J Bone Joint Surg Am* 98(14): 1153-1160.

Tat, J., et al. (2018). "Distal Biceps Repair With Flexible Instrumentation and Risk of Posterior Interosseous Nerve Injury: A Cadaveric Analysis." *Orthop J Sports Med* 6(11): 2325967118810523.

Grewal, R., et al. (2012). "Single versus double-incision technique for the repair of acute distal biceps tendon ruptures: a randomized clinical trial." *J Bone Joint Surg Am* 94(13): 1166-1174.

Watson, J. N., et al. (2014). "Repair techniques for acute distal biceps tendon ruptures: a systematic review." *J Bone Joint Surg Am* 96(24): 2086-2090.

Mazzocca, A. D., et al. (2007). "Biomechanical evaluation of 4 techniques of distal biceps brachii tendon repair." *Am J Sports Med* 35(2): 252-258.

Idler, C. S., et al. (2006). "Distal biceps tendon repair: a biomechanical comparison of intact tendon and 2 repair techniques." *Am J Sports Med* 34(6): 968-974.

Caekebeke, P., et al. (2016). "Distal biceps tendon repair: comparison of clinical and radiological outcome between bio-absorbable and non-absorbable screws." *J Shoulder Elbow Surg*: accepted for publication.

Caekebeke, P., et al. (2016). "Radiological and Clinical Evaluation of the Transosseous Cortical Button Technique in Distal Biceps Tendon Repair." *J Hand Surg Am* 41(12): e447-e452.

Potapov, A., et al. (2011). "Progressive osteolysis of the radius after distal biceps tendon repair with the bioabsorbable screw." *J Shoulder Elbow Surg* 20(5): 819-826.

Cain, R. A., et al. (2012). "Complications following distal biceps repair." *J Hand Surg Am* 37(10): 2112-2117.

Citak, M., et al. (2011). "Surgical repair of the distal biceps brachii tendon: a comparative study of three surgical fixation techniques." *Knee Surg Sports Traumatol Arthrosc* 19(11): 1936-1941.

Siebenlist, S., et al. (2015). "Double intramedullary cortical button versus suture anchors for distal biceps tendon repair: a biomechanical comparison." *Knee Surg Sports Traumatol Arthrosc* 23(3): 926-933.

Siebenlist, S., et al. (2011). "The double intramedullary cortical button fixation for distal biceps tendon repair." *Knee Surg Sports Traumatol Arthrosc* 19(11): 1925-1929.

Siebenlist, S., et al. (2019). "Intramedullary Cortical Button Repair for Distal Biceps Tendon Rupture: A Single-Center Experience." *J Hand Surg Am* 44(5): 418 e411-418 e417.

Siebenlist, S., et al. (2011). "Biomechanical in vitro validation of intramedullary cortical button fixation for distal biceps tendon repair: a new technique." *Am J Sports Med* 39(8): 1762-1768.

Rausch, V., et al. (2020). "The Radioulnar Distance at the Level of the Radial Tuberosity." *Clin Anat* 33(5): 661-666.

Rokito, A. S., et al. (1996). "Partial rupture of the distal biceps tendon." *J Shoulder Elbow Surg* 5(1): 73-75.

- Bourne, M. H. and B. F. Morrey (1991). "Partial rupture of the distal biceps tendon." *Clin Orthop Relat Res*(271): 143-148.
- Bain, G. I., et al. (2008). "Treatment of partial distal biceps tendon tears." *Sports Med Arthrosc* 16(3): 154-161.
- Hobbs, M. C., et al. (2009). "Distal biceps tendinosis: evidence-based review." *J Hand Surg Am* 34(6): 1124-1126.
- Bauer, T. M., et al. (2018). "Is nonoperative management of partial distal biceps tears really successful?" *J Shoulder Elbow Surg* 27(4): 720-725.
- Tomizuka, Y., et al. (2021). "Partial Distal Biceps Avulsion Results in a Significant Loss of Supination Force." *J Bone Joint Surg Am* 103(9): 812-819.
- Nielson, K. (1987). "Partial rupture of the distal biceps brachii tendon: a case report." *Acta Orthop Scand* 58: 287-288.
- Ramsey, M. L. (1999). "Distal biceps tendon injuries: diagnosis and management." *J Am Acad Orthop Surg* 7(3): 199-207.
- Berger, R. A. and A. P. C. Weiss (2004). *Hand Surgery*, Lippincott Williams & Wilkins.
- Bain, G., et al. (2019). *Surgical Techniques for Trauma and Sports Related Injuries of the Elbow*, Springer Berlin Heidelberg.
- Eames, M. H. and G. I. Bain (2006). "Distal biceps tendon endoscopy and anterior elbow arthroscopy portal." *Tech Shoulder Elbow Surg*(7): 139-142.
- Vandenbergh, M. and R. van Riet (2016). "Distal biceps ruptures: open and endoscopic techniques." *Curr Rev Musculoskelet Med* 9(2): 215-223.
- Gregory, T., et al. (2009). "Repair of distal biceps tendon rupture using a suture anchor: description of a new endoscopic procedure." *Am J Sports Med* 37(3): 506-511.
- Bhatia, D. N. and V. Kandhari (2018). "Analysis of technical feasibility and neurovascular safety of endoscopic distal biceps repair: a cadaveric study." *J Shoulder Elbow Surg* 27(11): 2057-2067.
- Rashid, A., et al. (2016). "Failure of distal biceps repair by gapping." *Shoulder Elbow* 8(3): 192-196.

OBJECTIVES AND RESEARCH QUESTIONS

OBJECTIVES AND RESEARCH QUESTIONS

Motivation of the thesis

The reason of present thesis can be found in the daily practice. Throughout my training and current practice, I have encountered several cases where current diagnostic tools and treatment options for distal biceps tendon pathology remained lacking. Aspects that stood out where the diagnostic delay of partial distal biceps tendon and the inability to safely and strongly reinsert the distal biceps tendon anatomically through a single incision technique. The journey started when we evaluated the added value of interference screws in distal biceps tendon repair. A technique that was deemed generally accepted showed to have inherent risks that could be avoided. This sparked the critical evaluation of existing techniques and the ultimate goal of this thesis that is stated below.

THE GOAL OF THIS THESIS IS TO IDENTIFY AND IMPROVE
SHORTCOMINGS IN CURRENT DIAGNOSIS AND TREATMENT STRATEGIES
FOR ACUTE COMPLETE AND PARTIAL DISTAL BICEPS TENDON
RUPTURES, BICIPITAL BURSTITIS AND TENDINOSIS.

PART 1: IMPROVEMENT AND EVALUATION OF DIAGNOSTIC TOOLS FOR DISTAL BICEPS TENDON PATHOLOGY

Objective 1: Can we improve the clinical diagnosis of partial distal biceps tendon ruptures and bicipital bursitis and tendinosis?

Compared to complete distal biceps tendon ruptures, the clinical diagnosis of partial distal biceps tendon ruptures and bicipital bursitis and tendinosis is often difficult. This may lead to diagnostic delay. In recent years two tests have been proposed to aid in the diagnosis of biceps pathology other than a complete tear. However, the accuracy of these tests was based on very small cohorts and the effect of combining these tests on diagnostic accuracy has not been examined.

- **Research question 1:** Can we develop and evaluate a specific test for partial distal biceps ruptures, bicipital bursitis or tendinosis?
- **Research question 2:** Which test yields the highest accuracy and can we improve diagnostic accuracy by combining tests in a clinical setting?

Objective 2: What is the accuracy of current imaging studies for distal biceps tendon pathology?

MRI sensitivity is high for complete tears but specificity is sparsely evaluated and based on small cohorts. The prevalence of asymptomatic signal changes, as seen for example in tendons around the shoulder, is unknown. This prevalence may influence the negative predictive value of MRI as a diagnostic tool for distal biceps tendon ruptures. A low prevalence would empower MRI in a research setting as reference standard to evaluate clinical investigations. FABS view MRI has been proposed to improve diagnosis of partial distal biceps tendon ruptures, bicipital bursitis and tendinosis. However, to date, no evaluation has been performed on the sensitivity, specificity and accuracy of the FABS view MRI.

- **Research question 3:** What is the prevalence of biceps signal changes on MRI in the asymptomatic population?
- **Research question 4:** Does the FABS view MRI yield a higher sensitivity and specificity compared to standard MRI for partial distal biceps tendon ruptures, bicipital bursitis and tendinosis. Is the FABS view MRI more accurate in quantifying a partial tear compared to a standard MRI?

PART 2: IMPROVEMENT AND EVALUATION OF TREATMENT OPTIONS FOR DISTAL BICEPS TENDON PATHOLOGY

Objective 3: Is the current treatment of partial distal biceps tendon ruptures and bicipital bursitis and tendinosis safe?

Endoscopy has been proposed to evaluate and treat bicipital bursitis, tendinosis and low-grade partial distal biceps tendon tears. Both a single-portal and a two-portal technique have been described. Clinical results of single-portal endoscopic distal biceps tendon repair have been shown to be comparable to open techniques in small series. No evaluation of safety of this technique has been performed.

- **Research question 5:** Is the single incision distal biceps endoscopy safe for surrounding anatomic structures?

Objective 4: Can we improve the current treatment options for complete distal biceps tendon ruptures?

The single-incision approach has gained popularity in recent years. Low risk of heterotopic ossification and strong tendon fixation options allow early range of motion are advantages while non-anatomic fixation and risk of iatrogenic posterior interosseous nerve damage are disadvantages. Intramedullary fixation has been postulated as a possible solution for these problems. However, current fixation options are essentially

onlay techniques which have a higher risk of gap formation. The ideal fixation is performed through a single-incision approach, has a high initial load to failure and allows an anatomic repair with no risk of PIN damage and an intra-osseous tendon position preventing gap formation.

- **Research question 6:** What are the anatomic factors surrounding the radial tuberosity that have to be considered to design an intramedullar fixation device?
- **Research question 7:** Does the intramedullar fixation device have a similar biomechanical profile as current fixation devices?
- **Research question 8:** What are the clinical outcomes of the intramedullar fixation device? Can we restore native supination strength?

PART 1: IMPROVEMENT AND EVALUATION OF DIAGNOSTIC TOOLS FOR DISTAL BICEPS TENDON PATHOLOGY

Diagnosis of complete distal biceps tendon ruptures is relatively straightforward. Various clinical tests have been described. Ultrasound and MRI investigation can confirm the diagnosis but are often not necessary. Diagnosis of partial distal biceps tendon ruptures and bicipital bursitis and tendinosis is often more difficult. There is a paucity of clinical tests and although specific MRI views have been described, not much is known of the accuracy of the imaging studies of these pathologies.

CHAPTER 1

DEVELOPMENT OF A SPECIFIC TEST FOR PARTIAL DISTAL BICEPS TENDON RUPTURES, BICIPITAL BURSITIS AND TENDINOSIS

DEVELOPMENT OF A SPECIFIC TEST FOR PARTIAL DISTAL BICEPS TENDON RUPTURES, BICIPITAL BURSITIS AND TENDINOSIS

SUMMARY

Symptoms of partial distal biceps tendon ruptures, bicipital bursitis and tendinosis are vague. The absence of a specific and sensitive test to detect distal biceps tendon pathology other than a full tear, there is often a significant delay in diagnosis, or the diagnosis may be missed altogether. We developed a specific test for these pathologies: the biceps provocation test. The BPT is a 2-part test. The elbow is flexed to 70° with the forearm supinated. The examiner's hands are placed on the patient's forearm and the patient is asked to flex the elbow against resistance (BPTs). The forearm is then pronated and the test is repeated (BPTp). Pain is documented for both supination and pronation using a visual analog scale from 0 to 10. The test is positive when the patient indicates an increase in pain with BPTp compared with BPTs. We evaluated the sensitivity and specificity of this clinical test in 30 patients with suspected distal biceps tendon pathology and 30 patients with another elbow pathology. Patients with a complete tear were excluded. Sensitivity and specificity were both 100% in this small group of 60 patients, with a high prevalence of distal biceps tendon pathology. The BPT appears to be highly accurate in the clinical diagnosis of distal biceps tendon pathology.

Distal Biceps Provocation Test

Pieter Caekebeke¹, Eva Schenkels², Simon N. Bell^{3,4} and Roger van Riet^{2,5,6}

¹Department of Orthopedic Surgery and Traumatology, Ziekenhuis Oost-Limburg, Genk, Belgium

²Department of Orthopedic Surgery, AZ Monica, Antwerp

³Melbourne Shoulder and Elbow Centre, Melbourne, Victoria, Australia.

⁴Department of Surgery, Monash Medical Centre, Monash University, Melbourne, Victoria, Australia.

⁵Department of Orthopedic Surgery, University Hospital Antwerp, Edegem, Belgium

⁶Orthopaedic Specialists, Harley Street Specialist Hospital, 18-22 Queen Anne St, London W1G 8HU, United Kingdom

Journal of Hand Surgery (American volume). 2021, 46(8): 710.e1-710.e4.

INTRODUCTION

The diagnosis of a complete rupture of the distal biceps tendon is mainly based on clinical examination. A variety of clinical tests have been described (O'Driscoll et al. 2007, Devereaux et al. 2013, Metzman et al. 2015). Ultrasound or magnetic resonance imaging (MRI) can be used to confirm the diagnosis, but are usually not needed (Festa et al. 2010, de la Fuente et al. 2018). Clinical exam and advanced imaging are less conclusive in patients with a partial tear, symptomatic degenerative changes of the tendon or bicipital bursitis. Patients often complain of pain in the antecubital region, exacerbated with activity. Biceps strength is usually good and resistance tests may be negative. Supination against resistance can be painful for a number of reasons, such as a radiocapitellar plica or arthritis or compression of the posterior interosseous nerve because of compression by the supinator muscle. Weakness or pain with resisted flexion is often not present because the brachialis muscle is the strongest elbow flexor and palpation of the insertion is often not possible. Standard MRI is not sensitive to detect these lesions (Festa, Mulieri et al. 2010). Sensitivity is greatly improved with the use of the 'flexion abduction supination (FABS) view' (Giuffre et al. 2004) but clinical suspicion is needed for the treating physician to

order these specific views. In the absence of a specific and sensitive test to detect distal biceps tendon pathology other than a full tear, there is often a significant delay in diagnosis, or the diagnosis may be missed altogether. The purpose of this study was to determine the sensitivity and specificity of the distal biceps provocation test for distal biceps tendon pathology other than complete tears.

MATERIAL AND METHODS

After institutional review board approval, sixty patients were included in this study. Patients included presented to our out-patient clinic, dedicated to elbow pathology. Patients were examined clinically, and the new Antwerp Biceps Test (BPT) was performed in all patients as a standard part of the exam. The BPT was performed in a blinded fashion. In other words, the examiner did not see any imaging exams or referral letters before the clinical exam and the BPT. A FABS view MRI was ordered in thirty patients with a positive BPT and, as a control, in thirty consecutive patients with a negative BPT, where an MRI was indicated for elbow pathology. Patients in the control group were also scanned in the FABS position. Patients with a complete distal biceps tendon tear at clinical exam and ultrasound imaging were excluded. Radiologists were blinded to the clinical findings and history. Biceps tendon pathology was confirmed by FABS view MRI. The BPT is a two-part test. (Figure 1) The patient is standing, with the elbow supported by the examiner and flexed at seventy degrees. The examiner's hands are placed on the patient's forearm and the patient is asked to flex the elbow against resistance with the forearm supinated (BPTs). Care is taken not to place the hands on the hand or wrist as resisted wrist flexion might elicit pain in other elbow pathologies. (Figure 1a) The forearm is then pronated, and the test is repeated (BPTp). (Figure 1b) Pain is documented for both positions, using a visual analogue scale from 0 to 10. The test is positive when the patient indicates any increase in pain with BPTp when compared to BPTs. Patients usually also indicate a decrease in strength due to pain inhibition. Based

on a desired significance level of 0.05, a Cohen's *d* of 0.8 and a required power of 0.8, we calculated the sample size for each of the equal size groups to be 26.

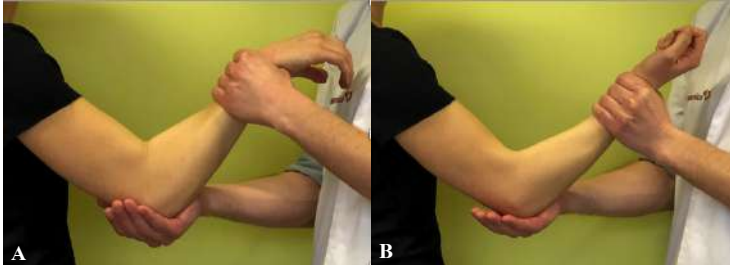

Figure 1. The BPT is a two-part test. **A** The patient is standing, with the elbow supported by the examiner and flexed to seventy degrees. The examiner's hands are placed on the patient's forearm and the patient is asked to flex the elbow against resistance with the forearm supinated (BPTs). (Copyright MoRe Foundation) **B** The forearm is then pronated, and the test is repeated (BPTp). Care is taken not to place the hands on the hand or wrist as resisted wrist flexion or extension might elicit pain in other elbow pathologies. (Copyright MoRe Foundation)

RESULTS

The average age in the distal biceps tendon pathology group was 52 years (range 35-65 years). Twenty-four patients were male and six were females. The dominant arm was involved in twenty patients. In twenty-four out of the thirty patients (80%) a partial distal biceps tendon rupture was confirmed on a FABS view MRI. In the other six patients (20%) FABS view MRI showed degenerative changes without partial tearing.

In the control group the average age was 49 years (range 27-75 years). Twenty patients were male and ten were female. The dominant arm was involved in nineteen patients. Diagnoses were made by clinical examination and confirmed by FABS view MRI. Specific care was taken to rule out distal biceps tendon pathology on these images. Seventeen (57%) patients were diagnosed with lateral epicondylitis and seven (23%) with medial epicondylitis. There were two (7%) cases of posterior interosseous nerve compression and one (3%) with ulnar nerve compression. Nerve compression syndromes were all confirmed using EMG. One patient (3%) was diagnosed with a symptomatic

radio-humeral plica and one with radiocapitellar arthritis (3%). One patient had non-specific elbow and forearm pain due to fibromyalgia (3%). There were no clear differences between the biceps and non-biceps group with respect to age and involvement of the dominant elbow. The biceps provocation test was positive in all patients with distal biceps tendon pathology. BPTp was more painful than BPTs in all patients. The average VAS score BPTs was 2 out of 10 (range 0-7). This increased to an average VAS of 7 out of 10 for the BPTp (range 4-10). In the control group BPTp and BPTs were rated as equally painful by 27 patients and BPTp was less painful than BPTs in 3. VAS score for BPTs ranged from 0 to 5 and from 0 to 3 for BPTp. Sensitivity and specificity of the BPT were both 100% in our series of sixty patients.

DISCUSSION

Clinical examination is usually sufficient to confidently diagnose complete distal biceps ruptures. Various clinical tests, such as the hook test, the biceps crease interval test and the biceps squeeze test have been described (O'Driscoll, Goncalves et al. 2007, Devereaux and ElMaraghy 2013). The sensitivity and specificity of these tests is excellent (O'Driscoll, Goncalves et al. 2007, Devereaux and ElMaraghy 2013). MRI has a sensitivity (85%) and specificity (92%) respectively, in the diagnosis of complete distal biceps tendon ruptures (Festa, Mulieri et al. 2010, Giuffre and Moss 2004). In contrast, besides vague antecubital pain often exacerbated by resisted flexion or supination, no clinical tests have been described to accurately diagnose partial distal biceps tendon ruptures, distal biceps tendon bursitis or tendinosis. Conventional elbow MRI can be useful in diagnosing this type of pathology, but sensitivity is low (sensitivity 59,1% and specificity 100%) (Festa, Mulieri et al. 2010). A FABS view MRI greatly improves sensitivity and specificity to detect this pathology (Giuffre and Moss 2004), but these are generally only requested based on the patient's history and clinical suspicion. This may lead to delayed, or even missed, diagnosis of distal biceps tendon pathology. In our daily

practice the BPT is included in our standard clinical elbow investigation. The distal biceps tendon wraps around the radial tuberosity when the arm is pronated, and the tendon is stretched and compressed when the biceps is activated. (Figures 2 and 3) We believe that the pathophysiology is an impingement of the inflamed, thickened or ruptured tissue between the tendon and the radius. This tissue is compressed onto the radius with pronation. Flexion against resistance will then elicit pain. This may explain the increase in pain when the biceps is tested in pronation. The current study shows that the BPT can be used in the clinical setting for the diagnosis of partial distal biceps tendon ruptures, tendinosis, degenerative changes or bursitis.

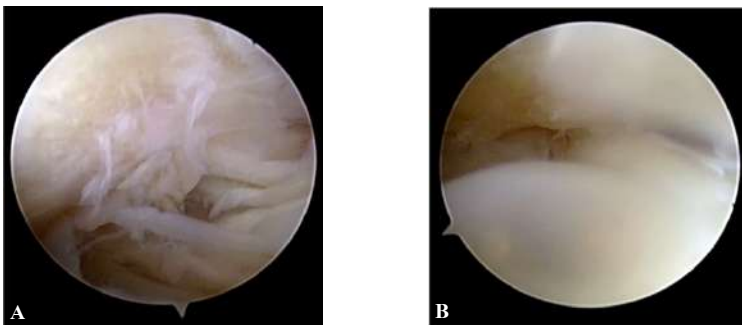


Figure 2. Endoscopic view of the biceps tendon in a patient with a partial tear. **A** The tear is clearly visible in supination. (Copyright MoRe Foundation) **B** The pathological tissue is compressed against the tuberosity when the forearm is pronated, and the tear is no longer visible. (Copyright MoRe Foundation)

There are some limitations to this study. Firstly, this is a small cohort. Ascertainment bias may be present as patients were recruited from a highly specialized elbow practice where the surgeon may be more suspicious with regards to distal biceps tendon pathology. Results may have been different if the BPT was used in a general orthopedic setting or emergency room. Furthermore, in the control group the majority of patients had medial or lateral epicondylitis. This, and the fact that patients with a positive BPT were automatically included in the study, may have introduced some selection bias. It is

highly unlikely that a sensitivity and specificity of 100% would have been found if these weaknesses had been addressed but this would probably not change the conclusion that the BPT is an addition to the tests available to examine a patient's elbow. Finally, the biggest weakness is that FABS view MRI, used as the reference in this study is not 100% sensitive and therefore it would be possible that patients in the control group had a false negative test. In the group with a positive BPT, seventeen patients (57%) eventually underwent endoscopic surgery at an average 6 months of symptoms (range 2-13 months) (Caekebeke et al. 2018). Biceps tendon pathology was confirmed in all seventeen. Both the sensitivity and the specificity of our test were excellent, but this will likely be influenced by the limitations listed. False positive and false positive tests may occur once the test will be used more frequently and in patients with pathologies that were not included in this study.

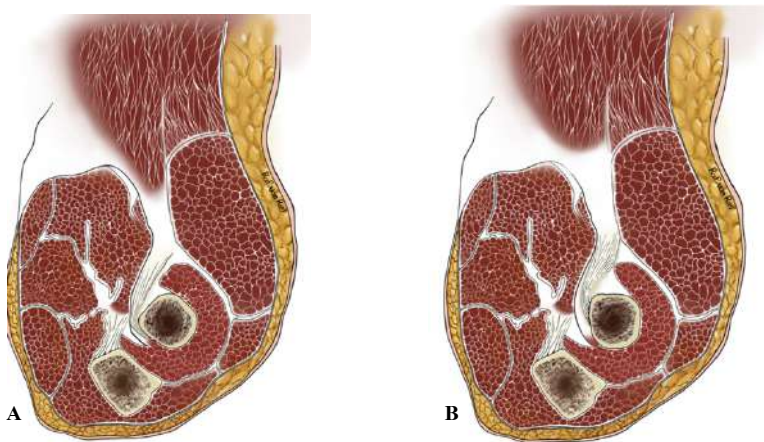


Figure 3. **A** Position of the biceps tendon with the forearm supinated. **B** Position of the biceps tendon with the forearm pronated. As the distal biceps tendon wraps around the radial tuberosity when the arm is pronated, the tendon is stretched and compressed when the biceps is activated. (Copyright MoRe Foundation)

CONCLUSION

The BPT appears to be highly accurate in the clinical diagnosis of distal biceps tendon pathology.

ACKNOWLEDGEMENT

We would like to thank Raf van Riet for the excellent illustrations.

REFERENCES

- O'Driscoll, S. W., et al. (2007). "The hook test for distal biceps tendon avulsion." *Am J Sports Med* **35**(11): 1865-1869.
- Devereaux, M. W. and A. W. ElMaraghy (2013). "Improving the rapid and reliable diagnosis of complete distal biceps tendon rupture: a nuanced approach to the clinical examination." *Am J Sports Med* **41**(9): 1998-2004.
- Metzman, L. S. and K. A. Tivener (2015). "The Supination-Pronation Test for Distal Biceps Tendon Rupture." *Am J Orthop (Belle Mead NJ)* **44**(10): E361-364.
- Festa, A., et al. (2010). "Effectiveness of magnetic resonance imaging in detecting partial and complete distal biceps tendon rupture." *J Hand Surg Am* **35**(1): 77-83.
- de la Fuente, J., et al. (2018). "Ultrasound classification of traumatic distal biceps brachii tendon injuries." *Skeletal Radiol* **47**(4): 519-532.
- Giuffre, B. M. and M. J. Moss (2004). "Optimal positioning for MRI of the distal biceps brachii tendon: flexed abducted supinated view." *AJR Am J Roentgenol* **182**(4): 944-946.
- Caekebeke, P., et al. (2018). "Distal Biceps Endoscopy at the Elbow." *Techniques in shoulder and elbow surgery* **19**(2): 93-94.

CHAPTER 2

EVALUATION OF CLINICAL TESTS FOR PARTIAL DISTAL BICEPS TENDON RUPTURES, BICIPITAL BURSITIS AND TENDINOSIS

EVALUATION OF CLINICAL TESTS FOR PARTIAL DISTAL BICEPS TENDON RUPTURES, BICIPITAL BURSTITIS AND TENDINOSIS

SUMMARY

The clinical diagnosis of partial distal biceps tendon ruptures or tendinosis can be challenging. Three clinical tests have been described to aid in an accurate and timely diagnosis: the biceps provocation test, the TILT sign and the resisted hook test. For present study, two dedicated elbow surgeons included 20 consecutive patients suspected of distal biceps tendon pathology each. Patients with a complete distal biceps tendon tear were excluded. As a control, the same number of consecutive patients with various elbow pathologies other than distal biceps tendon problems were included. All three tests were performed in both control and patients with suspected biceps tendon pathology. FABS view MRI and/or surgical exploration was performed both groups. The findings of the clinical tests were determined before MRI and other technical investigations were analyzed. Our study showed that the biceps provocation test yielded a higher accuracy compared to the resisted hook test and TILT sign. When combining the biceps provocation test and the resisted hook test, the sensitivity increases to 98%. We advise integration of this test in the daily practice to minimize delay of diagnosis of partial distal biceps tendon ruptures, distal biceps tendon bursitis or tendinosis. FABS view MRI is still advised to distinguish between a partial biceps tendon rupture and a tendinosis or bursitis at the distal biceps tendon insertion as this may influence further treatment.

Evaluation of clinical tests for partial distal biceps tendon ruptures and tendinitis

Pieter Caekebeke¹, Uroš Meglič², Michel P.J. van den Bekerom^{3,4} and Roger van Riet^{5,6,7}

¹Department of Orthopedic Surgery and Traumatology, Ziekenhuis Oost-Limburg, Genk, Belgium

²University Medical Centre Ljubljana, department of Orthopaedic surgery, Zaloska cesta 9, 1000 Ljubljana, Slovenia

³Department of Human Movement Sciences, Amsterdam Movement Sciences, Vrije Universiteit Amsterdam, Amsterdam, The Netherlands

⁴OLVG, Department of orthopedic surgery, Oosterpark 9, 1090 HM Amsterdam, the Netherlands

⁵Department of Orthopedic Surgery, AZ Monica, Antwerp

⁶Department of Orthopedic Surgery, University Hospital Antwerp, Edegem, Belgium

⁷Orthopaedic Specialists, Harley Street Specialist Hospital, 18-22 Queen Anne St, London W1G 8HU, United Kingdom

Journal of Shoulder and Elbow surgery. 2021, 0;S1058-2746(21)00763-1

INTRODUCTION

Unlike the diagnosis of complete distal biceps tendon ruptures (Devereaux et al. 2013, O'Driscoll et al. 2007), the clinical diagnosis of partial distal biceps tendon tears, tendinosis or bicipital bursitis remains to be difficult. Both the clinical exam and advanced imaging are less conclusive. Patients often complain of pain in the antecubital region, exacerbated with activity. Biceps strength is usually well maintained and resistance tests may be negative. Magnetic resonance imaging (MRI) is often used (Festa et al. 2010). It is recommended to use the 'flexion abduction supination (FABS) view' (Schenkels et al. 2020, Giuffrè et al. 2004) to better detect distal biceps tendon pathology. Schenkels et al. reported a sensitivity of 76% for standard MRI and 84% for the FABS view (Schenkels, Caekebeke et al. 2020, Giuffrè and Moss 2004). The absence of specific and sensitive clinical tests for these pathologies may lead to a delay in diagnosis, or the diagnosis may be missed altogether. In recent years three different clinical tests;

the biceps provocation test, TILT sign and resisted hook test (Shim et al. 2018, Caekebeke et al. 2021, Pallante et al. 2019) have been proposed to aid in an accurate and timely diagnosis. However, not much is known about the sensitivity, specificity and inter-rater reliability, as available evidence is based on small groups or only case based. Furthermore, these tests have not been compared together in the same patient group. The purpose of this study was to review the sensitivity, specificity and accuracy of three clinical tests for partial distal biceps tendon ruptures, tendinosis or bicipital bursitis.

MATERIAL AND METHODS

Clinical tests

Three clinical tests were included in the present study. The biceps provocation test (Caekebeke, Schenkels et al. 2021) and the TILT sign (Shim and Strauch 2018) were published in 2021 and 2018 respectively. The resisted hook test was first published in 2019 as an aid to examine biceps tendon integrity after biceps tendon repair. In 2021 it was published to aid diagnosis partial biceps tendon pathology (Pallante and O'Driscoll 2019, Harasymczuk et al. 2020).

The biceps provocation test, published in 2021, is a two-part test. (Figure 1) The patient is standing, with the elbow supported by the examiner and flexed at seventy degrees. The examiner's hand is placed on the patient's forearm, with the other hand supporting the elbow, and the patient is asked to flex the elbow against resistance with the forearm supinated (ABTs). Care is taken not to place the hand on the hand or wrist as resisted wrist flexion or extension will elicit pain in other elbow pathologies. (Figure 1a) The forearm is then pronated and the test is repeated (ABTp). (Figure 1b) Pain is documented for both positions, using a visual analogue scale from 0 to 10. The test is positive when the patient reports an increase in pain with ABTp when compared to ABTs. Patients usually also indicate a decrease in strength due to pain inhibition (Caekebeke, Schenkels et al. 2021).

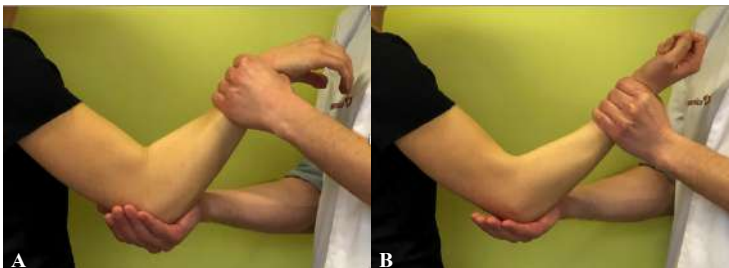

Figure 1. The BPT is a two-part test. **A** The patient is standing, with the elbow supported by the examiner and flexed to seventy degrees. The examiner's hands are placed on the patient's forearm and the patient is asked to flex the elbow against resistance with the forearm supinated (BPTs). (Copyright MoRe Foundation) **B** The forearm is then pronated, and the test is repeated (BPTp). Care is taken not to place the hands on the hand or wrist as resisted wrist flexion or extension might elicit pain in other elbow pathologies. (Copyright MoRe Foundation)

For the TILT sign, the patient's forearm is passively supinated and pronated with the elbow flexed to 90° while the examiner firmly palpates the dorsal forearm, overlying the radial tuberosity. The tuberosity presents itself beneath the examining fingers in full forearm pronation. A positive test is indicated by tenderness over the radial (or lateral) aspect of the tuberosity (TILT sign) only in full forearm pronation, and not in supination. (Shim and Strauch 2018)

The resisted hook test was first published in 2019 to examine biceps tendon integrity after biceps tendon repair (Pallante and O'Driscoll 2019). In 2020 it was published as a test to diagnose partial biceps tendon ruptures (Harasymczuk, Vaichinger et al. 2020).

The test is performed by positioning the shoulder in horizontal abduction with the elbow in 90° and the forearm supinated. The biceps tendon is 'hooked' on the radial side of the tendon, by the index finger of the examiner, and the patient is instructed to resist a pronation torque applied by the examiner. The test is considered to be positive if this maneuver is painful.

Evaluation of the tests

All tests were performed by two dedicated elbow surgeons in two participating centers: ZOL Genk, Belgium (Center1) and AZ Monica, Antwerp, Belgium (Center 2).

After institutional review board approval, each of the participating centers included all consecutive patients suspected of distal biceps tendon pathology, such as a partial tear, tendinosis or bicipital bursitis. Patients with a complete distal biceps tendon tear were excluded. As a control, the same number of consecutive patients with various elbow pathologies other than distal biceps tendon problems were also included. All elbow pathologies were noted. All three tests were performed in both control and patients with suspected biceps tendon pathology. FABS view MRI and/or surgical exploration was performed in patients in the suspected biceps tendon group to confirm or rule out distal biceps tendon pathology. FABS view MRI was performed in the control group.

The findings of the clinical tests were determined before MRI, surgery or other technical investigations were analyzed. The results were statistically analyzed (SPSS Software, Chicago, IL). Comparison of the tests for each participating center was performed using t-test and significance level was set at 0.05. Values reported for sensitivity, specificity and accuracy were calculated. Sensitivity and specificity were calculated for the combination of two test in a parallel testing setup.

RESULTS

The separate outcomes for each center are given in Table I.

All following results are calculated across both centers.

The average age in the distal biceps tendon pathology group was 47 years (range 35-67 years). 37 patients were male and 3 females. The dominant arm was involved in 19 patients. In the control group, the average age was 44 years (range 22-72 years). 34 patients were male and 6 were female. The dominant arm was involved in 26 patients. There were no statistical differences between the biceps and non-biceps group with

respect to age, sex and involvement of the dominant elbow. (p-value age: 0.7 / p-value dominance= 0.2 / p-value sex: 0.1)

	Center 1		Center 2	
	Biceps Group (n=20)	Control Group (n=20)	Biceps Group (n=20)	Control Group (n=20)
Age	47 (35-67)	45 (22-72)	46 (35-61)	42 (22-63)
Sex	17 male	20 male	20 male	14 male
MRI diagnosis				
<i>Partial tear</i>	9		5	
<i>Tendinosis</i>	11		15	
<i>Lateral epicondylitis</i>		11		12
<i>Posterolateral instability</i>				1
<i>Synovitis</i>		3		
<i>PIN compression</i>		1		6
<i>Symptomatic plica</i>		5		1
Biceps Provocation Test				
<i>Sensitivity</i>		100%		95%
<i>Specificity</i>		95%		95%
<i>Accuracy</i>		97,50%		95%
THLT Sign				
<i>Sensitivity</i>		55%		35%
<i>Specificity</i>		77%		65%
<i>Accuracy</i>		62,50%		55%
Resisted Hook Test				
<i>Sensitivity</i>		85%		65%
<i>Specificity</i>		95%		65%
<i>Accuracy</i>		90%		65%

Table I. Demographics and outcomes separated by participating center.

14 out 40 patients (35%) had a partial distal biceps tendon rupture which was confirmed on a FABS view MRI. In the remaining 26 patients (65%) FABS view MRI showed a

tendinosis or bursitis without partial tearing.

For the control group, diagnoses were made by clinical examination and confirmed by FABS view MRI. Specific attention was paid to rule out distal biceps tendon pathology on these images.

23 out of 40 patients (57%) were diagnosed with lateral epicondylitis. There was one (2,5%) case of posterior interosseous nerve compression, 11 (28%) with a symptomatic radiohumeral plica, 4 patients (10%) were diagnosed with intra-articular elbow synovitis and one with posterolateral instability (2,5%).

The ABT was positive in 39 patients with distal biceps tendon pathology and negative in one patient. There were 18 patients with a positive TILT sign and 22 with a negative TILT sign. The resisted hook test was positive in 30 patients and negative in 10 patients. In the control group, 38 patients had a negative ABT and 2 patients a positive ABT. The TILT sign was positive in 13 patients and negative in 27 patients. The resisted hook test was negative in 32 patients and positive in 8 patients.

The combined sensitivity and specificity and accuracy for the ABT was 95%, 97% and 96% respectively. For the resisted hook test, the combined sensitivity, specificity and accuracy were 78%, 76% and 77% respectively. The combined sensitivity, specificity and accuracy for the TILT sign was 58%, 55% and 56% respectively.

When combining the ABT and resisted hook test in a parallel testing setup the sensitivity increased to 98% while the specificity was 73%. The sensitivity and specificity for the ABT and TILT sign in a parallel testing setup was 97% and 53% respectively.

Finally, the sensitivity and specificity for the TILT sign and the resisted hook test in as parallel testing setup was 90% and 41% respectively.

DISCUSSION

Clinical examination is usually sufficient to confidently diagnose complete distal biceps ruptures. Various clinical tests, such as the hook test, the biceps crease interval test and the biceps squeeze test yield a very high sensitivity and specificity (up to 100% sensitivity and specificity) (O'Driscoll et al. 2007, Devereaux et al. 2013)

Until recently, no clear clinical tests were available to diagnose partial distal biceps tendon ruptures, distal biceps tendon bursitis or tendinosis. As technical investigation is usually requested based on the patient's history and clinical suspicion, significant delay or even missed diagnosis of distal biceps tendon pathology regularly occurred.

Three different clinical tests have been described in the last three years. The biceps provocation test, the TILT sign and the resisted hook test (Shim and Strauch 2018, Caekebeke, Schenkels et al. 2021, Pallante and O'Driscoll 2019). These may aid in a timely and accurate diagnosis of partial distal biceps ruptures, bicipital bursitis of tendinosis. The sensitivity and specificity and accuracy for the ABT was 95%, 97% and 96%. For the resisted hook test, sensitivity, specificity and accuracy were 78%, 76% and 77%. And sensitivity, specificity and accuracy for the TILT sign was 58%, 55% and 56% respectively. In the original paper, the TILT was positive in all three patients included. There was no control group, and sensitivity and specificity were not reported (Shim and Strauch 2018).

Both the biceps provocation test and the resisted hook test rely on impingement of the inflamed, thickened or ruptured tissue between the tendon and the radius. This tissue is compressed onto the radius with pronation. Tensioning the tendon by flexion against resistance or additionally hooking the tendon will then cause pain. The TILT sign relies on the digital compression of inflamed, thickened or ruptured tissue onto the radius in pronation. We believe that the inferior results of this test may be the result of failure to identify the correct location of the tuberosity in patients with biceps pathology. Furthermore, overlying muscles will decrease the compressive effect onto the tuberosity

and compressing the overlaying structures in patients with for example lateral epicondylitis or radial tunnel syndrome may result in a false positive test. Of note is that false positive results for the TILT sign occurred only in patients with lateral epicondylitis.

When combining the biceps provocation test and the resisted hook test in a parallel test setup the sensitivity increases to 98%. In a parallel test setup, if either test is positive, then the patient is considered to be positive. However, although this increases sensitivity, it lowers specificity, potentially leading to an increase in false positive findings. In our case, combined specificity was 73%. When compared to MRI, both sensitivity and specificity are higher for the biceps provocation test and similar for the resisted hook test (Schenkels, Caekebeke et al. 2020). Although these tests may therefore be performed independently of an MRI, we still suggest performing a FABS view MRI to improve specificity and to quantify the severity of the pathology and quality of the tendon, as this might alter further treatment. There are some limitations to this study. Firstly, this is a relatively small cohort. Secondly, in the control group the majority of patients had medial or lateral epicondylitis. A concern might be that the examiner would be biased. However, we performed the clinical examination starting with the three clinical tests and without a history taking. Therefore, we believe the bias was minimized.

CONCLUSION

The biceps provocation test yielded a higher accuracy compared to the resisted hook test and TILT sign. When combining the biceps provocation test and the resisted hook test, the sensitivity increases to 98%. We advise integration of this test in the daily practice to minimize delay of diagnosis of partial distal biceps tendon ruptures, distal biceps tendon bursitis or tendinosis. FABS view MRI is still advised to distinguish between a partial biceps tendon rupture and a tendinosis or bursitis at the distal biceps tendon insertion as this may influence further treatment.

REFERENCES

- Devereaux, M. W. and A. W. ElMaraghy (2013). "Improving the rapid and reliable diagnosis of complete distal biceps tendon rupture: a nuanced approach to the clinical examination." *Am J Sports Med* **41**(9): 1998-2004.
- O'Driscoll, S. W., et al. (2007). "The hook test for distal biceps tendon avulsion." *Am J Sports Med* **35**(11): 1865-1869.
- Festa, A., et al. (2010). "Effectiveness of magnetic resonance imaging in detecting partial and complete distal biceps tendon rupture." *J Hand Surg Am* **35**(1): 77-83.
- Schenkels, E., et al. (2020). "Is the flexion-abduction-supination magnetic resonance imaging view more accurate than standard magnetic resonance imaging in detecting distal biceps pathology?" *J Shoulder Elbow Surg*.
- Giuffrè, B. M. and M. J. Moss (2004). "Optimal positioning for MRI of the distal biceps brachii tendon: flexed abducted supinated view." *AJR Am J Roentgenol* **182**(4): 944-946.
- Shim, S. S. and R. J. Strauch (2018). "A novel clinical test for partial tears of the distal biceps brachii tendon: The TILT sign." *Clin Anat* **31**(2): 301-303.
- Caekebeke, P., et al. (2021). "Distal Biceps Provocation Test." *J Hand Surg Am*.
- Pallante, G. D. and S. W. O'Driscoll (2019). "Return of an Intact Hook Test Result: Clinical Assessment of Biceps Tendon Integrity After Surgical Repair." *Orthop J Sports Med* **7**(2): 2325967119827311.
- Harasymczuk, M., et al. (2020). Algorithm For Diagnosing Complete And Partial Distal Biceps Tendon Tears: Hook Test And Resisted Hook Test. [ESSE-SECEC](#). virtual meeting.

CHAPTER 3

EVALUATION OF MRI SIGNAL CHANGES OF THE DISTAL BICEPS TENDON IN ASYMPTOMATIC PATIENTS

EVALUATION OF MRI SIGNAL CHANGES OF THE DISTAL BICEPS TENDON IN ASYMPTOMATIC PATIENTS

SUMMARY

MRI investigation is widely used for complete ruptures of the distal biceps tendon. The reliability of this investigation for bicipital bursitis and tendinosis is unknown.

The purpose of present study was to assess the prevalence of incidental (asymptomatic) signal changes in the distal biceps tendon in patients who underwent MRI including the elbow. Our null hypothesis was that signal changes of the distal biceps tendon do not occur in asymptomatic patients. This would empower MRI as a diagnostic tool for bicipital bursitis and tendinosis as well as complete and partial distal biceps tendon ruptures. We evaluated 1191 elbow MRI scans including the distal biceps tendon insertion. The prevalence of incidental findings was calculated and sensitivity, specificity, positive predictive value, negative predictive value, false positive probability and false negative probability were calculated. The prevalence of distal biceps tendon signal changes on MRI in asymptomatic patients is very low. The negative predictive value of 99% shows that patients without signal changes on MRI may be assumed to have no distal biceps tendon pathology. MRI investigation of distal biceps tendon is a valuable tool in the diagnosis of tendinosis and bicipital bursitis.

Evaluation of MRI signal changes of the distal biceps tendon in asymptomatic patients.

Pieter Caekebeke¹, Annelien Brauns¹, Michel P.J. van den Bekerom^{2,3}, Joris Duerinckx¹ and Roger van Riet^{4,5,6}

¹Department of Orthopedic Surgery and Traumatology, Ziekenhuis Oost-Limburg, Genk, Belgium

²Department of Human Movement Sciences, Amsterdam Movement Sciences, Vrije Universiteit Amsterdam, Amsterdam, The Netherlands

³OLVG, Department of orthopedic surgery, Oosterpark 9, 1090 HM Amsterdam, the Netherlands

⁴Department of Orthopedic Surgery, AZ Monica, Antwerp

⁵Department of Orthopedic Surgery, University Hospital Antwerp, Edegem, Belgium

⁶Orthopaedic Specialists, Harley Street Specialist Hospital, 18-22 Queen Anne St, London W1G 8HU, United Kingdom

Journal of Hand Surgery (American volume). Accepted for publication.

INTRODUCTION

The diagnosis of tendinosis and bursitis of the distal biceps tendon can be challenging. The clinical findings include antecubital pain with activity and can be combined with some weakness to resisted flexion and supination (Hobbs et al. 2009). These vague symptoms may lead to delayed or missed diagnosis. Magnetic resonance imaging (MRI) has been proposed to confirm clinical diagnosis. On MRI, a degenerated distal biceps tendon (DBT) may be thickened and have signal heterogeneity, instead of the usual low signal intensity. Bicipital bursitis shows as a hyperintense flattened, oval, or round shaped cystic-appearing mass on T2 images that shows fluid signal intensity on all pulse sequences unless containing inflammatory debris or calcification (Chang et al. 2009). Considering enthesopathies such as lateral epicondylitis, such signal changes could become more prevalent with age, regardless of symptoms (Steinborn et al. 1999, van

Leeuwen et al. 2016). If that should also be the case for distal biceps pathology, this would greatly diminish the value of MRI investigation and may lead to overtreatment and mistreatment (Steinborn et al. 1999, Bossen et al. 2013, Kinaci et al. 2015).

Our primary study objective was to assess the prevalence of incidental (asymptomatic) signal changes in the DBT in patients who underwent a dedicated MRI including the elbow. Our null hypothesis was that signal changes of the DBT do not occur in asymptomatic patients.

MATERIALS AND METHODS

After internal review board approval, all MRI scans (MRI Philips Ingenia – 3T) covering the elbow performed in Ziekenhuis Oost-Limburg (Genk, Belgium) from January 2012 to August 2020 were obtained. This resulted in 1277 MRI scans. Inclusion criteria were a complete visualization of the DBT and its insertion onto the radial tuberosity, a complete medical record, a completed treatment whether successful or not and a complete radiology report by a trained musculoskeletal radiologist. If multiple MRI scans of the same elbow were available, only the first one was included. Following these criteria, 1248 MRI scans were included. Thirteen were excluded due to an incomplete file. The remaining were excluded due to insufficient MRI images (incomplete visualization of the insertion and movement artifacts). These images were first evaluated separately by the principal (LVM, resident in orthopedic surgery with special interest in hand and elbow surgery) and secondary investigator (AB, dedicated hand and elbow surgeon). This was performed blinded as not to be influenced by the radiology report. Next, the radiology report was searched for the description of the appearance of the DBT and possible alterations or pathology. Finally, the medical chart was consulted to obtain the age, sex, race, occupation, medical history including the presence of inflammatory joint disease and the indication for the MRI. These indications were categorized as acute trauma not including suspicion for DBT pathology (N=179), arthritis both inflammatory

and degenerative (N=175), medial and lateral enthesopathy and triceps tendinopathy (N=562), mass or swelling (N=44), instability (N=22), infection (N=11), nerve pathology (N=91) and DBT pathology (N=164). Indications such as trauma were proven while others such as tendon pathology and biceps complaints resulted from clinical suspicion on physical examination. Descriptive statistics for patient characteristics are presented. For continuous variables, means and standard deviations are reported and for categorical variables numbers and proportions are given for each category.

Sensitivity, specificity, positive predictive value, negative predictive value, false positive probability, and false negative probability were calculated. Patient history and the physical examination were considered the reference standard for the diagnosis of DBT. The AUC (area under the curve) was calculated based on a logistic regression model, with DBT pathology the binary outcome and MRI scan review the predictor. In multivariable logistic regression analyses, the association of explanatory variables – age, sex, race, occupation and inflammatory disease with incidental distal biceps tendon signal changes were assessed, accounting for possible confounding by any of the included factors. Adjusted odds ratios (ORs) are provided with 95% confidence intervals (CIs) and P values.

The IRR (inter-rater reliability) was calculated between the investigators and the radiology report.

RESULTS

The study included 1191 patients who underwent an MRI scan including the elbow, of whom 676 were men (56%). The mean age at the time of MRI for men was 50 (SD, 13) years compared to 48 (SD, 13) years for women ($P<.05$ by unpaired t test). The overall mean age was 49 (SD, 13) (range 4-93). Most patients were Caucasian (1095 [91%]). Six hundred twenty-five patients performed manual labor (50%), 471 patient performed

non-manual labor (37%) and 195 were either retired or a student (12%). Sixty-one patients had some form of inflammatory disease (4%). (Table 1)

Variable N=1191	No. (%)
Age in years (mean / SD)	49 (12)
<i>Age 20-40</i>	217 (18%)
<i>Age 40-60</i>	764 (64%)
<i>Age 60-80</i>	194 (17%)
<i>Age 80-100</i>	16 (1%)
Men	676 (56)
Inflammatory disease	61 (5)
Manual labor	625 (52)
Race	
<i>Caucasian</i>	1095 (91)
<i>African</i>	6 (0,2)
<i>Middle Eastern</i>	81 (8)
<i>Asian</i>	9 (0,8)
Indication	
<i>Distal biceps tendinopathy</i>	164 (13)
<i>Mass of swelling</i>	44 (3)
<i>Trauma</i>	124 (10)
<i>Arthritis</i>	175 (14)
<i>Lateral epicondylitis</i>	442 (35)
<i>Medial epicondylitis</i>	101 (8)
<i>Triceps pathology</i>	19 (1)
<i>Nerve pathology</i>	91 (7)
<i>Infection</i>	11 (0,8)
<i>Instability</i>	20 (2)

SD, standard deviation

Table I. Demographics

MRI scans of 31 of 164 patients (18%) in whom the MRI scan was performed for distal biceps pathology showed no biceps pathology according to the radiology report. The negative patients were treated according to the MRI diagnosis with a resolution of their complaints. Two of these patients (6%) had no pathology according to the radiology report but a positive sign upon review by the investigators. A positive sign was defined as a thickened tendon or signal heterogeneity, instead of the usual low signal intensity or signs of bicipital bursitis such as a hyperintense flattened, oval, or round shaped cystic-appearing mass on T2 images. Eight patients without a clinical indication of DBT pathology nor a final diagnosis and treatment had signal changes both on the radiology report and upon review (0.7%). Six of these patients had a successful therapy with resolution of their complaints. Two patients had some remaining complaints after treatment. Both deemed the complaints insufficient to continue therapy or investigations. Of the 1105 patients without signal changes on MRI scan, four were treated for biceps pathology. All of them were after trauma and were treated non-surgical with satisfactory outcome. They were considered the false negatives because the history and physical investigation was considered the reference standard. Thirty-two patients who were treated for DBT pathology had unsatisfactory outcome of treatment. One of these had a complete DBT rupture which was treated non-surgical.

The IRR between the two investigators was 100%, while the IRR between one of the investigators and the radiology report was 99%.

The sensitivity, specificity, positive predictive value, negative predictive value, false positive probability and false negative probability and AUC were calculated based on the investigator review because these included 2 patients the investigators felt were misdiagnosed by the radiologist.

The AUC quantifies the ability of the model to distinguish DBT pathology. The higher the AUC (near 1) the better the model is in predicting DBT pathology. An excellent

model has AUC near 1, a poor model has an AUC close to 0. An AUC of 0.5 indicates that the model is not performing better than a random classification of DBT pathology.

The sensitivity was 97% (95% CI: 93%-99%), the specificity was 99% (95% CI: 98%-99%), the positive predictive value was 94% (95% CI: 89%-97%), the negative predictive value was 99% (95% CI: 99%-99%), The false positive probability (FDR) was 6% (95% CI: 3%-10%) and the false negative probability (FOR) was 0.3% (95% CI: 0.1%-0.9%). (Table 2, 3)

	Negative signal on scan	Positive signal on scan
Negative DBT diagnosis	1044 (TN)	8 (FP)
Positive DBT diagnosis	4 (FN)	135 (TP)

Table 2: The cross table used to calculate the predictive estimates, detailing the number of patients with/without DBT and with and without MRI findings. DBT= Distal Biceps Tendinopathy, TN= True Negative, FN= False Negative, FP= False Positive, TP= True Positive.

Performance indicators	Results	95% CI
Sensitivity (TP/(TP+FN))	0.9712	[0.928;0.9921]
Specificity (TN/(TN+FP))	0.9928	[0.9858;0.9969]
Positive predictive value TP/(TP+FP)	0.9441	[0.8942;0.9712]
Negative predictive value TN/(TN+FN)	0.9964	[0.9905;0.9986]

Table 3: Sensitivity, Specificity, Positive predictive value and Negative predictive value based on the results as mentioned in table 2.

The AUC (area under the curve) was 0.98 (0.96 cross validated) in a model where MRI scan review by the investigators was used as a predictor of DBT pathology. (Figure 1) Multivariable logistic regression demonstrated no significant association between age (OR, 0.039; 95% CI, 0.035-0.042; SE, 0.023; P=0.09), sex (OR, 0.475; 95% CI, 0.471-0.478; SE, 0.744; P=0.52), race (OR, 0.341; 95% CI, 0.338-0.344; SE, 0.545; P=0.53), occupation (OR, 0.558; 95% CI, 0.553-0.561; SE, 0.415; P=0.18), inflammatory disease (OR, 0.465; 95% CI, 0.463-0.468; SE, 0.635; P=0.99) and asymptomatic signal changes

of the distal biceps tendon. No subdivisions with respect to age were made as no association was found.

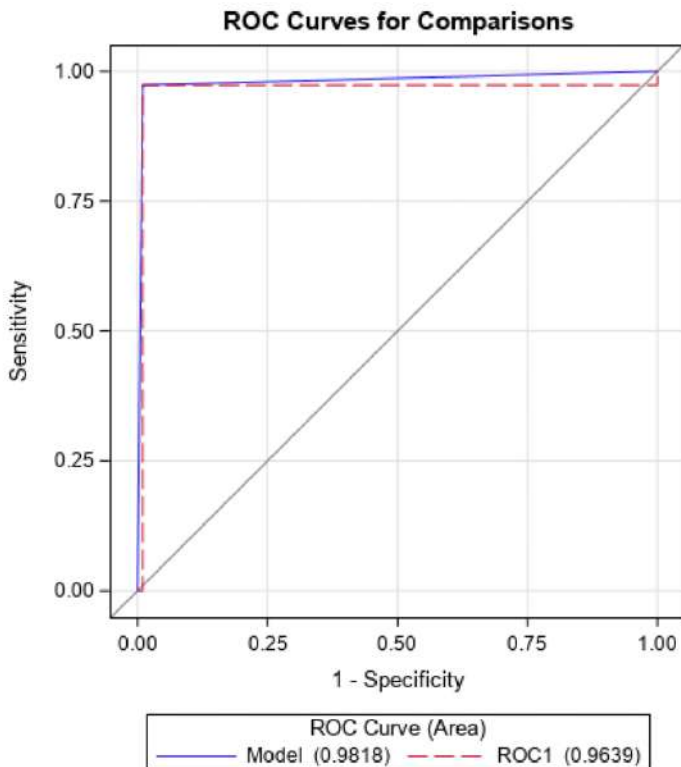


Figure 1: The AUC (area under the curve) for a model where MRI scan review by the investigators was used as a predictor of DBT pathology. (Continuous line: the AUC / dashed line: cross validation)

DISCUSSION

MRI is widely used to evaluate the DBT, typically to diagnose complete ruptures (Falchook et al. 1994, Festa et al. 2010). Questions remain regarding the effectiveness of MRI to evaluate more discrete pathology of the DBT like tendinosis or bicipital

bursitis. A high sensitivity and specificity of MRI scans, both for complete as well as partial DBT ruptures, and bicipital bursitis or tendinosis may lead to timely diagnosis and unnecessary further investigation as well as reduce mistreatment and overtreatment. The present study evaluated the occurrence of signal changes in asymptomatic patients because their absence would suggest value for MRI as a diagnostic tool for distal biceps tendinosis of bicipital bursitis. In 2004, Giuffrè et al. suggested the flexion abduction supination view (FABS) to optimally view the DBT from the musculotendinous junction to its insertion, usually on a single image (or in one or, at most, two sections) (Giuffrè and Moss 2004). Recently, the effectiveness of the FABS view MRI was compared to a standard MRI in the diagnosis of partial DBT ruptures and tendinosis (Schenkels et al. 2020). The sensitivity and specificity showed to be comparable between standard and FABS view MRI (Schenkels et al. 2020). The results of this investigation may be therefore extrapolated to FABS view MRI investigation. The IRR between the investigator evaluation of signal change and the radiology report was very high in present study. As one of the investigators was an orthopedic registrar lacking significant clinical experience, the high reliability suggests that the absence of signal changes may be detected independent of clinical experience.

We found a very low prevalence of signal changes in the asymptomatic population (0,7%). All cases with asymptomatic findings could be explained by their elbow pathology. Three patients incurred an acute trauma with multiple elongation lesions on MRI, including the biceps tendon, triceps tendon and brachialis tendon. Although no clear biceps pathology was found on clinical investigation, it may be overshadowed by the other pathologies. However, we cannot say with certainty that this signal change would not have been present before the trauma. Three patients had longstanding degenerative arthritis due to rheumatoid arthritis. This inflammatory pathology may explain the signal change of the DBT because the brachialis tendon and the triceps also

showed signal changes. One patient had multidirectional instability after an high impact trauma. We believe that this instability might have contributed to the signal changes seen in both the biceps and brachialis tendons. The final patient was diagnosed with lateral epicondylitis. After surgical treatment, anterior pain remained. As this pain was acceptable for the patient, no further treatment was performed. In this case, the lateral complaints may have overshadowed in the clinical investigation.

In 18% of patients the MRI, performed for the suspicion of biceps pathology, showed no biceps pathology. The requesting physicians we both primary care givers and orthopedic surgeons. The clinical investigation on which the suspicion of biceps pathology was based remains unclear. In this patient group all patients were treated according to the MRI diagnosis with a full resolution of their complaints. Clinical investigation of partial biceps tendon ruptures, bicipital bursitis and tendinosis remains challenging. In recent years several clinical test have been reported to aid in the clinical diagnosis (Shim et al. 2018, Harasymczuk et al. 2020, Caekebeke et al. 2021). As the MRI investigations in present study were collected starting in 2012, these tests were not yet common knowledge and this have influenced the clinical investigation of care givers not specialized in elbow pathology.

Asymptomatic signal changes have been described in several areas of the upper extremity. Teunis et al. report rotator cuff abnormalities in 355 of 2444 asymptomatic shoulders (15%), with the prevalence increasing from 7% (5 of 75) in patients aged 20 to 29 years, to 28% (130 of 468) in patients aged 70 to 79 years, and to 56% (33 of 59) in patients aged 80 years or older (Teunis et al. 2014). Van Leeuwen et al. identified signal changes in the ECRB origin on MRI scans in 369 out of 3374 patients (11%) without any clinical complaints. The prevalence of asymptomatic signal increased with age from 5.7% in patients aged 18 to 30 years up to 16% in patients older than 71 years

of age. Older age was independently correlated with the incidental finding of ECRB enthesopathy on MRI (van Leeuwen et al. 2016). Bastian and colleagues describe asymptomatic signal changes in several structures around the elbow including the common extensor tendon, flexor tendon, collateral ligaments, cartilage, biceps tendon, triceps and brachialis tendons. In comparison to the triceps and brachialis tendon, the biceps tendon had a relatively low prevalence of asymptomatic signal changes. There was a lower increase of signal changes in the biceps tendon compared to the common extensor tendon and flexor tendons (Bastian et al. 2019). The prevalence of asymptomatic signal changes in present study is very low (0,7%). This increases the value of MRI investigation as a diagnostic tool for these pathologies. Our study showed no correlation between explanatory variables – age, sex, race, occupation, and inflammatory disease with incidental distal biceps tendon signal changes. MRI can therefore be used for distal biceps tendon pathology independent of age, sex, race, occupation and whether the patient has an inflammatory disease.

There are several limitations to this study. First, most patients included in this study were Caucasian, and our sample may therefore not represent the average patient in other countries. Furthermore, due to our setting, our data should be interpreted as most representative of a tertiary care center with a strong primary care system.

Second, we assessed the MRI scans of patients who had symptoms around the elbow and not asymptomatic volunteers. This leads to an incomplete representation of general population. The age of the investigated population seems to be an adequate representation of the age profile of DBT pathology. However, we assume that this does not alter the results reported in this study.

Third, it could be that the MRI was ordered by another physician and that there was pain at the elbow but not mentioned in our file. Therefore, it should be mentioned that in all MRI examinations, the indication for MRI as included with the radiology report was

used as the most important factor, but that the patient chart was searched for further information.

Finally, there was a variation in MRI scanners used to obtain the images and difference in imaging technique. This may have affected the identification of signal changes by the researchers and the radiologists.

CONCLUSION

The prevalence of DBT signal changes on MRI in asymptomatic patients is very low. The negative predictive value of 99% shows that patients without signal changes on MRI may be assumed to have no DBT pathology. MRI investigation of DBT is a valuable tool in the diagnosis of tendinosis and bicipital bursitis.

REFERENCES

- Hobbs, M. C., et al. (2009). "Distal biceps tendinosis: evidence-based review." *J Hand Surg Am* **34**(6): 1124-1126.
- Chang, A. and T. T. Miller (2009). "Imaging of tendons." *Sports Health* **1**(4): 293-300.
- van Leeuwen, W. F., et al. (2016). "Incidental magnetic resonance imaging signal changes in the extensor carpi radialis brevis origin are more common with age." *J Shoulder Elbow Surg* **25**(7): 1175-1181.
- Steinborn, M., et al. (1999). "Magnetic resonance imaging of lateral epicondylitis of the elbow with a 0.2-T dedicated system." *Eur Radiol* **9**(7): 1376-1380.
- Kinaci, A., et al. (2015). "Surgical procedures of the elbow: a nationwide cross-sectional observational study in the United States." *Arch Bone Jt Surg* **3**(1): 13-18.
- Bossen, J. K., et al. (2013). "Does rewording MRI reports improve patient understanding and emotional response to a clinical report?" *Clin Orthop Relat Res* **471**(11): 3637-3644.
- Falchook, F. S., et al. (1994). "Rupture of the distal biceps tendon: evaluation with MR imaging." *Radiology* **190**(3): 659-663.
- Festa, A., et al. (2010). "Effectiveness of magnetic resonance imaging in detecting partial and complete distal biceps tendon rupture." *J Hand Surg Am* **35**(1): 77-83.
- Giuffrè, B. M. and M. J. Moss (2004). "Optimal positioning for MRI of the distal biceps brachii tendon: flexed abducted supinated view." *AJR Am J Roentgenol* **182**(4): 944-946.

- Schenkels, E., et al. (2020). "Is the flexion-abduction-supination magnetic resonance imaging view more accurate than standard magnetic resonance imaging in detecting distal biceps pathology?" *J Shoulder Elbow Surg*.
- Shim, S. S. and R. J. Strauch (2018). "A novel clinical test for partial tears of the distal biceps brachii tendon: The TILT sign." *Clin Anat* **31**(2): 301-303.
- Caekebeke, P., et al. (2021). "Distal Biceps Provocation Test." *J Hand Surg Am*.
- Harasymczuk, M., et al. (2020). Algorithm For Diagnosing Complete And Partial Distal Biceps Tendon Tears: Hook Test And Resisted Hook Test. ESSE-SECEC. virtual meeting.
- Teunis, T., et al. (2014). "A systematic review and pooled analysis of the prevalence of rotator cuff disease with increasing age." *J Shoulder Elbow Surg* **23**(12): 1913-1921.
- Bastian, S. A., et al. (2019). "Variations of magnetic resonance imaging findings in asymptomatic elbows." *J Shoulder Elbow Surg* **28**(6S): S154-S160.

CHAPTER 4

COMPARISON OF TWO MRI TECHNIQUES IN THE DIAGNOSIS OF PARTIAL DISTAL BICEPS TENDON RUPTURES

COMPARISON OF TWO MRI TECHNIQUES IN THE DIAGNOSIS OF PARTIAL DISTAL BICEPS TENDON RUPTURES

SUMMARY

Partial biceps tendon pathology is difficult to diagnose. The flexion-abduction-supination (FABS) magnetic resonance imaging (MRI) view has been advocated to improve the accuracy of MRI investigation. Although it was widely adopted in clinical practice, the sensitivity and specificity of the FABS view for partial distal biceps tendon tears and other distal biceps tendon pathology has not been studied. The study included 50 patients with surgically confirmed distal biceps tendon pathology and 50 patients with other elbow disorders. In both groups, standard elbow MRI (retrospective review of previously obtained MRI data) was performed in half of the patients whereas FABS views MRI were obtained in the other half. These were evaluated by 2 independent musculoskeletal radiologists. The sensitivity and specificity of both MRI views were determined. Tendinosis and grade of rupture were reported from MRI and then compared with surgical findings. No significant differences in sensitivity and specificity were found between the FABS view and standard elbow MRI in the diagnosis of partial distal biceps tendon injuries, with high sensitivity and specificity for both views. Inter-rater reliability was better for FABS views, and FABS views were significantly more accurate than surgical findings in grading the extent of pathology.

Is the FABs view MRI more accurate than standard MRI in detecting distal biceps pathology?

Eva Schenkels¹, Pieter Caekebeke², Linus Swinnen³, Jef Peeters³ and Roger van Riet^{1,4,5}

¹Department of Orthopedic Surgery, AZ Monica, Antwerp

²Department of Orthopedic Surgery and Traumatology, Ziekenhuis Oost-Limburg, Genk, Belgium

³AZ Monica, department of radiology, AZ Monica Hospitals, Antwerp, Belgium

⁴Department of Orthopedic Surgery, University Hospital Antwerp, Edegem, Belgium

⁵Orthopaedic Specialists, Harley Street Specialist Hospital, 18-22 Queen Anne St, London W1G 8HU, United Kingdom

Journal of shoulder and elbow surgery, 2020, 2 (12), p.2654-2660

INTRODUCTION

The diagnosis of a complete tear of the distal biceps tendon is mainly based on clinical examination (Sarda et al. 2013, Schmidt et al. 2013). A variety of clinical test have been described (Schmidt, Jarrett et al. 2013, O'Driscoll et al. 2007). However, in a complete tear with an intact lacertus fibrosus, partial tears, tendonitis or bursitis the clinical image may be less obvious (Shim et al. 2018, Bourne et al. 1991, Vardakas et al. 2001, Rokito et al. 1996, Durr et al. 2000).

Patients often complain of pain in the antecubital region, exacerbated with activity. Biceps strength is usually good and resistance tests may be negative. This often results in a significant delay in diagnosis, or it may be missed altogether (Bourne and Morrey 1991, Rokito, McLaughlin et al. 1996, Durr, Stabler et al. 2000).

MRI investigation (Figure 1) has been proposed if the diagnosis is unclear. Although MRI has been proven to be very sensitive for complete distal biceps tendon tears, the sensitivity for partial tears or other distal biceps tendon pathology is significantly lower (de la Fuente et al. 2018, Fitzgerald et al. 1994, Falchook et al. 1994, Festa et al. 2010).

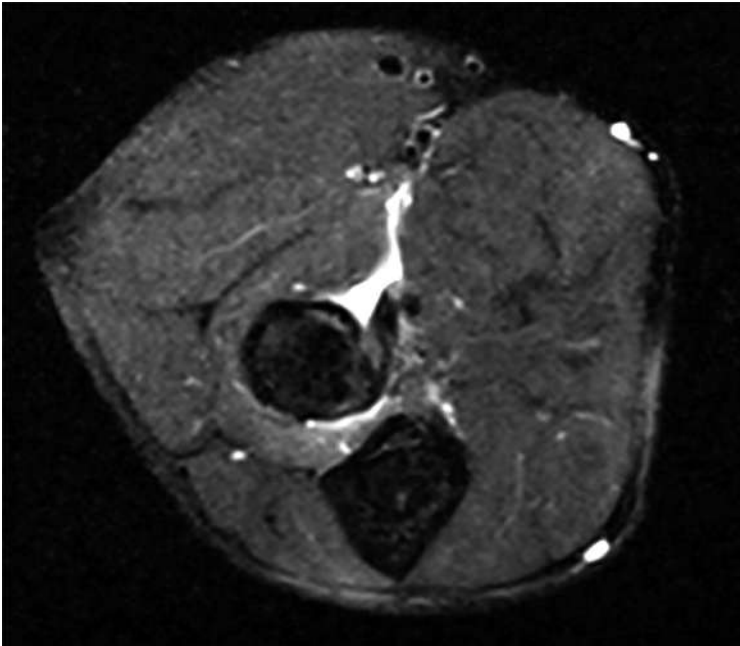


Figure 1. Standard magnetic resonance imaging view of distal biceps tendinosis. It should be noted that only a small portion of the tendon can be seen per the image. (Courtesy of MoRe Foundation)

In 2004, Giuffrè et al. suggested the flexion abduction supination view (FABS) to optimally view the distal biceps tendon from the musculotendinous junction to its insertion, usually on a single image (in one or, at most, two sections) (Giuffrè et al. 2004) (Figure 2). Although it was widely adopted in clinical practice, the sensitivity and specificity of the FABS view for partial distal biceps tendon tears and other distal biceps tendon pathology has not been studied.

The purpose of this study was to evaluate sensitivity, specificity and reproducibility of the FABS view MRI to detect distal biceps tendon pathology and to compare this to standard elbow MRI investigation.

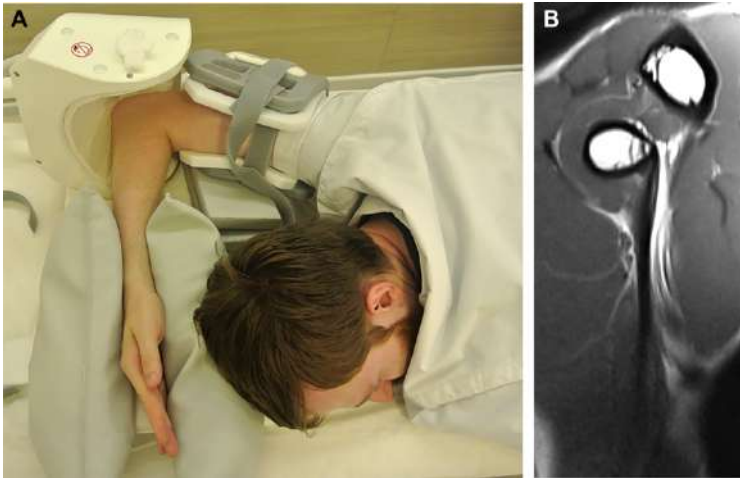


Figure 2. A Flexion-abduction-supination-view positioning with shoulder abduction and elbow flexion-supination.

B Flexion-abduction-supination magnetic resonance imaging view (3-dimensional double-echo steady state with water excitation) showing normal distal biceps tendon. The entire tendon can be viewed from the insertion to the musculotendinous junction on a single image. (Courtesy of MoRe Foundation)

MATERIAL AND METHODS

After internal review board approval, 100 patients with elbow pathology who underwent MRI investigation were included. All patients were treated by the senior author and MRIs were performed in a single institution. To be included in this study, biceps pathology had to be confirmed by biceps endoscopic surgery. MRI images had to satisfy the following criteria: (1) the area proximal to the biceps musculotendinous junction and distal to the radial tuberosity had to be viewable on the study; (2) the MRI hardware needed a magnet strength of 1.5 T; (3) no contrast was used. The scanner currently used is a Siemens 1.5 T Magnetom Aera, images taken before 2015 were taken by a Siemens 1,5T Symphony. The standard MRI protocol uses a 15-channel knee coil and includes axial T2 TSE fatsat, axial T1 TSE, coronal T1 TSE, coronal T2 TSE fatsat, sagittal T2 TSE fatsat. The patient

is positioned prone with the elbow extended above the head and thumb up (Superman position). Scan time for the standard elbow examination is 11 minutes and 17 seconds. The FABS view protocol has the following specifications: a 16-channel shoulder coil, included axial proton+T2 TSE fatsat, coronal T1 TSE and T2 fatsat, sagittal T2 TSE fatsat, axial and coronal 3D DESS with water excitation. For the FABS view MRI, patient positioning is very different: the patient lies prone with the arm in ‘FABS’ flexion-abduction-supination (Figure 2) during the total scanning time. Scan time for the FABS elbow examination: 15 minutes and 06 seconds. Detailed resolution of all MRI sequences is presented in Table I.

	T2, mm	T1, mm	PD, mm	3D DESS WE, mm
Standard elbow MRI sequences				
Axial	0.5 × 0.5 × 3	0.3 × 0.3 × 3	—	—
Coronal	0.6 × 0.6 × 2.5	0.6 × 0.6 × 2.5	—	—
Sagittal	0.4 × 0.4 × 3	—	—	—
FABS view MRI sequences				
Axial	0.3 × 0.3 × 3	—	0.3 × 0.3 × 3	0.3 × 0.3 × 2
Coronal	0.6 × 0.6 × 2.5	0.6 × 0.6 × 2.5	—	0.3 × 0.3 × 1.5
Sagittal	0.4 × 0.4 × 2.5	—	—	—

MRI, magnetic resonance imaging; *FABS*, flexion-abduction-supination; *T2*, fat and water highlighted; *T1*, fat highlighted; *PD*, proton density weighted; *3D DESS WE*, 3-dimensional double-echo steady state with water excitation.

Table I: Detailed resolution of MRI sequences for both standard elbow MRI and FABS views MRI

The Standard MRI images of 25 patients with distal biceps tendon pathology and 25 patients with another elbow problem, were retrospectively included from the surgeon’s database. Clinical and surgical notes were used to confirm the pathology. From 2018, 25 patients with distal biceps tendon pathology and 25 patients with another elbow problem were included prospectively and FABS views were obtained for these 50 patients. Patients were divided into four groups. The first group had FABS view images with distal biceps tendon pathology, surgically confirmed and graded during biceps endoscopy. A low-grade partial tear was defined as less than or equal to a 25% tear of the width of the distal biceps tendon attachment (Figure 3). An intermediate-grade tear was defined as a 25% to 50% tear of the width (Figures 4 and 5) and a high-grade partial

tear was defined as a greater than 50% tear of the width of the distal biceps tendon attachment (Figure 6).

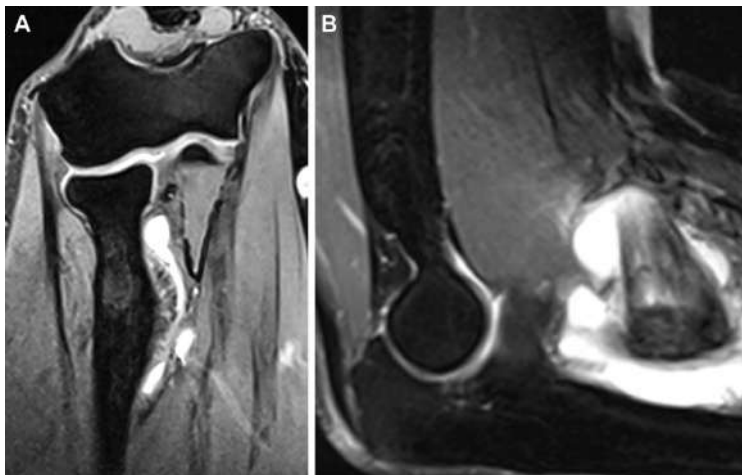


Figure 3. A-B Flexion-abduction-supination magnetic resonance imaging views (3-dimensional double-echo steady-state with water excitation) showing low-grade partial tear of distal biceps tendon and bicipital bursitis. (Courtesy of MoRe Foundation)

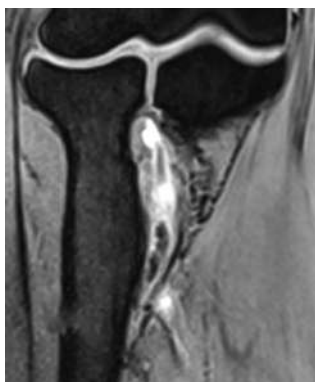

Figure 4. Flexion-abduction-supination magnetic resonance imaging view (3-dimensional double-echo steady-state with water excitation) showing intermediate-grade partial tear of distal biceps tendon (long head tear with short head intact). (Courtesy of MoRe Foundation)

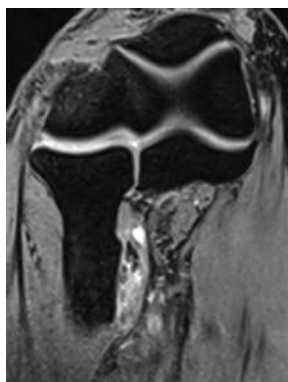


Figure 6. Flexion-abduction-supination magnetic resonance imaging view (3-dimensional double-echo steady-state with water excitation) showing high-grade partial tear of distal biceps tendon. (Courtesy of MoRe Foundation)

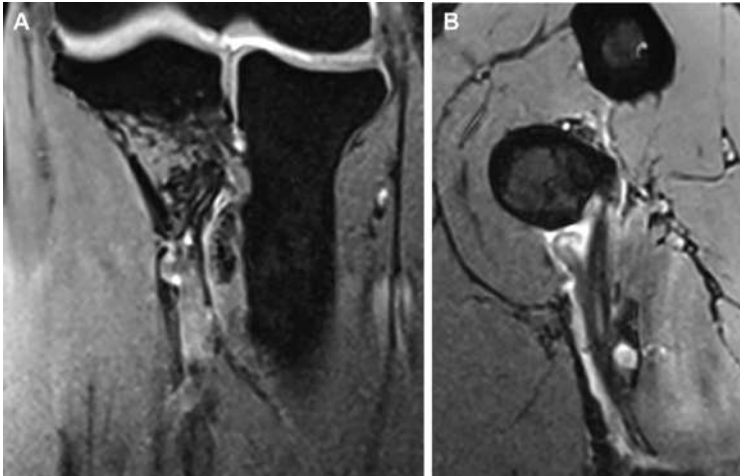


Figure 5. Flexion-abduction-supination magnetic resonance imaging views (3-dimensional double-echo steady-state with water excitation). **A** Intermediate-grade partial tear of distal biceps tendon with long head intact and short head tear. **B** Intermediate-grade partial tear of distal biceps tendon. (Courtesy of MoRe Foundation)

The second group included FABS views from patients with various elbow pathologies other than distal biceps tendon problems, such as lateral epicondylitis, ulnar nerve pathologies and medial epicondylitis. Patients did not complain of anterior elbow and forearm pain and clinical tests for distal biceps tendon pathology were negative.

The third group included patients with surgically confirmed distal biceps tendon pathology and preoperative standard MRI studies.

Finally, the fourth group consisted of standard MRI investigations from patients with other elbow pathologies than distal biceps tendon problems.

All investigations were blinded, randomized and evaluated by two independent radiologists, highly experienced in musculoskeletal imaging, with 8 and 22 years of practice respectively. The radiologists participating in this study were not involved in the original care of any patient in this study and did not receive any clinical information.

They were asked to provide a general diagnosis, and if the MRI proved positive for distal

biceps tendon pathology, to specify according to the following criteria (1) partial tear: characterize as either a high-grade, intermediate-grade or low-grade tear, using the definition provided earlier; (2) presence of tendinosis or (3) bicipital bursitis.

MRI interpretations were then correlated to the intraoperative findings and results were statistically analyzed (SPSS Software, Chicago, IL). Comparison of FABS and standard MRI was evaluated using t-test and significance level was set at 0.05. Values reported for sensitivity, specificity, positive predictive value, and negative predictive value were calculated. Furthermore, we evaluated the inter-observer reliability (IRR). For biceps pathology, the IRR in group 1 (FABS view) and group 3 (standard MRI) was based on the different types of distal biceps tendon pathology, as described above. The IRR for the other elbow pathologies was calculated on patients with either medial or lateral epicondylitis, as these were similarly distributed in group 2 (FABS view, 13 patients) and group 4 (standard MRI, 15 patients).

RESULTS

A total of 100 MRIs was included for review. Group 1 and 3 each included 25 surgically confirmed distal biceps tendinitis or partial ruptures. Group 2 and 4 each contained 25 MRIs of non-biceps pathologies. The mean ages in group 1 and 3 were 55 (range, 36-77 years) and 59 years (range, 34-87 years), respectively. In group 2 and 4 the mean ages were 48 years (range, 31-60 years) and 53 (range, 26-73 years). Group 1 consisted of 6 women and 19 men. In group 2, 8 women and 17 men were included. In the third group there were 8 women and 17 men and in group 4, 13 patients were women and 12 men. In both group 1 and 2, the dominant elbow was involved in 60% of patients. In group 3 and 4, the dominant elbow was involved in 56% and 68% respectively. In group 1, endoscopic findings included tendinosis or bicipital bursitis (12%), low-grade (20%), intermediate (12%) and high-grade (56%) partial distal biceps ruptures (Table II).

Group 1: biceps pathology with FABS view MRI	Radiologist 1, n	Radiologist 2, n	Endoscopy, n
Partial tears distal biceps tendon	14	11	22
Low grade (<25%)	7	4	5
Intermediate grade (25%-50%)	2	3	4
High grade (>50%)	5	4	13
Tendinosis	5	10	2
Bicipital bursitis	2	0	1
No biceps pathology	4	4	0

MRI, magnetic resonance imaging; *FABS*, flexion abduction supination.

Table II. Comparison of MRI interpretation reported by radiologists 1 and 2 with surgical findings (endoscopy) for FABS view MRI (group 1)

In group 3, there were no cases of tendinosis or bicipital bursitis and partial tears were divided into 60% low-grade, 8% intermediate and 32% high-grade tears (Table III).

In the biceps pathology groups 1 and 3, MRI interpretations were compared to intraoperative findings. Biceps pathology was correctly reported from FABS view MRI's in 84%, and in 76% on standard MRI's ($p=0.32$).

In the FABS view MRI group, 83% of tendinosis cases, 50% of low-grade tears, 67% of intermediate grade cases and 57% of high-grade partial tears were correctly identified (Table II). In the standard MRI group 23% of low-grade cases, none of the intermediate grade cases and 6% high-grade partial tears were correctly identified (Table III). There was a significant difference between FABS and standard MRI when comparing grading of the tears ($p=0.002$)

Group 3: biceps pathology with standard MRI	Radiologist 1, n	Radiologist 2, n	Endoscopy, n
Partial tears distal biceps tendon	13	9	25
Low grade (<25%)	9	7	15
Intermediate grade (25%-50%)	4	1	2
High grade (>50%)	0	1	8
Tendinosis	6	9	0
Bicipital bursitis	0	0	0
No biceps pathology	6	7	0

MRI, magnetic resonance imaging.

Table III. Comparison of MRI interpretation reported by radiologists 1 and 2 with surgical findings (endoscopy) for standard elbow MRI (group 3)

In the control groups 2 and 4, non-symptomatic biceps tendinosis was reported in 14% of cases on FABS view MRI's and in 2% on standard MRI.

The overall sensitivity in detecting distal biceps tendon pathology for the FABS view MRI was 84%, while the specificity was 86%. The standard MRI had an overall sensitivity and specificity in detecting distal biceps tendon pathology of 76% and 98%, respectively. There were no significant differences between FABS and standard MRI views in sensitivity ($p=0.32$) or specificity ($p=0.31$). The positive predictive value for the FABS view MRI was 86% and the negative predictive value was 84%. For standard MRI the positive and negative predictive values were 97% and 80%, respectively.

The inter-observer reliability (IRR) was 92% for the FABS view MRI's with biceps pathology, while for the standard MRI's with biceps pathology the IRR was 68%. In control groups the IRR was 88% for the FABS view MRI's and 96% for the standard MRI's. (Table IV)

	FABS view, %	Standard MRI, %
Sensitivity	84	76
Specificity	86	98
PPV	85	97
NPV	84	80
IRR	92	68

FABS, flexion abduction supination; *MRI*, magnetic resonance imaging; *PPV*, positive predictive value; *NPV*, negative predictive value; *IRR*, inter-rater (interobserver) reliability.

Table IV. Accuracy of FABS view and standard MRI view of partial distal biceps tendon ruptures

DISCUSSION

Partial ruptures of the distal biceps tendon are relatively uncommon injuries. Diagnosis is difficult since symptoms and clinical examination are often vague and aspecific (Shim and Strauch 2018, Bourne and Morrey 1991, Vardakas, Musgrave et al. 2001, Rokito, McLaughlin et al. 1996, Durr, Stabler et al. 2000). Literature has shown magnetic

resonance imaging (MRI) of the elbow to be a useful tool in the diagnosis of distal tendon pathology (Fitzgerald, Curry et al. 1994, Falchook, Zlatkin et al. 1994). However, most studies evaluate complete ruptures of the distal biceps tendon. A study that compared the effectiveness of standard elbow MRI for complete and partial ruptures, found the sensitivity of MRI to be only 59% for partial tears, compared to 100% for complete ruptures (Festa, Mulieri et al. 2010). The sensitivity (76%) of standard MRI views in the present study is higher than the previous reported sensitivity of 59% (Festa, Mulieri et al. 2010).

To improve the accuracy of MRI diagnosis of distal biceps tendon pathology, the flexion abduction supination view (FABS), was described by Giuffrè in 2004 (Giuffrè and Moss 2004). Although it has been used clinically, no specific research on the accuracy of the FABS view MRI had been published. Our data did not show a significant difference in sensitivity and specificity for FABS view MRI compared to standard MRI in the detection of distal biceps injuries.

The advantage of present study is that the radiologists were blinded to the purpose of this investigation. Only after the first distinction they were told to grade the distal biceps tendon ruptures as described before. In previous studies, the investigators were told that the MRI was suspected of distal biceps pathology (Williams et al. 2001).

There are several limitations to present study. Firstly, standard MRI and FABS MRI were not directly compared from the same patient. However, since the radiologists were not aware that they were evaluating distal biceps tendon pathologies in either group, we believe that the results of the study were not influenced. Secondly, we did not consider the chronicity of the tears. Previous research evaluated this and saw no influence on the results (Festa, Mulieri et al. 2010). Our FABS view MRI protocol included coronal and axial 3D sequences with slice thickness of 1.5 mm while the standard elbow MRI protocol had a slice thickness of 3 mm. Accuracy and consistency of the MRI

examination may have been influenced in favor of the FABS view by using thinner slice thickness compared to the standard MRI protocol.

Lastly, grading of the tear was based on surgical findings. This may have introduced an error but we feel this was the most accurate way possible.

CONCLUSION

The FABS view has shown to be a valuable tool in the diagnosis of partial distal biceps tendon injuries. No significant difference was found in sensitivity and specificity, when comparing FABS and standard views but interrater reliability was higher with FABS views and FABS views were significantly more accurate in grading the extent of the pathology when compared to surgical findings.

REFERENCES

- Sarda, P., et al. (2013). "Distal biceps tendon rupture: current concepts." *Injury* **44**(4): 417-420.
- Schmidt, C. C., et al. (2013). "The distal biceps tendon." *J Hand Surg Am* **38**(4): 811-821; quiz 821.
- O'Driscoll, S. W., et al. (2007). "The hook test for distal biceps tendon avulsion." *Am J Sports Med* **35**(11): 1865-1869.
- Shim, S. S. and R. J. Strauch (2018). "A novel clinical test for partial tears of the distal biceps brachii tendon: The TILT sign." *Clin Anat* **31**(2): 301-303.
- Bourne, M. H. and B. F. Morrey (1991). "Partial rupture of the distal biceps tendon." *Clin Orthop Relat Res*(271): 143-148.
- Vardakas, D. G., et al. (2001). "Partial rupture of the distal biceps tendon." *J Shoulder Elbow Surg* **10**(4): 377-379.
- Rokito, A. S., et al. (1996). "Partial rupture of the distal biceps tendon." *J Shoulder Elbow Surg* **5**(1): 73-75.
- Durr, H. R., et al. (2000). "Partial rupture of the distal biceps tendon." *Clin Orthop Relat Res*(374): 195-200.
- de la Fuente, J., et al. (2018). "Ultrasound classification of traumatic distal biceps brachii tendon injuries." *Skeletal Radiol* **47**(4): 519-532.
- Fitzgerald, S. W., et al. (1994). "Distal biceps tendon injury: MR imaging diagnosis." *Radiology* **191**(1):

203-206.

Falchook, F. S., et al. (1994). "Rupture of the distal biceps tendon: evaluation with MR imaging." *Radiology* **190**(3): 659-663.

Festa, A., et al. (2010). "Effectiveness of magnetic resonance imaging in detecting partial and complete distal biceps tendon rupture." *J Hand Surg Am* **35**(1): 77-83.

Giuffre, B. M. and M. J. Moss (2004). "Optimal positioning for MRI of the distal biceps brachii tendon: flexed abducted supinated view." *AJR Am J Roentgenol* **182**(4): 944-946.

Williams, B. D., et al. (2001). "Partial tears of the distal biceps tendon: MR appearance and associated clinical findings." *Skeletal Radiol* **30**(10): 560-564.

PART 2: IMPROVEMENT AND EVALUATION OF TREATMENT OPTIONS FOR DISTAL BICEPS TENDON PATHOLOGY

The treatment of partial distal biceps tendon ruptures and bicipital bursitis and tendinosis remains a challenge. With the popularization of endoscopic techniques, biceps endoscopy became more commonly used. Although the outcomes are promising, questions remain regarding the safety of this technique. The single incision technique is the technique of choice for many surgeons. The fixation with a bicortical button technique has the distinct advantage of a strong initial fixation allowing early rehabilitation. This technique, however, has some shortcomings. The inherent risk of posterior interosseous nerve damage and the inability for anatomical reinsertion lead to question regarding complication profile and functional outcome.

CHAPTER 5

EVALUATION OF THE SAFETY OF THE SINGLE-INCISION ENDOSCOPY OF THE DISTAL BICEPS TENDON

EVALUATION OF THE SAFETY OF THE SINGLE-INCISION ENDOSCOPY OF THE DISTAL BICEPS TENDON

SUMMARY

Clinical results of endoscopic distal biceps tendon repair have been shown to be comparable to open techniques in small series. We evaluated the safety of the endoscopic technique. Sixteen fresh-frozen paired cadaveric upper extremities were used. The distal biceps tendons were cut and then repaired with the classic single incision bone button technique. Eight were done through an open technique, and eight were repaired endoscopically. Safety and accuracy were assessed by comparing the distance of the repair to neurovascular structures as well as the distance of the bone tunnel to the native biceps insertion. There were no significant differences in variance between both groups. The single incision endoscopic-assisted technique of distal biceps repair can be performed consistently and with no added risk to neurovascular structures when compared to the classic open technique.

Accuracy and safety of the endoscopic repair of the distal biceps: a cadaveric study.

Pieter Caekebeke¹, Leesa Galatz² and Roger van Riet^{1,4,5}

¹Department of Orthopedic Surgery and Traumatology, Ziekenhuis Oost-Limburg, Genk, Belgium

²Department of Orthopedic Surgery, Icahn School of Medicine, Mount Sinai Health System, New York, NY

³Department of Orthopedic Surgery, AZ Monica, Antwerp

⁴Department of Orthopedic Surgery, University Hospital Antwerp, Edegem, Belgium

⁵Orthopaedic Specialists, Harley Street Specialist Hospital, 18-22 Queen Anne St, London W1G 8HU, United Kingdom

Acta Orthopaedica Belgica. 2020 Dec;86(4):711-716.

INTRODUCTION

Biceps tendon ruptures are relatively uncommon, with a reported prevalence of 1.2-2.5/100,000 per year (Safran et al. 2002). The diagnosis of a complete rupture is usually made by clinical examination only. The hook test is usually positive (O'Driscoll et al. 2007), there is weakness with resisted supination and often pain and mild weakness to resisted flexion (Sarda et al. 2013, Schmidt et al. 2013).

The biceps muscle may be retracted and the tendon stump can be palpated proximal to the elbow crease. The lacertus fibrosis is usually, but not always ruptured in these cases. Retraction of the muscle can be absent in patients where the lacertus remains intact. Radiographs, ultrasound and magnetic resonance scanning may aid the diagnosis, but don't always offer additional information.

Partial distal biceps tendon tears, tendonitis and bicipital bursitis are more difficult to diagnose by clinical examination only, and imaging modalities are usually needed in

these patients. Even then, it may prove to be difficult to differentiate between these pathologies with a sensitivity of less than 60% with conventional MRI (Festa et al. 2010). A simple debridement of the tendon by performing a bursectomy may suffice in patients with a tendinitis (Bain et al. 2008), whereas a completion of the tear followed by a reinsertion may be indicated in patients with a more substantial partial tendon tear (Dellaero et al. 2006, Kelly et al. 2003). As the treatment differs, it is important to be able to differentiate within this spectrum of pathological conditions. However, even intra-operatively it is often difficult to estimate the percentage of tendon that is involved. Tears usually initiate from the radial side of the tendon (Davis et al. 1956) and are more commonly found on the distal insertion of the short head. This is the portion facing the tuberosity and in order to inspect this side of the tendon, it needs to be dissected and retracted (Kelly, Steinmann et al. 2003). This may potentially have a detrimental effect on the already weakened insertion or disturb a tendon that is essentially intact. Biceps endoscopy has been proposed in order to overcome this disadvantage (Bain, Johnson et al. 2008, Eames et al. 2006, Sharma et al. 2005). It was first described by Sharma and Mackay who performed an endoscopically-assisted biceps tendon reinsertion in two patients with a full thickness tear (Sharma and MacKay 2005). The technique was later adapted to the technique most commonly used today (Bain, Johnson et al. 2008, Eames and Bain 2006, Vandenberghe et al. 2016).

The goal of this study was to evaluate the safety and accuracy of the single incision endoscopic-assisted technique compared to the open technique. Cadaveric research has been done (Bhatia et al. 2016, Bhatia et al. 2018), but the accuracy and safety of the endoscopic single incision technique has not been studied.

MATERIAL AND METHODS

Sixteen fresh-frozen paired cadaveric upper extremities were thawed to room

temperature. These specimens were donated to the university anatomy program and we paired and blinded. There were no visual signs of elbow deformities or previous surgery. The arms were positioned supine on a table. A 2-cm incision was made centrally on the forearm, 3-cm distal to the elbow crease. Following a visualization of the lateral cutaneous nerve, blunt dissection was carried to the biceps tendon and the bicipital bursa. (Figure 1A-B)

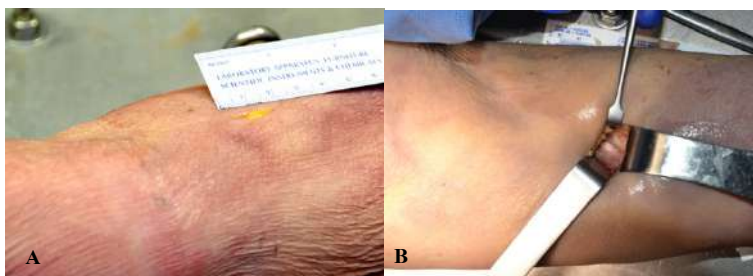


Figure 1: **A** Endoscopy was performed through a single anterior 2-cm incision. **B** Following blunt dissection the biceps tendon and bursa is visualized.

A 4.5 mm trocar was introduced into the bursa and advanced between the tendon and the bicipital tuberosity. The bicipital tuberosity is the first landmark and once the bone of the radius is identified, the scope is directed towards the tendon. The tendon was evaluated for any signs of pathology and the proximal and distal limits of the bursa were identified. (Figure 2)

The distal tendon was then cut under endoscopic visualization, delivered outside the incision, and sutured to a standard 4 by 12 mm cortical button (Smith&Nephew, London, UK) using no.2 Fiberwire (Arthrex, Naples, FL) suture. The repair was then performed in one of two ways, under direct 'open' or endoscopic view.

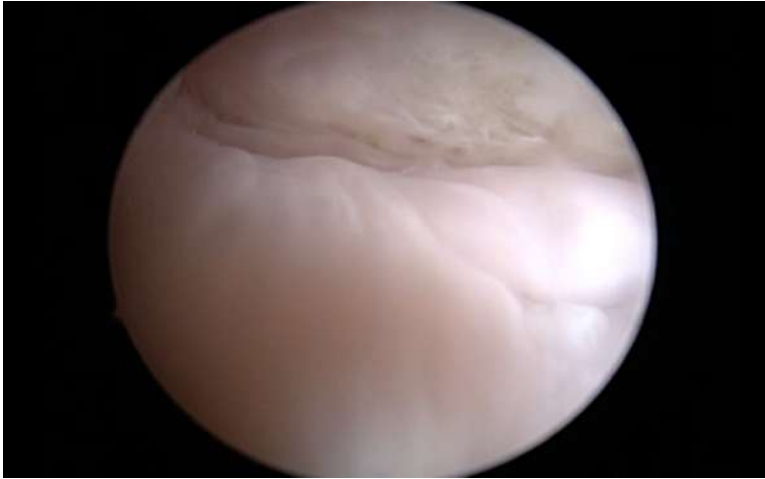

Figure 2: Endoscopic view of the biceps tendon. The tendon is below on the figure and the radial tuberosity above.

Paired specimens were equally divided between open and endoscopic repair, in order to obviate any differences between groups. With the forearm fully supinated, retractors were placed medially and laterally with respect to the radius, protecting all soft tissues during instrumentation. A guidewire was drilled perpendicular to the surface of the bicipital tuberosity at the edge of the biceps footprint and a bicortical endobutton repair was performed. An 8 mm cannulated drillbit was used to create a bone tunnel through the first cortex. A 4.5 mm cannulated drill was used to drill through the far cortex. The cortical button was then advanced through the bone tunnels and ‘flipped’. Fluoroscopy was used to confirm the correct position of the button.

Anatomic dissection of specimen was then performed. The distance from the center of the tunnel to the following structures were measured with the arm in neutral rotation- the superficial branch of radial nerve (SBRN), the anterior portion of the posterior interosseous nerve (aPIN), the median nerve, the ulnar artery, radial and recurrent radial arteries, and their bifurcation. (Figure 3)

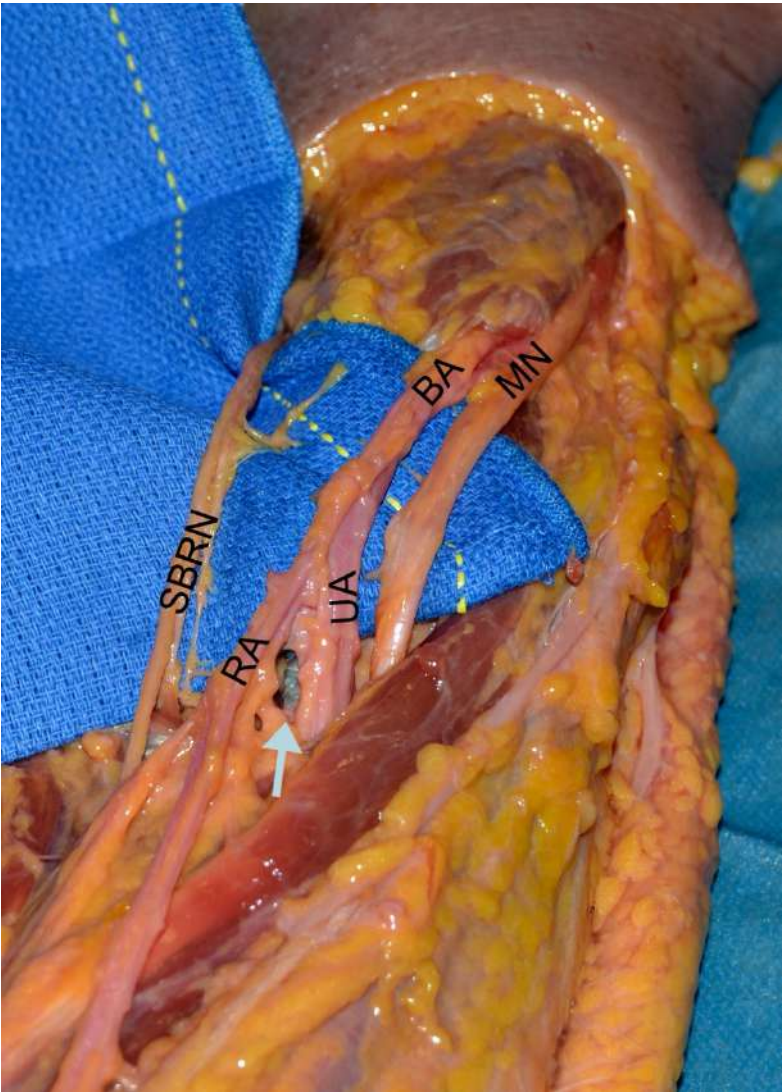


Figure 3: after insertion of the distal biceps the superficial branch of radial nerve (SBRN), the median nerve, the ulnar artery, radial and recurrent radial arteries, and their bifurcation were identified. Biceps reinsertion flagged with white arrow.

As the LACN was identified during blunt dissection, this entity was not included in the measurements. A handheld digital caliper with an accuracy of 0.1 mm was used for all measurements (SPI, digimax, USA). The shortest perpendicular distance was used for measurements.

The posterior aspect of the radius was then carefully dissected in order to identify the posterior interosseous nerve (pPIN). The distance from the button and the PIN was measured with the forearm in supination, as this is the position in which the guidepin is drilled. All soft tissues were then removed, leaving only the radius and biceps tendon repair.

Length and width of the bicipital tuberosity were measured. The distance from the center of the native tendon stump to the edge of the tunnel was measured, as well as the distance of the center of the tuberosity and the center of the tunnel. Paired t-tests were used to compare measurements. Variance was calculated as a measure of reproducibility. Significance level was set at $p=0.05$.

RESULTS

The proximal to distal length of the tuberosity was an average of 21.0 mm (range 17.7 to 26.3, SD 2.5 mm) and the average width was 11.2 mm (range 9.1 to 13.2, SD 1.2 mm). There were no significant differences between specimens where an open versus an endoscopic procedure was performed ($p=0.21$).

The average distance from the center of the native biceps tendon insertion and the tunnel that was drilled under direct, 'open', view was 1.1 mm (range 0.0 to 4.5, SD 1.7 mm), compared to an average of 2.2 mm (range 0.0 to 9.3, SD 3.1 mm) for the endoscopic group. This difference was not significant ($p=0.44$) and there was no significant difference in variance ($p=0.20$) between both groups. The average distance from the center of the bicipital tuberosity and the center of tunnel that was drilled under direct, open visualization was 1.4 mm (range 0.0 to 3.6, SD 1.4 mm), compared to an average

of 2.7 mm (range 0.0 to 9.0, SD 3.0 mm) for the endoscopic group. This difference was not significant ($p=0.35$) and there was no significant difference in variance ($p=0.11$) between both groups.

On the anterior side of the forearm, the ulnar artery was the closest neurovascular structure to the tunnel, with an average of 1.0 mm (range 0 to 6.1, SD 2.1mm). The radial artery and recurrent radial artery were located at an average distance of 3.1 mm (range 0 to 5.7, SD 2.5mm) and 18.7 mm (range 10.2 to 25.9, SD 4.9 mm) respectively, from the tunnel. The median nerve was an average of 10.2 mm (range 5.9 to 14.7, SD 2.6 mm) from the tunnel, and the SBRN and aPIN at 11.9 mm (range 8 to 15.6, SD 2.7 mm) and 12.0 mm (range 10.5 to 15.2, SD 1.4 mm) respectively (Table I).

The shortest distance between the pPIN and the endobutton at the posterior side of the radius was an average of 6.4 mm (range 1.3 to 12.0 mm, SD 3.6 mm), with the forearm in supination. When the arm was pronated, the button was in direct contact with the pPIN in 7 specimens. There were no significant differences between the open and endoscopic groups, for any of the anatomic measurements.

		Median nerve	Radial artery	Recurrent radial artery	ulnar artery	Sup branch Radial nerve	PIN ant	PIN post
Open	Average	10,1	1,6	18,6	1,2	12,6	11,6	4,6
	Max	14,7	5,7	25,9	6,1	15,2	15,6	8,1
	Min	5,9	0,0	10,2	0,0	10,5	8,0	1,3
	SD	2,6	2,5	4,9	2,1	1,4	2,7	2,6
endoscopic	Average	10,3	4,0	18,0	0,9	11,1	12,3	8,2
	Max	13,4	11,3	22,2	7,5	15,7	17,0	12,0
	Min	7,7	0,0	6,7	0,0	4,4	9,4	3,1
	SD	2,1	3,7	4,7	2,5	3,4	2,5	3,5

Rec: Recurrent; Avg: Average; Max: Maximum; Min: Minimum; SD: Standard Deviation

Table 1: Average distances between the vascular and neurological structures and the radial tunnel (mm).

DISCUSSION

Endoscopic distal biceps tendon repair is an emerging technique, and can be done safely with respect to neurovascular structures (Bain, Johnson et al. 2008, Eames and Bain 2006, Sharma and MacKay 2005, Vandenberghe and van Riet 2016, Duffiet et al. 2009, Gregory et al. 2009). The main potential advantage is the excellent visualization of the radial side of the tendon, without the need for pulling or retracting the injured tendon (Kelly, Steinmann et al. 2003) or additional disruption of the blood supply of the tendon (Dellaero and Mallon 2006). This portion of the tendon is the most commonly involved in partial biceps tendon ruptures and this portion may remain hidden from view in open techniques (Dellaero and Mallon 2006, Kelly, Steinmann et al. 2003). Although this procedure has been used clinically (Bain, Johnson et al. 2008, Eames and Bain 2006, Sharma and MacKay 2005, Duffiet and Fontes 2009, Gregory, Roure et al. 2009), limited studies have evaluated its safety and none have compared safety and accuracy to the classic single -incision open technique (Bhatia, DasGupta et al. 2016, Bhatia and Kandhari 2018). Endoscopic biceps tendon repair was first described by Sharma and MacKay in 2005 (Sharma and MacKay 2005). They made a small incision proximal to the elbow crease and drilled a guide wire from proximal to distal, creating an oblique tunnel in the radius. Although no complications occurred in the two patients reported (Sharma and MacKay 2005), Saldua et al. showed that this oblique angle carried an increased risk to the PIN and recommended a different trajectory (Saldua et al. 2008). Bain et al. adapted the endoscopic technique and this is what we have been using clinically to date (Eames and Bain 2006). Bhatia and colleagues showed that the 2-incision endoscopic technique is technically feasible in the treatment of distal biceps tendon ruptures (Bhatia, DasGupta et al. 2016, Bhatia and Kandhari 2018). They tested the technique with both suture anchors and cortical buttons. They also emphasize that the cortical button technique has a higher risk of iatrogenic injuries due to the position of the button. This technique differs however from our described technique as it is a 2-

incision technique which requires an added proximal portal. We prefer a single incision to minimize possible other risks due to a second portal as we believe that biceps endoscopy is feasible through a single incision. The aim of the current study was to determine, the feasibility and safety of an all-endoscopic distal biceps tendon repair. No significant differences with regards to the native insertion of the distal biceps tendon and the insertion of the reconstructed tendon were found when open and endoscopic techniques were compared. All tunnels were located within the native radial tuberosity. With respect to safety, comparison of the open and endoscopic techniques showed no significant differences with regards to the distance of neurovascular structures and the reconstructed biceps tendon or endobutton. Our results, like other studies, emphasize the importance of correct positioning of the arm in supination during endobutton insertion to protect the pPIN. When the forearm was pronated, all endobuttons contacted the nerve, so the endobutton must lie flush along the posterior cortex of the radius. The neurovascular structures were within mm of the tunnels and tendon, so it is imperative that retractors are placed on either side of the radius to provide direct visualization of the tendon stump and the radial tuberosity and to protect them during instrumentation. One of the limitations is that this study was performed on cadaveric specimens. We are therefore unable to comment on possible neuropraxia or compression injuries to the nerves (Cain et al. 2012). Secondly, the specimens were uninjured, so there was no scar or hematoma present. Therefore, these results may not be as easily applicable to the traumatic rupture, as they are to the partial tear or bursitis scenario.

CONCLUSION

In conclusion, our results show that the endoscopic technique can be performed consistently and with no added risk to neurovascular structures compared to the open technique. Due to the close proximity of the anterior neurovascular structures, we do recommend the use of retractors when shavers or drills are used.

REFERENCES

- Safran, M. R. and S. M. Graham (2002). "Distal biceps tendon ruptures: incidence, demographics, and the effect of smoking." *Clin Orthop Relat Res* (404): 275-283.
- O'Driscoll, S. W., et al. (2007). "The hook test for distal biceps tendon avulsion." *Am J Sports Med* **35**(11): 1865-1869.
- Sarda, P., et al. (2013). "Distal biceps tendon rupture: current concepts." *Injury* **44**(4): 417-420.
- Schmidt, C. C., et al. (2013). "The distal biceps tendon." *J Hand Surg Am* **38**(4): 811-821; quiz 821.
- Festa, A., et al. (2010). "Effectiveness of magnetic resonance imaging in detecting partial and complete distal biceps tendon rupture." *J Hand Surg Am* **35**(1): 77-83.
- Bain, G. I., et al. (2008). "Treatment of partial distal biceps tendon tears." *Sports Med Arthrosc* **16**(3): 154-161.
- Dellaero, D. T. and W. J. Mallon (2006). "Surgical treatment of partial biceps tendon ruptures at the elbow." *J Shoulder Elbow Surg* **15**(2): 215-217.
- Kelly, E. W., et al. (2003). "Surgical treatment of partial distal biceps tendon ruptures through a single posterior incision." *J Shoulder Elbow Surg* **12**(5): 456-461.
- Davis, W. M. and Z. Yassine (1956). "An etiological factor in tear of the distal tendon of the biceps brachii; report of two cases." *J Bone Joint Surg Am* **38-A** (6): 1365-1368.
- Eames, M. H. and G. I. Bain (2006). "Distal biceps tendon endoscopy and anterior elbow arthroscopy portal." *Tech Shoulder Elbow Surg* (7): 139-142.
- Sharma, S. and G. MacKay (2005). "Endoscopic repair of distal biceps tendon using an EndoButton." *Arthroscopy* **21**(7): 897.
- Vandenbergh, M. and R. van Riet (2016). "Distal biceps ruptures: open and endoscopic techniques." *Curr Rev Musculoskelet Med* **9**(2): 215-223.
- Bhatia, D. N., et al. (2016). "Cadaveric study of anterior and posterior elbow endoscopy portals for endoscopic distal biceps repair: comparative anatomy-at-risk." *Surg Radiol Anat* **38**(7): 781-791.
- Bhatia, D. N. and V. Kandhari (2018). "Analysis of technical feasibility and neurovascular safety of endoscopic distal biceps repair: a cadaveric study." *J Shoulder Elbow Surg* **27**(11): 2057-2067.
- Duffiet, P. and D. Fontes (2009). "[Endoscopic repair of distal biceps brachii tendon avulsion: a new technique. Report of 25 cases]." *Chir Main* **28**(3): 146-152.
- Gregory, T., et al. (2009). "Repair of distal biceps tendon rupture using a suture anchor: description of a new endoscopic procedure." *Am J Sports Med* **37**(3): 506-511.

Saldua, N., et al. (2008). "The effect of drilling angle on posterior interosseous nerve safety during open and endoscopic anterior single-incision repair of the distal biceps tendon." *Arthroscopy* **24**(3): 305-310.

Cain, R. A., et al. (2012). "Complications following distal biceps repair." *J Hand Surg Am* **37**(10): 2112-2117.

CHAPTER 6

IDENTIFYING ANATOMIC LANDMARKS IMPORTANT FOR INTRAMEDULLAR DISTAL BICEPS TENDON FIXATION

IDENTIFYING ANATOMIC LANDMARKS IMPORTANT FOR INTRAMEDULLAR DISTAL BICEPS TENDON FIXATION

SUMMARY

The aim of this study was to measure cortex thickness and medullar canal width of the bicipital tuberosity in a large cohort size, to evaluate the accessibility of a possible intramedullar fixation device and the resistance to pullout strengths of the anterior cortex. The final objective was to determine the length of tendon ingrowth size that will be expected when using this surgical technique which may prevent tendon-bone gapping. A total of 144 computer tomography images of the proximal radius were used. Bone thickness of the anterior and posterior cortex and medullar canal size were measured proximal, distal and at the radial tuberosity. The possible ingrowth of the tendon was measured both for an anatomical and non-anatomical reinsertion. The radial tuberosity anatomy can accommodate the new distal biceps fixation device. The anterior cortex on which the new device relies for support has a similar thickness as the posterior cortex used in bicortical fixation devices which may suggest similar resistance to pull-out strengths. The availability for intra-osseous fixation of the tendon stump may avoid tendon gapping.

Radial tuberosity anatomy in intramedullar repair of distal biceps tendon ruptures. A radiological study.

Laurens van Melkebeke¹, Roger van Riet^{2,3,4}, Joris Duerinckx¹ and Pieter Caekebeke¹

¹Department of Orthopedic Surgery and Traumatology, Ziekenhuis Oost-Limburg, Genk, Belgium

²Department of Orthopedic Surgery, AZ Monica, Antwerp

³Department of Orthopedic Surgery, University Hospital Antwerp, Edegem, Belgium

⁴Orthopaedic Specialists, Harley Street Specialist Hospital, 18-22 Queen Anne St, London W1G 8HU, United Kingdom

Acta Orthopaedica Belgica. Accepted for publication

INTRODUCTION

Surgical repair of complete distal biceps tendon (DBT) ruptures results in a higher flexion and supination force and endurance compared to non-operative treatment (Baker et al. 1985). Widely used techniques such as the single incision techniques with bicortical button fixation (Bain et al. 2000) have a high load to failure allowing early active range of a motion, and loading, almost immediately after surgery (Mazzocca et al. 2007). With this technique the tendon stump is placed inside the radial bone, thus minimizing the risk of gap formation between the DBT stump and the bone during active biceps contraction (Rashid et al. 2016). The biggest disadvantage of this technique is the potential iatrogenic damage to the posterior interosseous nerve (PIN) (Amarasooriya et al. 2020). In recent years intramedullary fixation has been proposed to minimize the risk of PIN damage (Caekebeke et al. 2020, Caekebeke et al. 2021). Knowledge on the load to failure and outcomes of these techniques are limited to small series biomechanical or in vivo series (Caekebeke et al. 2020, Caekebeke et al. 2021). In contrast to the bicortical technique in which the button is supported by the thick posterior cortex, in these techniques, the bony support is by the anterior cortex. There is little known regarding the anterior cortex anatomy around the radial tuberosity, its thickness in different sections and its possible

importance in assuring a good resistance to pulling out of the implants use in surgical reinsertion of the DBT. The few studies that describe the anterior cortex are small series (Lazaro-Amoros et al. 2017). The width of the intramedullary canal, which has to allow the intramedullary fixation device, has not been described specifically around the radial tuberosity, nor has any study evaluated the possible intraosseous tendon length allowed by an intramedullary fixation device. The purpose of the present study was to describe the osseous anatomy of the proximal radius especially concerning the radial tuberosity with clinical application regarding distal biceps tendon repair. We determined the size of the cortices and medullary canal width at the level of the tuberosity as well as proximal and distal to the tuberosity. Given the recent development of intramedullary fixation methods we determined the length of tendon ingrowth size that will be expected when using this surgical technique.

MATERIAL AND METHODS

Data collection

We collected all CT scans of the elbow regardless of the indication executed by the radiology department at our institution from July 2019 until December 2020 with a total of 144. All CT scans were separately evaluated and measured by two authors of this article (LVL and PC). We used a multiple detector computed tomography (MDCT) scanner (Siemens Somatom Force, Siemens Healthineers, Germany) for the acquisition of the images. These images were transferred to Siemens Syngo.via software (Siemens Healthineers, Germany) for analysis and measurements with a calibration of 0.1mm. Inclusion criteria were the visualization of the proximal radial bone from the elbow joint to 20mm distal of the tuberosity. CT scans without the availability of reconstructed images in the axial, coronal and sagittal plane were excluded. We excluded all patients

younger than 18 years, patients with dysplasia, patients with fractures of the radial tuberosity and proximal ulna or previous surgery around the elbow.

Measurement technique

The measurements were performed in the axial plane of the radial bone after referencing the long axis of the proximal radius in the coronal and sagittal planes perpendicular to the proximal radial joint line to become a standardized true axial view. (Fig. 1)

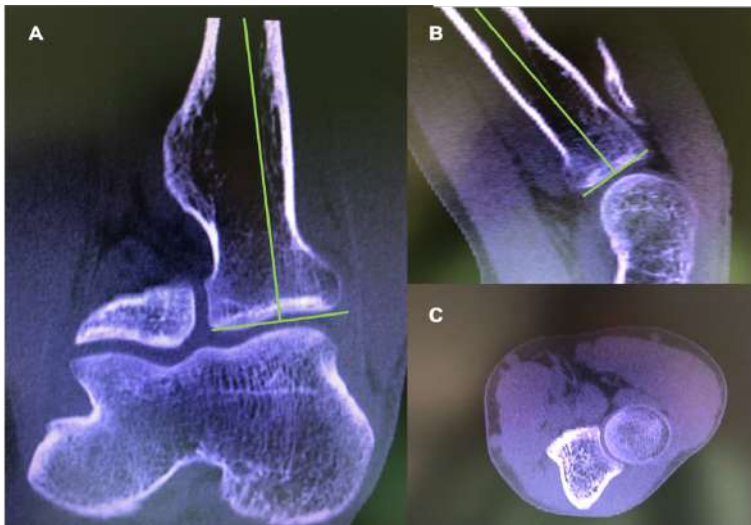

Figure 1: Alignment of the axial images based on the perpendicular in a coronal and sagittal view.

We divided the proximal radius into three zones based on the position of intramedullary fixation methods extending outside the tuberosity region (Caeckebeke, Duerinckx et al. 2020). We measured the anterior and posterior cortex distal (Distal anterior and posterior cortex width; DAC and DPC) and proximal (Proximal anterior and posterior cortex width; PAC and PPC) and at the center (Tuberosity anterior and posterior cortex width;

TAC and TPC) of the radial tuberosity. The width of the canal was measured both distal and central and proximal of the radial tuberosity (Proximal, distal and tuberosity medullar canal width; PMC, DMC and TMC). (Fig.2)

To determine the possible length of ingrowth of the tendon stump we determined the distance from the 'Transtuberosity line' (TTL) to the cortex of the radial tuberosity both in an anatomical and non-anatomical fashion. The TTL was determined in a true sagittal view, as determined above, by connecting the medullar sides of the anterior cortex from proximal to distal. This represents the edge of the intramedullar button onto which the tendon is fixated. (Fig 2)

This line was reproduced in the axial view and two measurements were performed. First, we measured the length of the connecting line between the TTL and the apex of the radial tuberosity representing the non-anatomical position of tendon reinsertion technique (Tuberosity apex distance; TAD). A second measurement was the line connecting the TTL to the anatomical insertion site of the distal biceps. (Tuberosity insertion distance; TID). The center of the biceps tendon insertion is slightly anterior to the tuberosity apex and the tendon was also visible on the CT scans to aid in pinpointing the true anatomical insertion place. (Fig 3) We compared measurements between male and female patients. All measurements are given in millimeters (mm).

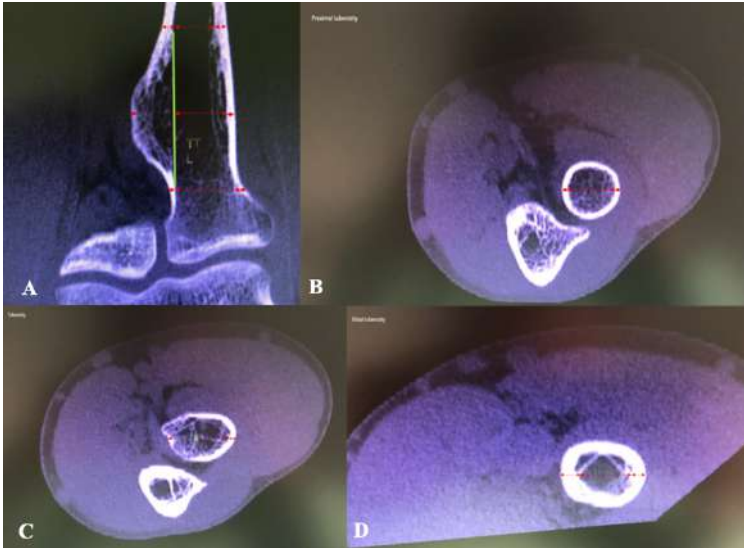


Figure 2: A The button line (green) as reference for the intramedullar button. Measurements of cortices and medullary canal are also depicted to clarify but were measured on an axial view for accuracy. B Measurements of cortices and medullary canal proximal of the tuberosity. C Measurements of cortices and medullary canal at the tuberosity. D Measurements of cortices and medullary canal distal of the tuberosity.

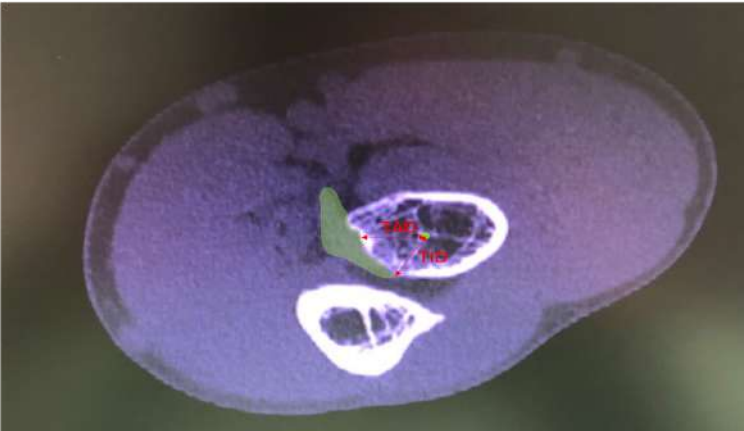


Figure 3: Depiction of the measurement of the Tuberosity apex distance (TAD) and the Tuberosity insertion distance (TID). The tendon is depicted in green.

Statistical analysis

The sample size was estimated based on a power analysis done on the first 50 patients. The required number of patients to acquire adequate representation of the general population was 125. We used descriptive statistical analysis to collect the following data of each of the previously mentioned areas for all the patients together and each gender separately. We determined the mean of each distance with its lower and upper border of the 95% confidence interval, the standard deviation, the minimum and maximum and the 25th and 75th percentile.

RESULTS

The CT investigations of 144 patients were included in present study. Of these, 72 were male and 72 female. The average age was 51. A significant age difference was seen between the male and female group ($P < 0,05$). The averages of all measurements are given in Table I.

Measurement	Male(SD) N=72	Female(SD) N=72
Proximal Anterior Cortex (PAC)	3,2 (0,6)	2,7(0,6)
Proximal Medullary Canal (PMC)	9,3(1,6)	8(1,2)
Proximal Posterior Cortex (PPC)	2,8(0,6)	2,4(0,6)
Distal Anterior Cortex (DAC)	3,5(0,6)	2,9(0,6)
Distal Medullary Canal (DMC)	8,4(0,6)	7,4(1,2)
Distal Posterior Cortex (DPC)	3,4(0,6)	3,1(0,5)
Tuberosity Anterior Cortex (TAC)	2(0,9)	1,8(0,5)
Tuberosity Medullary Canal (TMC)	8,3(1,5)	7,1(0,9)
Tuberosity Posterior Cortex (DPC)	3,1 (0,5)	2,7 (0,5)
Tuberosity Apex Distance (TAD)	8,4(1,3)	7,2(1,1)
Tuberosity Insertion Distance (TID)	8,1(1,3)	7,1(0,9)

Table I: Averages main outcome measurements.

The average width of the medullary canal was 9,3mm proximal, 8,4mm distal and 8,3mm at the tuberosity (SD: 1,6, 1,3 and 1,5 respectively) for the male group and 8mm proximal, 7,4mm distal and 7,1mm at the tuberosity (SD: 1,2, 1,2 and 0,9, respectively)

for the female group. The interval of the 25th and 75th percentile across both groups was between 7,6mm and 9,6mm proximal, between 7,1mm and 8,9mm distal and between 6,8mm and 8,5mm at the center of the tuberosity. The lowest measurement was 5,1mm proximal, 5,0mm distal and 4,6mm at the center of the tuberosity. A significant difference was seen between the male and female groups ($P<0,05$)

The average anterior cortex measured 3,2mm (SD 0,6) proximal, 3,5mm (SD 0,6) distal and 2mm (SD 0,9) at the radial tuberosity in male patients and 2,7mm (SD 0,6) proximal, 2,9mm (SD 0,6) distal and 1,8mm (SD 0,5) at the radial tuberosity in female patients. The interval of the 25th and 75th percentile across both groups was between 2,5mm and 3,5mm proximal, between 2,7mm and 3,7mm distal and between 1,5mm and 2,1mm at the center of the tuberosity. A significant difference was seen between the male and female groups ($P<0,05$)

The average posterior cortex measured 2,8mm (SD 0,6) proximal, 3,4mm (SD 0,6) distal and 3,1mm (SD 0,5) at the radial tuberosity in male patients and 2,4mm (SD 0,6) proximal, 3,1mm (SD 0,5) distal and 2,7mm (SD 0,5) at the radial tuberosity in female patients. The interval of the 25th and 75th percentile across both groups was between 2,1mm and 3,0mm proximal, between 2,8mm and 3,7mm distal and between 2,5mm and 3,4mm at the center of the tuberosity. A significant difference was seen between the male and female groups ($P<0,05$)

The tuberosity apex distance was 8,4 mm on average in male patients and 7,2mm in female patients. The interval of the 25th and 75th percentile across both groups was between 6,7mm and 8,3mm. The lowest measurement was 44mm. The tuberosity insertion distance was 8,1mm on average in male patients and 7,1mm in female patients. The interval of the 25th and 75th percentile across both groups was between 6,7mm and

8,3mm. The lowest measurement was 5,1mm. There was no significant difference between the two measurements ($P= 0,59$).

DISCUSSION

Distal biceps tendon ruptures are relatively uncommon comprising 3% of all biceps tendon tears (Morrey 1993). Operative treatment has become standard to ensure recovery of elbow flexion and more important supination strength and endurance (Morrey 2000). Various fixation devices have been proposed with intramedullary fixation being the most recent development. Intramedullary fixation has the distinct advantage to minimize posterior interosseous nerve damage and thus allowing for an optimal anatomical reinsertion through a single anterior incision. Several aspect of tendon fixation seems to be important such as a high load to failure to allow early active range of motion and loading (Mazzocca, Burton et al. 2007). Furthermore, intraosseous positioning of the repaired tendon minimizes gap formation (Rashid, Copas et al. 2016). In recent years, two different intramedullary fixation techniques have been described. First, a double button fixation on the anterior cortex of the radial tuberosity (Siebenlist et al. 2011) and second a singular intramedullary button that hooks on thicker anterior cortex on both sides of the radial tuberosity (Caekebeke et al. 2020, Caekebeke et al. 2021). The first technique has shown to have a similar load to failure to the bicortical button technique. There is a need to place two buttons as the anterior cortex of the radial tuberosity is markedly thinner than the posterior cortex. This has been shown in small series evaluating the cortex thickness and density at the radial tuberosity (Lazaro-Amoros et al. 2017).

The dual button technique places the repaired tendon against the outer cortex which may lead to gap formation as shown in repairs with the anchor technique (Rashid, Copas et al. 2016). The second intramedullary fixation uses a larger button which is inserted by an 8mm drill hole in allowing an intra-osseous positioning of the tendon stump. The

larger button hooks on the thicker anterior cortex on both sides of the radial tuberosity. Biomechanical evaluation seems to be promising with similar load to failure as the bicortical button technique (Caekebeke et al. 2020). Not much is known, however, regarding the anatomical factors regarding this technique. The thickness of the cortex on both sides has never been evaluated nor is the diameter of the medullary canal. This is needed to evaluate if the button will reliably fit inside the medullary canal. As the tendon is pulled inside the radial bone, risk of gap formation should be minimized. However, as of yet, no information exists on the amount of tendon that can be pulled inside the radial bone.

The goal of this study was to provide accurate measurement of the anterior cortex, both of the radial tuberosity and on both sides of the tuberosity. A second objective was to describe the diameter of the medullary canal on different sites around the radial tuberosity as well as the possible depth the tendon can be pulled inside the bone both in a non-anatomical and anatomical repair. Prior studies regarding radial tuberosity anatomy used microCT images while standard CT images were used for this study. Similar results between measurements on microCT and standard CT have been reported (Lazaro-Amoros et al. 2017). As the thickness of the anterior and posterior cortex in present study are comparable to previous mentioned results, we assumed that standard CT is indeed as proficient to measure cortical thickness. This allowed a larger cohort to perform measurements on to meet power analysis requirements.

The anterior cortex on both sides of the tuberosity are of the same average thickness as the posterior cortex with a respectively mean of 3,2mm anterior and 2,9mm posterior indicating that this part around the radial tuberosity offers similar resistance as the posterior cortex. The medullary canal averaged at 8,1 mm which would be sufficient to accommodate the proposed intramedullary fixation design.

The average tunnel depth was 8,4 mm with non-anatomical repair and 7,1 mm when measured in line of an anatomical repair. The average slippage of the tendon during mobilization and active contraction of the distal biceps tendon has been evaluated in biomechanical studies and ranged from $0,83 \pm 0,13\text{mm}$ to $1,4 \pm 1,4\text{mm}$ (Caekebeke et al. 2020, Siebenlist et al. 2015). The tunnel depth seems to be sufficient to allow some slippage and to avoid tendon-bone gapping as seen with anchor fixation (Rashid, Copas et al. 2016).

There are several limitations to this study. First, all measurements were performed on stand CT images. Although microCT images may yield more accurate measurements, several studies shown adequate accuracy when using standard CT compared to microCT. We opted for standard CT images to obtain a large measurement cohort which significantly surpasses the number required in the power analysis. Finally, the measurement of the posterior and anterior cortex at the radial tuberosity is comparable to previous microCT measurements (Lazaro-Amoros et al. 2017). Second, given that the CT scans were taken for different indications on a non-standardized manner we manually aligned the plane of the radial tuberosity by using the sagittal and coronal planes to have standardized measurements. This may lead to a margin of error but given the fact that our results are comparable to previous studies on standardized microCT we assumed adequate measurements. Finally, although these measurements give us an adequate image of the possible tunnel depth, in vivo investigation is required to see if this depth is sufficient to prevent gap formation in clinical situation. The same goes for the strength of the anterior cortex. Although it has a similar thickness as the posterior cortex and previous biomechanical studies seems to be promising, in vivo evaluation of this intramedullary fixation has to be conducted.

CONCLUSION

The radial tuberosity anatomy can accommodate the new distal biceps fixation device. The anterior cortex on which the new device relies for support has a similar thickness as the posterior cortex used in bicortical fixation devices which may suggest similar resistance to pull-out strengths. The availability for intra-osseous fixation of the tendon stump may avoid tendon gapping. The intra-osseous length for the tendon stump allowed by the device surpassed reported tendon slippage during mobilization and active contraction of the distal biceps tendon.

REFERENCES

- Baker, B. E. and D. Bierwagen (1985). "Rupture of the distal tendon of the biceps brachii. Operative versus non-operative treatment." *J Bone Joint Surg Am* **67**(3): 414-417.
- Bain, G. I., et al. (2000). "Repair of distal biceps tendon rupture: a new technique using the Endobutton." *J Shoulder Elbow Surg* **9**(2): 120-126.
- Mazzocca, A. D., et al. (2007). "Biomechanical evaluation of 4 techniques of distal biceps brachii tendon repair." *Am J Sports Med* **35**(2): 252-258.
- Rashid, A., et al. (2016). "Failure of distal biceps repair by gapping." *Shoulder Elbow* **8**(3): 192-196.
- Amarasooriya, M., et al. (2020). "Complications After Distal Biceps Tendon Repair: A Systematic Review." *Am J Sports Med* **48**(12): 3103-3111.
- Caekebeke, P., et al. (2020). "A new intramedullary fixation method for distal biceps tendon ruptures: a biomechanical study." *J Shoulder Elbow Surg*.
- Caekebeke, P., et al. (2021). "In vivo evaluation of a new intramedullary distal biceps tendon fixation device." *J Shoulder Elbow Surg*.
- Lazaro-Amoros, A., et al. (2017). "Bicipital tuberosity bone characteristics in surgical reattachment of the distal biceps: anatomical and radiological study." *Surg Radiol Anat* **39**(2): 135-140.
- Morrey, B. F. (1993). Tendon injuries around the elbow. *The elbow and its disorders*. B. F. Morrey and J. Sanchez-Sotelo, Saunders: 492-504.
- Morrey, B. F. (2000). Tendon injuries about the elbow. *The elbow and its disorders 3rd ed.* B. F. Morrey, Saunders: 468-478.

Siebenlist, S., et al. (2011). "The double intramedullary cortical button fixation for distal biceps tendon repair." *Knee Surg Sports Traumatol Arthrosc* **19**(11): 1925-1929.

Siebenlist, S., et al. (2015). "Double intramedullary cortical button versus suture anchors for distal biceps tendon repair: a biomechanical comparison." *Knee Surg Sports Traumatol Arthrosc* **23**(3): 926-933.

CHAPTER 7

BIOMECHANICAL EVALUATION OF AN INTRAMEDULLAR DISTAL BICEPS TENDON FIXATION DEVICE

BIOMECHANICAL EVALUATION OF AN INTRAMEDULLARY DISTAL BICEPS TENDON FIXATION DEVICE

SUMMARY

Various techniques have been described for distal biceps tendon reinsertion. All current techniques have specific shortcomings with complications such as heterotopic ossification, nerve damage, gap formation. In present study a standard bicortical button was compared to the new intramedullary fixation device using fresh-frozen cadaveric specimens. The fixation strengths were tested both cyclically and statically. Load to failure and method of failure were also recorded. There were no failures during the cyclic load testing. The mean load to failure for the bicortical group was 296 ± 97 N, whereas the new button group showed a higher mean load to failure of 356 ± 37 N. The new intramedullary fixation device yields comparable loads to failure compared with currently used techniques in a biomechanical setup. These findings together with the theoretical advantages suggest that this technique might be a valuable solution in distal biceps tendon rupture repair.

A new intramedullary fixation method for distal biceps tendon ruptures: a biomechanical study.

Pieter Caekebeke¹, Joris Duerinckx¹, Johan Bellemans¹ and Roger van Riet^{2,3,4}

¹Department of Orthopaedics Surgery and Traumatology, Ziekenhuis Oost-Limburg, Genk, Belgium

²Department of Orthopedic Surgery, AZ Monica, Antwerp

³Department of Orthopedic Surgery, University Hospital Antwerp, Edegem, Belgium

⁴Orthopaedic Specialists, Harley Street Specialist Hospital, 18-22 Queen Anne St, London W1G 8HU, United Kingdom

Journal of Shoulder and Elbow surgery. 2020, 29(10):2002-2006.

INTRODUCTION

Distal biceps tendon ruptures are relatively uncommon. Their incidence is estimated to be 1.2 in 100000 (Sarda et al. 2013, Safran et al. 2002). The most common mechanism is a forced eccentric contraction of the biceps brachii muscle with the elbow positioned in flexion and supination (Schmidt et al. 2013). Operative treatment is usually indicated to ensure maximal recovery of elbow strength and endurance (Baker et al. 1985, Chillemi et al. 2007). Various fixation methods have been described, including suture anchors, interference screws and fixation buttons (Lynch et al. 1999, Morrey et al. 1985, Bain et al. 2000, Siebenlist et al. 2019). The construct with the highest load to failure is the extramedullary bicortical fixation button method as first described by Bain and colleagues (Bain, Prem et al. 2000, Mazzocca et al. 2007). This allows for early active range of motion, and loading, almost immediately after surgery. A second advantage of this fixation technique is the intra-osseous placement of the distal biceps tendon, minimizing the chance of gap formation between the tendon stump and the bone during active biceps contraction (Mazzocca, Burton et al. 2007, Sethi et al. 2010). The main disadvantage of the extramedullary cortical button is that the distal biceps tendon cannot

be anatomically reattached at the insertion site at the radial tuberosity as this would place the posterior interosseous nerve at significant risk for entrapment behind the cortical button (Lo et al. 2011). In order to protect the nerve, the biceps tendon has to be attached more anterior on the radius but this potentially decreases final supination strength (Schmidt et al. 2010).

The purpose of the present study is to evaluate a new intramedullary fixation device. Because this button is placed inside the intramedullary canal of the radius, it allows safe reattachment of the distal biceps tendon at its anatomical footprint. We compared the fixation strength of this new intramedullary button with the classic bicortical button. We hypothesize that both buttons provide comparable fixation strength.

The purpose of the present study is to evaluate a new intramedullary fixation device. Because this button is placed inside the intramedullary canal of the radius, it allows safe reattachment of the distal biceps tendon at its anatomical footprint. We compared the fixation strength of this new intramedullary button with the classic bicortical button. We hypothesize that both buttons provide comparable fixation strength.

MATERIAL AND METHODS

Specimens

12 elbows were harvested from 6 fresh frozen cadavers and thawed at room temperature. The contralateral specimens were used to compare the standard extramedullar bicortical endobutton technique (Endobutton, Smith & Nephew, Watford, United Kingdom) to the new intramedullar fixation button.

New button design

The button was designed using 3D software (Autodesk fusion 360) and printed in Titanium (Materialize, Leuven, Belgium) (Figure 1). The initial designs were printed in a polyamide plastic and tested on 12 radius specimens to determine size. The design features a bel shape to allow the tendon to be pulled into the bone with a maximum depth of 3mm plus the thickness of the proximal cortex. The button has a width of 4mm and a length of 24 mm to span the single drill hole of 8mm that is made at level of the radial tuberosity to insert the distal biceps tendon into the bone. This length also allows purchase on the thick cortical bone alongside the thinner bone of the tuberosity (Figure 2)



Figure 1: The fixation device

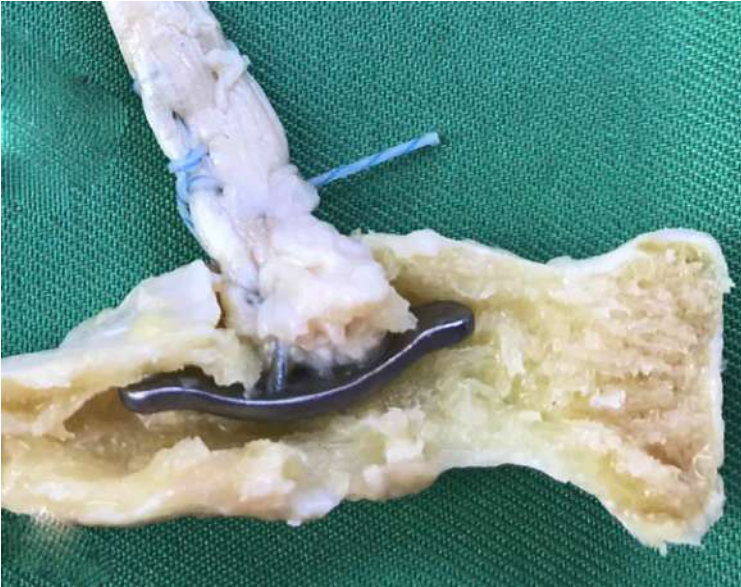

Figure 2: The peddles of the new button span over the radial tuberosity and get support on the thick anterior cortex.

Surgical technique and biomechanical testing

In each specimen, the distal biceps tendon was transected at its insertion on the radial tuberosity. A partially absorbable suture (FiberLoop 2; Arthrex, Naples, FL, USA) was passed in a whipstitch fashion in the distal 20 mm of the distal biceps tendon so that its ends emerged at the distal tendon stump. Both ends of the suture were passed through the holes in the button.

The commercially available extramedullary fixation button is made of titanium. A 4.5-mm guide pin is drilled through the radius at level of the radial tuberosity. Next, an 8mm cannulated drill is used to open the near cortex. A 4.5 mm cannulated drill is used to drill through the far cortex. The button is passed through the drill holes in the radius and

flipped extramedullary on the posterior cortex. Fluoroscopy was used to confirm the correct position of the button.

For the intramedullary button, the guide pin was drilled only through the near cortex at the footprint of the biceps tendon, and overdrilled with a cannulated 8mm drill. The button is inserted intramedullary by sliding it into the medullary canal and positioned into the drill hole by pulling on both the sutures simultaneously. The tendon is pulled into the radius by pulling the sutures separately, using the tension slide technique described by Sethi (Sethi et al. 2008). The tendon is fixed by tying the suture. Fluoroscopy was again used to confirm the correct position of the button. (Figure 3)

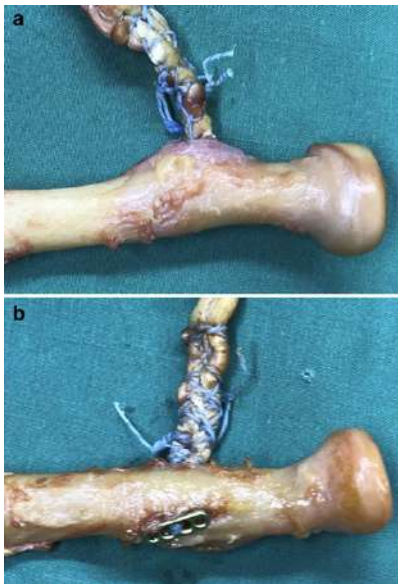

Figure 3: A-B The two different setups showing one with an intramedullary and one with a bicortical fixation.




Figure 4: The test setup with a custom mount at 30° to simulate the native line of pull. Hand drawn lines were used for measurement of displacement.

Following preparation, the radii and reconstructed biceps were removed from the forearm. All soft tissues were removed. The proximal 10 cm of radial bone were preserved. The radii were clamped to a custom mount (Figure 4). The tendon was firmly attached to a metal clamp. The line of pull on the biceps was chosen to be at a 30-degree flexion angle as this was deemed to be a physiological loading condition. Specimens were cyclically loaded for 1,000 cycles at 2.5 Hz from 5 to 100 N. Following each 1,000 cycles, the load was returned to 5 N (preload) and a strict lateral view of the mounted constructs was photographed. For displacement measurements, three hand-drawn regions of interest (ROIs) were appointed at the proximal, central and distal area of the restored footprint of distal biceps tendon (Figure 3). Afterwards, all specimens in which failure did not occur during cyclic loading were loaded to failure with an extension rate of 4 mm/s. Maximum load to failure was defined at a sudden drop in force of >50 % from the applied maximum force. Stiffness of the construct was calculated using the linear portion of the load-displacement graph from the load to failure testing. The mode of failure for each repair was recorded. Measurements were compared using Student's T test.

RESULTS

Cyclic loading

All constructs completed the cyclical testing without failure. After 1,000 cycles with 100 N, the mean tendon–bone displacement was 0.87 ± 0.13 mm for the bicortical group and 0.83 ± 0.13 mm for the new button group.

Static loading

The mean load to failure for the bicortical group was 296 ± 97 N. Mean load to failure for the new intramedullary button group was 332 ± 44 N ($P=0.19$). The mean difference in load to failure between both repair groups was not statistically significant. The mean stiffness of the bicortical group was 58.2 ± 9.2 N/mm, and 61.1 ± 9.7 N/mm in the new button group ($P=0.6$).

There was one failure in the bicortical group due to knot failure in an early stage of testing (16%). Three constructs (50%) failed by suture tearing through the tendon and 2 constructs (33%) failed by button pull-out with fracture avulsion of the anterior cortex. In the new intramedullary button group one construct failed due to button pull-out with fracture avulsion of the anterior cortex (16%). The remaining five (83%) failed by suture tearing through the tendon.

DISCUSSION

In distal biceps tendon repair, the anterior single incision approach has gained popularity over the two-incision technique (Grewal et al. 2012). The latter has a higher risk of forearm bone synostosis and loss of forearm rotation or rotational strength (Kelly et al. 2000), and a higher risk of posterior interosseous nerve injury (Dunphy et al. 2017).

Several implant types have been described to reattach the distal biceps tendon to the radius through the single incision approach (Lynch, Beard et al. 1999, Morrey, Askew et al. 1985, Bain, Prem et al. 2000). Extramedullary cortical button fixation is favorable because it provides the strongest initial fixation (Mazzocca, Burton et al. 2007). However, the local anatomy with the posterior interosseous nerve curving around the radius on the opposite side of the tuberosity creates an increased risk of damaging the

nerve when using this device. As a result, it is advised to insert the tendon in a non-anatomical position (Lo, Li et al. 2011). However, this leads to decreased supination strength (Schmidt, Weir et al. 2010, Schmidt et al. 2012).

An intramedullary fixation device that does not violate the posterior cortex of the radius has been advocated to decrease the risk of nerve injury, while allowing an anatomical repair (Siebenlist et al. 2011, Volk et al. 2019). However, fixation on the thin cortex of the radial tuberosity may lead to suboptimal fixation strength and possible button breakout. Previous biomechanical studies (Siebenlist, Lenich et al. 2011) showed that both the load to failure of the unicortical fixation is lower than the bicortical fixation and that the method to failure is potentially catastrophic with a fracture of the anterior cortex. Siebenlist and colleagues therefore advised a stronger double button unicortical fixation method (Siebenlist, Lenich et al. 2011). However, in their technique the buttons are essentially used as an anchor with fixation of the tendon onto the bone and not in a bone tunnel. This can, in turn, lead to gap formation due to tendon pistoning. This is inherent of tendon fixation against the bone instead of in a bone tunnel (Mazzocca et al. 2007, Sethi et al. 2010).

The goal of this study was to biomechanically evaluate a novel fixation device developed in response to these concerns. The unicortical fixation decreases the risk of nerve injury while allowing an anatomical position of the repaired tendon. The increased length of the button allows the button to hold against the thicker anterior cortex of the radius instead of the weaker tuberosity. Due to the bell shape of the button the tendon can be pulled into the bone tunnel, decreasing potential tendon to bone gap formation. The biomechanical results of the new button are comparable to other currently used techniques (Mazzocca, Burton et al. 2007, Siebenlist, Lenich et al. 2011). Both load to failure (356N) and stiffness (61N/mm) are similar to the excellent results of the bicortical button technique (Mazzocca, Burton et al. 2007, Siebenlist, Lenich et al. 2011).

Noteworthy in our bicortical groups is that one construct of the bicortical group failed early at 116N due to knot failure. Without this the mean load of failure would be $332 \pm 44\text{N}$ which is similar to previous reported results of the bicortical fixation. Fracture avulsion of the anterior cortex was only found in one single specimen at maximal load to failure. The load to failure of these technique and our described results are higher than the native tendon as described by Idler and colleagues (Idler et al. 2006). Tendon re-rupture is seldomly seen due to the high initial fixation strength of currently used techniques (Kelly, Morrey et al. 2000). The new button yields the same initial fixation strength as most other techniques (Mazzocca, Burton et al. 2007, Siebenlist, Lenich et al. 2011, Idler, Montgomery et al. 2006). This allows for immediate postoperative mobilization and loading.

One possible concern with the new button is the risk of toggling of the button in larger radius during the insertion. Fluoroscopy is used to ensure proper positioning.

There are some limitations of our study. First, the human cadaveric specimens were of an older age than the typical age for distal biceps ruptures, but comparable with the specimen age in other studies. It is possible that in younger specimens with better bone quality, less failures with bony avulsions would occur. This may be especially relevant for classical intramedullary buttons where this was the predominant failure mode. Even in these older specimens a clear difference is present between the new button and the classical button. Second, a relatively small group of specimens was used although this is comparable to other reported biomechanical studies.

CONCLUSION

The new intramedullary fixation device yields comparable loads to failure compared to currently used techniques, when tested in a biomechanical in vitro setup. These findings together with the theoretical advantages suggest that this technique might be a valuable solution in distal biceps tendon rupture repair.

REFERENCES

- Sarda, P., et al. (2013). "Distal biceps tendon rupture: current concepts." *Injury* **44**(4): 417-420.
- Safran, M. R. and S. M. Graham (2002). "Distal biceps tendon ruptures: incidence, demographics, and the effect of smoking." *Clin Orthop Relat Res*(404): 275-283.
- Schmidt, C. C., et al. (2013). "The distal biceps tendon." *J Hand Surg Am* **38**(4): 811-821; quiz 821.
- Baker, B. E. and D. Bierwagen (1985). "Rupture of the distal tendon of the biceps brachii. Operative versus non-operative treatment." *J Bone Joint Surg Am* **67**(3): 414-417.
- Chillemi, C., et al. (2007). "Rupture of the distal biceps brachii tendon: conservative treatment versus anatomic reinsertion--clinical and radiological evaluation after 2 years." *Arch Orthop Trauma Surg* **127**(8): 705-708.
- Lynch, S. A., et al. (1999). "Repair of distal biceps tendon rupture with suture anchors." *Knee Surg Sports Traumatol Arthrosc* **7**(2): 125-131.
- Morrey, B. F., et al. (1985). "Rupture of the distal tendon of the biceps brachii. A biomechanical study." *J Bone Joint Surg Am* **67**(3): 418-421.
- Bain, G. I., et al. (2000). "Repair of distal biceps tendon rupture: a new technique using the Endobutton." *J Shoulder Elbow Surg* **9**(2): 120-126.
- Siebenlist, S., et al. (2019). "Intramedullary Cortical Button Repair for Distal Biceps Tendon Rupture: A Single-Center Experience." *J Hand Surg Am* **44**(5): 418 e411-418 e417.
- Mazzocca, A. D., et al. (2007). "Biomechanical evaluation of 4 techniques of distal biceps brachii tendon repair." *Am J Sports Med* **35**(2): 252-258.
- Sethi, P., et al. (2010). "Biomechanical evaluation of distal biceps reconstruction with cortical button and interference screw fixation." *J Shoulder Elbow Surg* **19**(1): 53-57.
- Lo, E. Y., et al. (2011). "The effect of drill trajectory on proximity to the posterior interosseous nerve during cortical button distal biceps repair." *Arthroscopy* **27**(8): 1048-1054.

- Schmidt, C. C., et al. (2010). "The effect of biceps reattachment site." *J Shoulder Elbow Surg* **19**(8): 1157-1165.
- Sethi, P. M. and J. E. Tibone (2008). "Distal biceps repair using cortical button fixation." *Sports Med Arthrosc Rev* **16**(3): 130-135.
- Grewal, R., et al. (2012). "Single versus double-incision technique for the repair of acute distal biceps tendon ruptures: a randomized clinical trial." *J Bone Joint Surg Am* **94**(13): 1166-1174.
- Kelly, E. W., et al. (2000). "Complications of repair of the distal biceps tendon with the modified two-incision technique." *J Bone Joint Surg Am* **82-A**(11): 1575-1581.
- Dunphy, T. R., et al. (2017). "Surgical Treatment of Distal Biceps Tendon Ruptures: An Analysis of Complications in 784 Surgical Repairs." *Am J Sports Med* **45**(13): 3020-3029.
- Schmidt, C. C., et al. (2012). "Repaired distal biceps magnetic resonance imaging anatomy compared with outcome." *J Shoulder Elbow Surg* **21**(12): 1623-1631.
- Siebenlist, S., et al. (2011). "Biomechanical in vitro validation of intramedullary cortical button fixation for distal biceps tendon repair: a new technique." *Am J Sports Med* **39**(8): 1762-1768.
- Volk, C., et al. (2019). "[Intramedullary button refixation of the distal biceps tendon in a single incision technique : Surgical technique (approach of the authors)]." *Unfallchirurg* **122**(10): 812-813.
- Idler, C. S., et al. (2006). "Distal biceps tendon repair: a biomechanical comparison of intact tendon and 2 repair techniques." *Am J Sports Med* **34**(6): 968-974.

CHAPTER 8

CLINICAL EVALUATION OF THE INTRAMEDULLARY FIXATION DEVICE

CLINICAL EVALUATION OF THE INTRAMEDULLARY FIXATION DEVICE

SUMMARY

Intramedullary fixation in distal biceps tendon repair may be a solution to address specific shortcomings of current fixation techniques. Most investigations are limited to biomechanical evaluation. We evaluated functional and radiographic outcomes at up to 6 months of follow-up. Patients with an acute distal biceps tendon rupture eligible for surgical repair were invited to take part in the study. Ten patients were included in the final analysis. There were no failures of fixation in the patient group examined. Elbow mobility was symmetrical for all patients from 3 months onward. Supination strength was 86% of the uninjured side at final follow-up. The mean Disabilities of the Arm, Shoulder and Hand score and Mayo Elbow Performance Score at final follow-up were 0 and 100, respectively. Computed tomography images showed no signs of button migration, cortical thinning due to button pressure, or button breakout. The tendon could be followed to the button in all cases. The intramedullary fixation button technique to repair the distal biceps tendon has excellent functional outcomes at 6 months. No adverse reactions of the button on the bone were seen. As this technique minimizes the risk of posterior interosseous nerve injury and has a sufficient bone tunnel to avoid gap formation, this may be a promising new technique for distal biceps tendon rupture refixation.

In vivo evaluation of a new intramedullar distal biceps tendon fixation device.

Pieter Caekebeke¹, Kira Vande Voorde¹, Joris Duerinckx¹, and Roger van Riet^{2,3,4}

¹Department of Orthopedic Surgery and Traumatology, Ziekenhuis Oost-Limburg, Genk, Belgium

²Department of Orthopedic Surgery, AZ Monica, Antwerp

³Department of Orthopedic Surgery, University Hospital Antwerp, Edegem, Belgium

⁴Orthopaedic Specialists, Harley Street Specialist Hospital, 18-22 Queen Anne St, London W1G 8HU, United Kingdom

Journal of Shoulder and Elbow surgery. 2021, 30(12):2869-2874

INTRODUCTION

Early primary repair of distal biceps tendon (DBT) ruptures is usually indicated in complete ruptures, to ensure optimal recovery of supination and flexion strength and endurance (Baker et al. 1985, Chillemi et al. 2007). Single and double incision approaches have been described. Single incision techniques have gained popularity due to the lower risk of heterotopic ossification or even radio-ulnar synostosis compared to double-incision techniques (Amarasooriya et al. 2020, Failla et al. 1990, Watson et al. 2014). Various fixation devices have been described, including suture anchors, interference screws and fixation buttons (Bain et al. 2000, Lynch et al. 1999, Morrey et al. 1985, Mazzocca et al. 2007, Siebenlist et al. 2015). The bicortical button technique as described by Bain and colleagues (Bain, Prem et al. 2000) offers the highest load to failure (Mazzocca, Burton et al. 2007). This allows for early range of motion and loading, immediately after surgery. This technique, however, does not allow an anatomic reinsertion of the DBT as it would put the posterior interosseous nerve (PIN) at significant risk for entrapment behind the cortical button with PIN palsies being reported up to 1,6% (Amarasooriya, Bain et al. 2020, Lo et al. 2011, Besmens et al. 2021). In order to protect the nerve, it is advised to reattach the tendon more anteriorly on the radial

tuberosity. Although this is safer for the nerve, this decreases final supination strength (Schmidt et al. 2010, Bellringer et al. 2020). Intramedullary or on-lay fixation have been advised to achieve a more anatomic reinsertion (Bellringer et al. 2020, Siebenlist et al. 2011). Initial fixation strength of these techniques is lower and they do not allow an intraosseous fixation as seen with the Endobutton technique (Bain et al. 2000). This increases the risk of gap formation between the tendon stump and the radial bone during active biceps contraction, delaying rehabilitation (Mazzocca, Burton et al. 2007, Rashid et al. 2016). We recently proposed a new design of intramedullary tendon fixation that considers these problems while still offering a high load to failure (Caekebeke et al. 2020).

The purpose of the present study is to report our first in vivo experience with this new device.

MATERIAL AND METHODS

Patient selection and follow-up

This is a retrospective case-control study performed in a single center. After internal review board approval, ten consecutive DBT repairs were included. These included 9 males and 1 female patient. In two cases, surgery was performed for a high grade partial DBT rupture not responding to conservative treatment. The tendon was completely detached in these patients and reinsertion was performed as described below. All patients were seen at 2 weeks, 6 weeks, 3 months and 6 months follow up. Passive and active range of motion of the elbow and forearm were measured using a handheld goniometer. The distance from the elbow crease to the biceps muscle belly was measured at every follow-up (biceps crease interval). From 6 weeks onwards, supination strength was measured in full supination with the elbow in 90° of flexion using a pronation-supination dynamometer (Baseline[®] hydraulic wrist dynamometer, Arex). Strength measurements

were noted as a percentage of the contralateral side. Functional evaluation included the Mayo Elbow Performance Score (MEPS), the Dutch version of the Disabilities of the Arm, Shoulder and Hand (DASH) questionnaire, and the visual analog scale for pain both in rest and with active biceps contraction. The MEPS is a widely applied measure of function of the elbow. It is a clinician-completed score that includes 4 categories: pain, motion, stability, and the ability to perform 5 functional tasks. The DASH score is a validated patient-oriented rating scale that analyzes factors involved in activities of daily living, followed by optional questions. Possible complications were recorded. Radiographic evaluation was performed at 2 weeks and 3 months postop to ensure correct positioning of the button. A CT scan was done at 6 months to evaluate implant positioning and effect of the button on the anterior cortex. Furthermore, cortex closure around the tendon and cortex reaction to the button was evaluated by measuring the drill hole width at the outer edge of the anterior cortex and at the button. Distribution of variables is given as mean, standard deviation and range.

Button design

The button design was used following the previous reported dimensions (Caekebeke, Duerinckx et al. 2020) and printed in titanium by a commercial company specialized in titanium implant for maxillofacial surgery. (Figure 1) The design features a bell shape of 3mm to allow insertion of the button through an 8mm drill hole on the proximal cortex. The button has a width of 4mm and a length of 24 mm to span the radial tuberosity. This length also allows purchase on the thick cortical bone alongside the thinner bone of the tuberosity.



Figure 1: The fixation device

Surgical technique

Surgical exploration was performed through a 3-cm longitudinal incision starting centrally 3cm distal to the elbow crease and extending distally. In case of marked proximal retraction or adherence of the distal biceps tendon stump, a secondary 1cm incision was made at the site of the stump and the tendon was passed distally to the initial incision. After debridement of the biceps tendon to healthy tissue, a partially absorbable suture (FiberLoop 2; Arthrex, Naples, FL, USA) was passed in a whipstitch fashion in the distal 20 mm of the tendon so that its ends emerged at the distal tendon end. With the forearm held in hyper supination, a guide pin (1.6 mm Kirshner wire) was drilled perpendicular through the radial tuberosity until it touched the opposite cortex. Care was

taken that the drill guide did not perforate the opposite cortex to prevent damage to the posterior interosseous nerve. The reinsertion site was non-anatomical for this first in vivo testing. If the new construct would have failed a conversion to a bicortical technique would still be possible. The guidewire was then over-reamed through the anterior cortex with an 8 mm cannulated drill bit. The depth of this bone tunnel was to the posterior cortex. Extensive lavage with 500ml of saline was performed after removal of visible bone debris. The intramedullary canal was opened with the use of a curved clamp. Next the button was loaded on the free suture ends of the FiberLoop suture-tendon construct. The button was then inserted into the bone tunnel using a mosquito clamp. The button was centered under the bone tunnel by pulling on both sutures simultaneously. In this way, the button flips to engage the anterior cortex of the radial tuberosity. (Figure 2A-G)

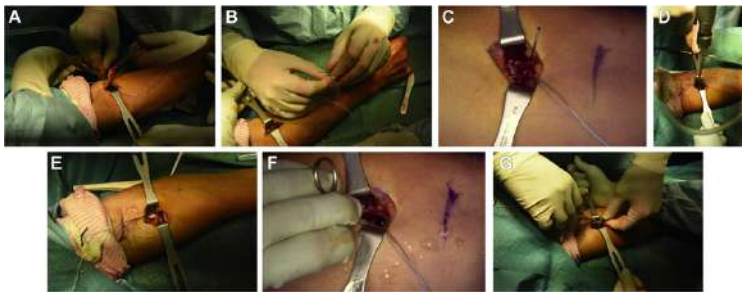


Figure 2: Surgical steps **A** Suture is passed in the distal 20mm of tendon stump. **B:** Button is loaded unto suture ends. **C:** Guide pin is drilled perpendicular to the tuberosity in hyper supination. **D-E:** A 8mm unicortical hole is drilled. **F:** the medullary canal is opened using a curved mosquito clamp. **G:** the button is inserted using a mosquito clamp.

Once the button was positioned correctly, the tendon was pulled into the radius by pulling both sutures separately, using the tension slide technique described by Sethi (Sethi et al. 2008). One of the suture ends was passed through the tendon with a free needle and then tied to the remaining suture end onto the button using a knot pusher. Fluoroscopy was

used to confirm the correct final position of the button. Prior to wound closure, further rinsing and hemostasis was performed. Active and passive mobilization was allowed the day after surgery. Physiotherapy was started from two weeks onward. Muscle strengthening commenced at two months postoperatively. Controlled, unlimited lifting was allowed at three months. Sport activities were allowed at five months.

RESULTS

All patients had a trauma mechanism suggestive of excessive eccentric loading of a flexed and supinated arm. Patient demographics are listed in Table 1. The mean time to surgery was 9 days for the patients with complete ruptures (range, 1-17 days). Of the two patients with partial tendon ruptures, one was operated 3 months and the other 1,5 years after trauma. Four patients (40%) experienced temporary hypoesthesia in the innervation area of the lateral antebrachial cutaneous nerve. This resolved in all cases. No heterotopic ossification was observed in this series. At two weeks after surgery, all patients had full elbow flexion and an average active (and passive) extension deficit of 10° (range 0°-20°). All patients recovered full extension at six weeks postoperative. An average active pronation deficit of 26° (range 0°-50°) was present at the two-week follow-up. At six weeks one patient still had a pronation deficit of 10°. All patients recovered full active and passive pronation 3 months postoperatively. The average VAS score for pain at two weeks after surgery was 1 (range 0-2) in rest and 4 (range 3-7) with active supination. No patient experienced pain at six weeks after surgery. The average biceps crease interval was 2,6 cm (range 1,5 cm-3 cm) and was constant in each patient in every follow-up. The average supination strength at six weeks was 44% (range 25%-72%), 71% at three months (range 44%-88%) and 86% (range 83%-100%) at six months.

Variable	Demographic data	Outcomes			
		2 weeks	6 weeks	3 mo	6 mo
Age, yr	52 ± 11				
Male sex	9				
Side					
Dominant	8				
Nondominant	2				
Extension, °		10 ± 9	0	0	0
Flexion, °		135	135	135	135
Pronation, °		26 ± 12	89 ± 3	90	90
Supination, °		90	90	90	90
Supination strength, %		—	44 ± 8	71 ± 15	86 ± 12
Biceps crease interval, cm		2.6 ± 0.3	2.6 ± 0.3	2.6 ± 0.3	2.6 ± 0.3
DASH score		24 ± 11	7 ± 6	0	0
MEPS		87 ± 7	100	100	100

DASH, Disabilities of the Arm, Shoulder and Hand; *MEPS*, Mayo Elbow Performance Score.

Continuous data are presented as mean ± standard deviation, and categorical data are presented as number.

Table 1: Demographics, functional and clinical outcomes.

Radiographic evaluation at 6 weeks showed no migration of the button or button breakout. No adverse cortical reactions. (Figure 3) CT evaluation of the proximal radius was performed six months after surgery in 9 patients. (Figure 4) One patient refused CT imaging due to active chemotherapy at that time. There were no signs of button migration, cortical thinning due to button pressure or button breakout. Average drill hole width was 7,8mm (range 7,6mm-8,1mm) at the outer edge of the anterior cortex and 7,6mm (range 7,3mm-7,9mm) at the button.

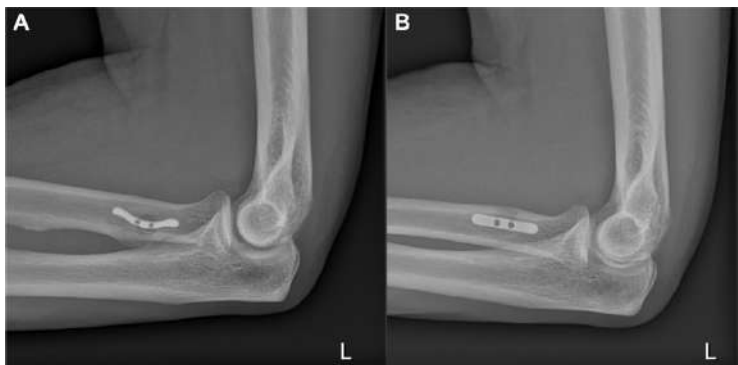

Figure 3 A-B: Radiographic follow-up at 2 weeks. No signs of cortex breakthrough and centralization of the button at the drill hole.

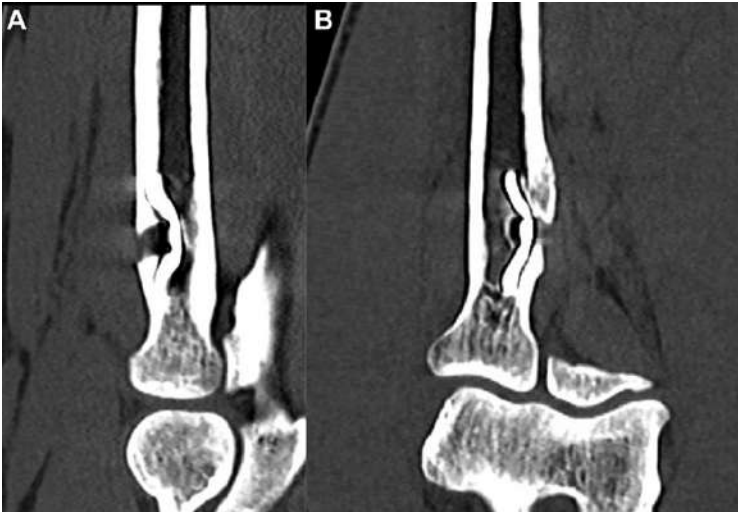

Figure: CT image at 6 months. The oblique tunnel in image **A** shows the way the tendon adheres. **B** shows a centralization of the button at the drill hole.

DISCUSSION

Various implants have been used to repair a complete distal biceps tendon rupture through a single anterior incision (Bain et al. 2000, Mazzocca et al. 2007, Caekebeke et al. 2016, Caekebeke et al. 2016). The bicortical button technique is widely preferred due to its high load to failure allowing early range of motion (Mazzocca et al. 2007); Due to its inherent risk of posterior interosseous nerve injury authors have proposed intramedullar fixation devices yielding similar loads to failure (Siebenlist, Elser et al. 2011, Caekebeke et al. 2020). The purpose of present study was to evaluate and report the first in vivo result of a new intramedullar button (Caekebeke et al. 2020).

Short-term functional outcomes at two weeks, six weeks and three months in present study were comparable to our experiences with the bicortical technique. Functional outcomes at six months were excellent and comparable to the reported outcomes of other

intramedullary fixation methods (Siebenlist et al. 2011, Siebenlist et al. 2019). Supination strength in maximal supination was on average 86% of the contralateral uninjured side. This may be explained by the non-anatomical reinsertion (Schmidt et al. 2010). These findings compare to previously reported outcomes of non-anatomical reinsertion techniques (Chavan et al. 2008). Quick-DASH and MEPS outcome scores were excellent for all patients. These scores are slightly better than other studies (Chillemi et al. 2007, Caekebeke et al. 2016, Dunphy et al. 2017, Peeters et al. 2009) but this may be influenced due to the fact the patients in this study knew this was an evaluation of a new technique. We suspect that knowledge of the purpose of this study may have influenced the outcome score submitted by our patients.

The only complication noted in our study was a transient LACN neuropraxia. This minor complication is seen quite often in a limited anterior incision (reported range 7%-57%) (Amarasooriya et al. 2020, Caekebeke et al. 2016), and typically resolves spontaneously, as it did in our patients. Heterotopic ossification is more often described in a double-incision technique than the single-incision technique (Kelly et al. 2000). We did not observe this in our series. Although low incidence has been reported with the single incision technique (Amarasooriya et al. 2020), we believe that removal of bone debris after drilling, extensive lavage and haemostasis are paramount to avoid heterotopic bone formation. PIN injury has been reported to be 0.3% (Amarasooriya et al. 2020). Although rare, this complication may be disastrous. We saw no PIN injuries in this series. This is inherent to the intramedullary placed button. As the posterior cortex is not breached and no retractors are placed posterior to the radius, the risk of PIN injury is minimized (Becker et al. 2019).

Radiographic evaluation showed no migration of the button during the postoperative period. This may indicate that at the least the button is connected to the tendon, whether

by an intact repair or with the sutures. The intramedullary repair described in this study should decrease the chance of gap formation described, with anchors or onlay techniques (Rashid et al. 2016). Furthermore, CT evaluation showed no closure of the bone tunnel. Slight closure was seen in all tunnels, indicating repair of the bone around the tunnel but none of the tunnels had closed completely. Soft tissue views of the CT images allow us to follow the tendon to the bone in all cases. Previous investigation in ACL surgery reported healing of the bone tunnel at six months (Nebelung et al. 2003). We do not suspect further changes after this time.

There are several limitations to the present study. First, the study cohort was small. We chose a small cohort due to the novelty of this technique. Further investigation is needed to confirm these results on a larger scale. Second, a non-anatomical repair was preferred for the current investigation. This allows conversion to a standard Endobutton technique if the new construct would have failed. This was not needed in our group. Theoretically, the intramedullary fixation will allow for an anatomical fixation of the ruptured distal biceps tendon. The next logical step will be to evaluate this fixation with an anatomical reinsertion and comparison of the functional results of both reinsertion sites. Third, supination strength was reported as a percentage compared to uninjured contralateral side. We used this technique as it is the commonly reported method. However, no data is available on the exact difference of supination strength between the dominant and non-dominant side. Finally, we only have a relatively short follow-up. As tunnel healing is reported to be complete at six months after surgery, and we saw no differences in functional outcomes between three and six months we do not think longer follow-up will have a significant effect on the results presented.

CONCLUSION

The intramedullary fixation button technique to repair the distal biceps tendon has excellent functional outcomes at six months. No adverse reactions of the button on the bone were seen. As this technique minimizes the risk of PIN injury and has sufficient bone tunnel to avoid gap formation this may be a promising new technique for distal biceps tendon ruptures.

REFERENCES

- Baker, B. E. and D. Bierwagen (1985). "Rupture of the distal tendon of the biceps brachii. Operative versus non-operative treatment." *J Bone Joint Surg Am* **67**(3): 414-417.
- Chillemi, C., et al. (2007). "Rupture of the distal biceps brachii tendon: conservative treatment versus anatomic reinsertion--clinical and radiological evaluation after 2 years." *Arch Orthop Trauma Surg* **127**(8): 705-708.
- Amarasooriya, M., et al. (2020). "Complications After Distal Biceps Tendon Repair: A Systematic Review." *Am J Sports Med* **48**(12): 3103-3111.
- Failla, J. M., et al. (1990). "Proximal radioulnar synostosis after repair of distal biceps brachii rupture by the two-incision technique. Report of four cases." *Clin Orthop Relat Res*(253): 133-136.
- Watson, J. N., et al. (2014). "Repair techniques for acute distal biceps tendon ruptures: a systematic review." *J Bone Joint Surg Am* **96**(24): 2086-2090.
- Bain, G. I., et al. (2000). "Repair of distal biceps tendon rupture: a new technique using the Endobutton." *J Shoulder Elbow Surg* **9**(2): 120-126.
- Lynch, S. A., et al. (1999). "Repair of distal biceps tendon rupture with suture anchors." *Knee Surg Sports Traumatol Arthrosc* **7**(2): 125-131.
- Morrey, B. F., et al. (1985). "Rupture of the distal tendon of the biceps brachii. A biomechanical study." *J Bone Joint Surg Am* **67**(3): 418-421.
- Mazzocca, A. D., et al. (2007). "Biomechanical evaluation of 4 techniques of distal biceps brachii tendon repair." *Am J Sports Med* **35**(2): 252-258.
- Siebenlist, S., et al. (2015). "Double intramedullary cortical button versus suture anchors for distal biceps tendon repair: a biomechanical comparison." *Knee Surg Sports Traumatol Arthrosc* **23**(3): 926-933.

Lo, E. Y., et al. (2011). "The effect of drill trajectory on proximity to the posterior interosseous nerve during cortical button distal biceps repair." *Arthroscopy* **27**(8): 1048-1054.

Besmens, I. S., et al. (2021). "Management of posterior interosseous nerve (PIN) palsies after distal biceps tendon repair using a single incision technique- a conclusive approach to diagnostics and therapy." *J Plast Surg Hand Surg*: 1-6.

Schmidt, C. C., et al. (2010). "The effect of biceps reattachment site." *J Shoulder Elbow Surg* **19**(8): 1157-1165.

Bellringer, S. F., et al. (2020). "Biomechanical comparison of transosseous cortical button and Footprint repair techniques for acute distal biceps tendon ruptures." *Shoulder Elbow* **12**(1): 54-62.

Siebenlist, S., et al. (2011). "The double intramedullary cortical button fixation for distal biceps tendon repair." *Knee Surg Sports Traumatol Arthrosc* **19**(11): 1925-1929.

Rashid, A., et al. (2016). "Failure of distal biceps repair by gapping." *Shoulder Elbow* **8**(3): 192-196.

Caekebeke, P., et al. (2020). "A new intramedullary fixation method for distal biceps tendon ruptures: a biomechanical study." *J Shoulder Elbow Surg*.

Sethi, P. M. and J. E. Tibone (2008). "Distal biceps repair using cortical button fixation." *Sports Med Arthrosc Rev* **16**(3): 130-135.

Caekebeke, P., et al. (2016). "Radiological and Clinical Evaluation of the Transosseous Cortical Button Technique in Distal Biceps Tendon Repair." *J Hand Surg Am* **41**(12): e447-e452.

Caekebeke, P., et al. (2016). "Distal biceps tendon repair: comparison of clinical and radiological outcome between bio-absorbable and non-absorbable screws." *J Shoulder Elbow Surg*: accepted for publication.

Siebenlist, S., et al. (2019). "Intramedullary Cortical Button Repair for Distal Biceps Tendon Rupture: A Single-Center Experience." *J Hand Surg Am* **44**(5): 418 e411-418 e417.

Chavan, P. R., et al. (2008). "Repair of the ruptured distal biceps tendon: a systematic review." *Am J Sports Med* **36**(8): 1618-1624.

Dunphy, T. R., et al. (2017). "Surgical Treatment of Distal Biceps Tendon Ruptures: An Analysis of Complications in 784 Surgical Repairs." *Am J Sports Med* **45**(13): 3020-3029.

Peeters, T., et al. (2009). "Functional outcome after repair of distal biceps tendon ruptures using the endobutton technique." *J Shoulder Elbow Surg* **18**(2): 283-287.

Kelly, E. W., et al. (2000). "Complications of repair of the distal biceps tendon with the modified two-incision technique." *J Bone Joint Surg Am* **82-A**(11): 1575-1581.

Becker, D., et al. (2019). "How to avoid posterior interosseous nerve injury during single-incision distal biceps repair drilling." *Clin Orthop Relat Res* **477**: 424-431.

Nebelung, W., et al. (2003). "Histological findings of tendon-bone healing following anterior cruciate ligament reconstruction with hamstring grafts." *Arch Orthop Trauma Surg* **123**(4): 158-163.

CHAPTER 9

DOES INTRAMEDULLAR ANATOMICAL REINSERTION LEAD TO BETTER SUPINATION STRENGTH?

DOES INTRAMEDULLAR ANATOMICAL REINSERTION LEAD TO BETTER SUPINATION STRENGTH?

SUMMARY

Intramedullar fixation in distal biceps tendon repair has been proposed to address specific shortcomings of current fixation techniques. Previous studies described a non-anatomical repair. We evaluated functional and radiographic outcomes at up to 6 months of follow-up. Patients with an acute distal biceps tendon rupture eligible for surgical repair were invited to take part in the study. Eleven patients were included in the final analysis. There were no failures of fixation in the patient group examined. Elbow mobility was symmetric for all patients from 6 months onwards. Supination strength was similar to the uninjured side at final follow-up. Mean Disabilities of the Arm, Shoulder, and Hand score and Mayo Elbow Performance Score at final follow-up were 0 and 100, respectively. Computed tomography images showed no signs of button migration, cortical thinning due to button pressure or button breakout. The tendon could be followed to the button in all cases. One case of heterotopic ossification was seen. Anatomical intramedullary fixation of the DBT has excellent functional outcomes at six months. The anatomical repair resulted in a restoration of supination strength. This technique allows an anatomical reinsertion of the distal biceps tendon while minimizing the risk of PIN injury. The intraosseous position of the tendon avoids gap formation. No adverse reactions of the button on the bone were seen.

Anatomical intramedullar distal biceps tendon fixation. Our first experience.

Pieter Caekebeke¹, Laurens Van Melkebeke¹, Joris Duerinckx¹ and Roger van Riet^{2,3,4}

¹Department of Orthopaedics Surgery and Traumatology, Ziekenhuis Oost-Limburg, Genk, Belgium

²Department of Orthopedic Surgery, AZ Monica, Antwerp

³Department of Orthopedic Surgery, University Hospital Antwerp, Edegem, Belgium

⁴Orthopaedic Specialists, Harley Street Specialist Hospital, 18-22 Queen Anne St, London W1G 8HU, United Kingdom

Journal of Shoulder and Elbow surgery international. Accepted for publication

INTRODUCTION

Early primary repair of distal biceps tendon (DBT) ruptures is usually indicated in complete ruptures, to ensure optimal recovery of supination and flexion strength and endurance (Baker et al. 1985, Chillemi et al. 2007). Single and double incision approaches have been described. Single incision techniques have gained popularity due to the lower risk of heterotopic ossification and radio-ulnar synostosis compared to double-incision techniques (Amarasooriya et al. 2020, Failla et al. 1990, Watson et al. 2014). Fixation devices with a high initial load to failure (Mazzocca et al. 2007) allow early range of motion and loading, immediately after surgery. The bicortical button as described by Bain et al offers the highest load to failure (Bain et al. 2000). The bicortical button technique does not allow an anatomic reinsertion of the DBT as it would put the posterior interosseous nerve (PIN) at significant risk for entrapment behind the cortical button with PIN palsies being reported in up to 4,6% (Amarasooriya, Bain et al. 2020, Lo et al. 2011, Besmens et al. 2021). A more anterior reinsertion on the radial tuberosity is advised in order to protect the nerve. This reduces final supination strength as the radial edge of the tuberosity, which acts as a fulcrum point for the DBT, is removed by the drill bit used to make the bone tunnel (Schmidt et al. 2010, Bellringer et al. 2020). We recently

proposed an intramedullar fixation device which theoretically allows an anatomical reinsertion without risk for the PIN (Caekebeke et al. 2020, Caekebeke et al. 2021). The first reported results were favourable. These results were based on a non-anatomical reinsertion (Caekebeke, Vande Voorde et al. 2021). To date, however, no evaluation of an anatomical reinsertion has been performed.

The purpose of present study is to evaluate the short-term outcomes of an anatomical reinsertion using this intramedullar fixation device.

MATERIAL AND METHODS

Patient selection and follow-up

This is a retrospective case-control study performed in a single center. After internal review board approval, eleven consecutive DBT repairs were included. All patients were male. All patients had a complete distal biceps tendon rupture. Patients were seen at 2 weeks, 6 weeks, 3 months and 6 months follow up. Passive and active range of motion of the elbow and forearm were measured using a handheld goniometer. The distance from the elbow crease to the biceps muscle belly was measured at every follow-up (biceps crease interval). From 6 weeks onwards, supination strength was measured in full supination with the elbow in 90° of flexion using a pronation-supination dynamometer (Baseline □ hydraulic wrist dynamometer, Arex). Strength measurements were noted as a percentage of the contralateral side. Functional evaluation included the Mayo Elbow Performance Score (MEPS), the Dutch version of the Disabilities of the Arm, Shoulder and Hand (DASH) questionnaire, and the visual analog scale for pain both in rest and with active biceps contraction. The MEPS is a widely applied measure of function of the elbow. It is a clinician-completed score that includes 4 categories: pain, motion, stability, and the ability to perform 5 functional tasks. The DASH score is a validated patient-oriented rating scale that analyzes factors involved in activities of daily living, followed by optional questions. Possible complications such as LACN

neuropraxia, PIN damage, heterotopic ossification and rerupture rates were recorded. Radiographic evaluation was performed at 2 weeks and 3 months postop to ensure correct positioning of the button. A CT scan was done at 6 months to evaluate implant positioning and effect of the button on the anterior cortex by comparing it with the preoperative radiographs. Furthermore, cortex closure around the tendon and cortex reaction to the button was evaluated by measuring the drill hole width at the outer edge of the anterior cortex and at the button. Distribution of variables is given as mean, standard deviation and range.

Button design

The button design was used following the previous reported dimensions (Caekebeke, Duerinckx et al. 2020) and printed in titanium by a commercial company specialized in titanium implant for maxillofacial surgery (Figure 1). The design features a bell shape with an offset height of 3mm at its center to allow insertion of the button through an 8mm drill hole on the proximal cortex. The button has a width of 4mm and a length of 24 mm to span the radial tuberosity. This length also allows purchase on the thick cortical bone alongside the thinner bone of the tuberosity.



Figure 1: The fixation device

Surgical technique

Surgical exploration was performed through a 3-cm longitudinal incision starting centrally 3cm distal to the elbow crease and extending distally. In case of marked proximal retraction or adherence of the distal biceps tendon stump, a secondary 1cm incision was made at the site of the stump and the tendon was passed distally to the initial incision. After debridement of the biceps tendon to healthy tissue, a partially absorbable suture (FiberLoop 2; Arthrex, Naples, FL, USA) was passed in a whipstitch fashion in the distal 20 mm of the tendon so that its ends emerged at the distal tendon end. With the forearm held in hypersupination, a guide pin (1.6 mm Kirshner wire) was drilled through the radial tuberosity starting as far ulnar as possible, aiming oblique towards the radial cortex, until it touched the opposite cortex. The angle to the bone needs to be at least 45°.

This creates a hole to the medullar canal in which the device can be inserted. A too shallow angle would not create a hole but would ream the cortex. As we could not drill the guide wire and reamer in the posteromedial facet of the tuberosity with great enough angle, the native site of tendon insertion could not be achieved but was approximated as close as possible. The aim was to reinsert the tendon as ulnarly as possible with the cam of the tuberosity preserved. Care was taken that the drill guide did not perforate the opposite cortex to prevent damage to the posterior interosseous nerve. The guidewire was then over-reamed through the anterior cortex with an 8 mm cannulated drill bit. The depth of this bone tunnel was to the posterior cortex. Extensive lavage with 500ml of saline was performed after removal of visible bone debris. The intramedullary canal was opened with the use of a curved clamp. Next the button was loaded on the free suture ends of the FiberLoop suture-tendon construct. The button was then inserted into the bone tunnel using a mosquito clamp. The button was centered under the bone tunnel by pulling on both sutures simultaneously. In this way, the button flips to engage the anterior cortex of the radial tuberosity. Once the button was positioned correctly, the tendon was pulled into the radius by pulling both sutures separately, using the tension slide technique described by Sethi.²³ One of the suture ends was passed through the tendon with a free needle and then tied to the remaining suture end onto the button using a knot pusher. Fluoroscopy was used to confirm the correct final position of the button. Prior to wound closure, further rinsing and hemostasis was performed. Active and passive mobilization was allowed the day after surgery. Physiotherapy was started from two weeks onward. Muscle strengthening commenced at two months postoperatively. Controlled, unlimited lifting was allowed at three months. Sport activities were allowed at five months.

RESULTS

All patients had a trauma mechanism suggestive of excessive eccentric loading of a flexed and supinated arm. Patient demographics are listed in Table 1.

Variable	Demographic data	Outcomes			
		2 weeks	6 weeks	3 mo	6 mo
Age	46 ± 9				
Male sex	11				
Side					
Dominant	7				
Nondominant	4				
Extension °		10 ± 9	1	0	0
Flexion °		135	135	135	135
Pronation °		50 ± 12	80 ± 3	88 ± 1	90
Supination °		90	90	90	90
Supination strength (%)		7	57% ± 25	78% ± 14	99% ± 2
Biceps crease distance (CM)		2,4 ± 0,2	2,4 ± 0,2	2,4 ± 0,2	2,4 ± 0,2
DASH		29 ± 20	4 ± 6	1 ± 4	0
MEPS		86 ± 6	98 ± 4	100	100

DASH, Disabilities of Arm, Shoulder, and Hand; MEPS, Mayo Elbow Performance Score; PEEK

Continuous data are shown as the mean ± standard deviation and categorical data as number.

Table 1: Demographics, functional and clinical outcomes.

The average age was 46 years (range 42-61). The mean time to surgery was 4 days for the patients with complete ruptures (range, 1-8 days). Four patients (36%) experienced temporary hypoesthesia in the innervation area of the lateral antebrachial cutaneous nerve. This resolved in all cases. Heterotopic ossification was seen in one patient (9%). As the ossification did not limit motion or function, no further treatment was required. At two weeks after surgery, all patients had full elbow flexion and supination. The average active (and passive) extension deficit at two weeks was 10° (range 0°-20°). One patient had an extension deficit of five degrees at six weeks. All patients recovered full extension at three months postoperative. An average active pronation deficit of 40° (range 0°-70°) was present at the two-week follow-up. An average active pronation deficit of 10° (range 0°-35°) was present at the six-week follow-up. At three months one patient still had a pronation deficit of 10°. All patients recovered full active and passive pronation six months postoperatively. The average VAS score for pain at two weeks after surgery was 1 (range 0-2) in rest and 4 (range 3-6) with active supination. No patient

experienced pain at six weeks after surgery. The average biceps crease interval was 2,8 cm (range 2 cm-3 cm) and was constant in each patient in every follow-up. The average supination strength at six weeks was 57% (range 40%-81%), 78% at three months (range 62%-90%) and 99% (range 92%-107%) at six months. One patient had shoulder surgery at the same side 6 weeks after the distal biceps repair which made strength testing at 3 months impossible. At 6 months after surgery, strength was still less than the contralateral side (89%). Radiographic evaluation at 6 weeks showed no migration of the button or button breakout. No adverse cortical reactions. (Figure 2)

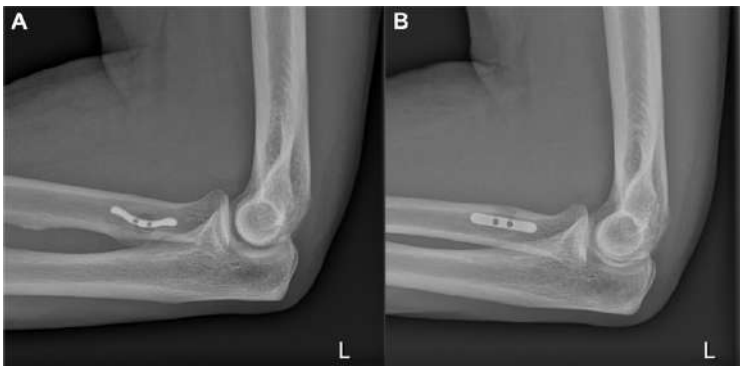

Figure 2 A-B: Radiographic follow-up at 2 weeks. No signs of cortex breakthrough and centralization of the button at the drill hole.

CT evaluation of the proximal radius was performed six months after surgery in all patients. There were no signs of button migration, cortical thinning due to button pressure or button breakout. Average drill hole width was 7,7mm (range 7,5mm-8mm) at the outer edge of the anterior cortex and 7,5mm (range 7,2mm-7,8mm) at the button.

DISCUSSION

Bicortical button fixation has gained popularity due to its high initial load to failure allowing early range of motion and rehabilitation. The position of the button at the far

side of the radial bone poses an inherent risk of posterior interosseous nerve injury and non-anatomical fixation. Several authors proposed an intramedullar fixation to alleviate the risk of PIN damage and allow an anatomical reinsertion via a single-incision approach. Load to failure and early outcomes of a non-anatomical reinsertion seem favourable. The purpose of the present study was to evaluate and report the short-term outcomes of an intramedullar anatomical reinsertion of the distal biceps tendon.

Functional outcome at two weeks, six weeks and three months in the present study was comparable to our experience with non-anatomical DBT reinsertion with the same intramedullar button (ref?). Functional outcome at six months was excellent and comparable to the reported outcome of other fixation methods (Bain et al. 2000, Caekebeke et al. 2016, Caekebeke et al. 2016, Chavan et al. 2008, Citak et al. 2011). Full pronation was regained later in the rehabilitation period compared to non-anatomical fixation (Caekebeke, Vande Voorde et al. 2021). We believe that this is a result of the anatomical reinsertion site. As the DBT rotates around the radial bone with pronation, the repaired tendon would stretch more with more ulnar (i.e. anatomical) reinsertion. Supination strength in maximal supination was comparable to the contralateral uninjured side and previous reported biomechanical outcomes of anatomical onlay reinsertion. (Bellringer et al. 2020). One patient had slightly less supination strength. However, we believe this was due to the concomitant shoulder operation at the same side. Although the site of the reinsertion of the tendon is not completely at site of the native insertion, we believe that supination strength may be explained by the safeguarding of the radial edge of the tuberosity which acts as a fulcrum (Schmidt et al. 2015) (figure 3). Quick-DASH and MEPS outcome scores were excellent for all patients.

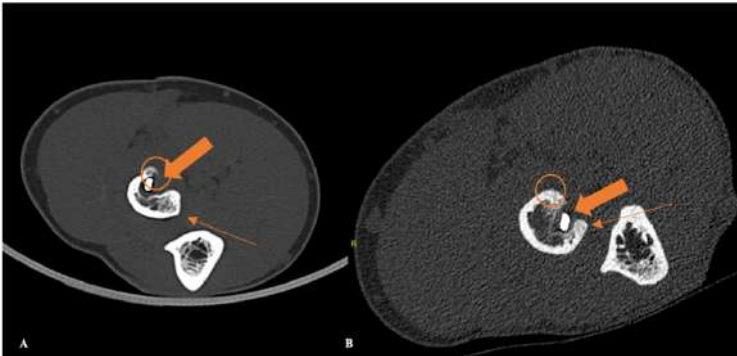


Figure 3A – B: CT image at 6 months. **A:** Non-anatomical repair with the drill hole through the fulcrum point of the radial tuberosity. **B:** Anatomical repair with preservation of the fulcrum point. Fat arrow: orientation of the drill hole and site of tendon reinstitution. Small arrow: Native tendon insertion site. Circle: Cam of the tuberosity acting as a fulcrum point.

We noted a transient LACN neuropraxia in 36% of our cases. This minor complication is seen quite often in a limited anterior incision (reported range 7%-57%) (Amarasooriya, Bain et al. 2020, Caekebeke, Vermeersch et al. 2016) and typically resolves spontaneously, as it did in our patients. Heterotopic ossification is more often described in a double-incision technique than the single-incision technique (Kelly et al. 2000). We did observe a small heterotopic ossification in one patient. We believe this may be due to insufficient lavage at the end of the procedure. As the HO did not limit movement, it was treated expectantly. The removal of bone debris after drilling, extensive lavage and haemostasis remains paramount to avoid heterotopic bone formation. PIN injury has been reported to be 0.3% (Amarasooriya, Bain et al. 2020). Although rare, this complication may be disastrous. We observed no PIN injuries in this series. This is inherent to the intramedullar placed button. As the posterior cortex is not breached and no retractors are placed posterior to the radius, the risk of PIN injury is minimized (Becker et al. 2019).

Radiographic evaluation showed no migration of the button during the postoperative period. We believe this to be an indication that at the least the button is connected to the

tendon, whether by an intact repair or with the sutures. Gap formation is a well described complication of anchor or onlay techniques (Rashid et al. 2016). The intraosseous position of the tendon described in this repair should minimize the risk of gap formation. CT evaluation showed no closure of the bone tunnel. Slight closure is to be expected as the bone repairs around the tendon. Present study showed no complete closure of the bone tunnel after six months. Soft tissue views of the CT images allow us to follow the tendon to the bone in all cases indicating that no gap formation was present (Pelc et al. 2001). Previous investigation in ACL surgery reported healing of the bone tunnel at six months (Nebelung et al. 2003). We do not suspect further changes after this time.

There are several limitations to the present study. First, the study cohort was small. We chose a small cohort due to the novelty of this technique. Further investigation is needed to confirm these results on a larger scale. Second, supination strength was reported as a percentage compared to uninjured contralateral side. We used this technique as it is the commonly reported method. Furthermore, we did not evaluate supination endurance. However, no data is available on the exact difference of supination strength between the dominant and non-dominant side. As the majority of patients had a trauma at the dominant side, this may have influenced the outcomes with a slight overestimation of the supination strength regained at final follow-up. Finally, we only have a relatively short follow-up. As tunnel healing is reported to be complete at six months after surgery, and we saw no differences in functional outcomes between three and six months we do not think longer follow-up will have a significant effect on the results presented.

CONCLUSION

Anatomical intramedullary fixation of the DBT has excellent functional outcomes at six months. The anatomical repair resulted in a restoration of supination strength. This technique allows an anatomical reinsertion of the distal biceps tendon while minimizing

the risk of PIN injury. The intraosseous position of the tendon avoids gap formation. No adverse reactions of the button on the bone were seen.

REFERENCES

- Baker, B. E. and D. Bierwagen (1985). "Rupture of the distal tendon of the biceps brachii. Operative versus non-operative treatment." *J Bone Joint Surg Am* **67**(3): 414-417.
- Chillemi, C., et al. (2007). "Rupture of the distal biceps brachii tendon: conservative treatment versus anatomic reinsertion--clinical and radiological evaluation after 2 years." *Arch Orthop Trauma Surg* **127**(8): 705-708.
- Amarasooriya, M., et al. (2020). "Complications After Distal Biceps Tendon Repair: A Systematic Review." *Am J Sports Med* **48**(12): 3103-3111.
- Failla, J. M., et al. (1990). "Proximal radioulnar synostosis after repair of distal biceps brachii rupture by the two-incision technique. Report of four cases." *Clin Orthop Relat Res*(253): 133-136.
- Watson, J. N., et al. (2014). "Repair techniques for acute distal biceps tendon ruptures: a systematic review." *J Bone Joint Surg Am* **96**(24): 2086-2090.
- Mazzocca, A. D., et al. (2007). "Biomechanical evaluation of 4 techniques of distal biceps brachii tendon repair." *Am J Sports Med* **35**(2): 252-258.
- Lo, E. Y., et al. (2011). "The effect of drill trajectory on proximity to the posterior interosseous nerve during cortical button distal biceps repair." *Arthroscopy* **27**(8): 1048-1054.
- Besmens, I. S., et al. (2021). "Management of posterior interosseous nerve (PIN) palsies after distal biceps tendon repair using a single incision technique- a conclusive approach to diagnostics and therapy." *J Plast Surg Hand Surg*: 1-6.
- Schmidt, C. C., et al. (2010). "The effect of biceps reattachment site." *J Shoulder Elbow Surg* **19**(8): 1157-1165.
- Bellringer, S. F., et al. (2020). "Biomechanical comparison of transosseous cortical button and Footprint repair techniques for acute distal biceps tendon ruptures." *Shoulder Elbow* **12**(1): 54-62.
- Caekebeke, P., et al. (2020). "A new intramedullary fixation method for distal biceps tendon ruptures: a biomechanical study." *J Shoulder Elbow Surg*.
- Caekebeke, P., et al. (2021). "In vivo evaluation of a new intramedullary distal biceps tendon fixation device." *J Shoulder Elbow Surg* **30**(12): 2869-2874.
- Sethi, P. M. and J. E. Tibone (2008). "Distal biceps repair using cortical button fixation." *Sports Med Arthrosc Rev* **16**(3): 130-135.

- Bain, G. I., et al. (2000). "Repair of distal biceps tendon rupture: a new technique using the Endobutton." *J Shoulder Elbow Surg* **9**(2): 120-126.
- Caekebeke, P., et al. (2016). "Distal biceps tendon repair: comparison of clinical and radiological outcome between bio-absorbable and non-absorbable screws." *J Shoulder Elbow Surg*: accepted for publication.
- Caekebeke, P., et al. (2016). "Radiological and Clinical Evaluation of the Transosseous Cortical Button Technique in Distal Biceps Tendon Repair." *J Hand Surg Am* **41**(12): e447-e452.
- Chavan, P. R., et al. (2008). "Repair of the ruptured distal biceps tendon: a systematic review." *Am J Sports Med* **36**(8): 1618-1624.
- Citak, M., et al. (2011). "Surgical repair of the distal biceps brachii tendon: a comparative study of three surgical fixation techniques." *Knee Surg Sports Traumatol Arthrosc* **19**(11): 1936-1941.
- Schmidt, C. C., et al. (2015). "The Importance of Preserving the Radial Tuberosity During Distal Biceps Repair." *J Bone Joint Surg Am* **97**(24): 2014-2023.
- Dunphy, T. R., et al. (2017). "Surgical Treatment of Distal Biceps Tendon Ruptures: An Analysis of Complications in 784 Surgical Repairs." *Am J Sports Med* **45**(13): 3020-3029.
- Peeters, T., et al. (2009). "Functional outcome after repair of distal biceps tendon ruptures using the endobutton technique." *J Shoulder Elbow Surg* **18**(2): 283-287.
- Kelly, E. W., et al. (2000). "Complications of repair of the distal biceps tendon with the modified two-incision technique." *J Bone Joint Surg Am* **82-A**(11): 1575-1581.
- Becker, D., et al. (2019). "How to avoid posterior interosseous nerve injury during single-incision distal biceps repair drilling." *Clin Orthop Relat Res* **477**: 424-431.
- Rashid, A., et al. (2016). "Failure of distal biceps repair by gapping." *Shoulder Elbow* **8**(3): 192-196.
- Pelc JS, Beaulieu CF. Volume rendering of tendon-bone relationships using unenhanced CT. *AJR Am J Roentgenol* 2001;176:973-977. 10.2214/ajr.176.4.1760973
- Nebelung, W., et al. (2003). "Histological findings of tendon-bone healing following anterior cruciate ligament reconstruction with hamstring grafts." *Arch Orthop Trauma Surg* **123**(4): 158-163.

DISCUSSION AND CONCLUSIONS

DISCUSSION AND CONCLUSIONS

Although our knowledge of distal biceps tendon (DBT) pathology has evolved significantly over the last few years, some elements of diagnosis and treatment still remain controversial. Our research focused on improving the diagnosis and treatment of distal biceps tendon ruptures.

Clinical diagnosis of partial distal biceps tendon ruptures and bicipital bursitis and tendinosis.

The goal of the first two chapters of this thesis was to fill the void in diagnostic tools for partial distal biceps tendon ruptures, bicipital bursitis and tendinosis. The diagnosis of these pathologies is often difficult and based on vague symptoms such as pain in the antecubital region, exacerbated with activity. Biceps strength is usually good and resistance tests may be negative. This may lead to a diagnostic lag or even missed diagnosis, especially in the primary care setting. We endeavored to offer an easy to perform diagnostic tool that can be incorporated in daily practice. In Chapter 1, we developed a specific test for these pathologies: the biceps provocation test (BPT). The BPT is a two-part test. The elbow is flexed to 70° with the forearm supinated. The examiner's hands are placed on the patient's forearm and the patient is asked to flex the elbow against resistance (BPTs). The forearm is then pronated and the test is repeated (BPTp). Pain is documented for both supination and pronation using a visual analog scale from 0 to 10. The test is positive when the patient indicates an increase in pain with BPTp compared with BPTs. Our study showed that the BPT was highly accurate in the clinical diagnosis of DBT pathology. Although the reported outcomes were excellent, this study was based on a small cohort. Ascertainment bias may have been present because patients were recruited from a highly specialized elbow practice in which the surgeon may have been more suspicious with regard to distal biceps tendon pathology. Results might have

been different if the BPT were used in a general orthopedic setting or emergency room. Furthermore, in the control group, most patients had medial or lateral epicondylitis. In addition, because patients with a positive BPT were automatically included in the study, this may have introduced some selection bias. It is highly unlikely that a sensitivity and specificity of 100% would have been found if these weaknesses had been addressed, but this would probably not change the conclusion that the BPT is an addition to the tests available to examine a patient's elbow. As we did not know the sensitivity and specificity of the MRI evaluation used as reference standard it is possible that patients in the control group had a false-negative test. Both the sensitivity and the specificity of our test were excellent, but this would likely have been influenced by the limitations listed. False-positive and false-negative tests may occur once the test is used more widely and in patients with pathologies that were not included in this study. Despite these limitations, we consider the biceps provocation test a valuable tool in the diagnosis of partial distal biceps tendon ruptures, bicipital bursitis and tendinosis. It is an easy to use clinical tool which can be implemented in the daily practice of dedicated elbow surgeons as well as primary care givers.

In the following years, two other clinical tests have been described to diagnose this pathology: the tilt sign and the resisted hook test. The tilt sign was described in a descriptive study based on three patients (Shim et al. 2018). The resisted hook test was evaluated on 21 patients with partial tears (Harasymczuk et al. 2020). The reported accuracy was excellent. To evaluate the accuracy of these test compared to the BPT we set up a multicenter evaluation described in Chapter 2. We noted a higher sensitivity and specificity of the BPT compared to the other tests. When these tests were implemented in a parallel setup the sensitivity increased to 98%. This study showed that the BPT in combination with the resisted hook test is a valuable addition to the diagnostic tool kit of the care giver. As the sensitivity increase by using the BPT and resisted hook test

together we advise to use them in the clinical elbow examination the increase diagnostic accuracy of partial distal biceps tendon ruptures, bicipital bursitis and tendinosis. The limitations of this study include a small cohort and the limited variety of pathologies in the control group. Further investigation on a larger patient group with a well-balanced control group is needed to ascertain the correct sensitivity and specificity of this test. As all the aforementioned tests are not able to distinguish between bursitis, tendinosis of partial ruptures and no grading of the partial rupture is possible. We therefore still advise further imaging studies to confirm diagnosis and aid in determining a treatment plan.

Imaging studies for distal biceps tendon pathology

MRI investigation is frequently advised to diagnose DBT pathology. The added value to diagnose complete DBT ruptures is questionable as the clinical investigation is often sufficient. The sensitivity of standard MRI investigation of DBT pathology is reported to be excellent for complete ruptures but significantly worse for partial ruptures (Festa et al. 2010). The specificity of this investigation for both complete and partial ruptures is seldomly investigated and based on small cohorts. Furthermore, not much was known regarding the asymptomatic signal changes of the DBT as is seen in other pathologies such as lateral epicondylitis (van Leeuwen et al. 2016). A large cohort evaluation is necessary to determine the negative predictive value of MRI investigation. This may be useful for primary care givers to distinguish between various elbow pathologies. MRI investigation is often used as a reference standard in research, for example to evaluate clinical diagnostic tools such as the biceps provocation test. As the specificity and the occurrence of signal change in asymptomatic patients is unknown, patients in the control group may have a positive MRI without clinically significant DBT pathology. We acknowledged this hiatus when we evaluated the biceps provocation test. In Chapter 3, we set up a large cohort study to evaluate MRI signal changes in asymptomatic changes. We evaluated 1191 MRI scans and found a very low prevalence of signal changes in

patients without distal biceps tendon pathology. We saw no influence of age on the prevalence of asymptomatic changes. This study empowers MRI investigation as a reference standard for research purposes. Additionally, MRI can be used to distinguish between elbow pathologies by primary care givers, less practiced in clinical evaluation of the elbow. There are several limitations to this study. First, most patients included in this study were Caucasian, and our sample may therefore not represent the average patient in other countries. Furthermore, due to our setting, our data should be interpreted as most representative of a tertiary care center with a strong primary care system. Second, we assessed the MRI scans of patients who had symptoms around the elbow and not asymptomatic volunteers. This leads to an incomplete representation of general population. Finally, there was a variation in MRI scanners used to obtain the images and difference in imaging technique. This may have affected the identification of signal changes by the researchers and the radiologists.

Although the sensitivity of MRI is more investigated than the specificity, it is reported to be very low (59%). In 2004, Guiffre described the FABS view in which the complete tendon can be visualized (Guiffre et al. 2004). Although widely adopted, we found no investigation on the accuracy of this investigation. We think it is important that clear guidelines can be offered for health care professionals to aid in diagnosis and subsequent treatment. In Chapter 4, we set up retrospective evaluation in which the FABS view was compared to standard MRI. Our data did not show a significant difference in sensitivity and specificity for the FABS view MRI compared with standard MRI in the detection of distal biceps injuries. However, inter-rater reliability was higher with FABS views, and FABS views were significantly more accurate than surgical findings in grading the extent of the pathology. The advantage of our study is that the radiologists were blinded to the purpose of this investigation. Only after the first distinction they were told to grade the distal biceps tendon ruptures as described before. In previous studies, the investigators

were told that the MRI scans suggested distal biceps pathology which may have introduced bias (Williams et al. 2001). In this study, standard MRI and FABS MRI obtained in the same patient were not directly compared. However, because the radiologists were not aware that they were evaluating distal biceps tendon pathologies in either group, we believe that the results of the study were not influenced. We did not consider tear chronicity. Previous research evaluated this and saw no influence on the results (Festa et al. 2010). Our protocol for the FABS view MRI included coronal and axial 3-dimensional sequences with a slice thickness of 1.5 mm whereas the standard elbow MRI protocol had a slice thickness of 3 mm. The accuracy and consistency of the MRI examination may have been influenced in favor of the FABS view by using a thinner slice thickness than with the standard MRI protocol. The grading of the tear was based on surgical findings. This may have introduced an error, but we believe this was the most accurate possible method. The advantages of the FABS view in this study were a better inter-rater reliability and a higher accuracy in grading the extent of pathology. As the grading of the lesion may influence further treatment we still recommend the FABS view MRI to be used for the diagnosis of partial distal biceps tendon ruptures, bicipital bursitis and tendinosis despite similar sensitivity and specificity of both views.

Treatment of partial distal biceps tendon ruptures, bicipital bursitis and tendinosis.

Various treatment options have been described for partial distal biceps tendon rupture, tendinitis or bicipital bursitis. A simple debridement of the tendon by performing a bursectomy may suffice in patients with a tendonitis (Bain et al. 2008). Completion of the tear followed by a reinsertion may be indicated in patients with a more substantial partial tendon tear (Dellaero et al. 2006, Kelly et al. 2003). As the treatment differs, it is important to be able to differentiate within this spectrum of pathological conditions. However, even intra-operatively it is often difficult to estimate the percentage of tendon that is involved. Tears usually initiate from the radial side of the tendon (Davis et al.

1956) and are more commonly found on the distal insertion of the short head. This is the portion facing the tuberosity and in order to inspect this side of the tendon in minor tears, it needs to be dissected and retracted (Kelly et al. 2003). This may potentially have a detrimental effect on the already weakened insertion or disturb a tendon that is essentially intact. Biceps endoscopy has been proposed in order to overcome this disadvantage (Bain et al. 2008, Eames et al. 2006, Sharma et al. 2005). Distal biceps endoscopy was first described by Sharma and MacKay in 2005 (Sharma et al. 2005). They made a small incision proximal to the elbow crease and drilled a guide wire from proximal to distal, creating an oblique tunnel in the radius. Although no complications occurred in the two patients reported (Sharma et al. 2005), Saldua et al. showed that this oblique angle carried an increased risk to the posterior interosseous nerve (PIN) and recommended a different trajectory (Saldua et al. 2008). Bain et al. adapted the endoscopic technique to a single incision technique and this is our preferred technique (Eames et al. 2006). Bhatia and colleagues later proposed a 2-incision endoscopic technique to improve work space. They commented a single incision does not allow sufficient room for the camera and working tools. They showed to be technically feasible in the treatment of DBT ruptures (Bhatia et al. 2016, Bhatia et al. 2018). They tested the technique with both suture anchors and cortical buttons. They also emphasize that the cortical button technique has a higher risk of iatrogenic injuries to the posterior interosseous nerve due to the position of the button. This technique differs however from our preferred technique as it is a 2-incision technique which requires an added proximal portal. In our hands, we favor a single incision to minimize possible other risks due to a second portal. We believe that biceps endoscopy is feasible through a single incision. Small cohort results seem to be promising (van Riet. 2017). For the 2-incision technique, evaluation of the safety has been published (Bhatia et al. 2018). Not much is known about the safety of single incision technique in regards to the surrounding structures. In Chapter 5, we saw no significant differences with regards to the distance of neurovascular structures and the

reconstructed biceps tendon or endobutton between an open and single incision endoscopic techniques. Our results, like other studies, emphasize the importance of correct positioning of the arm in supination during endobutton insertion to protect the PIN (Bhatia et al. 2018). The neurovascular structures were within millimeters of the tunnels and tendon, so it is imperative that retractors are placed on either side of the radius to provide direct visualization of the tendon stump and the radial tuberosity and to protect them during instrumentation. As distal biceps endoscopy becomes more popular, further research is needed regarding clinical and functional outcomes as reports on this are rare. Furthermore, indications have to be clearly defined as most indications currently are based on expert opinion.

Treatment of complete distal biceps tendon ruptures

Distal biceps tendon repair has been described through a single incision approach and a double incision approach. The single incision approach has become progressively popular. This approach has a lower risk of heterotopic ossification, compared to the double incision technique. A popular fixation technique is the bicortical button technique. It offers the highest initial load to failure, allowing early rehabilitation. The intra-osseous fixation of the tendon prevents gap formation, a described complication of other fixation techniques (Rashid et al. 2016). The biggest downside of the bicortical button is the risk of iatrogenic nerve damage. Due to its course on the posterolateral side of the radial bone, the posterior interosseous nerve (PIN) is in danger when a bicortical button is placed on the far cortex of the radius. A non-anatomical reinsertion is therefore advised as it puts the button out of the way of the PIN. Previous research has shown that even with a non-anatomical reinsertion, the PIN lies in close proximity of the button. This may lead to possible catastrophic outcomes (Becker et al. 2019, Lo et al. 2011, Amin et al. 2016). In an attempt to alleviate the risk of PIN damage, several authors evaluated mono-cortical buttons which would allow a repair on the ulnar border of the

radial tuberosity (Siebenlist et al. 2011, Siebenlist et al. 2015, Siebenlist et al. 2019). Additionally, this would allow a more anatomical positioning of the repair keeping the bony landmarks of the radial tuberosity intact and thus improving the supination force of the repaired tendon (Schmidt et al. 2015). However, fixation on the thin cortex of the radial tuberosity may lead to suboptimal fixation strength and possible button or anchor breakout. Previous biomechanical studies (Siebenlist et al. 2011) showed that the load to failure of the unicortical fixation is lower than the bicortical fixation. They also reported that the method of failure is potentially catastrophic with a fracture of the anterior cortex. Siebenlist and colleagues therefore advised a stronger, double button, unicortical fixation method (Siebenlist et al. 2011). However, in their technique the buttons are essentially used as an anchor with fixation of the tendon onto the bone and not in a bone tunnel. This could lead to gap formation between tendon and bone due to tendon pistoning. This is inherent of tendon fixation against the bone instead of in a bone tunnel (Mazzocca et al. 2007, Sethi et al. 2010, Rashid et al. 2016). In our opinion, based on aforementioned reasons, the ideal fixation would be performed through a single incision approach. The fixation should be intramedullary with a high initial load to failure and an intra-osseous tendon fixation to prevent gapping.

The goal of the last part of this thesis was to develop a fixation device that would encompass these requirements. To determine the size and shape of an intramedullary fixation device we needed a clear understanding of the bony anatomy of the radial tuberosity. We therefore set up a large cohort radiological study. We measured the important dimensions and landmarks of the radial tuberosity (Chapter 6). As the anterior cortex of the radial tuberosity is weak we evaluated the anterior cortex on both sides of the tuberosity. The anterior cortex on both sides of the tuberosity, on which a possible new device relies for support, has a similar thickness as the posterior cortex used in bicortical fixation devices which may suggest similar resistance to pull-out strengths.

The availability for intra-osseous fixation of the tendon stump was evaluated. The tunnel depth seems to be sufficient to allow some slippage and to avoid tendon-bone gapping as seen with anchor fixation. Based on these measurements we devised a new fixation design with the aim to alleviate the aforementioned problems with the current fixation devices. The unicortical fixation decreases the risk of nerve injury while allowing an anatomical position of the repaired tendon. The increased length of the button allows the button to hold against the thicker anterior cortex of the radius instead of the weaker tuberosity. Due to the bell shape of the button the tendon can be pulled into the bone tunnel, decreasing potential tendon to bone gap formation. The device was designed using 3DCAD software and printed in titanium. This allowed fast adaptation in the initial design process.

As stated before, a high load to failure offers initial fixation strength which allow early range of motion and rehabilitation. We therefore performed a biomechanical evaluation of this new fixation device in Chapter 7. The biomechanical results of the new button are comparable to other currently used techniques (Siebenlist et al. 2011, Mazzocca et al. 2007). Both load to failure (356N) and stiffness (61N/mm) are similar to the excellent results of the bicortical button technique (Siebenlist et al. 2011, Mazzocca et al. 2007). We did not use an additional interference screw since literature has shown tunnel widening with possible catastrophic results, without adding extra strength to the initial fixation (Caekebeke et al. 2016). Fracture avulsion of the anterior cortex was only found in one single specimen in the new button group at maximal load to failure. In the bicortical group this was seen in three cases. The load to failure of the new technique was higher than the native tendon as described by Idler and colleagues (Idler et al. 2006). Tendon rerupture is seldomly seen in bicortical button fixation due to the high initial fixation strength (Kelly et al. 2000). The new button yields the same initial fixation strength as most other techniques (Siebenlist et al. 2011, Mazzocca et al. 2007, Idler et

al. 2006). Besides the lower rerupture risk, this allows for immediate postoperative mobilization and loading. This may result in a faster rehabilitation. There were some limitations of this biomechanical evaluation. First, the human cadaveric specimens were of an older age than the typical age for distal biceps ruptures, but comparable with the specimen age in other studies. It is possible that in younger specimens with better bone quality, less failures with bony avulsions would occur. This may be especially relevant for classical intramedullary buttons where this was the predominant failure mode. Even in these older specimens a clear difference is present between the new button and the classical button. Second, a relatively small group of specimens was used although this is comparable to other reported biomechanical studies. We felt that the results were encouraging and allowed an in vivo evaluation of the new device.

The conclusion of this thesis was an in vivo evaluation of the new fixation device. In a first study, we placed the new button non-anatomical in ten patients (Chapter 8). If the new construct would have failed a conversion to a bicortical technique would still be possible. There were no failures of fixation in the patient group examined. Elbow mobility was symmetrical for all patients from 3 months onward. Supination strength was 86% of the uninjured side at final follow-up. The mean Disabilities of the Arm, Shoulder and Hand score (DASH score) and Mayo Elbow Performance Score at final follow-up were 0 and 100, respectively. Computed tomography images showed no signs of button migration, cortical thinning due to button pressure, or button breakout. The tendon could be followed to the button in all cases. No adverse reactions of the button on the bone were seen. We saw a temporary lateral antebrachial cutaneous nerve (LACN) neuropraxia in 40% of cases. These rates have been reported in literature but are undeniable on the higher side (Grewal et al. 2012). Several investigators attribute the increased rate of LACN neurapraxias to the necessary retraction of the nerve during exposure and preparation of the bicipital tuberosity in the single anterior incision

approach (Grewal et al. 2012, Citak et al. 2011). This is in contrast to the double-incision technique where the LACN nerve is retracted for a brief time compared with the single-incision approach (Grewal et al. 2012). One proposed method to limit LACN nerve damage is the use of a limited anterior incision and skin tension during retraction. This may be the reason for the more occurrence of this complication in our study as we used a larger incision. As this was a new technique and an ideal visualization was preferred we opted for a larger incision. The neuropraxia was temporary in all cases. Although it is temporary in most cases reported in literature, patient often find it annoying and as such it is important to counsel patients of the potential risk with a single-incision technique. Following the promising results of a non-anatomical refixation, we performed eleven anatomical reinsertions using the new fixation device (Chapter 9). Functional outcome at two weeks, six weeks and three months in the present study was comparable to our experience with non-anatomical DBT refixation with the same intramedullar button (Caekebeke et al. 2021). Functional outcome at six months was excellent and comparable to the reported outcome of other fixation methods (Bain et al. 2000, Caekebeke et al. 2016, Caekebeke et al. 2016, Chavan et al. 2008, Citak et al. 2011). Full pronation was regained later in the rehabilitation period compared to non-anatomical fixation (Caekebeke, et al. 2021). We believe that this is a result of the anatomical reinsertion site. As the DBT rotates around the radial bone with pronation, the repaired tendon would stretch more with more ulnar (i.e. anatomical) reinsertion. Supination strength was comparable to the contralateral uninjured side and previous reported outcomes of anatomical onlay reinsertion. (Bellringer et al. 2020). In our studies we did not consider dominance. Previous literature suggest that a constant relation does exist in strength related to the dominance (Rey et al. 2014). The strength difference related to dominance and daily activities, which we assume to be also a determining factor, needs to be considered in the future long-term evaluations of this new technique. Supination strength was evaluated using a hand-held dynamometer. We measured the supination

strength in full supination. Strength measurements in other positions of rotation may therefore differ from our results. Previous investigations showed that the biggest difference in supination strength lies in the position of final supination (Bellringer et al. 2020). We believe that this position is most important to evaluate differences between non-anatomical and anatomical refixation. Furthermore, we did not evaluate endurance of supination. As this is an important deficit associated with distal biceps tendon ruptures, endurance measurements need to be included in long term evaluation of this technique. Our technique is not a full anatomical reinsertion. As a hole is needed to insert the button, we have to be able to drill at least 45-50° to the radial bone. It is not possible to reach the posteromedial tuberosity at 45-50° via a single incision. Besides the insertion site, the cam effect of the tuberosity is important for supination strength. The more anatomical reinsertion does not drill through the cam as seen in a standard bicortical fixation. Our hypothesis was that even with a near anatomical reinsertion, native supination strength could be achieved. Quick-DASH and MEPS outcome scores were excellent for all patients. These scores are slightly better than other studies (Chillemi et al. 2007, Caekebeke et al. 2016, Dunphy et al. 2017, Peeters et al. 2009) but this may be influenced due to the fact the patients in this study knew this was an evaluation of a new technique. We suspect that knowledge of the purpose of these studies may have influenced the outcome score submitted by our patients. We again saw relatively high rates of LACN neuropraxia. As mentioned before, a smaller incision may reduce the risk of this minor although annoying complication. Heterotopic ossification (HO) is more often described in a double-incision technique than the single-incision technique (Kelly et al. 2000). We did observe a small heterotopic ossification in one patient in this group. We believe this may be due to insufficient lavage at the end of the procedure. As the HO did not limit movement, it was treated expectantly. The removal of bone debris after drilling, extensive lavage and haemostasis remains paramount to avoid heterotopic bone formation. A major and possible catastrophic complication is iatrogenic PIN damage. As

the posterior cortex is not breeched in this new technique, the risk is alleviated. Radiographic and CT imaging in both studies showed no full closure of the bone tunnel. Slight closure is to be expected as the bone repairs around the tendon. Present study showed no complete closure of the bone tunnel after six months. Soft tissue views of the CT images allow us to follow the tendon to the bone in all cases indicating that no gap formation was present. Both in vivo studies had a follow-up of six months. As we do not expect tendon-healing to be complete after six months we deemed this follow-up sufficient for the first experience studies. Further follow-up to evaluate the long-term follow-up and evaluation of this technique in larger series to correctly identify the complication profile and clinical and radiographical outcome is undoubtedly necessary and will be performed.

CONCLUSION

The research presented in this thesis provided new diagnostic tools and treatment options for distal biceps tendon pathology. We developed a clinical test to accurately and timely diagnose partial distal biceps tendon ruptures, bicipital bursitis and tendinosis and we compared it to other described clinical tests. We found distal biceps endoscopy through a single incision technique to be safe for surrounding structures. Furthermore, we proposed a new fixation device based on shortcomings of current techniques and anatomical landmarks of the radial tuberosity. In vivo evaluation showed that this new technique may be a valuable treatment option for distal biceps tendon ruptures. The functional outcomes at 6 months were excellent. The risk of posterior interosseous nerve damage is alleviated. The intramedullar fixation showed to be sufficiently strong for early rehabilitation and allows an anatomical repair with full return of supination strength. Moreover, the intramedullar position of the tendon should minimize the risk of gap formation.

REFERENCES

- Shim, S. S. and R. J. Strauch (2018). "A novel clinical test for partial tears of the distal biceps brachii tendon: The TILT sign." *Clin Anat* 31(2): 301-303.
- Harasymczuk, M., et al. (2020). Algorithm For Diagnosing Complete And Partial Distal Biceps Tendon Tears: Hook Test And Resisted Hook Test. ESSE-SECEC. virtual meeting.
- Festa, A., et al. (2010). "Effectiveness of magnetic resonance imaging in detecting partial and complete distal biceps tendon rupture." *J Hand Surg Am* 35(1): 77-83.
- van Leeuwen, W. F., et al. (2016). "Incidental magnetic resonance imaging signal changes in the extensor carpi radialis brevis origin are more common with age." *J Shoulder Elbow Surg* 25(7): 1175-1181.
- Giuffre, B. M. and M. J. Moss (2004). "Optimal positioning for MRI of the distal biceps brachii tendon: flexed abducted supinated view." *AJR Am J Roentgenol* 182(4): 944-946.
- Williams, B. D., et al. (2001). "Partial tears of the distal biceps tendon: MR appearance and associated clinical findings." *Skeletal Radiol* 30(10): 560-564.
- Festa, A., et al. (2010). "Effectiveness of magnetic resonance imaging in detecting partial and complete distal biceps tendon rupture." *J Hand Surg Am* 35(1): 77-83.
- Giuffre, B. M. and M. J. Moss (2004). "Optimal positioning for MRI of the distal biceps brachii tendon: flexed abducted supinated view." *AJR Am J Roentgenol* 182(4): 944-946.
- Bain, G. I., et al. (2008). "Treatment of partial distal biceps tendon tears." *Sports Med Arthrosc* 16(3): 154-161.
- Dellaero, D. T. and W. J. Mallon (2006). "Surgical treatment of partial biceps tendon ruptures at the elbow." *J Shoulder Elbow Surg* 15(2): 215-217.
- Kelly, E. W., et al. (2003). "Surgical treatment of partial distal biceps tendon ruptures through a single posterior incision." *J Shoulder Elbow Surg* 12(5): 456-461.
- Davis, W. M. and Z. Yassine (1956). "An etiological factor in tear of the distal tendon of the biceps brachii; report of two cases." *J Bone Joint Surg Am* 38-A(6): 1365-1368.
- Eames, M. H. and G. I. Bain (2006). "Distal biceps tendon endoscopy and anterior elbow arthroscopy portal." *Tech Shoulder Elbow Surg*(7): 139-142.
- Sharma, S. and G. MacKay (2005). "Endoscopic repair of distal biceps tendon using an EndoButton." *Arthroscopy* 21(7): 897.
- Saldua, N., et al. (2008). "The effect of drilling angle on posterior interosseous nerve safety during open and endoscopic anterior single-incision repair of the distal biceps tendon." *Arthroscopy* 24(3): 305-310.
- Bhatia, D. N., et al. (2016). "Cadaveric study of anterior and posterior elbow endoscopy portals for endoscopic distal biceps repair: comparative anatomy-at-risk." *Surg Radiol Anat* 38(7): 781-791.

Bhatia, D. N. and V. Kandhari (2018). "Analysis of technical feasibility and neurovascular safety of endoscopic distal biceps repair: a cadaveric study." *J Shoulder Elbow Surg* 27(11): 2057-2067.

Van Riet R. (2017). *Partial tears of the distal biceps - Work-up and treatment*. SECEC. Berlin.

Becker, D., et al. (2019). "How to avoid posterior interosseous nerve injury during single-incision distal biceps repair drilling." *Clin Orthop Relat Res* 477: 424-431.

Lo, E. Y., et al. (2011). "The effect of drill trajectory on proximity to the posterior interosseous nerve during cortical button distal biceps repair." *Arthroscopy* 27(8): 1048-1054.

Amin, N. H., et al. (2016). "Complications of Distal Biceps Tendon Repair: A Meta-analysis of Single-Incision Versus Double-Incision Surgical Technique." *Orthop J Sports Med* 4(10): 2325967116668137.

Siebenlist, S., et al. (2015). "Double intramedullary cortical button versus suture anchors for distal biceps tendon repair: a biomechanical comparison." *Knee Surg Sports Traumatol Arthrosc* 23(3): 926-933.

Siebenlist, S., et al. (2011). "The double intramedullary cortical button fixation for distal biceps tendon repair." *Knee Surg Sports Traumatol Arthrosc* 19(11): 1925-1929.

Siebenlist, S., et al. (2011). "Biomechanical in vitro validation of intramedullary cortical button fixation for distal biceps tendon repair: a new technique." *Am J Sports Med* 39(8): 1762-1768.

Siebenlist, S., et al. (2019). "Intramedullary Cortical Button Repair for Distal Biceps Tendon Rupture: A Single-Center Experience." *J Hand Surg Am* 44(5): 418 e411-418 e417.

Schmidt, C. C., et al. (2015). "The Importance of Preserving the Radial Tuberosity During Distal Biceps Repair." *J Bone Joint Surg Am* 97(24): 2014-2023.

Mazzocca, A. D., et al. (2007). "Biomechanical evaluation of 4 techniques of distal biceps brachii tendon repair." *Am J Sports Med* 35(2): 252-258.

Sethi, P., et al. (2010). "Biomechanical evaluation of distal biceps reconstruction with cortical button and interference screw fixation." *J Shoulder Elbow Surg* 19(1): 53-57.

Rashid, A., et al. (2016). "Failure of distal biceps repair by gapping." *Shoulder Elbow* 8(3): 192-196.

Caekebeke, P., et al. (2016). "Distal biceps tendon repair: comparison of clinical and radiological outcome between bioabsorbable and nonabsorbable screws." *J Shoulder Elbow Surg* 25(3): 349-354.

Idler, C. S., et al. (2006). "Distal biceps tendon repair: a biomechanical comparison of intact tendon and 2 repair techniques." *Am J Sports Med* 34(6): 968-974.

Kelly, E. W., et al. (2000). "Complications of repair of the distal biceps tendon with the modified two-incision technique." *J Bone Joint Surg Am* 82-A(11): 1575-1581.

Grewal, R., et al. (2012). "Single versus double-incision technique for the repair of acute distal biceps tendon ruptures: a randomized clinical trial." *J Bone Joint Surg Am* 94(13): 1166-1174.

- Citak, M., et al. (2011). "Surgical repair of the distal biceps brachii tendon: a comparative study of three surgical fixation techniques." *Knee Surg Sports Traumatol Arthrosc* 19(11): 1936-1941.
- Rashid, A., et al. (2016). "Failure of distal biceps repair by gapping." *Shoulder Elbow* 8(3): 192-196.
- Caekebeke, P., et al. (2021). "In vivo evaluation of a new intramedullary distal biceps tendon fixation device." *J Shoulder Elbow Surg* 30(12): 2869-2874.
- Caekebeke, P., et al. (2019). Distal biceps tendon repair with the Endobutton technique. Surgical techniques for trauma and sports related injuries of the elbow. G. I. Bain, D. Eygendaal and R. van Riet, Springer.
- Caekebeke, P., et al. (2016). "Distal biceps tendon repair: comparison of clinical and radiological outcome between bio-absorbable and non-absorbable screws." *J Shoulder Elbow Surg*: accepted for publication.
- Caekebeke, P., et al. (2016). "Radiological and Clinical Evaluation of the Transosseous Cortical Button Technique in Distal Biceps Tendon Repair." *J Hand Surg Am* 41(12): e447-e452.
- Chavan, P. R., et al. (2008). "Repair of the ruptured distal biceps tendon: a systematic review." *Am J Sports Med* 36(8): 1618-1624.
- Rey, P. B., et al. (2014). "[Is there any correlation between the strength of pronation and supination of the dominant hand and that of the non-dominant one in right-handed healthy adults: preliminary results]." *Chir Main* 33(1): 17-22.

ENGLISH SUMMARY

ENGLISH SUMMARY

The distal biceps tendon is the connection of the biceps muscle to the radial bone of the forearm. It is this structure that is the focus of this dissertation. Complete distal biceps tendon ruptures occur in 2.55 per 100.00 cases. The vast majority occurs in males between 40 and 60 years of age. The most commonly described mechanism is an excessive eccentric contraction of the biceps brachii with the elbow held in a slightly flexed and supinated (= with the palm up) position. Besides complete ruptures, partial ruptures, tendon inflammation and inflammation of the surrounding tissue can occur. The exact incidence of these injuries is unknown. The clinical investigation of complete ruptures is straightforward, and many clinical tests have been described. In contrast, the diagnosis of partial biceps tendon injuries is more difficult. The symptoms are vague and few clinical tests have been described. We proposed a new clinical test to detect these injuries, the distal biceps provocation test. The distal biceps provocation test is easy to implement in daily practice and was found to be highly accurate. We compared this clinical test to other recently reported diagnostic tests. The distal biceps provocation test yielded the highest accuracy. If there is a clinical suspicion of partial distal biceps injury, an MRI is often advised. Standard MRI has been described to be lacking in the ability to detect partial distal biceps tendon injuries. Therefore, a patient position in the MRI, called the flexion abduction supination view was described and it was postulated that this would result in a better view of the distal biceps tendon and its injuries. We evaluated this technique and found that, although it has similar accuracy to standard MRI to detect partial biceps tendon injuries, it has a higher accuracy in defining the extent of the injury. We therefore advise to use this technique when a suspicion of an injury is present. We saw that signs of pathology on MRI almost never occur in asymptomatic patients which make the MRI a valuable tool both in research and the clinical practice.

Due to the position of the distal biceps tendon over the bone it attaches to, the extent of the partial injury cannot be directly evaluated via an open surgical technique. Therefore, a technique was developed that uses a camera. This is called an endoscopic technique. We found this endoscopic technique to be as safe as the previously used open technique with the added advantage that the tendon could be inspected without releasing it from the bone.

In case of a complete rupture of the distal biceps tendon, various techniques have been described to re-attach the tendon to the bone. One of the important factors is the initial strength of fixation of the tendon to the bone. The stronger the fixation, the faster the patient can mobilize and rehabilitate. One of the most used techniques is the fixation of the tendon to a metal plate which hooks on the far side of the bone. With this technique, a drill hole is made where the surgeon wants the tendon to heal. As the tendon is fixed to the metal plate, the tendon is pulled into the drill hole where it will re-attach to the bone. One of the risks of this technique is that a very important nerve runs closely to the site where the plate sits on the back of the bone. Additionally, the tendon cannot be reinserted at the original site as that would put this nerve in danger. Ideally, the metal plate would hook on the interior side of the front of the bone since the nerve would no longer be at risk and the tendon could be reinserted at the native reinsertion site. This would need to be combined with a strong fixation. After radiographical evaluation of the internal structures of the insertion site we proposed a new fixation device. This device, which is essentially a metal plate in a special shape, allows the tendon to be fixed securely into the bone without additional risk of injuring the nerve on the far side of the bone. We performed strength testing and saw that this fixation is as strong as the standard metal plate. We then performed a total of 21 distal biceps tendon repairs with the new fixation device. We saw no failures of fixation in the patient group. Functional and clinical

outcomes were excellent for all patients at final follow-up. Strength was similar to the uninjured side at final follow-up.

To conclude, our research provided new diagnostic tools and treatment options for distal biceps tendon pathology. We developed a clinical test to accurately and timely diagnose partial distal biceps tendon ruptures, bicipital bursitis and tendinosis and we compared it to other described clinical tests. We found distal biceps endoscopy through a single incision technique to be safe for surrounding structures. Furthermore, we proposed a new fixation device based on shortcomings of current techniques and anatomical landmarks of the radial tuberosity. The functional outcomes at 6 months were excellent.

NEDERLANDSTALIGE SAMENVATTING

NEDERLANDSTALIGE SAMENVATTING

De distale bicepspees is de verbinding van de biceps spier met een van de botten van de onderarm. Deze structuur is de focus van dit proefschrift.

Volledige distale bicepspeesrupturen treden op in 2,55 per 100,000 gevallen. De overgrote meerderheid komt voor bij mannen tussen de 40 en 60 jaar oud. Het meest beschreven mechanisme is een overmatige excentrische samentrekking van de biceps brachii met de elleboog in een gebogen en gesupineerde (= met de palm omhoog) positie. Naast volledige scheuren, kunnen gedeeltelijke scheuren, peesontsteking en ontsteking van het omliggende weefsel optreden. De exacte incidentie van deze letsels is onbekend. Het klinische onderzoek van volledige scheuren is relatief duidelijk en er zijn veel klinische tests beschreven. De diagnose van gedeeltelijke bicepspees letsels daarentegen is moeilijker. De symptomen zijn vaag en er zijn nauwelijks nauwkeurige testen beschreven. We stelden een nieuwe klinische test voor om deze letsels op te sporen: de distale biceps provocatietest. De distale biceps provocatietest is eenvoudig uit te voeren in de dagelijkse praktijk en bleek zeer nauwkeurig te zijn. We vergeleken deze klinische test met andere recent gerapporteerde diagnostische testen. De distale biceps provocatietest leverde de hoogste nauwkeurigheid op.

Bij klinische verdenking op gedeeltelijk distaal bicepsletsel wordt vaak een MRI geadviseerd. Standaard MRI is minder accuraat om gedeeltelijke distale bicepspeesletsels te detecteren. Daarom werd een patiëntpositie in de MRI beschreven, de zogenaamde flexie-abductie-supinatieweergave. Deze zou resulteren in een beter zicht op de distale bicepspees en mogelijke letsels. We evalueerden deze techniek en ontdekten dat, hoewel het een vergelijkbare nauwkeurigheid heeft als standaard MRI om gedeeltelijke bicepspeesblessures te detecteren, het een hogere nauwkeurigheid heeft bij het bepalen van de grootte van het letsel. Wij adviseren daarom deze techniek te gebruiken bij een vermoeden van een blessure. We zagen dat tekenen van letsels op MRI,

bijna nooit voorkomen bij asymptomatische patiënten, wat de MRI een waardevol hulpmiddel maakt, zowel in onderzoek als in de klinische praktijk.

Vanwege de positie van de distale bicepspees over het bot waaraan het hecht, kan de omvang van de partieel letsel niet worden beoordeeld via een open chirurgische techniek. Daarom is er een techniek ontwikkeld waarbij gebruik wordt gemaakt van een camera. Dit wordt een endoscopische techniek genoemd. We evalueerden deze techniek en zagen dat deze endoscopische techniek even veilig is als de eerder gebruikte open techniek, met als bijkomend voordeel dat de pees kon worden geïnspecteerd zonder deze van het bot los te maken. Bij een volledige ruptuur van de distale bicepspees zijn verschillende technieken beschreven om de pees weer aan het bot te bevestigen. Een van de belangrijke factoren is de initiële sterkte van de fixatie van de pees op het bot. Hoe sterker de fixatie, hoe sneller de patiënt kan mobiliseren en revalideren. Een van de meest gebruikte technieken is de fixatie van de pees aan een metalen plaat die aan de andere kant van het bot haakt. Bij deze techniek wordt een boorgat gemaakt waar de chirurg de pees wil laten hechten. Een van de risico's van deze techniek is dat een zeer belangrijke zenuw dicht bij de plaats van de plaat loopt. Bovendien kan de pees niet worden ingebracht op de oorspronkelijke plaats, omdat dit deze zenuw nog meer in gevaar zou brengen. Idealiter zou de metalen plaat aan de binnenkant van het bot blijven haken, omdat de zenuw niet langer in gevaar zou zijn en de pees opnieuw zou kunnen worden ingebracht op de oorspronkelijke plaats van herinbrenging. Dit zou moeten worden gecombineerd met een sterke fixatie. Na radiografische evaluatie van de interne structuren van de inbrengplaats stelden we een nieuw fixatieapparaat voor. Dit apparaat, dat in wezen een metalen plaat in een speciale vorm is, zorgt ervoor dat de pees stevig in het bot wordt gefixeerd zonder enig risico van de zenuw aan de andere kant van het bot. We hebben een sterktestet uitgevoerd en zagen dat deze bevestiging net zo sterk is als de standaard metalen plaat. Vervolgens hebben we in totaal 21 distale bicepspees herstellen uitgevoerd met het

nieuwe fixatieapparaat. We zagen geen falen van fixatie in de patiëntengroep. Functionele en klinische resultaten waren uitstekend voor alle patiënten bij de laatste opvolging. De sterkte was vergelijkbaar met de niet-gewonde kant bij de laatste opvolging.

Concluderend heeft ons onderzoek nieuwe diagnostische hulpmiddelen en behandelingsopties opgeleverd voor distale bicepspeespathologie. We ontwikkelden een klinische test om partiële distale bicepspeesrupturen, bicipitale bursitis en tendinose nauwkeurig en tijdig te diagnosticeren en we vergeleken deze met andere beschreven klinische tests. We beschreven dat endoscopie van de distale biceps via een enkele incisie techniek veilig is voor omliggende structuren. Verder hebben we een nieuw fixatieapparaat voorgesteld op basis van tekortkomingen van de huidige technieken en anatomische kenmerken van de radiale tuberositas. De functionele resultaten na 6 maanden waren uitstekend.

CURRICULUM VITAE AND LIST OF PUBLICATIONS

CURRICULUM VITAE AND LIST OF PUBLICATIONS

PERSONALIA

Name	CAEKEBEKE Pieter J. J. S.
Date of birth	August 24, 1985
Place of birth	Gent, Belgium
Nationality	Belgian
Marital status	Married to Nathalie Lauwers
Office address	Department of Orthopedic Surgery Ziekenhuis Oost-Limburg Schiepse Bos 6, 3600 Genk, Belgium
Office tel	+32 89 326118
Email	pieter.caekebeke@gmail.com

STUDIES

1991-1997	Sint-Jozefscollege, Aalst, Belgium
1997-2003	Sint-Jozefscollege, Aalst, Belgium Latin-Mathematics

UNIVERSITY STUDIES

2003-2011	Medical school at katholieke Universiteit Leuven
-----------	--

CLINICAL EDUCATION AND PROFESSIONAL APPOINTMENTS

2010-2011	<p>Internship Medicine: AZ Sint Blasius, Dendermonde, Belgium</p> <p>Internship Surgery: ASZ Aalst, Aalst, Belgium</p> <p>Internship Pediatrics: Townsville Hospital, Townsville, Australia</p> <p>Internship OB&Gyn: Townsville Hospital, Townsville, Australia</p>
2011-2012	Residency General Surgery: UZ Gasthuisberg, Leuven, Belgium
2012-2013	Residency General Surgery: AZ Sint Maarten, Duffel, Belgium
2013-2014	Residency Orthopedic Surgery: UZ Pellenberg, Leuven, Belgium
2014-2015	Residency Orthopedic Surgery: Ziekenhuis Oost-Limburg, Genk, Belgium
2015-2016	<p>Residency Orthopedic Surgery: AZ Monica, Deurne, Belgium</p> <p>Residency Orthopedic Surgery: UZ Pellenberg, Leuven, Belgium</p>
2016 – 2017	Residency Orthopedic Surgery: UZ Pellenberg, Leuven, Belgium
2017-2018	Fellowship hand and microsurgery at the Royal North Shore Hospital, Sydney, Australia
2018	Fellowship elbow surgery at AZ Monica, Deurne, Belgium

PROFESSIONAL SERVICE

2018-present	<p>Hand and elbow surgeon in the Department of orthopedics and traumatology of Ziekenhuis Oost-Limburg, Genk, Belgium</p> <p>Hand and elbow surgeon in the Department of orthopedics and traumatology of Ziekenhuis Maas en Kempen, Maaseik, Belgium</p>
--------------	--

PEER-REVIEWED PUBLICATIONS

Pyoderma gangrenosum following trauma of the knee: a case of pathergy and review of orthopaedic cases.

Steenbrugge F, Raaijmakers M, **Caekebeke P**, Van Landuyt K.

Injury. 2011;42:421-3. DOI: 10.1016/j.injury.2010.06.015.

Sublaminar devices for the correction of scoliosis: metal wire versus polyester tape.

Caekebeke P, Moke L, Moens P.

Acta Orthop Belg. 2013;79:216-21.

Distal biceps tendon repair: comparison of clinical and radiological outcome between bioabsorbable and nonabsorbable screws.

Caekebeke P, Corten K, Duerinckx J.

J Shoulder Elbow Surg. 2016;25:349-54. DOI: 10.1016/j.jse.2015.12.007.

Radiological and Clinical Evaluation of the Transosseous Cortical Button Technique in Distal Biceps Tendon Repair.

Caekebeke P, Vermeersch N, Duerinckx J, van Riet R.

J Hand Surg Am. 2016;41:e447-e452. DOI: 10.1016/j.jhssa.2016.08.014.

Lateral collateral ligament injuries of the elbow - chronic posterolateral rotatory instability (PLRI).

Conti Mica M, **Caekebeke P**, van Riet R.

EFORT Open Rev. 2016;1:461-468. DOI: 10.1302/2058-5241.160033.

Trapezium anatomy as a radiographic reference for optimal cup orientation in total trapeziometacarpal joint arthroplasty.

Duerinckx J, **Caekebeke P**.

J Hand Surg Eur Vol. 2016;41:939-943. DOI: 10.1177/1753193416630496.

Short report letter: Cortical contact is unnecessary to prevent stem subsidence in cementless trapeziometacarpal arthroplasty.

Duerinckx J, Perelli S, **Caekebeke P**.

J Hand Surg Eur Vol. 2018;43:98-99. DOI: 10.1177/1753193417733377.

Can surgical guidelines minimize complications after Maia(R) trapeziometacarpal joint arthroplasty with unconstrained cups?

Caekebeke P, Duerinckx J.

J Hand Surg Eur Vol. 2018;43:420-425. DOI: 10.1177/1753193417741237.

Reply to: Can surgical guidelines minimize complications after Maia(R) trapeziometacarpal joint arthroplasty with unconstrained cups?

Caekebeke P, Duerinckx J.

J Hand Surg Eur Vol. 2018;43:896-897. DOI: 10.1177/1753193418791435.

The effect of cup orientation on stability of trapeziometacarpal total joint arthroplasty: a biomechanical cadaver study.

Brauns A, **Caekebeke P**, Duerinckx J.

J Hand Surg Eur Vol. 2019;44:708-713. DOI: 10.1177/1753193419851775.

Can a ratio between medial and lateral meniscal volumes be calculated to determine critical meniscal volume in view of post-meniscectomy symptoms?

Van Elst C, **Caekebeke P**, Vandenneucker H, Bellemans J, Scheys L.

Acta Orthop Belg. 2020 Mar;86(1):77-81.

Radiohamate impingement after proximal row carpectomy.

Caekebeke P, De Smet L.

Acta Orthop Belg. 2020 Mar;86(supplement 1):77-81.

A New Intramedullary Fixation Method for Distal Biceps Tendon Ruptures: A Biomechanical Study.

Caekebeke P, Duerinckx J, Bellemans J, van Riet R.

J Shoulder Elbow Surg. 2020 29; S1058-2746(20)30176-2. DOI: 10.1016/j.jse.2020.01.102.

Trapeziometacarpal total joint arthroplasty: The effect of capsular release on range of motion.

Van Hove B, Vantilt J, Bruijnes A, **Caekebeke P**, Corten K, Degreef I, Duerinckx J.

Hand Surg Rehabil. 2020 May 6; S2468-1229(20)30102-X. DOI: 10.1016/j.hansur.2020.04.008.

Is the flexion-abduction-supination magnetic resonance imaging view more accurate than standard magnetic resonance imaging in detecting distal biceps pathology?

Schenkels E, **Caekebeke P**, Swinnen L, Peeters J, van Riet R.

J Shoulder Elbow Surg. 2020 Dec;29(12):2654-2660. doi: 10.1016/j.jse.2020.05.014.

Accuracy and safety of the endoscopic repair of the distal biceps: a cadaveric study.

Caekebeke P, Galatz L, van Riet R.

Acta Orthop Belg. 2020 Dec;86(4):711-716.

In vitro biomechanical analysis of proximal phalangeal osteotomy fixation.

Deschuyffeleer S, Duerinckx J, **Caekebeke P**.

J Wrist Surg. 2021 Apr;10(2):154-157. doi: 10.1055/s-0040-1721409.

Fluoroscopy-guided cup placement in total trapeziometacarpal joint arthroplasty.

Dirkx G, **Caekebeke P**, Duerinckx J.

Hand Surg Rehabil. 2021 Apr;40(2):205-206. doi: 10.1016/j.hansur.2020.10.013.

Minimally invasive corrective osteotomy for metacarpal malrotation

Duerinckx J, **Caekebeke P**.

Techniques in Hand & Upper Extremity Surgery. May 2021

Postoperative rehabilitation in elbow surgery.

Verstuyft L, **Caekebeke P**, van Riet R.

J Clin Orthop Trauma. 2021 Jun 18;20:101479. doi: 10.1016/j.jcot.2021.101479.

Distal biceps provocation test.

Caekebeke P, Schenkels E, Bell S, van Riet R.

J hand surg Am. 2021. Mar 20;S0363-5023(21)00005-8.doi: 10.1016/j.jhsa.2020.12.012.

Acute complete and partial distal biceps tendon ruptures: what have we learned? A review.

Caekebeke P, Duerinckx J, van Riet R.

EFORT Open Rev. 2021 Oct 19;6(10):956-965. doi: 10.1302/2058-5241.6.200145.

Evaluation of clinical tests for partial distal biceps tendon ruptures and tendinitis.

Caekebeke P, Meglic U, van den Bekerom MPJ, van Riet R.

J Shoulder Elbow Surg. 2021 Nov 10;S1058-2746(21)00763-1. doi: 10.1016/j.jse.2021.10.012.

In vivo evaluation of a new intramedullary distal biceps tendon fixation device.

Caekebeke P, Vande Voorde K, Duerinckx J, van Riet R.

J Shoulder Elbow Surg. 2021 Dec;30(12):2869-2874. doi: 10.1016/j.jse.2021.06.006.

TEXTBOOK CHAPTERS

Caekebeke P, Meislin M, van Riet R. *Evaluation and management of posterolateral rotatory instability (PLRI)*. Book chapter in *The unstable elbow: an evidence-based approach to evaluation and management*, R.Z. Tashjian, Editor. 2016, Springer.

Caekebeke P, Bain GI, van Riet R. *Distal biceps tendon repair with the Endobutton technique*. Book chapter in *Surgical techniques for trauma and sports related injuries of the elbow*, G.I. Bain, D. Eygendaal and R. van Riet, Editors. 2019, Springer.

Caekebeke P, van Riet R. *Distal biceps endoscopy*. Book chapter in *Surgical Techniques for trauma and sports related injuries of the elbow*, G.I. Bain, D. Eygendaal and R. van Riet, Editors. 2019, Springer.

PEER REVIEW

Reviewer for:

Journal of Shoulder and Elbow Surgery (JSES)

Shoulder & Elbow

Journal of Bone and Joint Surgery (Essential Techniques)

Clinical Biomechanics

HONOURS AND AWARDS

Graduated as medical Doctor with High Honours, 2011

GRANTS

BVOT (Belgische vereniging voor orthopedie en traumatologie) Grant 2018

PROFESSIONAL MEMBERSHIPS

BVOT (Belgische vereniging voor orthopedie en traumatologie)

BELSS(Belgische vereniging voor schouder en elleboog chirurgie)

SECEC (European society for elbow and shoulder surgery): Ordinary member

BHG (Belgian hand group)

PANELS AND COMMITTIES

2020-2022: ESSKA elbow and wrist committee

2021-2024: Board member Belgian elbow and shoulder surgery society (BELSS)