Unilateral Cleft Lip Nasal Deformity: Three-Dimensional Analysis of the Primary Deformity and Longitudinal Changes following Primary Correction of the Nasal Foundation

Raymond W. Tse, M.D.
Robert Knight, M.D.
Makinna Oestreich, B.Sc.
Mica Rosser, B.Sc.
Ezgi Mercan, Ph.D.

Seattle, Wash.

Background: Objective assessment of the unilateral cleft lip nasal deformity and the longitudinal changes with treatment is critical for optimizing cleft care.

Methods: Consecutive patients undergoing cleft lip repair and foundation-based rhinoplasty were included (n = 102). Three-dimensional images preoperatively, postoperatively, and at 5 years of age were assessed and compared to age-matched controls. Images were normalized to standard horizontal, craniocaudal, and anteroposterior axes.

Results: Cleft subalare was similar in position relative to controls but was 1.6 mm retrodisplaced. Subnasale was deviated 4.6 mm lateral to midline and had the greatest displacement of any landmark. Noncleft subalare was displaced 2.3 mm laterally. Regression analysis with deviation of subnasale from the midline as a dependent variable revealed progressive lateral displacement of noncleft subalare, narrowing of noncleft nostril, and intercanthal widening. Surgery corrected nasal base displacements along all axes, resulting in landmark positions similar to controls. Symmetry of nasal base correction persisted at 5-year follow-up, with no recurrent cleft alar base retrusion, regardless of initial cleft type.

Conclusions: Unilateral cleft lip nasal deformity may be "driven" by displacement of the anterior nasal spine and caudal septum. The cleft alar base is normal in position but retruded, whereas the noncleft alar base is displaced laterally. Changes with surgery involve anterior movement of the cleft alar base but also include medial movement of the noncleft alar base and columella. Symmetry of correction, including alar base retrusion, was stable over time and did not rely on alveolar bone grafting. (*Plast. Reconstr. Surg.* 145: 185, 2020.)

Cleft lip is associated with a complex three-dimensional, twisted deformity of the nose. Displacement of nasal base elements results in a "tilted tripod,"[1] septal deformity, and collapse of the arch forms that define the nose.[2] Although primary correction is undertaken with initial cleft lip repair, recurrent deformity is common, and 35 to 74 percent of children require secondary revision.[3–7] Given that current surgical practices are guided by expert opinion and experience, objective understanding of the initial deformity and the longitudinal changes that occur with treatment and growth is critical to improving care.

In a separate report, we described an alternate approach to primary rhinoplasty and assessed the associated three-dimensional nasal changes.[8] Image audit revealed several surprising observations that challenge current concepts regarding the unilateral cleft lip nasal deformity. First, rather than lateral displacement of the cleft alar base,[9–14] it was the noncleft alar base that was farther from the facial midline (Fig. 1). Second, rather than the

From the Division of Craniofacial and Plastic Surgery, Seattle Children's Hospital; and the Division of Plastic Surgery, University of Washington.
Received for publication May 17, 2018; accepted May 2, 2019.
Presented at the 75th Annual Meeting of the American Cleft Palate–Craniofacial Association, in Pittsburgh, Pennsylvania, April 10 through 14, 2018.
Copyright © 2019 by the American Society of Plastic Surgeons
DOI: 10.1097/PRS.0000000000006389

Disclosure: *The authors have no financial interest to disclose.*

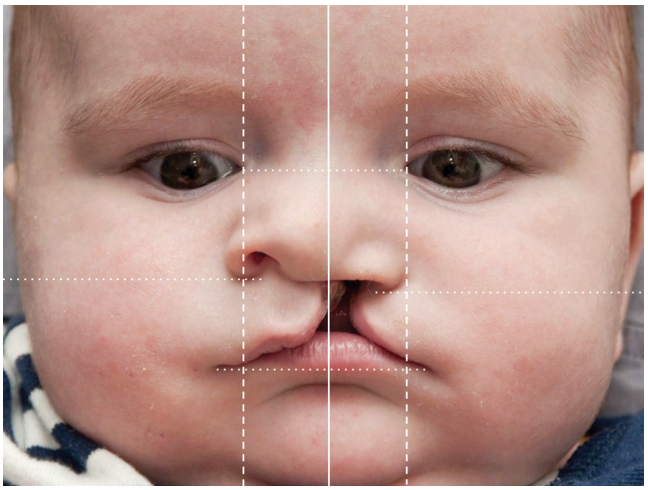

Fig. 1. The unilateral cleft lip nasal deformity. The noncleft alar base is displaced lateral relative to the cleft alar base.

cleft alar base moving medial with surgery, it was the noncleft alar base. Finally, rather than recurrent retrusion of the cleft alar base over time, the immediate postsurgical advancement was maintained. To formally investigate these observations, we undertook detailed quantitative three-dimensional spatial analysis of the nasal base with aims to assess the following:

1. Preoperative morphology of the unilateral cleft lip nasal deformity.
2. Changes that occur with cleft lip repair and our approach to primary rhinoplasty.[8]
3. Stability of surgical corrections over time.

PATIENTS AND METHODS

Subjects with Clefts

Consecutive patients undergoing cleft lip repair and foundation-based primary rhinoplasty from 2010 to 2013 were included (n = 102). Surgical details are described in a separate report.[8] Component reconstruction included approximation of nasal sill and lip as a single unit, creation of a perialar muscle sling, primary septal repositioning, nasal floor closure, and lateral nasal sidewall release and reconstruction. The approach aims to produce a stable foundation to address the underlying cause of the nasal deformity and involves no tip dissection.

We accessed our center's image database to obtain three-dimensional images (3dMD Cranial System; 3dMD, Atlanta, Ga.) preoperatively, postoperatively, and at late follow-up. Images were captured in the clinic by our center's professional imaging technologist. To avoid the influence of other surgical treatments, we excluded images following secondary alveolar bone grafting or other procedures that could alter nasal form.

Age-Matched Controls

Three-dimensional images of children without clefts were obtained from Craniobank[15] (6 months; n = 33) and FaceBase (www.facebase.org) (Accession FB00000491; project U01DE020078)[16] (5 years; n = 40).

Image Analysis

Standard anthropometric landmarks[17] were identified using 3dMD Vultus (Fig. 2). Images were normalized to standard axes using the inter-endocanthion line (en-en) to define the x axis (medial-lateral) and the midpoint of that line to define the facial midline. Images were rotated to the horizontal defined by Tanikawa et al.[18] so that y (craniocaudal) and z (anteroposterior) axes could be defined: images were set with a 7.5-degree downward rotation from the subnasale-tragal axis (Fig. 2). Images of patients with right clefts were reflected so that all images had left clefts.

Landmarks and changes with treatment and time were assessed along each axis and, when applicable, relative to the midline. Landmark positions on the noncleft side were reflected across the defined facial midline to measure relative displacement of corresponding cleft-side landmarks and to provide a matched-pair analysis of symmetry.

Statistical Analysis

Differences between groups were assessed using t test, with values of $p < 0.02$ considered significant. The relationship of landmark displacements was assessed using a linear regression model with the distance from the subnasale to the midline as the dependent variable. Significance was assessed by analysis of variance, with values of $p < 0.02$ considered significant. We applied a Bonferroni correction given the number of variables studied.

RESULTS

Subject demographics are summarized in Figure 3.

Preoperative: Alar Base Displacements

Landmark positions along x and y axes are summarized in Figure 4. Neither side of the nose was normal when comparing subjects to themselves and to controls. The noncleft subalare was farther lateral relative to midline than the cleft subalare; the cleft subalare was farther posterior relative to the noncleft side.

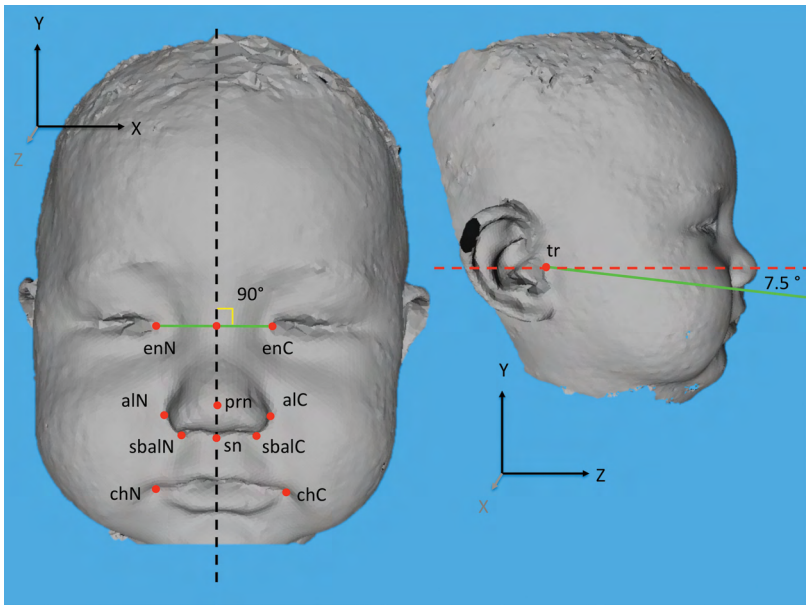

Fig. 2. Three-dimensional image analysis. (*Left*) Interendocanthion line defined the *x* axis and facial midline. Standard anthropometric landmarks included the following: endocanthion (*en*), pronasale (*prn*), alare (*al*), subalare (*sbal*), subnasale (*sn*), and chelion (*ch*). Images of subjects with clefts were normalized so that noncleft (*N*) side was on the right side of face and the cleft (*C*) side was on the left side of face. (*Right*) Images were normalized to a rotated Camper's plane [tragion (*tr*) to subnasale, −7.5 degrees] to define the horizontal and the *y* axis and *z* axis.[18]

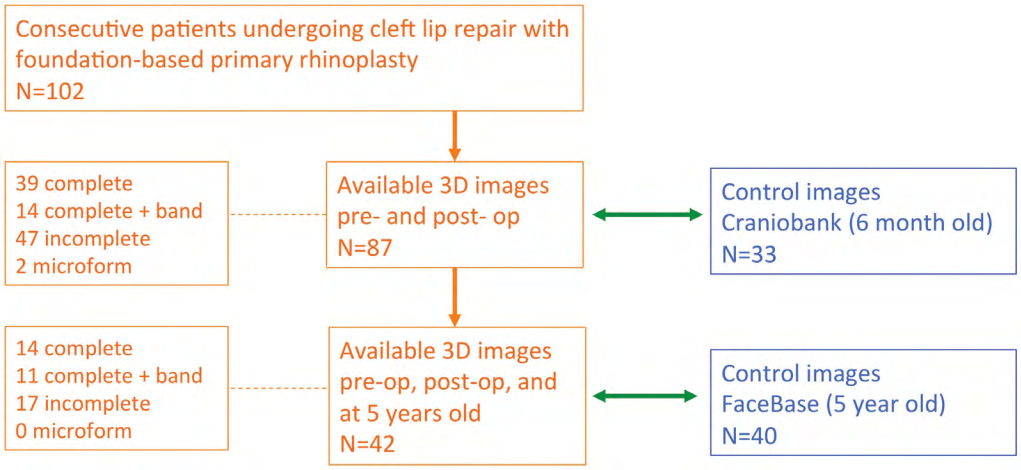

Fig. 3. Subjects and demographics. Analysis of 289 images involving 87 subjects with clefts and 73 age-matched controls. *3D*, three-dimensional.

When the noncleft subalare was reflected across the facial midline, the cleft subalare was 2.3 mm medial (closer to the midline) and 1.5 mm inferior to the reflected point. The asymmetry of subalare landmarks was progressively greater for more severe cleft types with increasing lateral and superior displacement of the noncleft subalare (Table 1).

When comparing subjects with clefts to controls, the cleft subalare was normal in position, whereas the noncleft subalare was displaced lateral and superior. Landmark positions along the *z* axis (anteroposterior) are summarized in Figure 5. The cleft subalare was 1.6 mm posterior relative to the noncleft side and 2.1 mm posterior relative to controls. Displacements were

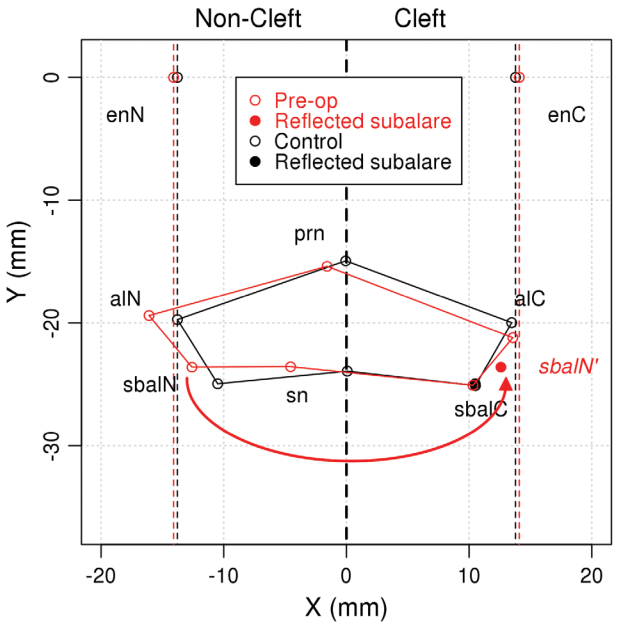

Fig. 4. Preoperative plot of landmarks along the *x* and *y* axes. Average cleft subject landmarks are in *red outline* with the position of the noncleft subalare, reflected across the midline, marked in *solid red* (*sbalN′*). Average age-matched control subject landmarks are in *black outline*, with reflected subalare marked in *solid black*. The subnasale (*sn*) and noncleft subalare (*sbalN*) were displaced superior and lateral, whereas the position of the cleft subalare (*sbalC*) was further medial and matched that of control subjects. *en*, endocanthion; *prn*, pronasale alare; *al*, alare; *sbal*, subalare; *C*, cleft side; *N*, noncleft side.

progressively greater with increasing cleft type (Table 1)

Preoperative: Subnasale Displacement Drives Deformity

Among landmarks assessed, the single greatest displacement, compared to controls, was that of the subnasale (Table 1). Mean *x*-axis displacement was 4.6 mm for all subjects (2.7 mm for incomplete and 6.2 mm for complete).

We found that increasing deviation of subnasale was associated with increasing severity of cleft type and displacement of landmarks. Figure 6 illustrates the pattern of deformation that occurs when the distance of the subnasale from the midline was used as the dependent variable in a regression model. On the cleft side, there was no change along the *x* axis, but there was progressively greater retropositioning along the *z* axis. On the noncleft side, there was lateral displacement of the subalare, but the widening was proportionately less than the displacement of the subnasale. As a result, progressive widening of the cleft-side nostril was associated with progressive narrowing

Table 1. Landmark Distances

Comparison to Control	*x* (mm)	*y* (mm)	*z* (mm)
Preoperative sn vs. control sn			
All	−4.62*	0.36	−1.43*
Complete	−6.23*	0.36	−1.92*
Complete with band	−4.55*	1.11	−1.47
Incomplete	−2.71*	−0.22	−0.80
Preoperative noncleft sbal vs. control sbal			
All	−2.10*	1.35	−1.01*
Complete	−3.07*	1.77	−1.56*
Complete with band	−2.36*	2.06	−1.13
Incomplete	−0.71	0.29	−0.24
Preoperative cleft sbal vs. control sbal			
All	−0.21	0.03	−2.07*
Complete	0.04	−0.24	−4.42*
Complete with band	−0.50	0.94	−2.71*
Incomplete	−0.28	−0.38	−0.60
Alar base symmetry			
Preoperative noncleft sbal vs. cleft sbal			
All	−2.28*	−1.47*	−1.57*
Complete	−3.01*	−2.16*	−2.74*
Complete with band	−2.83*	−1.26	−1.46
Incomplete	−0.97	−0.81	−0.25
Postoperative noncleft sbal vs. cleft sbal			
All	−0.73	−0.13	0.52
Complete	−1.37*	−0.19	0.33
Complete with band	−0.60	−0.02	0.16
Incomplete	−0.04	−0.13	1.07

sn, subnasion; sbal, subalare.
*Significant difference between landmark positions ($p < 0.02$).

of the non–cleft-side nostril. In addition, we found that increasing deviation of the subnasale from the midline was also associated with progressive widening of the intercanthal distance. All of the associations were statistically significant ($p < 0.02$). When the Bonferroni correction was applied, all associations remained significant, except for intercanthal widening.

Changes with Surgery

The largest magnitude changes were in movement of the subnasale and the noncleft alar base position (Figs. 7 and 8). Both shifted medial. There was little medial movement of the cleft alar base position along the *x* axis; however, there was significant anterior movement along the *z* axis (Figs. 7 and 9). Alar base and subnasale correction approached that of normal controls along all axes. Cleft and noncleft alar base positions were within 1 mm following surgery when landmarks were reflected across the midline (Table 1).

Stability of Correction

Symmetry of alar base correction and midline position of the subnasale persisted at 5 years (Fig. 8) and was within 2 mm (Figs. 10 and 11).

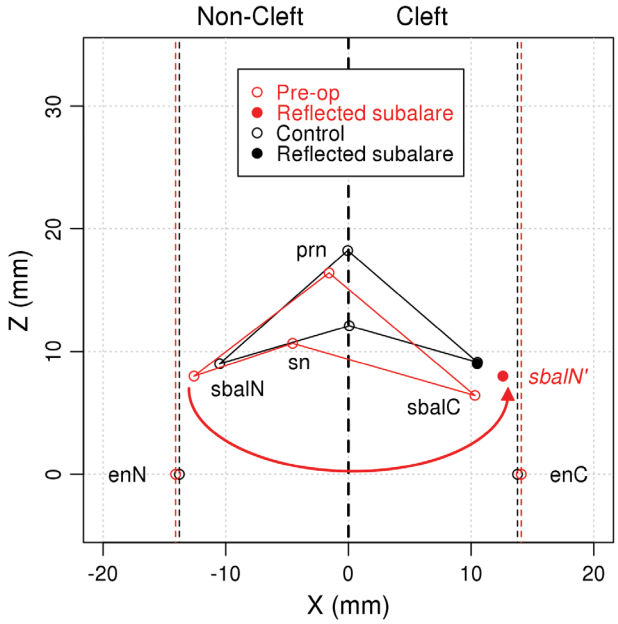

Fig. 5. Preoperative scatter plot of landmarks along the *x* and *z* axes. Average cleft subject landmarks are in *red outline*, with the position of the noncleft subalare reflected across the midline marked in *solid red* (*sbalN'*). Average age-matched control subject landmarks are in *black outline*, with reflected subalare marked in *solid black*. The cleft subalare (*sbalC*) was retropositioned relative to the noncleft side and to control subjects. *en*, endocanthion; *prn*, pronasale alare; *al*, alare; *sbal*, subalare; *C*, cleft side; *N*, noncleft side.

Overcorrection of alar base retrusion was also stable (Fig. 9), with persistent relative protrusion of 1 to 2 mm (Fig. 12).

Relative to controls, subjects with clefts had symmetric widening of the alar base and loss of nasal projection. However, symmetry of the alar base and proximity of the subnasale to the midline was similar (Fig. 8).

Changes and Stability for Each Cleft Type

Nasal base displacements were progressively greater for increasing cleft severity (Figs. 10 through 12). Landmark positions normalized following surgery, regardless of cleft type. Variance in relative nasal base positions was within the same range as age-matched controls. Alar base retrusion normalized for all cleft types and remained stable at 5 years of age, before secondary alveolar bone grafting (Fig. 12).

DISCUSSION

Correction of the unilateral cleft lip nasal deformity remains a surgical problem without an optimal solution. Objective understanding of the primary deformity, alterations with treatment, and changes with time and growth are key to realizing more ideal algorithms. Findings of this study were unexpected and change our perceptions of the primary deformity and approaches to reconstruction (Table 2).

Preoperative Nasal Deformity

The unilateral cleft lip nasal deformity is classically described as one that arises from lateral and inferior displacement of the cleft side alar base,[9–14] with the noncleft side considered normal. Findings of our study disagree. Neither side is normal, and rather than the cleft alar base, it is the noncleft alar base that is displaced laterally relative to the facial midline (Figs. 1 and 13).

Based on our analysis of three-dimensional images, displacement of the subnasale is the single greatest abnormality and correlates with progressive nasofacial deformation that involves posterior displacement of the cleft alar base, lateral displacement of the noncleft alar base, narrowing of the noncleft nostril width, and widening of the intercanthal distance. In addition, as opposed to previous reports that the septum is dislocated onto the noncleft side of the anterior nasal spine,[12,19] we found that the caudal septum was always tightly associated with the anterior nasal spine. Together, these findings suggest that the anterior nasal spine or caudal septum drive the deformity of the nose. We surmise that disruption of the horizontal buttress of the maxilla results in a "split" that ascends the bony skeleton (Fig. 14). Mechanical forces from upward thrust of the tongue and mandible combined with the uncoupled growth of the premaxilla on one side result in projection and lateral twist of the premaxilla. The cleft alar base is left behind and the noncleft alar base is driven forward and lateral. This would explain the progressive narrowing of the noncleft nostril and widening of the intercanthal distance with greater displacement of the subnasale from midline. It would also explain why the deformity of the palate and vomer conspicuously match the shape of the tongue (Fig. 13).

The findings of this study complement current models of the cleft lip nasal deformity. Our observations are consistent with Latham's cadaveric studies in which the anterior nasal spine results from calcification of the septopremaxillary ligament as the premaxilla and lateral maxillary processes fuse.[20]

They confirm the displacement of the base elements of the tilted tripod model[1] and provide some insight regarding the patterns of that

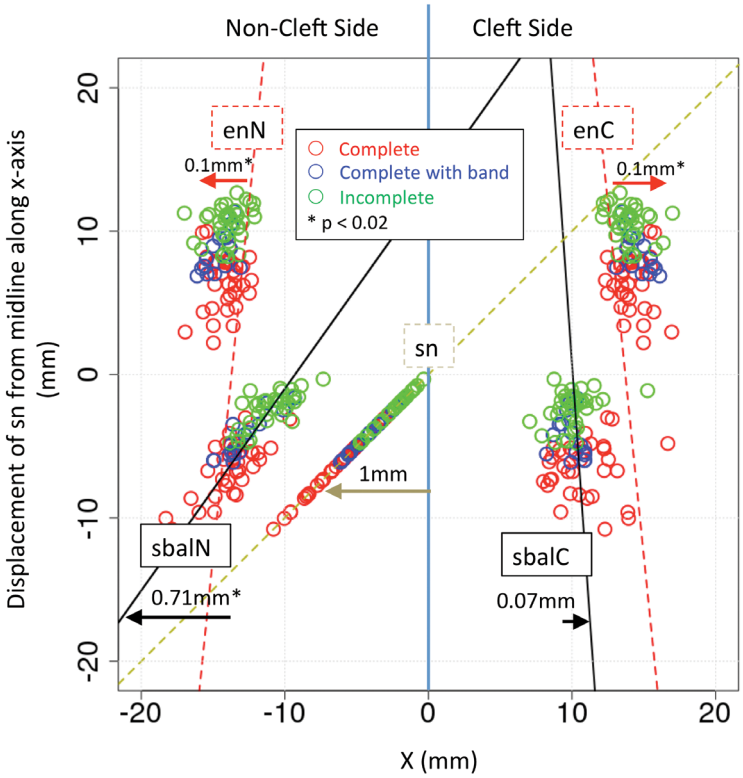

Fig. 6. Preoperative deformity versus subnasale displacement. Subjects with clefts were ordered according to *x* axis displacement of the subnasale (*sn*) from the midline. There was increasing subnasale displacement with greater severity of cleft type (complete > complete with band > incomplete). Regression analysis was performed to assess *x* axis changes of other landmarks with displacement of the subnasale. There was no significant change in the cleft subalare (*sbalC*), whereas there was significant lateral displacement of the noncleft subalare (*sbalN*), narrowing of the noncleft nostril, and widening of the intercanthal distance. *en*, endocanthion; *sbal*, subalare; *C*, cleft side; *N*, noncleft side.

displacement. Fisher and Mann proposed that the nose is composed of horizontal and oblique arch forms that collapse with displacement of base elements.[2] Fisher et al. later studied computed tomographic scans of 12 infants with complete unilateral cleft lip and palate and described displacement of base elements similar to what we found.[21] Our study differs in that we examined 87 subjects who spanned the spectrum of unilateral cleft lip and had a control group for comparison. We found a progression of deformity that seemed to follow the lateral deviation of subnasale and "split" of the facial skeleton. Given that widening of the maxillary arch has been found with greater cleft severity[22–25] and our finding that intercanthal distance increased with deviation of the subnasale, a progressive "split" of the facial skeleton is plausible and is consistent with Latham's concept of premaxillary growth.[20] The ascending deformation is also consistent with previous findings of upper lateral cartilage asymmetry,[26–29] dissociation of upper and lower cartilages,[26,30] nasal bone deviation,[28,29,31,32] and cranial base asymmetry.[33] Although reports of hypertelorism related to orofacial clefts have been inconsistent and contradictory,[34] we found a clear progressive widening when subnasale deviation was used as an indication of cleft deformity across the spectrum of presentation of unilateral cleft lip. The findings of our study and the concept of an ascending deformity of the facial skeleton provide a common thread that can link previous models and observations regarding the unilateral cleft deformity.

Surgical Changes

We have previously understood that correction of the cleft alar base involves release and medial, superior, and anterior positioning to match the

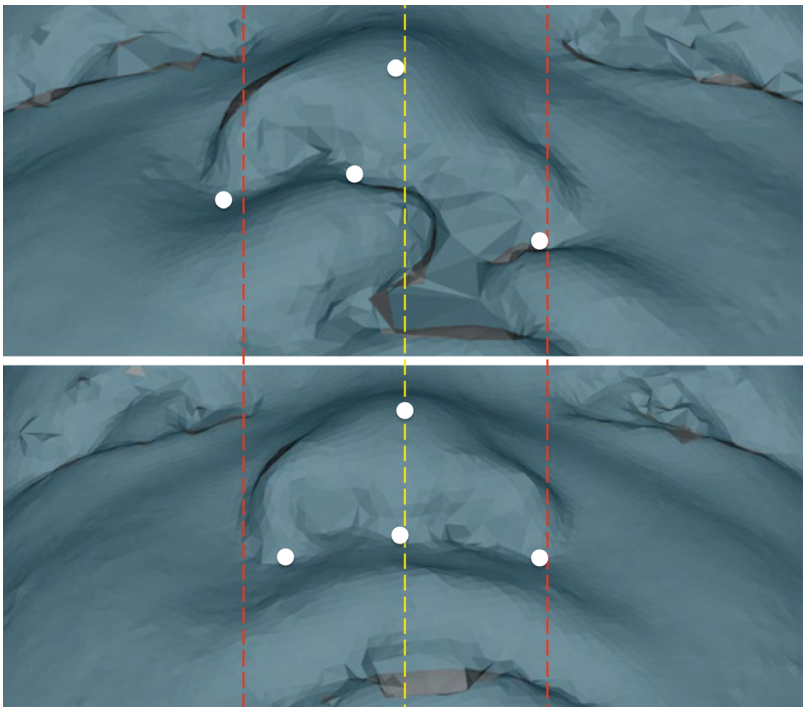

Fig. 7. Example three-dimensional images of subject before and after cleft lip repair with foundation-based primary rhinoplasty. The cleft alar base is posterior and moves anterior. The noncleft alar base and columella are displaced laterally and move medial.

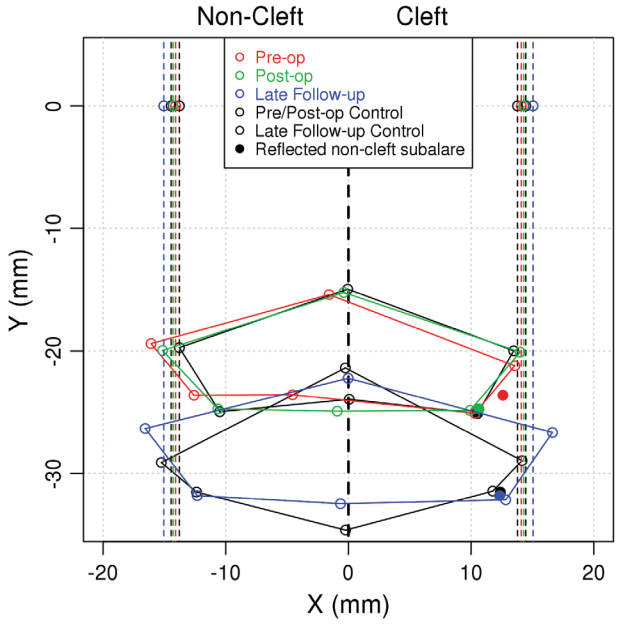

Fig. 8. Surgical changes and stability with time and growth (*x* and *y* axes). Surgical changes occurred primarily on the noncleft side, with shift of the subnasale to the midline and medial movement of the subalare to match the cleft side. There was no significant change in cleft subalare along *x* and *y* axes. Landmarks postoperatively approximated those of age-matched controls. Symmetry of nasal base correction persisted with time and growth, but there was widening relative to the older control image set.

noncleft side. Others have described the same.[35] This would make inherent sense given the muscle release, wide dissection over the anterior maxilla, and complete release along the piriform aperture that all occur on the cleft side. As opposed to these expected changes, we found that it is the noncleft alar base that moves medially, whereas the cleft alar base only moves anteriorly (and does not change horizontal position) (Figs. 7 and 13). These movements were surprising given that the noncleft alar base is outside of the surgical site of dissection and no alar cinch suture is performed. Correction of caudal septal position can account for movement of the subnasale to midline. Further medial movement of the noncleft alar base is likely from insertion of the lateral lip musculature into the dead space under the columella, thereby acting to tension the alar bases together. Even though the changes were not as expected, the surgical approach used in this study corrected the nasal base elements such that they were symmetric and similar to that of control subjects.

Stability of Correction

Recurrent or persistent cleft lip nasal deformity has been attributed to recurrent or residual alar base retrusion.[36–38] Studies of bony anatomy

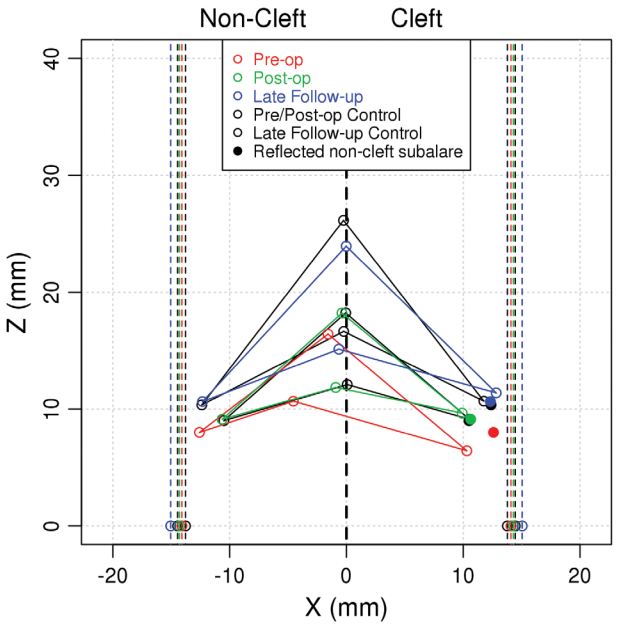

Fig. 9. Surgical changes and stability with time and growth (*x* and *z* axes). Surgical changes occurred primarily on the cleft side, with correction of the alar base retrusion that approximated age-matched control subjects. Symmetry of nasal base correction persisted with time and growth, but there was widening relative to the older control image set.

using computed tomographic scans document persistent anterior nasal spine deviation and cleft piriform retrusion following cleft lip repair and beyond 10 years of age.[37,39–42] As such, it is commonly believed that the ultimate correction of the nose requires correction of the bony base[11,13,40,43] by means of secondary alveolar bone grafting.[36,44–48] We found that three-dimensional alar base symmetry could be achieved immediately after primary repair and that symmetry of nasal base correction persisted with time and growth in all planes, including the *z* axis (anteroposterior). This was true regardless of cleft type or width of bony defect. Follow-up was 5 years and was before alveolar bone grafting. Based on these findings, stable anteroposterior correction of the alar base can be achieved without addressing the bony base.

Although we found that symmetry of nasal base correction persisted with time and growth, we found that both alar bases tended to widen with reduced pronasale projection when compared to age-matched control subjects. There may be several reasons for the differences between cleft and control subjects. The first is that longitudinal three-dimensional images of control subjects were not available and we used two sets of control images for comparison that included differing racial demographics. Images from Craniobank (used to compare cleft subjects immediately preoperatively and postoperatively) included a large number of African American subjects, whereas images from FaceBase (used to compare cleft subjects at 5 years of age) consisted of subjects of European Caucasian ancestry. Although

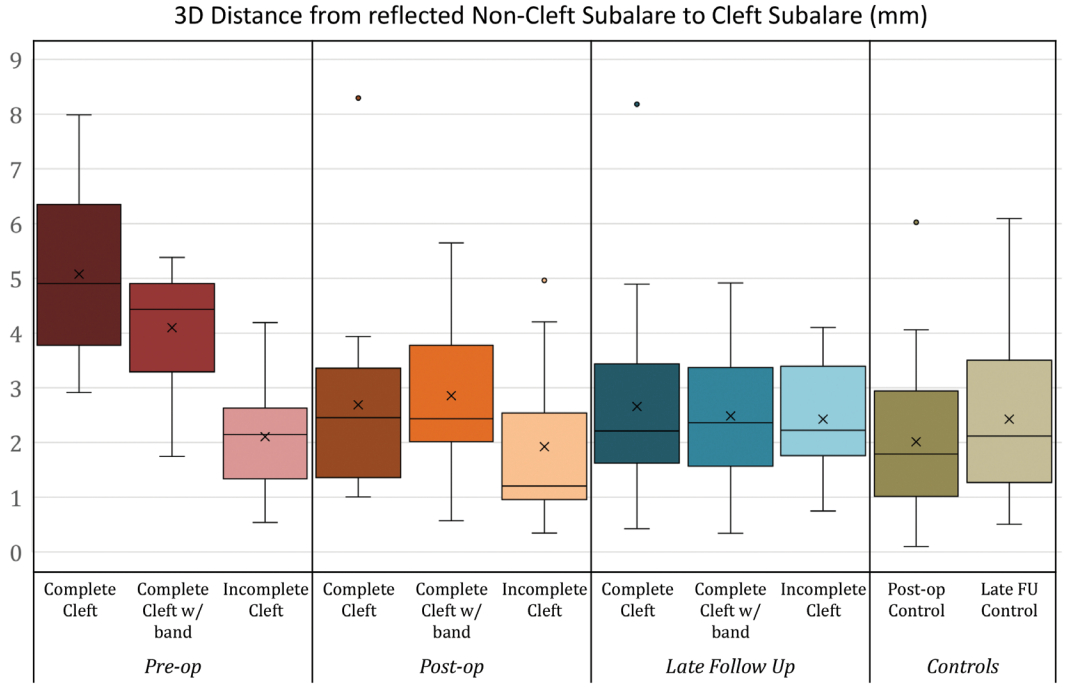

Fig. 10. Alar base differences by cleft type. Relative displacements normalized following surgery and persisted at 5 years of age, with variance similar to age-matched normal controls. *FU*, follow-up.

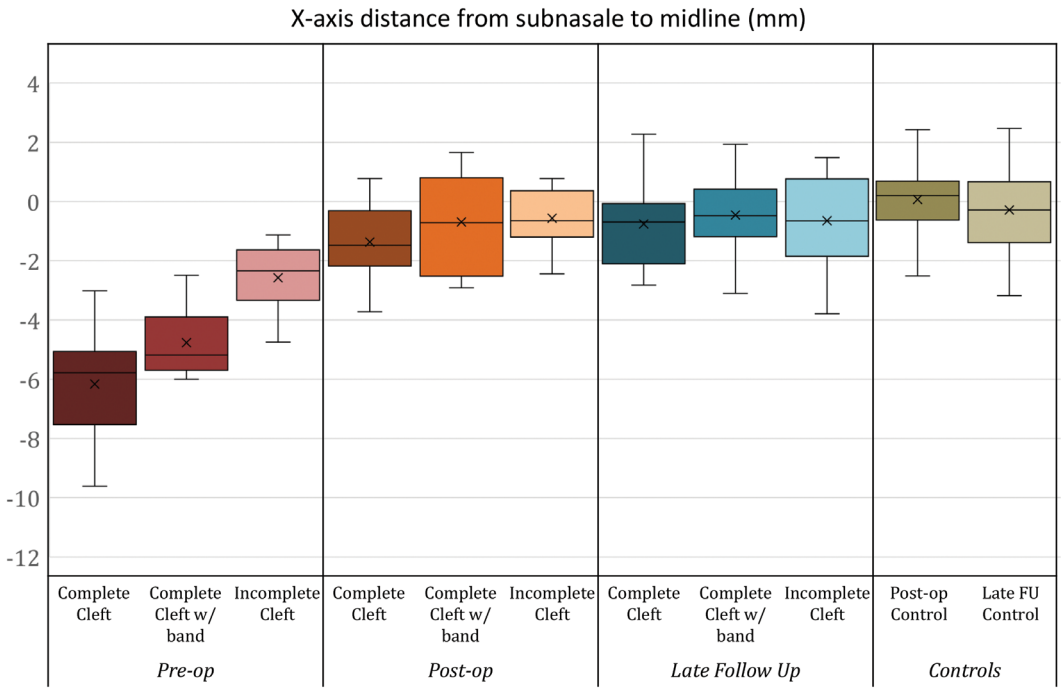

Fig. 11. Subnasale deviation by cleft type. Deviation normalized following surgery and persisted at 5 years of age, with variance similar to age-matched controls. *FU*, follow-up.

facial symmetry may be expected across racial variations, nasal width and facial projection could differ and account for some of the differences. The second may be that there is a progressive stretching of tissues that occurs following repair such that the interalar distance widens and the nasal tip loses

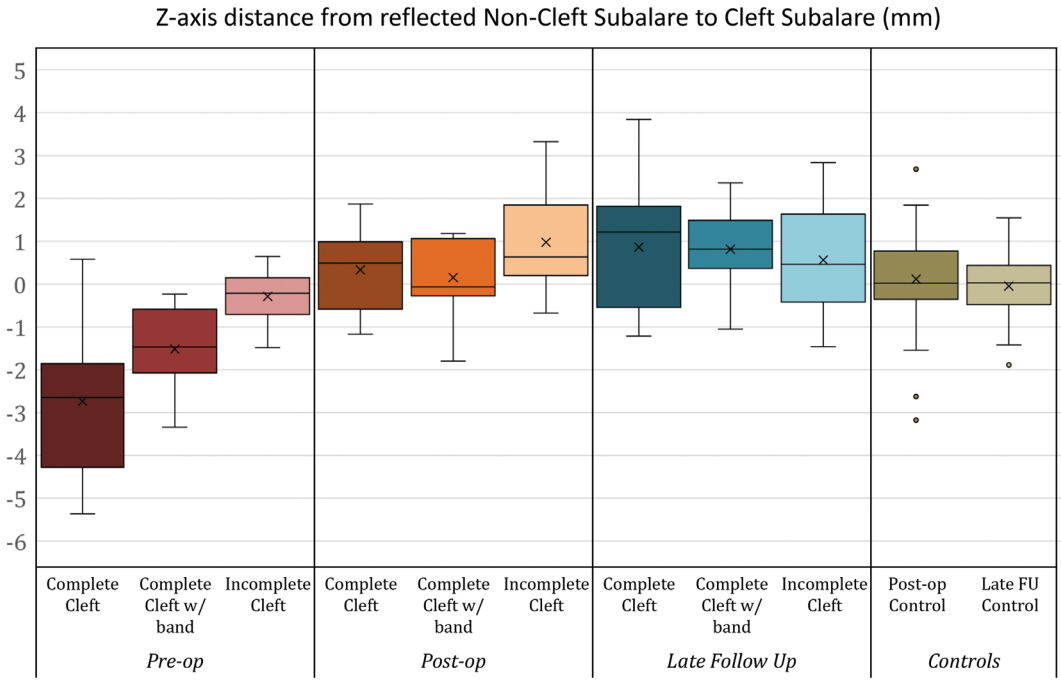

Fig. 12. Surgical correction of cleft alar base retrusion across cleft types. Alar base retrusion was corrected across cleft types. The correction persisted until late follow-up (average age, 5 years), before alveolar bone grafting. The correction was similar to variance in alar base position among age-matched control groups. *FU*, follow-up.

Table 2. Paradigms

	Concept	Paradigm Shift
Unrepaired unilateral cleft lip nasal deformity	The noncleft side is normal	Neither side is normal
	The cleft alar base is displaced laterally	The cleft alar base is displaced posteriorly and the columella and noncleft alar base are displaced laterally
	Widening of the cleft alar base drives the deformity	Projection and deviation of the anterior nasal spine drive the deformity
	The cleft side nostril widens with increasing deformity	The cleft side nostril widens *and* the noncleft side nostril narrows with increasing deformity
	The caudal septum is dislocated onto the noncleft side of the anterior nasal spine	The caudal septum is tightly associated with the anterior nasal spine, which can be split/bifid and deviated away from midline
	The deformity involves the nasolabial region	The deformity involves the nasolabial region and ascends the cranial base
Surgical changes to correct nasal base	The cleft alar base moves medial, superior, and anterior	The cleft alar base moves anterior *and* the noncleft alar base and columella move medial
Stability of surgical changes	Stable anteroposterior correction of alar base cannot be achieved until alveolar bone grafting	Stable anteroposterior correction of alar base can be achieved before alveolar bone grafting, regardless of cleft width

projection. The third may be that there is some degree of growth reduction among subjects with clefts relative to control subjects. Hypoplasia may be inherent in orofacial clefts.[49,50] It is also generally accepted that scarification from surgery has a cumulative effect on facial growth.[51] That effect has been found with both cleft lip repair[38,50,52,53] and cleft palate repair.[50,54,55] We cannot determine whether any additional growth change results from the approach we used for nasal correction. Previous studies have not demonstrated any greater growth disturbance from primary septoplasty[19,35,56–58] or nasal floor[59] closure relative to children who undergo cleft surgery without these adjunctive procedures. Future studies to formally examine patterns of facial growth are needed.

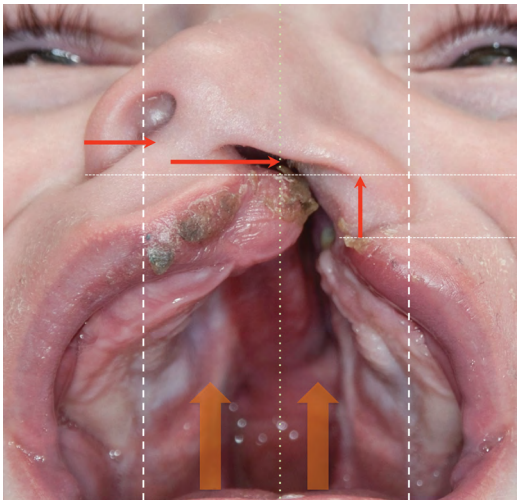

Fig. 13. Unilateral cleft deformity (same patient as in Fig. 1). The cleft alar base is retruded but normal in horizontal position. The noncleft alar base and columella are deviated laterally. Correction requires movement of each component along respective vectors (*red arrows*). Preoperative morphology may provide insights regarding "forces" at play. The vomer/septum is visible through the cleft but collapsed so that the most caudal margin deviates away from midline. The "fold"/site of vertical collapse is visible and the combined palatal and vomer/septal surfaces conspicuously take on the shape of the tongue. Loss of horizontal maxillary integrity may make the facial skeleton prone to collapse and widening of vertical buttresses and an ascending "split." Unhinged premaxillary growth on one side produces the anterior twist.

Approaches to Correction of Cleft Lip Nasal Deformity

Given that the most apparent and recognizable feature of the cleft lip nasal deformity is the asymmetric dissociation and collapse of lower lateral cartilages, correction of the nasal tip has become the focus of primary rhinoplasty. Although considerable improvement occurs by bringing the cartilages into apposition, recurrent or persistent deformity is common. This may be attributable to the unaddressed bony base or "foundation."

In a separate report, we described an alternate approach to primary rhinoplasty that focuses on the foundation to "upright the nose."[8] The approach may not seem intuitive; however, by correcting the underlying causes of the derangement, the "downstream" deformity may be improved. We have measured significant changes in nasal shape and symmetry, without direct nasal tip correction.[8]

Although we cannot directly compare either approach, in our experience, the foundation approach seems to produce adequate correction (Fig. 15). We do not plan on revisions, and few families have opted for them. If revision is needed, the stable and level foundation and the preservation of tissue planes may facilitate subsequent surgery.

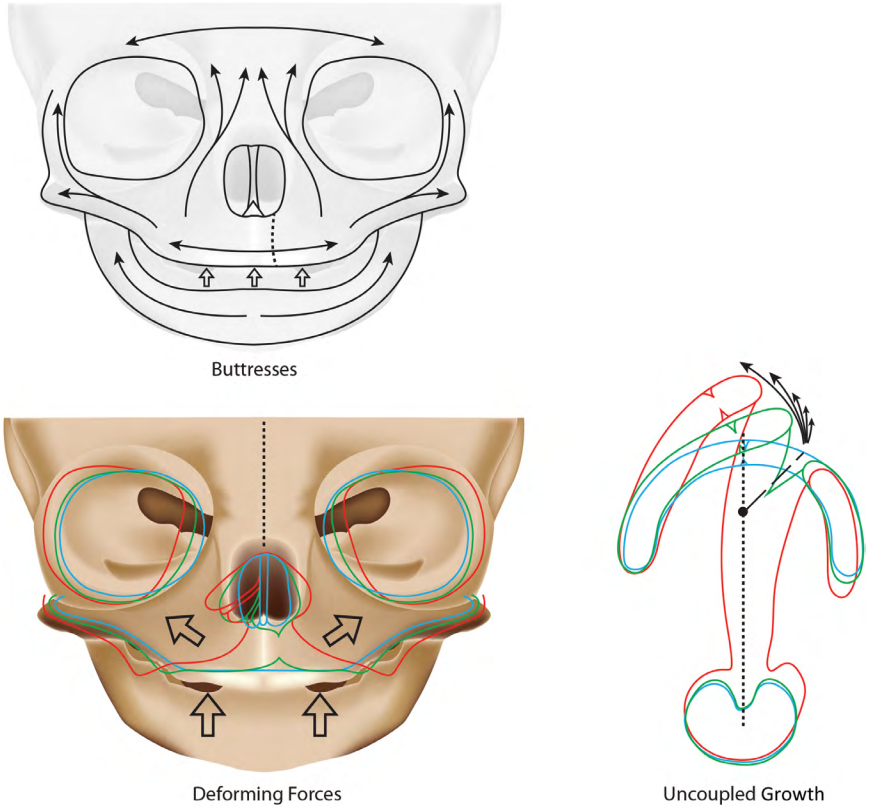

Fig. 14. Proposed concepts underlying unilateral cleft lip deformity. Ascending "split" in the facial skeleton explains decreasing but measurable alterations from the palate to the cranial base. Mechanical forces of tongue and occlusion may drive the collapse. Uncoupled premaxillary growth, that is progressively greater with greater cleft extent, produces the anterior twist.

Cutting et al. have previously warned that alar base correction in the absence of tip correction can produce a "small-nostril" deformity.[60] Their hypothesis was based on a study that assessed patients undergoing rotation-advancement with a collapsed nasal dome. We have not found that our approach produces such a deformity. The combination of septoplasty, lateral sidewall reconstruction, and extended nasal floor closure effectively elevate the dome[8] (Fig. 15). We also avoid the perialar incision used for rotation-advancement that can "bury" an incompletely released or uncorrected nose (i.e., as the lip is advanced across a collapsed dome). By maintaining the ala, sill, and upper lip as a single unit, micronostril can only be produced by overresection of the nasal sill/floor.

Sir Harold Gillies once wrote, "never do today what can honourably be put off till tomorrow." Primary rhinoplasty, whether working on the foundation, the tip, or both, can be technically demanding. An individual surgeon should decide on the components of correction that they are capable of executing reliably while considering the long-term outcomes, burden of care at each stage, and evidence available.

Perceptions of Symmetry and Form

The common perception that the cleft alar base is displaced laterally (rather than the noncleft alar base) is likely attributable to our cognition that uses the nasal dorsum as reference and our tolerance to the shift in nasal dorsal position or axis. If we do not recognize deviation of the lower nose as a deformity, the cleft alar base would clearly be laterally displaced. It is only with objective analysis or use of reference lines that we more easily recognize the nasal shift and displacement on the noncleft side (Figs. 1 and 13).

The cognition of human perceptions of nasal form is beyond the scope of this study; however, it may be that reconstruction of "local" recognizable nasal form (a concept similar to "averageness") is more important than shifts in nasal position or axis that would more significantly impact any measures of "global" symmetry. Further understanding



Fig. 15. Clinical example. The dome elevates with correction of the nasal foundation. Stable foundation at 5 years of age with preservation of nasal tip tissue planes.

of these perceptions may help us to better prioritize reconstructive goals and methods to measure outcomes.

Regardless of those perceptions, the findings of this study change some of our fundamental understanding of the primary unilateral cleft lip nasal deformity and the changes that we need to produce with surgical correction. The cleft alar base is not laterally displaced; rather, the lower nose is deviated and twisted away from midline. If we are to correct that primary deformity, we need to produce the corresponding changes.

Limitations of Methodology

Although few studies use objective measures to track longitudinal changes[60–62] and none include age-matched controls, several limitations of our study need to be acknowledged. Three-dimensional stereophotogrammetry is new, and there currently is no standard method of

three-dimensional registration and alignment of facial surface images. We chose to use the endocanthion line (en-en) to define the *x* axis given the human tendency to recognize eyes as a reference when examining a face (as confirmed by multiple eye-tracking studies[63–67]) and because this method has been found to produce the most valid three-dimensional midfacial reference plane on a facial mesh, even when compared to computer-based methods.[68] We have repeated our analysis using other methods of defining the *x* axis (using the en-en , ex-en-en-ex, and tr-tr lines), but this has not altered our findings.

As discussed, the racial background of our study population (multiple and mixed) did not fully match that of our control images. This may produce error when comparing facial proportions but is unlikely to produce significant error when comparing relative symmetry. Although normative pediatric three-dimensional image databases[16,69,70] are currently limited, better matching sets may become available in the future.

We found that the intercanthal distance widened with deviation of the subnasale from the midline on our initial regression analysis. That correlation was no longer significant with Bonferroni correction and at this point can only be considered our suspicion. Bonferroni correction has a tendency to produce false-negative results, and the magnitude of intercanthal widening relative to other facial dimensions may make this effect less apparent. With a larger population, the correlation may become clear.

Finally, this study was designed to assess nasal base changes with our approach and does not involve any direct comparisons. Other approaches may produce different changes and may have relative advantages and disadvantages. Through further objective audits, we might find ways to optimize long-term outcome and minimize patient burden.

CONCLUSIONS

Caudal septum deviation as measured by displacement of the subnasale from the midline drives the unilateral cleft lip nasal deformity. The noncleft alar base is displaced lateral, whereas the cleft alar base is left behind posteriorly. Noncleft nostril narrows and intercanthal distance widens with greater deformity. Foundation-based primary rhinoplasty involves significant medial movement of the noncleft alar base and columella with anterior movement of the cleft alar base. In this study, the approach corrected nasal base asymmetry along all axes (*x*, *y*, and *z*). Postoperative nasal base symmetry was similar to that of control subjects and persisted with time and growth.

Raymond W. Tse, M.D.
Seattle Children's Hospital
4800 Sand Point Way NE
Mail Stop OB.9.527
Seattle, Wash. 98105
raymond.tse@seattlechildrens.org

ACKNOWLEDGMENTS

We wish to thank Alex Kane, M.D., and Rami Hallac, Ph.D., of the University of Texas Southwestern/Children's Medical Center Analytic Imaging and Modeling Center for access to Craniobank images. We would also like to acknowledge FaceBase for access to normative images. The FaceBase Data Management Hub and the FaceBase Consortium are funded by the National Institute of Dental and Craniofacial Research. Thanks also to Chad Purnell, M.D., for assistance with manuscript editing.

PATIENT CONSENT

Parents or guardians provided written consent for the use of patients' images.

REFERENCES

1. Hogan VM. The tilted tripod: A theory of unilateral cleft lip nasal deformity. In: Hueston JT, ed. *Transactions of the Fifth International Congress of Plastic and Reconstructive Surgery.* Melbourne, Australia: Butterworths, 1971.
2. Fisher DM, Mann RJ. A model for the cleft lip nasal deformity. *Plast Reconstr Surg.* 1998;101:1448–1456.
3. Salyer KE, Xu H, Genecov ER. Unilateral cleft lip and nose repair; closed approach Dallas protocol completed patients. *J Craniofac Surg.* 2009;20(Suppl 2):1939–1955.
4. Mulliken JB, Martínez-Pérez D. The principle of rotation advancement for repair of unilateral complete cleft lip and nasal deformity: Technical variations and analysis of results. *Plast Reconstr Surg.* 1999;104:1247–1260.
5. Tajima S. Follow-up results of the unilateral primary cleft lip operation with special reference to primary nasal correction by the author's method. *Facial Plast Surg.* 1990;7:97–104.
6. Kane AA, Pilgram TK, Moshiri M, Marsh JL. Long-term outcome of cleft lip nasal reconstruction in childhood. *Plast Reconstr Surg.* 2000;105:1600–1608.
7. Salyer KE, Genecov ER, Genecov DG. Unilateral cleft lip-nose repair: A 33-year experience. *J Craniofac Surg.* 2003;14:549–558.
8. Tse RW, Mercan E, Fisher DM, Hopper RA, Birgfeld CB, Gruss JS. Unilateral cleft lip nasal deformity: Foundation-based approach to primary rhinoplasty. *Plast Reconstr Surg.* 2019;144:1138-1149.
9. Henry C, Samson T, Mackay D. Evidence-based medicine: The cleft lip nasal deformity. *Plast Reconstr Surg.* 2014;133:1276–1288.
10. Salyer KE, Marchac A, Chang M-S, Michienzi J, Genecov ER. Unilateral cleft lip/nose repair. In: Losee JE, Kirschner RE, eds. *Comprehensive Cleft Care.* New York: McGraw-Hill Medical; 2009:299–329.

11. Buchanan EP, Monson LA, Lee DY, et al. Secondary deformities of the cleft lip, palate, and nose. In: Neligan PC, ed. *Plastic Surgery*. Vol. 3. 4th ed. Philadelphia: Elsevier; 2017:637–659.
12. Greives MR, Camison L, Losee JE. Evidence-based medicine: Unilateral cleft lip and nose repair. *Plast Reconstr Surg*. 2014;134:1372–1380.
13. Guyuron B. MOC-PS(SM) CME article: Late cleft lip nasal deformity. *Plast Reconstr Surg*. 2008;121(Suppl):1–11.
14. LaRossa D. Unilateral cleft lip repair. In: Achauer BM, Eriksson E, Guyuron B, Coleman JJ, Russell RC, eds. *Plastic Surgery: Indications, Operations, Outcomes*. Vol. 2. Philadelphia: Elsevier Health Sciences; 2000:755–767.
15. Lipira AB, Sachanandani NS, Govier D, et al. Craniobank: An online collection of three-dimensional normative craniofacial images. *Plast Reconstr Surg*. 2010;126:70e–72e.
16. Weinberg SM, Raffensperger ZD, Kesterke MJ, et al. The 3D facial norms database: Part 1. A Web-based craniofacial anthropometric and image repository for the clinical and research community. *Cleft Palate Craniofac J*. 2016;53:e185–e197.
17. Tse R, Booth L, Keys K, et al. Reliability of nasolabial anthropometric measures using three-dimensional stereophotogrammetry in infants with unrepaired unilateral cleft lip. *Plast Reconstr Surg*. 2014;133:530e–542e.
18. Tanikawa C, Takada K, van Aalst J, Trotman CA. Objective three-dimensional assessment of lip form in patients with repaired cleft lip. *Cleft Palate Craniofac J*. 2010;47:611–622.
19. Morselli PG, Pinto V, Negosanti L, Firinu A, Fabbri E. Early correction of septum JJ deformity in unilateral cleft lip–cleft palate. *Plast Reconstr Surg*. 2012;130:434e–441e.
20. Latham RA. The pathogenesis of the skeletal deformity associated with unilateral cleft lip and palate. *Cleft Palate J*. 1969;6:404–414.
21. Fisher DM, Lo LJ, Chen YR, Noordhoff MS. Three-dimensional computed tomographic analysis of the primary nasal deformity in 3-month-old infants with complete unilateral cleft lip and palate. *Plast Reconstr Surg*. 1999;103:1826–1834.
22. Mello BZF, Fernandes VM, Carrara CFC, Machado MAAM, Garib DG, Oliveira TM. Evaluation of the intercanine distance in newborns with cleft lip and palate using 3D digital casts. *Int J Oral Maxillofac Surg*. 2009;38:1025–1029.
23. Harila V, Ylikontiola LP, Palola R, Sándor GK. Maxillary arch dimensions in cleft infants in Northern Finland. *Acta Odontol Scand*. 2013;71:930–936.
24. Lo LJ, Wong FH, Chen YR, Lin WY, Ko EW. Palatal surface area measurement: Comparisons among different cleft types. *Ann Plast Surg*. 2003;50:18–23; discussion 23–24.
25. Fernandes VM, Jorge PK, Carrara CF, Gomide MR, Machado MA, Oliveira TM. Three-dimensional digital evaluation of dental arches in infants with cleft lip and/or palate. *Braz Dent J*. 2015;26:297–302.
26. Patel KB, Mulliken JB. Correction of the vestibular web during primary repair of unilateral cleft lip. *Plast Reconstr Surg*. 2014;134:600e–607e.
27. Li AQ, Sun YG, Wang GH, Zhong ZK, Cutting C. Anatomy of the nasal cartilages of the unilateral complete cleft lip nose. *Plast Reconstr Surg*. 2002;109:1835–1838.
28. Atherton JD. A descriptive anatomy of the face in human fetuses with unilateral cleft lip and palate. *Cleft Palate J*. 1967;4:104–114.
29. Huffman WC, Lierle DM. Studies on the pathologic anatomy of the unilateral harelip nose. *Plast Reconstr Surg (1946)* 1949;4:225–234.
30. Stenstrom SJ, Oberg TR. The nasal deformity in unilateral cleft lip: Some notes on its anatomic bases and secondary operative treatment. *Plast Reconstr Surg Transplant Bull*. 1961;28:295–305.
31. Atherton JD. Morphology of facial bones in skulls with unoperated unilateral cleft palate. *Cleft Palate J*. 1967;4:18–30.
32. Veau V. Etude anatomique du bec-de-leivre unilateral total. *Annales d'Anatomie Pathologique et D'Anatomie Normale Medico-Chirurgicale*. 1928;6:601–632.
33. Kane AA, DeLeon VB, Valeri C, Becker DB, Richtsmeier JT, Lo LJ. Preoperative osseous dysmorphology in unilateral complete cleft lip and palate: A quantitative analysis of computed tomography data. *Plast Reconstr Surg*. 2007;119:1295–1301.
34. Weinberg SM, Leslie EJ, Hecht JT, et al. Hypertelorism and orofacial clefting revisited: An anthropometric investigation. *Cleft Palate Craniofac J*. 2017;54:631–638.
35. Anderl H, Hussl H, Ninkovic M. Primary simultaneous lip and nose repair in the unilateral cleft lip and palate. *Plast Reconstr Surg*. 2008;121:959–970.
36. Zhang L, Lu L, Li ZJ, et al. Anthropometric analysis of the maxillary bone and the alar base in unilateral cleft lip with secondary nasal deformity: Classification of a piriform margin bony depression. *Cleft Palate Craniofac J*. 2014;51:23–29.
37. Miyamoto J, Nagasao T, Nakajima T, Ogata H. Evaluation of cleft lip bony depression of piriform margin and nasal deformity with cone beam computed tomography: "Retruded-like" appearance and anteroposterior position of the alar base. *Plast Reconstr Surg*. 2007;120:1612–1620.
38. Xu Y, Li J, Zhao S, et al. Four-dimensional changes of nasolabial positions in unilateral cleft lip and palate. *J Craniofac Surg*. 2013;24:473–478.
39. Suri S, Utreja A, Khandelwal N, Mago SK. Craniofacial computerized tomography analysis of the midface of patients with repaired complete unilateral cleft lip and palate. *Am J Orthod Dentofacial Orthop*. 2008;134:418–429.
40. Agarwal R, Parihar A, Mandhani PA, Chandra R. Three-dimensional computed tomographic analysis of the maxilla in unilateral cleft lip and palate: Implications for rhinoplasty. *J Craniofac Surg*. 2012;23:1338–1342.
41. Urbanova W, Brudnicki A, Strydom H, Bronkhorst EM, Katsaros C, Fudalej PS. Nasolabial aesthetics correlates poorly with skeletal symmetry in unilateral cleft lip and palate. *J Plast Reconstr Aesthet Surg*. 2013;66:e1–e7.
42. Wu Y, Yang Y, Chen Y, Zhang Y, Wang G. Measurement and evaluation of the alar base in unilateral secondary lip nasal deformities by three-dimensional computed tomography. *Cleft Palate Craniofac J*. 2013;50:696–703.
43. Cohen M, Smith BE, Daw JL. Secondary unilateral cleft lip nasal deformity: Functional and esthetic reconstruction. *J Craniofac Surg*. 2003;14:584–593.
44. Krimmel M, Schuck N, Bacher M, Reinert S. Facial surface changes after cleft alveolar bone grafting. *J Oral Maxillofac Surg*. 2011;69:80–83.
45. Devlin MF, Ray A, Raine P, Bowman A, Ayoub AF. Facial symmetry in unilateral cleft lip and palate following alar base augmentation with bone graft: A three-dimensional assessment. *Cleft Palate Craniofac J*. 2007;44:391–395.
46. Kau CH, Medina L, English JD, Xia J, Gateno J, Teichgraber J. A comparison between landmark and surface shape measurements in a sample of cleft lip and palate patients after secondary alveolar bone grafting. *Orthodontics (Chic.)* 2011;12:188–195.
47. Kim SW, Park SO, Choi TH, Hai do T. Change in upper lip height and nostril sill after alveolar bone grafting in unilateral cleft lip alveolus patients. *J Plast Reconstr Aesthet Surg*. 2012;65:558–563.

48. Wu Y, Wang G, Yang Y, Zhang Y. Influence of alveolar-bone grafting on the nasal profile: Unilateral cleft lips, alveoli, and palates. *J Craniofac Surg.* 2010;21:1904–1907.
49. Chiu YT, Liao YF. Is cleft severity related to maxillary growth in patients with unilateral cleft lip and palate? *Cleft Palate Craniofac J.* 2012;49:535–540.
50. Zheng ZW, Fang YM, Lin CX. Isolated influences of surgery repair on maxillofacial growth in complete unilateral cleft lip and palate. *J Oral Maxillofac Surg.* 2016;74:1649–1657.
51. Moreira I, Suri S, Ross B, Tompson B, Fisher D, Lou W. Soft-tissue profile growth in patients with repaired complete unilateral cleft lip and palate: A cephalometric comparison with normal controls at ages 7, 11, and 18 years. *Am J Orthod Dentofacial Orthop.* 2014;145:341–358.
52. Li Y, Shi B, Song QG, Zuo H, Zheng Q. Effects of lip repair on maxillary growth and facial soft tissue development in patients with a complete unilateral cleft of lip, alveolus and palate. *J Craniomaxillofac Surg.* 2006;34:355–361.
53. Dalle Ore C, Schoenbrunner A, Brandel M, et al. Incidence of Le Fort surgery in a mature cohort of patients with cleft lip and palate. *Ann Plast Surg.* 2017;78(Suppl):S199–S203.
54. Liao YF, Prasad NK, Chiu YT, Yun C, Chen PK. Cleft size at the time of palate repair in complete unilateral cleft lip and palate as an indicator of maxillary growth. *Int J Oral Maxillofac Surg.* 2010;39:956–961.
55. Tomita Y, Kuroda S, Nakanishi H, Tanaka E. Severity of alveolar cleft affects prognosis of infant orthopedics in complete unilateral cleft lip and palate: Three-dimensional evaluation from cheiloplasty to palatoplasty. *J Craniofac Surg.* 2010;21:1503–1507.
56. Janiszewska-Olszowska J, Gawrych E, Wędrychowska-Szulc B, Stepien P, Konury J, Wilk G. Effect of primary correction of nasal septal deformity in complete unilateral cleft lip and palate on the craniofacial morphology. *J Craniomaxillofac Surg.* 2013;41:468–472.
57. Gawrych E, Janiszewska-Olszowska J. Primary correction of nasal septal deformity in unilateral clefts during lip repair: A long-term study. *Cleft Palate Craniofac J.* 2011;48:293–300.
58. Smahel Z, Müllerová Z, Nejedlý A. Effect of primary repositioning of the nasal septum on facial growth in unilateral cleft lip and palate. *Cleft Palate Craniofac J.* 1999;36:310–313.
59. Beidas OE, Thompson DM, El Amm CA. Anthropometric effect of mucoperiosteal nostril floor reconstruction in complete cleft lip. *J Craniofac Surg.* 2016;27:19–26.
60. Cutting CB, Bardach J, Pang R. A comparative study of the skin envelope of the unilateral cleft lip nose subsequent to rotation-advancement and triangular flap lip repairs. *Plast Reconstr Surg.* 1989;84:409–417; discussion 418–419.
61. Mulliken JB, LaBrie RA. Fourth-dimensional changes in nasolabial dimensions following rotation-advancement repair of unilateral cleft lip. *Plast Reconstr Surg.* 2012;129:491–498.
62. Cutting CB, Dayan JH. Lip height and lip width after extended Mohler unilateral cleft lip repair. *Plast Reconstr Surg.* 2003;111:17–23; discussion 24–26.
63. Morzycki A, Wong A, Hong P, Bezuhly M. Assessing attentional bias in secondary cleft lip deformities. *Cleft Palate Craniofac J.* 2019;56:257–264.
64. Holly R, Christine EP, Katherine SY, et al. Effects of infant cleft lip on adult gaze and perceptions of "cuteness." *Cleft Palate Craniofac J.* 2017;54:562–570.
65. van Schijndel O, Litschel R, Maal TJ, Bergé SJ, Tasman AJ. Eye tracker based study: Perception of faces with a cleft lip and nose deformity. *J Craniomaxillofac Surg.* 2015;43:1620–1625.
66. Meyer-Marcotty P, Gerdes AB, Stellzig-Eisenhauer A, Alpers GW. Visual face perception of adults with unilateral cleft lip and palate in comparison to controls: An eye-tracking study. *Cleft Palate Craniofac J.* 2011;48:210–216.
67. Dindaroğlu F, Doğan S, Amado S, Doğan E. Visual perception of faces with unilateral and bilateral cleft lip and palate: An eye-tracking study. *Orthod Craniofac Res.* 2017;20:44–54.
68. Wu J, Heike C, Birgfeld C, et al. Measuring symmetry in children with unrepaired cleft lip: Defining a standard for the three-dimensional midfacial reference plane. *Cleft Palate Craniofac J.* 2016;53:695–704.
69. Krimmel M, Breidt M, Bacher M, et al. Three-dimensional normal facial growth from birth to the age of 7 years. *Plast Reconstr Surg.* 2015;136:490e–501e.
70. Cho MJ, Hallac RR, Ramesh J, et al. Quantifying normal craniofacial form and baseline craniofacial asymmetry in the pediatric population. *Plast Reconstr Surg.* 2018;141:380e–387e.