OPEN

PRS GLOBAL OPEN

CASE REPORT

Pediatric/Craniofacial

Subtotal Mandible Reconstruction with a Free Fibula Flap and No Skin Incisions

Soobin Lim, MD*
Clairissa D. Mulloy, BS†
Zachary Stern-Buchbinder, MD‡
Hugo St. Hilaire, DDS, MD*
Mark W. Stalder, MD*

Summary: Resection of large mandibular tumors followed by primary reconstruction using free tissue transfer is typically accomplished using transcutaneous cervical incisions, which provide access for ablation as well as inset of the osseous free flap. This approach offers wide exposure; however, it subjects the patient to potential facial scarring, marginal mandibular nerve injury, lip deformity/incompetence, formation of orocutaneous fistulae, as well as functional impairments to speech, mastication, and deglutition. To reduce morbidity and to preserve aesthetics, a transoral approach can be used in cases that do not require a neck dissection. This technique can be coupled with transoral dissection of the facial vessels for intraoral microanastomoses to avoid extraoral incisions altogether. We present a case of a large 17.2 cm subtotal mandibulectomy and 3-segment fibular free flap reconstruction using virtual surgical planning, with patient-specific cutting guides and reconstruction plate performed entirely transorally without any skin incisions. Although technically challenging, this is a safe and effective technique for large segmental mandibular defects, which provides superior cosmetic and functional outcomes. *(Plast Reconstr Surg Glob Open 2020;8:e2964; doi: 10.1097/GOX.0000000000002964; Published online 23 July 2020.)*

Downloaded from https://journals.lww.com/prsgo by BhDMf5ePHKav1zEoum1tQfN4a+kJLhEZgbsIHo4XMi0hCywCX1AWnYQp/IlQrHD3JIOl9XFzqTXd1VCejg2K2IKUZdUDDVDNBPPqOxQbc= on 08/05/2020

Primary reconstruction of the mandible using free tissue transfer is typically performed transcutaneously using cervical incisions to provide access for both the resection and the inset of the osseous free flap. This approach allows for direct visualization of the proximal mandibular stumps for contouring and placement of the internal fixation hardware and direct access to the recipient vessels in the neck. Postoperative sequelae associated with this approach include facial scarring, marginal mandibular nerve injury, lip deformity/incompetence, formation of orocutaneous fistulae, as well as functional impairment of speech, mastication, and deglutition.[1]

To reduce morbidity and to preserve aesthetics, a transoral approach can be used in cases that do not require a neck dissection wherever it provides sufficient access for the necessary ablative and reconstructive procedures.[2] This technique can be coupled with a transoral approach to the facial vessels for intraoral microanastomoses. While technically challenging, this method avoids any cutaneous incisions, sparing the patient of the associated potential sequelae described above.[1]

The advent of virtual surgical planning (VSP) has resulted in greater efficiency and improved outcomes.[3] Compared to "freehand" mandibular reconstruction, VSP results in shorter ischemic time, total operative time, and length of hospital stay, with no difference in postoperative complication rates.[4] These techniques are important in the total transoral approach where mandibular exposure is comparatively limited.

We present a case of a 17.2-cm subtotal mandibulectomy and 3-segment fibular free flap reconstruction using virtual surgical planning, with patient-specific cutting guides and a custom-milled reconstruction plate performed entirely transorally without any skin incisions.

CASE

A 49-year-old woman with a history of mandibular lymphoma on intravenous bisphosphonate therapy presented with stage 2–3 medication-related osteonecrosis of the mandible, resulting in osteomyelitis and intraoral exposure of the symphysis and body of the mandible bilaterally. VSP was used to design osteotomy guides and

*From the *Division of Plastic and Reconstructive Surgery, Louisiana State University Health Sciences Center, New Orleans, La.; †School of Medicine, Louisiana State University Health Sciences Center, New Orleans, La.; and ‡Department of Surgery, Icahn School of Medicine at Mount Sinai, New York, N.Y.*

Received for publication February 5, 2020; accepted May 15, 2020.

Copyright © 2020 The Authors. Published by Wolters Kluwer Health, Inc. on behalf of The American Society of Plastic Surgeons. This is an open-access article distributed under the terms of the Creative Commons Attribution-Non Commercial-No Derivatives License 4.0 (CCBY-NC-ND), where it is permissible to download and share the work provided it is properly cited. The work cannot be changed in any way or used commercially without permission from the journal.

DOI: 10.1097/GOX.0000000000002964

Disclosure: *The authors have no financial interest to declare in relation to the content of this article.*

a patient-specific milled titanium reconstruction plate to restore the continuity and shape of the mandible through a transoral approach.[5]

First, an incision was made in the anterior labial sulcus and along the buccal and lingual margins of the denuded bone. A subperiosteal dissection was then performed, and the mandible exposed to allow for the placement of the osteotomy guides. The diseased bone was resected, and predictive holes were drilled in the proximal segments of the native mandible to facilitate precise placement of the patient-specific plate. The course of the facial artery was identified along the buccal mucosa using a Doppler. The facial artery and vein were then identified and dissected with enough length to allow for adequate mobilization. Branches of the facial nerve were identified and protected.

Simultaneous harvesting of the fibula osteocutaneous flap was performed in a standard fashion by a second surgeon. The bone was contoured on the back table using the fibula osteotomy guide and secured to the patient-specific plate using the predictive holes (Fig. 1A). The entire construct was then inset and fixed to the native mandible using the predrilled predictive holes. Next, the microvascular anastomosis was performed to the facial vessels through the intraoral exposure. The venous anastomosis was performed with a 3-0 coupler, and the arterial anastomosis was hand sewn. The inferior alveolar nerves were reconstructed bilaterally using a 70-mm cadaveric nerve graft (Axogen, Alachua, Fla.). The fibula skin paddle was inset intraorally after resuspension of the tongue to the reconstructed anterior segment. There were no intraoperative complications, and tracheostomy was not required.

Postoperatively, the fibula flap was monitored based on clinical evaluation of the intraoral skin paddle as well as the handheld Doppler. The postoperative computed tomography showed great fixation and position of the fibula flap (Fig. 1B). The patient had an uneventful postoperative course, and at 11 months follow up, she had partial sensation to the bilateral lower lip and an optimal aesthetic outcome (Fig. 2).

DISCUSSION

The mandible is vital for speech, mastication, deglutition, and airway support. Partial or total loss of the mandibular arch can result in compromise of these functions. In addition, the mandible is a major determinant of the aesthetic appearance of the lower third of the face. The goal in reconstruction of large mandibular defects is to restore form and function with an acceptable aesthetic result.

Bisphosphonates are therapeutic agents commonly used in patients with metastatic bone lesions. These drugs are potent inhibitors of osteoclast-mediated bone resorption but are associated with osteonecrosis of the jaw. Affected patients present with nonhealing, exposed, necrotic bone.[6] Current treatment recommendations focus on prevention and on a conservative approach. Surgical debridement or resection is required when disease is extensive.[7]

Microvascular osseous bone flaps are the first choice for large mandibular reconstructions as they demonstrate better aesthetic and functional scores with higher rates of bone union compared with nonvascularized bone graft.[8] While common donor sites include the fibula, iliac crest, and scapula, the fibula remains the workhorse flap for mandibular reconstruction for defects larger than 6 cm due to the availability of a long segment of bicortical bone ideal for the placement of osseointegrated implants, good pedicle length and caliber, and a reliable skin paddle when harvested based on septocutaneous perforators. In cases of drug-induced osteonecrosis, these flaps have been used successfully to restore both mucosal defects and the continuity of the mandible.[9]

There are reports of subtotal mandibular defects having been reconstructed with free fibula flaps via transoral approach but with a submandibular incision for the microvascular anastomosis.[2] Several reports of intraoral

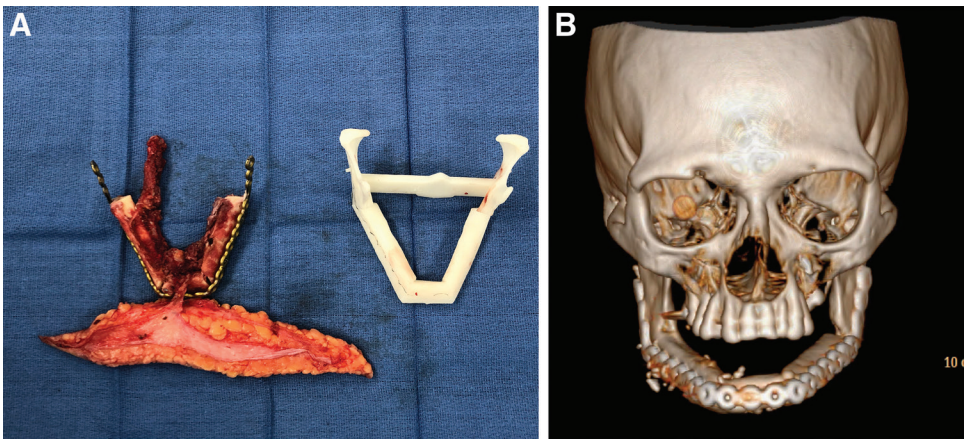

Fig. 1. Free fibula construct. A, The assembled fibula construct next to the printed model of the mandible. B, Postoperative CT scan demonstrates bone reconstruction in 3 segments of the large acquired mandibular defect. CT, computed tomography.

Fig. 2. Patient photographs. A, Preoperative photograph. B, Postoperative photograph depicting no external incisions.

anastomoses for microvascular mandibular, maxillary, and palatal reconstruction also exist for smaller defects.[10] To our knowledge, this is the first report of a 3-segment subtotal mandibular free flap reconstruction making use of VSP, patient-specific cutting guides, and reconstruction plate accomplished entirely without cutaneous incisions. This approach is ideal in cases where a neck dissection is not necessary, which may limit its use in head and neck cancers.

CONCLUSIONS

The intraoral approach for mandibular reconstruction and microvascular anastomosis using virtual planning and patient-specific plates is a safe and effective technique for large segmental mandibular defects. When feasible, this operation provides optimal cosmetic and functional outcomes.

Mark W. Stalder, MD
LSUHSC Department of Surgery
Division of Plastic and Reconstructive Surgery
1542 Tulane Ave., Room 734
New Orleans, LA 70112
E-mail: mstald@lsuhsc.edu

PATIENT CONSENT

The patient provided written consent for the use of her image.

REFERENCES

1. Cohen LE, Morrison KA, Taylor E, et al. Functional and aesthetic outcomes in free flap reconstruction of intraoral defects with lip-split versus non-lip-split incisions. *Ann Plast Surg.* 2018;80(4 suppl 4):S150–S155.
2. Bianchi B, Ferri A, Ferrari S, et al. Subtotal mandibular reconstruction using an intraoral approach: report of 2 cases. *J Oral Maxillofac Surg.* 2008;66:2654–2656.
3. Chan A, Sambrook P, Munn Z, et al. Effectiveness of computer-assisted virtual planning, cutting guides and pre-engineered plates on outcomes in mandible fibular free flap reconstructions: a systematic review protocol. *JBI Database System Rev Implement Rep.* 2019;17:2136–2151.
4. Powcharoen W, Yang WF, Yan Li K, et al. Computer-assisted versus conventional freehand mandibular reconstruction with fibula free flap: a systematic review and meta-analysis. *Plast Reconstr Surg.* 2019;144:1417–1428.
5. Ren W, Gao L, Li S, et al. Virtual planning and 3D printing modeling for mandibular reconstruction with fibula free flap. *Med Oral Patol Oral Cir Bucal.* 2018;23:e359–e366.
6. Ruggiero SL. Diagnosis and management of antiresorptive-related osteonecrosis of the jaw. *Gen Dent.* 2013;61:24–29.
7. Yarom N, Shapiro CL, Peterson DE, et al. Medication-related osteonecrosis of the jaw: MASCC/ISOO/ASCO clinical practice guideline. *J Clin Oncol.* 2019;37:2270–2290.
8. Foster RD, Anthony JP, Sharma A, et al. Vascularized bone flaps versus nonvascularized bone grafts for mandibular reconstruction: an outcome analysis of primary bony union and endosseous implant success. *Head Neck.* 1999;21:66–71.
9. Mücke T, Haarmann S, Wolff KD, et al. Bisphosphonate related osteonecrosis of the jaws treated by surgical resection and immediate osseous microvascular reconstruction. *J Craniomaxillofac Surg.* 2009;37:291–297.
10. Brandtner C, Bürger H, Hachleitner J, et al. The intraoral anastomosing technique in reconstructive surgery of the face—a consecutive case series of 70 patients. *J Craniomaxillofac Surg.* 2015;43:1763–1768.