OPEN

PRS GLOBAL OPEN

ORIGINAL ARTICLE

Reconstructive

Use of Flow-through Free Flaps in Head and Neck Reconstruction

Mark A. Maier, BS*
Patrick A. Palines, MD†
Richard F. Guidry, MD†
Mark W. Stalder, MD†‡

Background: Reconstructive obstacles in composite head and neck defects are compounded in reoperated, traumatized, irradiated, and vessel-depleted surgical fields. In cases that require multiple free flaps, recipient vessel accessibility and inset logistics become challenging. Strategic flow-through flap configurations mitigate these issues by supplying arterial inflow and venous outflow to a second flap in a contiguous fashion. This approach (1) permits the use of a singular native recipient vessel, (2) increases the reach of the vascular pedicle, avoiding the need for arteriovenous grafting, and (3) allows for a greater three-dimensional flexibility in configuring soft tissue and bony flap inset.

Methods: To demonstrate this technique, we conducted a retrospective review of all head and neck reconstruction patients presenting to us from March 2019 to April 2021.

Results: We present seven oncological and two traumatic patients (N = 9) who received flow-through free flaps for head and neck reconstruction. The most common flap used as the flow-through flap was the anterolateral thigh flap (N = 7), followed by the fibula flap (N = 2). Mean follow-up time was 507 days. No flap failures occurred.

Conclusion: In head and neck reconstruction, the use of the flow-through principle enables uninterrupted vascular flow for two distinct free flaps in single-stage reconstruction for patients with vessel-depleted, irradiated, and/or reoperated fields. We demonstrate that flow-through flaps in the head and neck may be used successfully for a variety of cases and flaps. *(Plast Reconstr Surg Glob Open 2024; 12:e5588; doi: 10.1097/GOX.0000000000005588; Published online 19 March 2024.)*

INTRODUCTION

Oncological and traumatic defects are the leading indications for adult head and neck reconstruction.[1] Maxillary, mandibular, and oral soft-tissue defects have a major impact on patients' lives, affecting speech articulation, respiration, deglutition, mastication, and facial aesthetics. Surgeons often must reconstruct these deficits using multiple flaps anastomosed to multiple recipient vessels.[2–4] Our approach involves the use of either a fasciocutaneous or osseus flow-through flap as a vascular conduit to perfuse a second flap for complex head and neck reconstructions (Fig. 1). This technique permits the use of a singular native recipient vessel in patients with suboptimal recipient sites due to extensive disease or trauma, prior radiation, or previous operations.[5–7] In addition, use of flow-through free flaps increases inflow vessel length and reduces the need for arteriovenous grafting to allow for a greater flexibility in configuring soft tissue and bony flap inset.

Reconstructive goals of extensive head and neck defects should include (1) providing oral competence, (2) obliteration of dead space, (3) reconstruction of bony structural support, and (4) reestablishment of premorbid function and aesthetics. The purpose of this article is to describe the potential benefits of a flow-through flap configuration to improve outcomes in head and neck reconstruction within the context of our institutional experience, using this technique.

METHODS

Our series includes nine patients who underwent two simultaneous free flaps, arranged in a flow-through

*From the *School of Medicine, Louisiana State University Health Sciences Center, New Orleans, La.; †Division of Plastic and Reconstructive Surgery, Louisiana State University Health Sciences Center, New Orleans, La.; and ‡University Medical Center—LCMC Health, New Orleans, La.*

Received for publication March 30, 2023; accepted December 11, 2023.

This work was presented at the American Association of Plastic Surgeons Centennial Meeting 2022, April 9–12, 2022, San Diego, California.

Copyright © 2024 The Authors. Published by Wolters Kluwer Health, Inc. on behalf of The American Society of Plastic Surgeons. This is an open-access article distributed under the terms of the Creative Commons Attribution-Non Commercial-No Derivatives License 4.0 (CCBY-NC-ND), where it is permissible to download and share the work provided it is properly cited. The work cannot be changed in any way or used commercially without permission from the journal.

DOI: 10.1097/GOX.0000000000005588

Disclosure statements are at the end of this article, following the correspondence information.

configuration, from March 2019 to April 2021. These patients were reconstructed by the senior author (M.W.S.). Patient characteristics (including age/sex, history, tobacco/radiation, and defect description) were collected. Indications for this technique were complex composite soft-tissue and bony defects in vessel-depleted, traumatized, irradiated, and/or reoperated fields.

When preparing the recipient site for reconstruction in these complex cases, it is important to note the available recipient vessels, acquire vascular imaging (if needed), and obtain the required flow-through flap pedicle length.[2,4] The neck that is previously irradiated or operated on does not preclude the use of recipient vasculature from the ipsilateral side.[2,8] However, recipient sites away from the zone of injury/radiation, as with the case of the transverse cervical vessels, may decrease the risk of vascular complications.[9]

In our series, free flaps were harvested in a standard fashion.[10–14] Fasciocutaneous flaps were used for external or intraoral coverage, whereas bony flaps were used to reestablish appropriate structural support for overlying soft tissue. In these cases, we performed vascular anastomosis in vivo by either initially anastomosing the flow-through flap to the recipient vessels or initially anastomosing the flow-through flap to the second flap on a sterile back table. We routinely use enoxaparin 40 mg daily for antithrombotic prophylaxis. An exception to this is when patients have a documented history of hypercoagulability, and further interventions to prevent postoperative thromboembolism are taken.[8,15] In addition, we perform flap checks every 1 hour the first 24 hours postoperatively, every 2 hours between 24 and 48 hours postoperatively, and every 4 hours for the remainder of the hospital admission.

Takeaways

Question: How can flow-through free flaps be optimally used in patients with complex head and neck defects involving vessel-depleted, irradiated, and/or reoperated fields?

Findings: This retrospective study consisted of nine patients, using variable flow-through flap configurations and recipient vessels for reconstruction. These techniques allowed for composite reconstruction of complex head and neck defects. There were no flap failures.

Meaning: We demonstrate successful use of flow-through free flaps with variable donor sites to permit the use of a singular recipient vessel, increase the reach of the vascular pedicle avoiding the need for arteriovenous grafting, and improve three-dimensional flexibility in configuring soft tissue and bony flap inset.

RESULTS

Seven oncological and two traumatic patients (n = 9) received two flaps arranged in a flow-through configuration. The mean age of patients was 57 years (range, 48–71 years), with demographics summarized in Table 1. Flaps harvested at our institution for reconstruction included anterolateral thigh (ALT; n = 7; 78%), fibula (n = 7; 78%), deep circumflex iliac artery (DCIA; n = 2; 22%), peroneal artery perforator (n = 1; 11%), and medial sural artery perforator (MSAP; n = 1; 11%) flaps (Table 2). Flow-through free flap configurations involved ALT→fibula (n = 5; 56%), ALT→DCIA (n = 2; 22%), fibula→peroneal artery perforator (n = 1; 11%), fibula→MSAP (n = 1; 11%). Recipient vessels included facial artery and vein (n = 7; 78%), transverse cervical artery and vein (n = 1; 11%), and occipital artery, external jugular vein, and internal jugular vein branch (n = 1; 11%.) Mean follow-up was 507 days (range, 118–989 days), excluding those deceased from nonsurgical complications. Complications included recipient site dehiscence (n = 5; 55%), orocutaneous fistula (n = 2; 22%), hematoma (n = 2; 22%), surgical site infection within

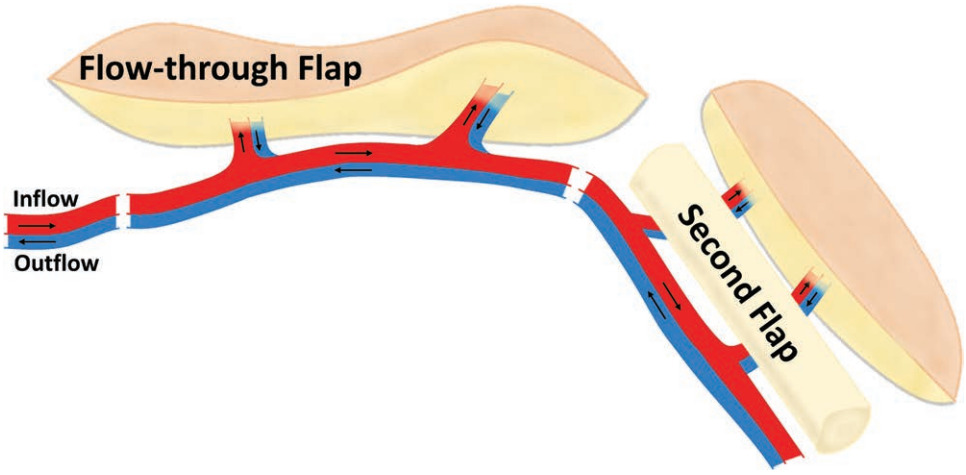

Fig. 1. Flow-through flap concept schematic. Inflow and outflow are demonstrated through arterial and venous perforators. Flow-through flap and second flap are labeled, which demonstrate a fasciocutaneous to bony flap configuration. In this series, the flow-through flap component was consistently used for facial and extraoral skin coverage, whereas the second flap provided intraoral skin coverage. An osteocutaneous flap may also be used as the flow-through flap.

Table 1. Patients Who Had Flow-through Flap Reconstruction

Age/Sex	History	Tobacco	Radiation	Head and Neck Defect
50/F	GSW	N	N	L hemimaxilla; L parasymphyseal mandibulectomy
48/M	Adenoid cystic carcinoma	N	Y	R maxillectomy; R frontal craniotomy
71/F	Liposarcoma, ORN	N	Y	L parasymphyseal to L subcondylar mandibulectomy
62/M	SCC, ORN	N	Y	L ramus to L body mandibulectomy
58/F	SCC	Y	N	R angle to L body mandibulectomy
62/M	SCC	Y	Y	R angle to L angle mandibulectomy, full-thickness anterior neck, and lower lip defect
49/M	SCC, ORN	N	Y	Bilateral body mandibulectomy
56/M	GSW	Y	N	Anterior segment mandibulectomy
58/M	SCC, prior flap failure	Y	Y	L ramus to R ramus mandibulectomy

F, female; M, male; GSW, gunshot wound; ORN, osteoradionecrosis; SCC, squamous cell carcinoma; Y, yes; N, no; L, left; R, right.

Table 2. Operative Details and Postoperative Course for Flow-through Recipients

Age/Sex	Timing of Reconstruction	Recipient Vessels	Flow-through Flap	Second Flap	Vascular Complications	Other Complications	Second-stage Revisions	Follow-up (d)
50/F	Delayed	L facial a. and v.	Fibula *one-segment*	Peroneal artery perforator		Flap dehiscence	Flap debulking, iliac crest bone graft to maxilla and left orbit, revision rhinoplasty, scar revision, hardware removal	989
48/M	Delayed	R facial a. and v.	Fibula *one-segment*	MSAP		Donor site dehiscence	Revision rhinoplasty with a cartilage graft	377
71/F	Delayed	L facial a. and v.	ALT	Fibula *one-segment*		Recipient site infection, flap dehiscence, orocutaneous fistula	Hardware removal	885
62/M	Immediate	L facial a. and v.	ALT	Fibula *one-segment*			Adjacent tissue transfer, hardware removal	732
58/F	Immediate	R facial a. and v.	ALT	Fibula *two-segments*		Flap dehiscence		118
62/F	Delayed	R transverse cervical a. and v.	ALT	Fibula *three-segments*	Arterial thrombosis, hematoma	Flap dehiscence		60*
49/M	Immediate	R occipital a., R external and internal jugular v.	ALT	Fibula × 2 *one-segment each*		Flap dehiscence		319
56/M	Delayed	R facial a. and v.	ALT	DCIA *one-segment*			Maxillary reconstruction using fibula flaps	163†
58/M	Delayed	L facial a. and v.	ALT	DCIA *three-segments*	Hematoma x 2	Orocutaneous fistula	Adjacent tissue transfer	126

*Deceased secondary to pneumonia.
†Deceased secondary to urosepsis.
L, left; R, right; a., artery; v., vein; ALT, anterolateral thigh; STSG, split-thickness skin graft.

30 days of surgery (n = 1; 11%), and arterial thrombosis (n = 1; 11%), as summarized in Table 2. All complications were managed with operative intervention and a course of antibiotics in the case of infection. There were no flap failures.

DISCUSSION

When a single flap is insufficient for tissue coverage of open wounds, multiple flaps should be considered for reconstruction.[3] This approach affords the opportunity to reconstruct large-volume defects using multiple tissue types without the need to significantly compromise a single donor site during flap harvest.[5,16,17] Flow-through flap constructs are a viable, reliable option for oncological or traumatic bony and soft-tissue head and neck defects. Their use can improve outcomes in these complex, composite defects in patients with vessel-depleted, irradiated, and/or reoperated fields.

Although some cases may be feasible with a single free flap, using two free flaps does not cause an increase in flap-related complications and may reduce donor site morbidity by reducing individual flap sizes.[18–20] However, this is not thoroughly described when the flaps are arranged in a flow-through fashion. Compared with a single flap, use of two flaps facilitates reconstruction of large defects that include intraoral mucosa, facial bone, and extraoral skin through ease of positioning and inset. We consistently used the

flow-through flap to provide extraoral skin coverage in this series, but the second flap was used for intraoral skin coverage. However, the best inset would likely have the second flap providing extraoral skin coverage for flap monitoring of this distal skin paddle, thereby facilitating simpler monitoring of both flaps. Although there are numerous options for flow-through flaps,[7,16] we often use ALT flaps as the flow-through component because the vascular pedicle typically provides good length and caliber, and will often have large branching vessels that can be used in the secondary anastomosis.[21] Likewise, at times we have used the free fibula flap as the flow-through component due to the similar aspects of its beneficial vascular anatomy.[17] We used the fibula flap as the flow-through component in two cases because the peroneal artery perforator flap was discovered to be optimal for intraoral coverage when multiple perforators were discovered along the fibula flap, and an ALT flap was unavailable in the 48-year-old man due to previous reconstructions. However, it should be noted that there are numerous flap options that can be used in a flow-through configuration, and selection will be based on the tissue requirements of the defect. Ultimately, it will be a combination of inset logistics, and vessel caliber and length that will lead to the decision of which flap will be used as the flow-through component.

As the preferred flap for head and neck reconstruction, the fibula flap was used as the bony component and second flap within most flow-through cases. In two cases, we used the DCIA flap as the bony component because the 56-year-old male patient required follow-up repair of the maxillary defects using the fibula flaps, whereas the 58-year-old male patient previously had two remote fibula flap failures, making the fibula flap either undesirable or unsuitable for use in both cases. In our case using the peroneal artery perforator flap as the second flap, we used this because there were additional peroneal perforators located near the fibula flap. This peroneal perforator flap provided intraoral coverage as a second flap, receiving blood flow from an osteocutaneous fibula flap that provided external skin coverage and mandibular bone. The MSAP flap was used in one case because this patient presented for tertiary reconstruction of the maxilla after a previous facial reconstruction using two ALT flaps (one fibula flap and one DCIA flap), which necessitated use of a fasciocutaneous flap with available perforators.

Choosing a recipient site for vessel anastomosis was often dictated by available vasculature due to defect size or previous irradiation, and size mismatch. In most cases, the facial artery and vein are optimal recipient vessels due to their anatomic location near the lower facial structures. When unavailable, either due to trauma or radiation, surgeons may opt to use other branches of the external carotid artery for inflow, such as the occipital artery, or directly

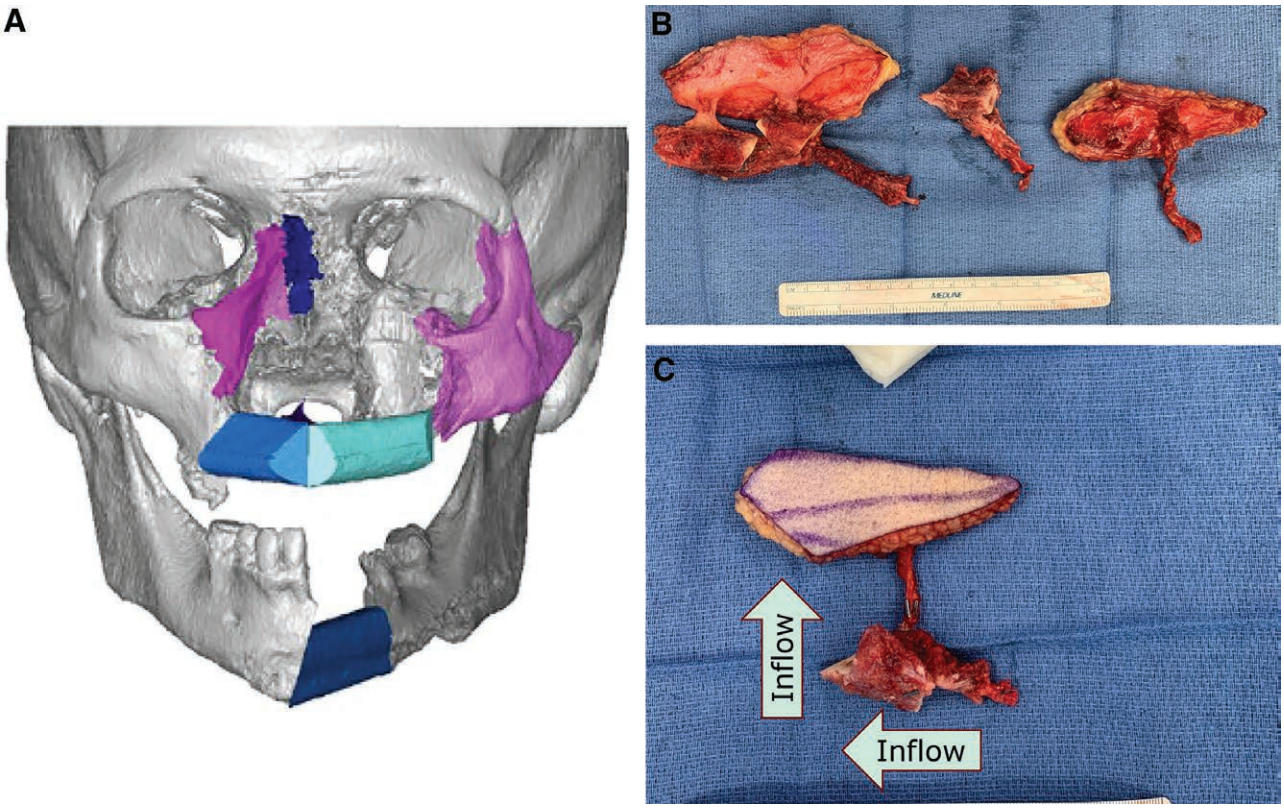

Fig. 2. A 50-year-old female patient after a gunshot wound to the face with the left facial artery as the recipient site, a one-segment fibula flap as the flow-through component, and a fasciocutaneous peroneal artery perforator flap as the distal flap. A, Virtual surgical planning highlighting the use of soft-tissue and bony flow-through free flaps in mandibular reconstruction. B, A photograph demonstrating fibula flap split into osteocutaneous and osseus segments to the left and a peroneal artery perforator flap on the right. C, Construct demonstrating fibula flap as the flow-through component to the peroneal artery perforator flap.

anastomose outflow to the external jugular vein. Although we have experienced some vessel mismatch, all anastomoses to the recipient vessel were successful and technically feasible. In vessel-depleted necks we have successfully used the transverse cervical vessels due to their location away from radiation or a surgically compromised field.[4,9] To improve operative time and flap design, the primary surgeon may also consider the use of virtual surgical planning and patient specific titanium plates when bony flaps are involved.[8,22] The ultimate goal of these cases is to improve speech articulation, respiration, deglutition, mastication, and facial aesthetics by reducing an exposed oral cavity.

For instance, a 50-year-old woman presented after a gunshot wound to the face requiring extensive bony reconstruction of the mandible and maxilla as well as soft-tissue coverage of the extraoral and intraoral skin (Fig. 2A). Intraoperatively, a fibula flap was dissected and partitioned to form a two-segment maxillary fibula flap with preservation of a 5-cm pedicle (Fig. 2B). Having separate flaps aided in inset, bony reconstruction, and ensuring adequate coverage. On the back table, the peroneal flow-through flap was anastomosed to the two-segment fibula flap for mandibular reconstruction due to limited recipient vessel availability (Fig. 2C). The final inset involved the left facial artery as the recipient site, a one-segment fibula flap as the flow-through flap, and a fasciocutaneous peroneal artery perforator flap as the distal flap (Fig. 3). Her initial course was complicated by flap dehiscence, although there was no flap loss. She has received extensive second-stage revisions such as flap debulking, bone grafts, revision rhinoplasty, scar revision, and hardware removal.

To further highlight this series, the 49-year-old man required a recipient site distal from the defect due to a history of a carotid endarterectomy and radiation to the area, leaving no viable inflow vessels, thus necessitating the use of the occipital artery of appropriate caliber for arterial anastomosis while using the external and internal jugular veins for venous anastomosis. This patient, specifically, required the use of three flaps: one ALT flap for extraoral coverage of the right neck skin, and two fibula flaps for intraoral skin coverage and reconstruction of the mandible.

This study is limited because of a limited sample size, retrospective nature, the descriptive nature of the data reported, and lack of a control group. As a retrospective review, information on defect and flap dimensions was often absent from the electronic medical records. Regarding defect sizes, these were missing mainly due to the three-dimensional nature of the defects after trauma or oncological resection. Although there was a high rate of dehiscence and orocutaneous fistulas in our series, these complications are well known after head and neck reconstruction and more prevalent in the setting of tobacco use, radiation, and malnutrition, as seen in our patient population.[23–25] Understanding predictive factors of wound healing outcomes, such as patient history, tissue necrosis, and infection state, should influence appropriate treatment plans to aid in reducing surgical site infections and dehiscence.[26] Managing postoperative venous congestion may prove difficult to manage and lead to sequelae or flap loss; however, this may be managed intraoperatively by assuring the flap is inset without twisting and incorporating multiple outflow tracts, as done in some of our cases.[27] Sequential anastomosis of the flow-through and second flaps may aid in inset and avoiding vessel kinking in these cases, thus potentially reducing venous congestion. Another technique in this regard is to perform anastomosis of the two flaps on the back table to save operative time. Anastomosis techniques should be further considered for this purpose. In complex reconstructive cases such as these, it is beneficial to identify patients who are at high risk for readmission before surgery. To achieve this goal, using tools such as the LACE+ (length of stay, acuity of admission, Charlson Comorbidity Index, and emergency department visits in the past 6 months) index may aid in resource allocation and preoperative planning.[28] In summary, we demonstrate technical and planning considerations to help reconstructive surgeons approach the use of flow-through flaps in a subset of complicated head and neck cases.

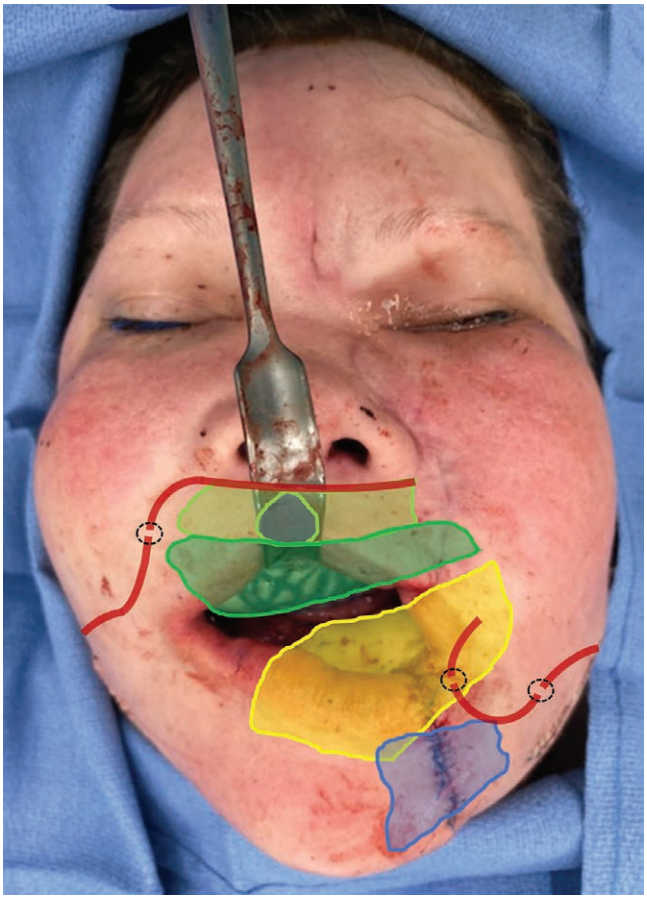

Fig. 3. Intraoperative photograph after initial reconstruction with overlay of flow-through flap construct: one-segment osseus flow-through fibula flap (blue), peroneal artery perforator flap (yellow), two-segment osteocutaneous fibula flap (green), and arterial anastomoses to the right and left facial arteries (red lines and black circles).

Mark W. Stalder, MD
Division of Plastic and Reconstructive Surgery
Louisiana State University Health Sciences Center
School of Medicine
2021 Perdido Ave, Room 8120
New Orleans, LA 70112
E-mail: mstald@lsuhsc.edu

DISCLOSURES

The authors have no financial interest to declare in relation to the content of this article. This work was not supported by any funding sources. None of the authors has a financial interest in any of the products, devices, or drugs mentioned in this article.

PATIENT CONSENT

The patient provided written consent for the use of images in this research study.

ACKNOWLEDGMENT

We certify that our institutional review board approved all content and procedures described within this article (protocol no.: 2244).

REFERENCES

1. Hurvitz KA, Kobayashi M, Evans GRD. Current options in head and neck reconstruction. *Plast Reconstr Surg.* 2006;118:122e–133e.
2. Yazar S, Wei FC, Chen HC, et al. Selection of recipient vessels in double free-flap reconstruction of composite head and neck defects. *Plast Reconstr Surg.* 2005;115:1553–1561.
3. Wei FC, Yazar S, Lin CH, et al. Double free flaps in head and neck reconstruction. *Clin Plast Surg.* 2005;32:303–308, v.
4. Yazar S. Selection of recipient vessels in microsurgical free tissue reconstruction of head and neck defects. *Microsurgery.* 2007;27:588–594.
5. Ao M, Asagoe K, Maeta M, et al. Combined anterior thigh flaps and vascularised fibular graft for reconstruction of massive composite oromandibular defects. *Br J Plast Surg.* 1998;51:350–355.
6. Ceulemans P, Hofer SOP. Flow-through anterolateral thigh flap for a free osteocutaneous fibula flap in secondary composite mandible reconstruction. *Br J Plast Surg.* 2004;57:358–361.
7. Bullocks J, Naik B, Lee E, et al. Flow-through flaps: a review of current knowledge and a novel classification system. *Microsurgery.* 2006;26:439–449.
8. Maier MA, Guidry RF, Palines PA, et al. Autologous mandible reconstruction in a hypercoagulable patient following multiple failed free flaps. *Plast Reconstr Surg Glob Open.* 2022;10:e3872.
9. Tessler O, Gilardino MS, Bartow MJ, et al. Transverse cervical artery: consistent anatomical landmarks and clinical experience with its use as a recipient artery in complex head and neck reconstruction. *Plast Reconstr Surg.* 2017;139:745e–751e.
10. Wong C, Wei F. Anterolateral thigh flap. *Head Neck.* 2010;32:529–540.
11. Hidalgo D. Free fibula flap: a new method of mandible reconstruction. *Plast Reconstr Surg.* 1989;84:71–79.
12. Taylor GI, Townsend P, Corlett R. Superiority of the deep circumflex iliac vessels as the supply for free groin flaps clinical work. *Plast Reconstr Surg.* 1979;64:745–759.
13. Ribuffo D, Atzeni M, Saba L, et al. Clinical study of peroneal artery perforators with computed tomographic angiography: implications for fibular flap harvest. *Surg Radiol Anat.* 2010;32:329–334.
14. Daar DA, Abdou SA, Cohen JM, et al. Is the medial sural artery perforator flap a new workhorse flap? A systematic review and meta-analysis. *Plast Reconstr Surg.* 2019;143:393e–403e.
15. Pannucci CJ, Kovach SJ, Cuker A. Microsurgery and the hypercoagulable state: a hematologist's perspective. *Plast Reconstr Surg.* 2015;136:545e–552e.
16. Costa H, Zenha H, Azevedo L, et al. Flow-through sequentially linked free flaps in head and neck reconstruction. *Eur J Plast Surg.* 2012;35:31–41.
17. Parr JM, Adams BM, Wagels M. Flow-through flap for salvage of fibula osseocutaneous vascular variations: a surgical approach and proposed modification of its classification. *J Oral Maxillofac Surg.* 2014;72:1197–1202.
18. Stalder MW, Mundinger GS, Bartow M, et al. Single versus simultaneous double free flaps for head and neck reconstruction: comparison of flap outcomes and donor-site morbidity. *Ann Plast Surg.* 2019;82:184–189.
19. Tharakan T, Marfowaa G, Akakpo K, et al. Multiple simultaneous free flaps for head and neck reconstruction: a multi-institutional cohort. *Oral Oncol.* 2023;136:106269.
20. Gulati A, Heaton CM, Park AM, et al. Outcomes associated with multiple free tissue transfers performed in a single day. *Facial Plast Surg Aesthet Med.* 2023;25:472–477.
21. Van Landuyt K. The anterolateral thigh flap for lower extremity reconstruction. *Semin Plast Surg.* 2006;20:127–132.
22. Palines PA, Ferrer JR, Yoo A, et al. Simplifying bony midface reconstruction with patient-specific titanium plates. *Plast Reconstr Surg Glob Open.* 2021;9:e3555.
23. Wernick B, Nahirniak P, Stawicki SP. Impaired wound healing. Treasure Island, Fla.: StatPearls Publishing. 2023. Available at https://www.ncbi.nlm.nih.gov/books/NBK482254/.
24. Crippen MM, Patel N, Filimonov A, et al. Association of smoking tobacco with complications in head and neck microvascular reconstructive surgery. *JAMA Facial Plast Surg.* 2019;21:20–26.
25. Fang Q, Yuan J, Du W, et al. Orocutaneous fistula formation in free flap reconstruction for oral squamous cell carcinoma. *Front Oncol.* 2022;12:887118.
26. Guarro G, Cozzani F, Rossini M, et al. The modified TIME-H scoring system, a versatile tool in wound management practice: a preliminary report. *Acta Bio Medica: Atenei Parmensis.* 2021;92:2021226.
27. Boissiere F, Gandolfi S, Riot S, et al. flap venous congestion and salvage techniques: a systematic literature review. *Plast Reconstr Surg Glob Open.* 2021;9:e3327.
28. Winter E, Glauser G, Caplan IF, et al. The LACE+ index as a predictor of 30-day patient outcomes in a plastic surgery population: a coarsened exact match study. *Plast Reconstr Surg.* 2020;146:296e–305e.